This is a digital copy of a book that was preserved for generations on library shelves before it was carefully scanned by Google as part of a project to make the world's books discoverable online.

It has survived long enough for the copyright to expire and the book to enter the public domain. A public domain book is one that was never subject to copyright or whose legal copyright term has expired. Whether a book is in the public domain may vary country to country. Public domain books are our gateways to the past, representing a wealth of history, culture and knowledge that's often difficult to discover.

Marks, notations and other marginalia present in the original volume will appear in this file - a reminder of this book's long journey from the publisher to a library and finally to you.

Usage guidelines

Google is proud to partner with libraries to digitize public domain materials and make them widely accessible. Public domain books belong to the public and we are merely their custodians. Nevertheless, this work is expensive, so in order to keep providing this resource, we have taken steps to prevent abuse by commercial parties, including placing technical restrictions on automated querying.

We also ask that you:

+ *Make non-commercial use of the files* We designed Google Book Search for use by individuals, and we request that you use these files for personal, non-commercial purposes.

+ *Refrain from automated querying* Do not send automated queries of any sort to Google's system: If you are conducting research on machine translation, optical character recognition or other areas where access to a large amount of text is helpful, please contact us. We encourage the use of public domain materials for these purposes and may be able to help.

+ *Maintain attribution* The Google "watermark" you see on each file is essential for informing people about this project and helping them find additional materials through Google Book Search. Please do not remove it.

+ *Keep it legal* Whatever your use, remember that you are responsible for ensuring that what you are doing is legal. Do not assume that just because we believe a book is in the public domain for users in the United States, that the work is also in the public domain for users in other countries. Whether a book is still in copyright varies from country to country, and we can't offer guidance on whether any specific use of any specific book is allowed. Please do not assume that a book's appearance in Google Book Search means it can be used in any manner anywhere in the world. Copyright infringement liability can be quite severe.

About Google Book Search

Google's mission is to organize the world's information and to make it universally accessible and useful. Google Book Search helps readers discover the world's books while helping authors and publishers reach new audiences. You can search through the full text of this book on the web at `http://books.google.com/`


BIBLIOTHECA · BOSTONIENSIS · MEDICINAE
SERVAT · ET · DOCET
FVNDATA
MDCCCLXXX
EX DONO

TRANSACTIONS

OF THE

AMERICAN

OPHTHALMOLOGICAL SOCIETY.

Vol. X.

HARTFORD:
PUBLISHED BY THE SOCIETY.
1905.

PRESS OF THE CASE, LOCKWOOD & BRAINARD COMPANY.

TRANSACTIONS

OF THE

AMERICAN

OPHTHALMOLOGICAL SOCIETY.

Thirty-ninth Annual Meeting.

WASHINGTON, D. C., 1903.

Vol. X, Part I.

HARTFORD:
PUBLISHED BY THE SOCIETY.
1903.

3361

Press of The Case, Lockwood & Brainard Company.

9074

TABLE OF CONTENTS.

	PAGE.
List of members,	5
Memoir of Dr. W. F. Norris, by Dr. S. D. Risley,	9
Minutes of the proceedings,	24
The present status of subconjunctival injections in ophthalmic therapeutics; Dr. C. S. Bull,	31
Case of pulsating exophthalmos, of traumatic origin; ligation of the common carotid; recovery; Dr. C. S. Bull,	38
Concerning the possible etiological factors in tobacco amblyopia revealed by an analysis of the urine of cases of this character; Dr. de Schweinitz,	41
Hypertrophy and degeneration of the meibomian glands; Dr. H. Knapp,	57
Why not employ intra-capsular irrigation in cataract operations? Dr. H. O. Reik,	64
Orbital-osteoma of ethmoidal origin; Dr. Percy Fridenberg,	83
Diseases of the eye in the white and negro races; Dr. H. D. Bruns,	87
Suggestions for a uniform nomenclature of the movements and motor anomalies of the eye; Dr. A. Duane,	102
A case of acute glaucoma incited by the use of euphthalmine for diagnostic purposes; Dr. H. W. Ring,	109
Vicarious menstruation into the retina, followed by detachment and retinitis striata; Dr. Percy Fridenberg,	116
Correction of sixteen diopters of astigmatism by galvano-cautery; Dr. C. F. Clark,	125
A case of acute panophthalmitis following discission of the capsule; Dr. L. H. Taylor,	130
Skin-grafting in ophthalmic surgery; Dr. F. Buller,	134
A case of leuco-sarcoma of the choroid; Dr. T. R. Pooley,	137
Tuberculosis of the eye — two cases; Dr. J. A. Spalding,	141
Tuberculosis of the conjunctiva; Dr. Edw. Jackson,	146
A type of degeneration involving the central zone of the choroid and retina; Dr. Edw. Jackson,	150
Are tenotomies for hyperphoria necessarily more uncertain in their results than those for esophoria and exophoria? Dr. S. Theobald,	154
Interstitial keratitis complicating ophthalmia neonatorum; Dr. A. A. Hubbell,	158

PAGE.

Argyrosis of conjunctiva and lachrymal sac, following use of protargol; Dr. G. E. de Schweinitz, ... 161

A case of double traumatic optic neuritis, followed by absolute blindness and recovery; Dr. W. H. Wilmer, ... 165

A case of traumatic ptosis, operated according to method of Dr. Gruening or Gillet de Grandmont; Dr. W. P. Marple, . . . 169

A case of retinitis pigmentosa; Dr. W. L. Pyle, ... 172

A case of orbital cellulitis, with empyema of the ethmoid and frontal sinuses; death; Dr. E. Gruening, ... 175

A case of spontaneous prolapse of both lachrymal glands; Dr. D. Roy, ... 179

Optic atrophy following intestinal hemorrhage; Dr. W. M. Sweet, . 183

An improved lantern for testing color-perception; Dr. C. H. Williams, 187

Report of the committee on standard test-types and on reading tests; Dr. C. H. Williams, chairman, ... 189

Appendix to report by Dr. John Green, ... 190

MEMBERS

OF THE

American Ophthalmological Society.

1903-1904.

ACTIVE MEMBERS.

The (*) indicates *Associate* Members.

NAME.	RESIDENCE.	PLACE.
Dr. A. E. ADAMS,	44 Grand Street,	Newburg, N. Y.
*Dr. J. L. ADAMS,	24 East 46th Street,	New York, N. Y.
Dr. L. A. W. ALLEMAN,	64 Montague Street,	Brooklyn, N. Y.
Dr. A. N. ALLING,	199 York Street,	New Haven, Conn.
Dr. G. W. ALLYN,	515 Penn Avenue,	Pittsburg, Pa.
Dr. A. ALT,	3036 Locust Street,	St. Louis, Mo.
†Dr. J. A. ANDREWS,	107 Madison Avenue,	New York, N. Y.
Dr. S. C. AYRES,	14 East 7th Street,	Cincinnati, Ohio.
Dr. WM. T. BACON,	75 Pratt Street,	Hartford, Conn.
Dr. H. W. BRADFORD,		Jamaica Plain, Mass.
*Dr. GUSTAVE E. BRUÈRE,	413 Oregonian Building,	Portland, Oregon.
*Dr. H. D. BRUNS,	Gas Co. Building,	New Orleans, La.
Dr. CHARLES S. BULL,	47 West 36th Street,	New York, N. Y.
Dr. F. BULLER,	123 Stanley Street,	Montreal, Canada.
Dr. SWAN M. BURNETT,	916 Farragut Sq. (17th St.),	Washington, D. C.
Dr. PETER A. CALLAN,	35 West 38th Street,	New York, N. Y.
Dr. F. P. CAPRON,	118 Angell Street,	Providence, R. I.
Dr. W. H. CARMALT,	87 Elm Street,	New Haven, Conn.
*Dr. JOHN T. CARPENTER, JR.,	1419 Walnut Street,	Philadelphia, Pa.
Dr. H. B. CHANDLER,	34½ Beacon Street,	Boston, Mass.
Dr. WM. CHEATHAM,	303 West Chestnut Street,	Louisville, Ky.
Dr. F. E. CHENEY,	120 Marlborough Street,	Boston, Mass.
Dr. J. H. CLAIBORNE,	39 West 36th Street,	New York City.
Dr. C. F. CLARK,	188 East State Street,	Columbus, Ohio.
*Dr. ANTON COE,	1110 F Street,	Washington, D. C.
Dr. DAVID COGGIN,	7 Chestnut Street,	Salem, Mass.
*Dr. WM. E. COWEN,	35 E. 60th Street,	New York, N. Y.
*Dr. WM. G. CRAIG,	75 Pratt Street,	Hartford, Conn.
Dr. C. M. CULVER,	36 Eagle Street,	Albany, N. Y.
*Dr. C. W. CUTLER,	36 East 33d Street,	New York, N. Y
Dr. W. S. DENNETT,	8 East 49th Street,	New York, N. Y.

† Temporarily residing at Santa Barbara, Cal.

NAME.	RESIDENCE.	PLACE.
Dr. HASKET DERBY,	182 Marlboro Street,	Boston, Mass.
Dr. RICHARD H. DERBY,	9 West 35th Street,	New York, N. Y.
Dr. LEWIS S. DIXON,	232 Clarendon Street,	Boston, Mass.
*Dr. ALEXANDER DUANE,	49 East 30th Street,	New York, N. Y.
Dr. J. B. EMERSON,	20 East 30th Street,	New York, N. Y.
Dr. ARTHUR E. EWING,	2670 Washington Avenue,	St. Louis, Mo.
Dr. T. H. FENTON,	1319 Spruce Street,	Philadelphia, Pa.
Dr. GEORGE F. FISKE,	100 State Street,	Chicago, Ill.
Dr. EDW. FRIDENBERG,	242 Lenox Avenue,	New York, N. Y.
*Dr. PERCY FRIDENBERG,	114 West 125th Street,	New York, N. Y.
Dr. H. FRIEDENWALD,	1029 Madison Ave.,	Baltimore, Md.
Dr. B. F. FRYER,	Cor. 9th and Cherry Streets,	Kansas City, Mo.
Dr. G. M. GOULD,	119 South 17th Street,	Philadelphia, Pa.
*Dr. H. Y. GRANT,	414 Delaware Avenue,	Buffalo, N. Y.
Dr. JOHN GREEN,	2670 Washington Avenue,	St. Louis, Mo.
Dr. EMIL GRUENING,	36 East 57th Street,	New York, N. Y.
*Dr. C. W. HADDOCK,		Beverly, Mass.
Dr. G. W. HALE,	Wilcox Building,	Nashville, Tenn.
Dr. WM. D. HALL,	10 Arlington Street,	Boston, Mass.
Dr. H. F. HANSELL,	254 South 16th Street,	Philadelphia, Pa.
Dr. GEORGE C. HARLAN,	1515 Walnut Street,	Philadelphia, Pa.
*Dr. HERBERT HARLAN,	516 Cathedral Street,	Baltimore, Md.
Dr. DAVID HARROWER,	9 Elm Street,	Worcester, Mass.
Dr. N. D. HARVEY,	262 Benefit Street,	Providence, R. I.
Dr. GUSTAVUS HAY,	383 Marlborough Street,	Boston, Mass.
Dr. NEIL J. HEPBURN,	317 West 23d Street,	New York, N. Y.
*Dr. WARD HOLDEN,	43 West 48th Street,	New York, N. Y.
Dr. E. E. HOLT,	723 Congress Street,	Portland, Me.
Dr. LUCIEN HOWE,	87 West Huron Street,	Buffalo, N. Y.
Dr. A. A. HUBBELL,	212 Franklin Street,	Buffalo, N. Y.
Dr. D. W. HUNTER,	80 West 40th Street,	New York, N. Y.
Dr. J. W. INGALLS,	874 Lafayette Avenue,	Brooklyn, N. Y.
Dr. E. E. JACK,	215 Beacon Street,	Boston, Mass.
Dr. EDWARD JACKSON,	McPhee Building,	Denver, Col.
Dr. B. JOY JEFFRIES,	15 Chestnut St., Beacon Hill,	Boston, Mass.
Dr. W. B. JOHNSON,	170 Broadway,	Paterson, N. J.
*Dr. H. W. KILBURN,	192 Marlborough Street,	Boston, Mass.
Dr. CHARLES J. KIPP,	560 Broad Street,	Newark, N. J.
*Dr. ARNOLD KNAPP,	26 West 40th Street,	New York. N. Y.
Dr. H. KNAPP,	26 West 40th Street,	New York, N. Y.
Dr. CARL KOLLER,	715 Madison Avenue,	New York, N. Y.
Dr. CHAS. W. KOLLOCK,	Cor. Wentworth & Com'g Sts.,	Charleston, S. C.
Dr. W. E. LAMBERT,	8 West 35th Street,	New York, N. Y.
*Dr. W. B. LANCASTER,	101 Newbury Street,	Boston, Mass.
*Dr. J. C. LESTER,	179 Schermerhorn Street,	Brooklyn, N. Y.
Dr. F. N. LEWIS,	35 W. 36th Street,	New York City.
Dr. J. A. LIPPINCOTT,	Arrott Bdg., Wood St. & 4th Av.,	Pittsburg, Pa.

NAME.	RESIDENCE.	PLACE.
Dr. F. B. LORING,	1420 K Street,	Washington, D. C.
Dr. D. B. LOVELL,	32 Pearl Street,	Worcester, Mass.
Dr. F. W. MARLOW,	731 University Block,	Syracuse, N. Y.
Dr. W. V. MARMION,	1110 8th Street, N. W.,	Washington, D. C.
Dr. W. B. MARPLE,	35 W. 53d Street,	New York, N. Y.
Dr. ARTHUR MATHEWSON,	139 Montague Street,	Brooklyn, N. Y.
Dr. CHAS. H. McILWAINE,	264 Willis Avenue,	New York, N. Y.
Dr. R. J. McKAY,	Cor. 9th and Market Streets,	Wilmington, Del.
Dr. C. S. MERRILL,	23 Washington Avenue,	Albany, N. Y.
Dr. B. L. MILLIKIN,	278 Prospect Street,	Cleveland, Ohio.
Dr. HORACE GEO. MILLER,	262 Benefit Street,	Providence, R. I.
Dr. J. LANCELOT MINOR,	14 Randolph Building,	Memphis, Tenn.
Dr. W. F. MITTENDORF,	140 Madison Avenue,	New York, N. Y.
Dr. RUSSELL MURDOCH,	418 Cathedral Street,	Baltimore, Md.
Dr. CHARLES A. OLIVER,	1507 Locust Street,	Philadelphia, Pa.
Dr. H. S. OPPENHEIMER,	16 E. 32d Street,	New York, N. Y.
Dr. R. J. PHILLIPS,	123 So. 39th Street,	Philadelphia, Pa.
Dr. THOMAS R. POOLEY,	107 Madison Avenue,	New York, N. Y.
Dr. WILLIAM C. POSEY,	1831 Chestnut Street,	Philadelphia, Pa.
Dr. M. H. POST,	Beaum't St., cor. Wash. Av.,	St. Louis, Mo.
*Dr. L. A. PREFONTAINE,	1317 Main Street,	Springfield, Mass.
Dr. H. R. PRICE,	163 Hancock Street,	Brooklyn, N. Y.
Dr. J. S. PROUT,	29 Schermerhorn Street,	Brooklyn, N. Y.
*Dr. WALTER L. PYLE,	1806 Chestnut Street,	Philadelphia, Pa.
*Dr. ALEX. QUACKENBOSS,	71 Newbury Street,	Boston, Mass.
Dr. ALEX'R RANDALL,	1717 Locust Street,	Philadelphia, Pa.
Dr. R. L. RANDOLPH,	816 Park Avenue,	Baltimore, Md.
Dr. WILLIAM RANKIN,	23 Cedar Street,	Newark, N. J.
Dr. J. M. RAY,	423 West Chestnut Street,	Louisville, Ky.
*Dr. R. G. REESE,	56 East 25th Street,	New York, N. Y.
Dr. R. A. REEVE,	22 Shuter Street,	Toronto, Canada.
Dr. O. H. REIK,	5 W. Preston Street,	Baltimore, Md.
Dr. STEPHEN O. RICHEY,	732 17th Street,	Washington, D. C
Dr. CHARLES E. RIDER,	53 South Fitzhugh Street,	Rochester, N. Y.
Dr. WHEELOCK RIDER,	53 South Fitzhugh Street,	Rochester, N. Y.
*Dr. G. O. RING,	1900 Chestnut Street,	Philadelphia, Pa.
Dr. H. W. RING,	187 Chestnut Street,	New Haven, Conn.
Dr. SAMUEL D. RISLEY,	1824 Chestnut Street,	Philadelphia, Pa.
Dr. EDMUND C. RIVERS,	1632 Welton Street,	Denver City, Col.
*Dr. WM. K. ROGERS,	188 East State Street,	Columbus, Ohio.
Dr. D. B. ST. JOHN ROOSA,	20 East 30th Street,	New York, N. Y.
*Dr. DUNBAR ROY,	Grand Opera House Block,	Atlanta, Ga.
Dr. JOHN D. RUSHMORE,	120 Montague Street,	Brooklyn, N. Y.
Dr. ROBERT SATTLER,	7th and Race Streets,	Cincinnati, Ohio.
Dr. T. B. SCHNEIDEMAN,	112 South 18th Street	Philadelphia, Pa.
Dr. G. E. DE SCHWEINITZ,	1401 Locust Street,	Philadelphia, Pa.
Dr. P. N. K. SCHWENK,	810 North 7th Street,	Philadelphia, Pa.

NAME.	RESIDENCE.	PLACE.
Dr. W. W. SEELEY,	4th Street and Broadway,	Cincinnati, Ohio.
Dr. HENRY L. SHAW,	19 Commonwealth Avenue,	Boston, Mass.
*Dr. WM. T. SHOEMAKER,	2031 Chestnut Street,	Philadelphia, Pa.
*Dr. WM. A. SHOEMAKER,	1006 Carlton Building,	St. Louis, Mo.
Dr. F. D. SKEEL,	58 E. 25th Street,	New York, N. Y.
Dr. J. A. SPALDING,	627 Congress Street,	Portland, Me.
Dr. MYLES STANDISH,	6 St. James Avenue,	Boston, Mass.
*Dr. E. W. STEVENS,	421 McPhee Building,	Denver, Col.
Dr. GEORGE T. STEVENS,	22 East 46th Street,	New York, N. Y.
*Dr. EDW. STIEREN,	Werthingham Building,	Pittsburg, Pa.
Dr. SAMUEL B. ST. JOHN,	68 Pratt Street,	Hartford, Conn.
Dr. GEO. STRAWBRIDGE,	202 So. 15th Street,	hiladelphia, Pa.
Dr. T. Y. SUTPHEN,	999 Broad Street,	Newark, N. J.
*Dr. WM. M. SWEET,	1205 Spruce Street,	Philadelphia, Pa.
Dr. J. OSCROFT TANSLEY,	28 West 43d Street,	New York, N. Y.
Dr. LEWIS H. TAYLOR,	41 South Franklin Street,	Wilkes-Barre, Pa.
Dr. SAMUEL THEOBALD,	304 West Monument Street,	Baltimore, Md.
Dr. CH. HERMON THOMAS,	1907 Chestnut Street,	Philadelphia, Pa.
Dr. A. G. THOMSON,	1426 Walnut Street,	Philadelphia, Pa.
*Dr. EDGAR S. THOMPSON,	19 E. 44th Street,	New York, N. Y.
Dr. WILLIAM THOMSON,	1426 Walnut Street,	Philadelphia, Pa.
Dr. JAS. THORINGTON,	120 South 18th Street,	Philadelphia, Pa.
Dr. JOHN VAN DUYN,	111 South Salina Street,	Syracuse, N. Y.
Dr. C. A. VEASEY,	116 South 19th Street,	Philadelphia, Pa.
Dr. O. F. WADSWORTH,	526 Beacon Street,	Boston, Mass.
*Dr. F. L. WAITE,	68 Pratt Street,	Hartford, Conn.
Dr. LEROY P. WALKER,	26 West 91st Street,	New York, N. Y.
Dr. DAVID WEBSTER,	327 Madison Avenue,	New York, N. Y.
Dr. J. E. WEEKS,	48 East 57th Street,	New York, N. Y.
*Dr. CASSIUS D. WESTCOTT,	31 Washington Street,	Chicago, Ill.
Dr. J. A. WHITE,	200 E. Franklin Street,	Richmond, Va.
Dr. W. H. WILDER,	103 State Street,	Chicago, Ill.
Dr. CHAS. H. WILLIAMS,	1069 Boylston Street,	Boston, Mass.
Dr. WM. H. WILMER,	1610 I Street N. W.,	Washington, D. C.
Dr. F. M. WILSON,	834 Myrtle Avenue,	Bridgeport, Conn.
*Dr. WILLIAM L. WOOD,	412 Oregonian Building,	Portland, Oregon.
*Dr. HIRAM WOODS,	842 Park Ave.,	Baltimore, Md.
Dr. J. P. WORRELL,	20 South 7th Street,	Terre Haute, Ind.
*Dr. S. LEWIS ZEIGLER,	1700 Walnut Street,	Philadelphia, Pa.
Total, ...		164

HONORARY MEMBERS.

Dr. C. SCHWEIGGER, ...		Berlin, Prussia.
Dr. F. P. SPRAGUE,	229 Commonwealth Avenue,	Boston, Mass.
Whole number, ...		166

Wm F Morris

DR. WILLIAM FISHER NORRIS.

A MEMOIR.

By S. D. RISLEY, A.M., M.D.

It has seemed to this society highly fitting that it should pause in its scientific proceedings to honor the memory of one of its distinguished members, and to enrich its annals with a suitable memoir. It is doubtless wise that for a brief hour we should relax our strenuous grasp upon the daily affairs which engross us and, turning our minds from the struggle for the emoluments of life, gravely contemplate, from its thoughtful beginning to its serene closing, the career of a man singularly endowed by nature and happy circumstance to enter the arena of human endeavor.

Dr. William Fisher Norris was born in Philadelphia January 6, 1839, and died November 18, 1901. He had for many years been subject to periodical attacks of rheumatism and rheumatic gout, and for a year or more prior to his death had suffered from glycosuria, which, however, was held under control by a prudent regimen, so that he continued his public and private work with such faithfulness that he did not appear to his friends and colleagues to be seriously out of health. In the early autumn of 1901 he returned from his usual vacation passed at his beautiful summer home, Woodbourne, in the mountains of Pennsylvania overlooking the picturesque and historic valley of the Wyoming, and entered upon his accustomed work.

He soon suffered an attack of pneumonia to which, after a lingering illness, he finally succumbed. His death came as a grave shock to a large group of surviving friends and professional colleagues, to whom many years of association had endeared him. Not only, however, to those who were honored by his personal friendship was his death a sore bereavement, but was felt as a

serious loss to this society and to American ophthalmology. But few men have been born to greater opportunity than was Dr. Norris, and still fewer, thus highly favored, have with equal singleness of purpose met the weighty responsibilities which attend upon the footsteps of fortuitous circumstances.

His father, Dr. George W. Norris, an eminent surgeon, and his mother, Mary P. Fisher, were both the descendents of cultured families who had been prominent in the business and social life of the community for several generations. He was personally endowed with a fine presence, vigorous health, and ample means.

His early education was obtained in the Ferris School, at that time held in much repute in Philadelphia for the thoroughness and efficiency of its preliminary training. He then entered the College Department of the University of Pennsylvania, from which he received the degree of Bachelor of Arts with the class of 1857 and matriculated in the Medical Department, graduating M.D. in 1861. In the same year he was elected resident physician in the Pennsylvania Hospital, and served the required term of eighteen months. Some phases of his character are well illustrated by a stirring episode occurring during his residency which he related to me many years later. Hearing an unusual commotion in one of the wards, he entered and found the nurses and many of the patients fleeing in dismay before a stalwart and violent lunatic, who had entered the opposite end of the ward with a huge cleaver in his upraised hand. No sooner had he seen the young doctor, dressed in his ward coat, than he ran violently with weapon raised to brain him. Dr. Norris awaited calmly his rapid approach and, as the blow descended, with quick eye, firm and accurate hand, grasped the wrist with the unyielding, paralyzing grasp of the trained athlete, and at the same time tripped the feet of the man, pinioned his arms, and so held him until help arrived and he was placed in a strait-jacket.

In this occurrence we see portrayed many phases of Dr. Norris' character: courage, no hesitation, no subterfuge, but a straightforward, thoughtful, efficient, and wise course of action under extraordinary stress of circumstances unforeseen. During

many years of almost daily association I many times witnessed demonstrations of this same mental grasp of trying situations.

The time spent in the calm and cloistered shades of this ancient and renowned hospital, then as now under the management of the Society of Friends, was for the most part, however, in vivid contrast to the stirring and anxious life of the nation. It was the early period of the Civil War. At the close of his residency in the hospital he sought and obtained a commission from the government as assistant surgeon in the U. S. army, and was placed in charge of the Douglas Hospital at Washington, where he served at this arduous post of duty until his resignation in 1865, when he retired with the brevet rank of captain, "conferred for meritorious service during the war." In this connection mention should be made of the splendid and heroic work which Dr. Norris performed in taking care of the wounded at Gettysburg, whither he was sent the day after the battle. "I have heard his conduct at this time most highly lauded by officers who were present, and have heard Dr. Norris himself relate how, in the church temporarily made to serve as a hospital, he had operated and dressed wounds continuously for thirty-six hours, without food or rest, being finally forced to desist from sheer exhaustion. The many letters of gratitude which he received in later years from patients whose lives he had saved full well bespoke the skill and care with which he had ministered to their needs."* During these anxious and busy times at this famous military hospital he found time to furnish numerous contributions to the Army Medical Museum, and in conjunction with Dr. William Thomson spent much time in the development of photography as a graphic means of recording the appearance of injuries and diseases, and in experiments in micro-photography. This splendid work of Drs. Thomson and Norris led, not only directly to the establishment of the "Photography Bureau" in the army, but they were the first to successfully reproduce by the wet collodion process, objects seen in the field of the microscope, with both low and high powers. This work reflected great credit upon the medical staff of the army and led to the splendid devel-

*G. W. Morris, M.D.

ERRATUM. — The footnote on page 11 should read G. W. Norris, M.D., instead of G. W. Morris, M.D.

opments later in the hands of Dr. Woodward, aided by the ample resources of the Surgeon-General's office (Thomson). It is probable that the optical studies involved in these researches were the beginning of his interest in physiological optics, forming, as it does, such an important chapter in ophthalmology, to which his subsequent life was devoted with such conspicuous success. Thus early in his professional life as a military surgeon we see evidence of that fondness for industrious research and painstaking study which so signally characterized his subsequent career.

In the autumn of 1865, then 26 years of age, he sailed for Europe for the purpose of pursuing his studies abroad, following in this the example of many illustrious predecessors who, for more than a hundred years, had rendered famous the courts of his alma mater.

When in reminiscent mood he often related to me many interesting and often amusing incidents falling under his observation while visiting the various ophthalmological clinics in Europe. His characterization and personal estimate of the men who conducted them, and his description of their peculiar methods of work, proved of great interest to me when in later years I was thrown in contact in Europe with these men of whom my first impressions had been received from Dr. Norris. The greater part of his time abroad was spent in Vienna under the instruction of Arlt, Jaeger, and Mauthner, for each of whom he retained throughout life the profoundest respect, and never lost his sense of gratitude to these eminent masters. To Arlt, especially, he often referred, not only as an authority in ophthalmology, but with affectionate regard, always speaking of him in tones which one employs only for the friend he loves.

He also spent much time in the Pathological Institute where, in conjunction with Stricker, he did valuable work in experimental study of the pathologic histology of the cornea, the results of which were published under their joint authorship in an extended brochure ("Study of the Inflammations of the Cornea") "Versuche Ueber Hornhautenzundung." The great value

of these early studies of the pathological histology of the cornea in Stricker's laboratory were constantly manifested in the daily routine of his clinical work by an obvious familiarity with the diseases of that important membrane, and furnish a striking illustration of the essential value of such work as preparation for the study, diagnosis, and treatment of disease.

I dwell upon this phase of his preparation for the reason that it had, in the first place, a controlling influence over his methods of work as furnishing an example for research in all other directions, and further, because it illustrates forcibly his mental trend. He was never satisfied with a more or less shrewd guessing at the nature of disease, or with the empirical therapeutic measures based upon a possibly false hypothetical premise. As a result of this mental habit his time was largely passed in the endeavor to verify by careful observation and laboratory study the theories promulgated by others.

The persistent, unflagging patience with which he kept in mind many unsolved problems in ophthalmology and patiently waited for the opportunity to study cases and to secure pathological material for examination, must ever remain, in the minds of those who were familiar with his work and its methods, as one of the striking characteristics of the man.

His mental habit was not, therefore, that of a Kepler, to construct hypotheses and then to spend his nights in hunting them down, but rather that of a Galileo, who observed the conditions presented and then constructed his conclusions from observed facts.

After visiting the principal clinics of the continent and in England he returned, in 1870, to Philadelphia, and soon after was appointed lecturer in ophthalmology and otology at the University of Pennsylvania, then located at 9th and Chestnut Sts., when together with Dr. George Strawbridge, who had a like appointment, he established the first of the special clinics in that institution. He had, however, resolved to devote himself to ophthalmology alone, and therefore appointed Dr. Bertolet to take charge of the diseases of the ear. Three years later, when the university was removed

to West Philadelphia and the University Hospital erected, Dr. Norris was made Clinical Professor of Ophthalmology and Dr. Strawbridge was awarded the professorship of Otology. Later, Dr. Norris was made honorary professor, and in 1876, full Professor of Ophthalmology, which chair he filled with dignity and honor to the close of his life. In 1870 he was elected a member of the American Ophthalmology Society, and in 1871 presented his first paper, entitled "Paralysis of the Trigeminus, followed by sloughing of the Cornea," a study, it will be observed, in line with his researches in Stricker's laboratory.

In April, 1872, a few months after the establishment of the special lectureship and clinic at 9th and Chestnut Sts., I received, by the hands of the late Dr. Charles Hunter, a message from Dr. Norris, whom I had never seen, requesting me to take the position of chief of clinic. The opportunity thus offered was eagerly accepted, and proved to be the beginning of an unbroken association as teacher and pupil, friend and colleague, destined to continue until the close of his eminently industrious, painstaking, and useful life. I cannot forget our first meeting, in his father's library at 16th and Locust Sts. I was much impressed by his unusual and striking personality. He was 33 years of age, possessed of a massive frame, well rounded, not corpulent, a large dome-like head, with the blonde hair of a Norseman, trimmed in the conventional form, a full beard, not long, light in color, fine in texture, a complexion ruddy with the tints of perfect, vigorous health, and a calm benignant manner, striking in one of his age, which found expression largely through his clear, blue, unhesitating eyes.

The years devoted exclusively to preparation were at an end, and he was carefully and thoughtfully beginning his special life work in the city of his birth. Any complete delineation of his career and its influence during the twenty-nine years, which comprise the interval between this beginning and its close, would form an important chapter in the history of American Ophthalmology as represented in Philadelphia. It was the beginning of a new era in the medical department of the University, indeed, it

may truthfully be said, in American medicine. At the time he made his choice, specialism in medicine was not regarded with favor in the United States, either by the eminent men who filled the chairs in our medical schools, by the body of the profession, or by the more conservative members of the community. The general feeling, therefore, certainly in Philadelphia, was one of hostility. The members of the Medical Faculty at the University, although they were teaching their own special branches of medicine and surgery, nevertheless, in the daily routine of medical and surgical practice covered with few exceptions the entire professional field. They, for the most part, both in training and mental habit, belonged to the preceding generation, had inherited a most vigorous and wholesome antipathy to charlatanism, and were prone to regard with distrust any innovation tending to disrupt the established conventions of professional life and practice. But few men could at that time have entered this new field in Philadelphia medicine so opportunely: the son of a great surgeon whose career had been pursued in the best associations of lay and professional life; an alumnus of the University, which from its earliest history had been the training school for the best youths of the city; well endowed intellectually, possessing ample means, and fully equipped for his chosen work in the schools of Europe; none, not even the most conservative, could gainsay his right to such a choice, assail his position, or criticise his preparation for special work. The profession in Philadelphia is therefore indebted to Dr. Norris, not only for his scientific achievements, but also for boldly assisting in opening the way for specialism in medicine to others less fortunately situated to follow. In this he was very fortunate in having for colleagues a coterie of eminent men, Dr. Dyer, too soon lost to science, Dr. Strawbridge, Dr. William Thomson, Dr. George C. Harlan, Dr. Douglass Hall, all members of this society, who, working together in perfect amity, removed very soon the last vestige of hostility to specialism. These men and a few others who were then devoting their time to special work in Philadelphia formed but a "corporal's guard," and were maintaining themselves in an uncongenial, not to say a hostile, environment.

The classes graduating in the University of Pennsylvania in 1870 received no instruction about the eye other than the inimitable lectures on its anatomy given annually by the renowned Joseph Leidy, and an occasional opportunity to witness the couching of a cataract by the professor of surgery, or to see examples of such inflammatory affections as applied for treatment at the semi-weekly clinics. During my own medical course at the University I did not hear the slightest mention made of the errors of refraction. There had been a large eye clinic at the now famous "Wills Eye Hospital" since 1836, but its daily service had been conducted for the most part by general physicians and surgeons who treated inflammations of the eye and operated on cataracts, sending the successful operations to the optician to select a cataract glass. But for a year or more a change had been creeping in. Dr. Dyer, even then a member of this Society, was doing pioneer work. During my last year in the Medical Department of the University the late Dr. Noyes gave a lantern lecture by invitation, on the diseases of the optic nerve and retina, and Dr. Wm. Thomson, by invitation of the late Dr. William Hunt, spoke to the students, assembled from the various medical schools at the Pennsylvania Hospital surgical clinic, on the refraction errors of the eye. Dr. Geo. C. Harlan, Dr. William Thomson, and Dr. Douglass Hall were on the staff at the Wills Hospital in 1871, and became my first teachers in that institution on diseases of the eye. I asked Dr. Harlan what books I should read. He suggested Soelberg Wells and Donders. I procured a copy of the first from my bookseller but could not secure a copy of Donders' book, but fortunately succeeded in finding one of the new Suydenham translations in the Mercantile Library, where I spent many hours over its pages until, at the time I joined Dr. Norris in his clinic, I could almost recite its coarse print from beginning to finish.

In 1872 there were probably but few more skillful operators than the eminent men composing the staff of the Wills Hospital, but they were standing on the verge of a new era in medicine, the era of specialism.

It is to their credit that they moved forward in the advancing column. Some are gone, but two at least of that staff, Dr. Thomson and Dr. Harlan, are still actively at work, in the front rank of modern ophthalmology, and are as earnestly as ever looking forward and inquiring of the future.

Such was the position of ophthalmology in Philadelphia when Dr. Norris began his work. It seems curious now to look back to the days of '72 and recall the conversations with my new instructor fresh from his European teachers and from the many continental clinics. He spoke frequently of the methods and manner of Donders, whose work I had learned to love and whose genius had fascinated me. We talked of full vs. under corrections in hypermetropia; of atropia, then the only mydriatic at command, for paralyzing the accommodation; was it necessary to employ it or were manifest corrections sufficient? As yet we were without the guiding influence of experience, but as the months and years passed in devotion to the work at the University Hospital Clinic, the habitual use of the mydriatics in the correction of all errors of refraction in asthenopic eyes came to be an established practice, and was systematically taught by Dr. Norris to his University class and became the constant habit, both in the private and public work of his assistants and many of his colleagues in Philadelphia, and in a few years was widely taught through the numerous published papers emanating from that clinic. Dr. Harlan tells me " that in 1870 and 1871 he used atropia for the determination of the total hypermetropia, but by no means constantly, and not at all for refraction purposes in myopia."

While the clinic was still at Ninth and Chestnut streets, it was our daily habit after the work for the day had been completed to walk to the market, then on Fifth Street, above Chestnut, on the site now occupied by the Bourse, for a lunch, which consisted of half a dozen salt oysters on the half shell and a glass of ale. This gave opportunity for many conversations on various topics. On the occasion of one of these saunters down Chestnut street, he said he did not see that there was opportunity for any further

brilliant discoveries in ophthalmology; that the exhaustive work of Helmholz in physiological optics and the invention of the ophthalmoscope; the classic work of Donders on "The Anomalies of Accommodation and Refraction", and the discoveries of von Graefe in choked disc and iridectomy for glaucoma, the field for any possible brilliant discoveries had been exhausted. Nothing could illustrate better the thoughtfulness of his daily conversation even when off duty than this, and it is interesting to note that the flight of years has served to demonstrate the essential correctness of the view then expressed, since most, if not all, subsequent advances have clustered around the teaching of these masters and have served only to enforce the correctness of their teaching or to develop and enlarge it.

After the removal of the clinic to West Philadelphia the work soon grew to such proportions that more assistance was required, and Dr. Norris appointed, I think in the order named, from time to time in the following years, Dr. Piearsol, now Professor of Anatomy in the University; Dr. Shakespeare, who during his work at the clinic devoted much time to the pathological histology of the eye in Dr. Norris's private laboratory at the hospital, and invented an ingenious ophthalmoscope by means of which not only the static refraction of the eye could be determined with mathematical accuracy, but the size of the blood vessels or any detail of the fundus could be accurately measured and sketched as with the micrometer, and who subsequently was appointed by the government to investigate the origin and nature of cholera. Later Dr. B. A. Randall, now Professor of Otology at the University; Dr. James Wallace; Dr. de Schweinitz, now Professor of Ophthalmology; Dr. G. Oram Ring and Dr. Jno. T. Carpenter, were successively appointed and under the inspiring influence which pervaded the clinic soon placed the eye service at the University Hospital in the front rank of American Ophthalmology and gave to it a world-wide repute by the publications which rapidly succeeded each other from their pens. I cannot forget Dr. Norris's early lectures in the amphitheater at Ninth and Chestnut streets. His extreme diffidence,

not to say embarrassment, in first appearing before the class in those days is still vivid in my memory, but his wise and careful teaching; his earnest search for the truth; his great respect, amounting almost to a feeling of reverence, for his great European teachers, whom he had so recently left, were but the commencement of his own career as a teacher, and fairly foreshadowed the long years of earnest, faithful, and helpful service which he rendered; a great service, not only to the afflicted whom he sought so earnestly to relieve, but to those of us who were privileged to labor with him and to come within the sphere of his stimulating influence and helpful personality. His assistants always entertained for him and his teaching the greatest respect. As an evidence of this it was quite natural to either actually defer to his opinion in any given case of disease, or to mentally refer the matter to his well-known views and practice, under like conditions. To the list of assistants enumerated must be added the names of Dr. Mellor, later appointed Chief of Clinic, and Dr. Charles A. Oliver, and Dr. William Zentmayer, both of whom worked with him at the Wills Eye Hospital, and are now members of its Surgical Staff. All who are familiar with the literature of American Ophthalmology must recall the literary activity of this group of assistants, who began their work at the University Hospital clinic and all of whom look back with gratitude and pride to Dr. Norris as their teacher and friend.

Dr. Norris was not himself a frequent contributor to journalistic literature. He only occasionally would permit the publication of a clinical lecture although often requested to do so, his answer being that there was nothing new in what he had said. His method as a lecturer was not brilliant and did not appeal to the undergraduate in such a manner as to awaken his enthusiasm, but to his assistants and to the numerous post-graduates who came to study ophthalmology at the clinic his lectures were of great interest and value. They were given in well-chosen words and formed an admirable outline of the subject under discussion, not only presenting his own views but the consensus of opinion as set forth in the literature. His thorough familiarity

with the opinions of those who spoke with recognized authority forbade, as it always does, a tendency to dogmatic teaching, which is the secret of the charm exercised by so many teachers. This familiarity with the work, especially of European writers, was obvious in all his contributions to the literature of ophthalmology. An admirable illustration of this is found in his article "Medical Ophthalmology," contributed in 1886, to a system of medicine edited by the late Dr. Wm. Pepper, where, in the brief space of sixty-seven pages, is found the best résumé of all that was known "of the eye symptoms which may be seen in the course of diseases of the general system and in connection with the pathological conditions of the various organs of the body." The introduction to this article is a model of clear, condensed statement, an epitome of all that is to follow, and might well be consulted as an example to be emulated. The same may be said of his portion of the admirable "Text Book of Ophthalmology" published in 1893 under the joint authorship of Dr. Norris and Dr. Oliver, in the brief preface of which he acknowledges his never forgotten "indebtedness to his former teachers, Ferdinand v. Arlt, Edward v. Jaeger, and Ludwig Mauthner, for many of the ideas inculcated in the following pages." Dr. Harlan, in his admirable biography of Dr. Norris presented to the College of Physicians of Philadelphia, to which I am greatly indebted, has pointed out in the following paragraph an important chapter in his life work:

"Perhaps the most important of Dr. Norris's work for advancing the medical interests of Philadelphia was in connection with the University Hospital. He was one of its originators; in fact, the project was launched by the appointment of a committee of the Alumni Society of the Medical Department on a motion made by him. He was a member of the finance committee, of which the indefatigable Pepper was chairman, and subsequently became president of its board of managers. To the last his devotion to its interests and his readiness to work for it never flagged. The last time I saw him, only a few days before his death, he spoke of it with affectionate interest, and expressed the hope that he might soon be well enough to go back to his work there."

The following resolutions passed by his fellow trustees show the estimation in which he was held by them:

"Whereas, The Board of Managers of the Hospital of the University of Pennsylvania has been bereft by death of its distinguished president, Dr. William F. Norris;

"Resolved, That the board has lost a colleague who, as one of the founders of our splendid hospital, gave of his knowledge and experience, time, and private means in the erection of the building, and when the structure was an accomplished fact continued as a member of its Board of Managers, his earnest and unceasing efforts in assuring its equipment, maintenance, extension, and improvement; that as president of the board for the last nine years, his successful administration, beset with difficulties, has been marked by foresight, patience, and a conscientious attention to duty; that we mourn a friend who, while he excited our admiration by his wisdom and energy, endeared himself to us by his gentleness and courtesy."

"In January, 1872, he became a member of the staff of the Wills Eye Hospital, where until within a year of the close of his life he worked with his characteristic care and fidelity, keeping in view the welfare of the patients committed to his care and always careful of the feelings and interests of his colleagues on the staff and maintaining the respect and friendship of both the Board of Management, the Staff of Surgeons, and their many assistants." — *Harlan.*

In addition to those already noted, Dr. Norris's principal contributions to the literature of Ophthalmology were an article on "Albuminuric Retinitis" in Dr. Tyson's monograph on Bright's disease; "Diseases of the Crystalline Lens," in the well-known "System of Diseases of the Eye by American and Foreign Authors," collaborated by him and Dr. Oliver; "Investigations of Double Staining in Microscopical Work," with Shakespeare; "A Description of the Anatomy of the Human Retina, with Special Consideration of the Terminal Loops of the Rods and Cones," with Wallace; "Foreign Bodies in the Orbit"; "Brain Tumor with Interesting Eye Symptoms."

He himself regarded the "System of Diseases of the Eye" as his monumental work. The care with which its large corps of contributors was selected affords a striking illustration of his familiarity with the special work of others and his keen appreciation of what was of lasting value. As a consequence the system is produced by a group of men, selected because of his estimate of the essential value of the work they had done along specific lines of research, and therefore affords the last best presentation of every phase of modern ophthalmology to the date of publication, and must stand as a monument to his sagacity, penetration, and learning.

As a surgeon he must be classed as conservative, rarely if ever stepping aside from the methods of procedure recognized by the best authorities.

As an operator he was careful, cautious, and painstaking, always keeping in mind the welfare of his patient rather than the brilliancy of his procedure or the statistical results of operation. This ever-present regard for the patient modified his attitude frequently towards the work allowed to his assistants and especially to hospital residents usually eager for opportunities to operate. Dr. Norris could not often be induced to risk the hope of a hospital patient, blind with cataract, for instance, by permitting the extraction in the hands of an inexperienced resident physician for the sake of practice, his attitude ever being based upon what he considered his duty to the patient.

Dr. Norris was elected president of this Society in 1884 and presided over its deliberations with dignity and address for five years. He was a member of the College of Physicians of Philadelphia and always took an active interest in its welfare, serving as one of its Board of Censors for ten years. When the forming of sections was decided upon by the College he took an active part in establishing the ophthalmological section, wrote the rules for its government, and was chosen its first chairman. Much of its success was due to his unflagging interest, and the part he took in its scientific work — his presence always being sadly missed when ill health no longer permitted his regular attendance. As the date of the meeting approached he would

frequently inquire of its different members if they had not something of interest to present.

His active life is reflected briefly in the following enumeration of his official positions: Assistant Surgeon in the United States Army, Professor of Ophthalmology in the University of Pennsylvania, Attending Surgeon at Wills Eye Hospital, Chairman of the Section in Ophthalmology and Member of the Board of Censors of the College of Physicians, Vice-President of the Philadelphia Pathological Society, Ophthalmologist to the University Hospital and President of its Board of Trustees, a member of the Academy of Natural Sciences, Companion in the Military Order of the Loyal Legion, member of the American Philosophical Society, and Director of the Mutual Assurance Company.

It is not probable that a life of luxurious ease ever presented itself as a serious temptation to Dr. Norris, if so, the deeper and more abiding charm of a life of devotion to higher ideals and more exalted ambitions claimed his unwavering loyalty — even though the requirement was that of unremitting toil. His life is now a memory, but it must ever remain with us as that of a noble, generous, unselfish presence, that with genial good will and unremitting industry wrought well by our side — a helpful course, and has gone to its reward.

MINUTES OF THE PROCEEDINGS.

THIRTY-NINTH ANNUAL MEETING.

ARLINGTON HOUSE,
WASHINGTON, D. C., May 13, 1903.

The thirty-ninth annual meeting of the Society, held in connection with the sixth congress of American Physicians and Surgeons at Washington, D. C., was called to order by the President, Dr. C. S. BULL, at 9.30 A. M.

A memorial notice of the late Dr. WM. F. NORRIS of Philadelphia was read by Dr. S. D. RISLEY.

The following gentlemen were invited to attend the sessions of the Society and take part in the discussions: Drs. H. B. Ellis and A. L. Macleish of Los Angeles; B. H. Grove, Buffalo; Park Lewis, Buffalo; G. M. Case, Elmira; J. C. Lester, Brooklyn; Drs. S. S. Bishop and W. B. Moulton, Portland.

The report of the Committee on Standards and Methods of Examination for Acuteness of Vision, Color Sense, and Hearing was read by the Chairman, Dr. C. H. Williams, and an additional report on test types for distant vision by Dr. John Green. The report, which is given further on, was accepted and the recommendations adopted.

The Bulletin Committee reported and the following papers were read:

1. Tuberculosis of the conjunctiva, Dr. Jackson.

Discussed by Drs. Knapp and Burnett.

2. Localized tuberculosis of the eye, Dr. Spalding.

3. Subsequent history of the case of adenoma of the meibomian glands reported at the meeting of this Society in 1901, Dr. Knapp.

4. Case of primary sarcoma of the upper lid of a three years old child, removal Oct. 22, 1902, no relapse thus far, April 16, 1903, Dr. Knapp.

Discussed by Drs. Millikin and Wilder.

5. Dislocation of the lachrymal gland (case), Dr. Roy.

Discussed by Drs. Randolph, Roy, Taylor, and Wadsworth.

6. Demonstration of preparations to show the attachments of the recti muscles, Dr. Howe.

7. Case of pulsating exophthalmos with ligation of the common carotid artery, Dr. Bull (read by title).

8. Glaucoma following use of exophthalmin for diagnostic purposes, Dr. H. W. Ring.

Discussed by Drs. Knapp, Pooley, and Pyle.

9. Argyrosis of the conjunctiva and lachrymal sac with microscopical examination of the excised sac, Dr. de Schweinitz.

Discussed by Dr. P. Fridenberg.

10. Concerning the possible etiological factors in tobacco-amblyopia revealed by an analysis of the urine in cases of this character, Dr. de Schweinitz.

11. Diseases of the eye in white and negro races, Dr. Bruns.

Discussed by Drs. Kollock and Howe.

(Society then went into executive session.)

Executive Session, Wednesday, May 13, 1903.

The Committee on Membership reported favorably upon the following candidates:

Dr. G. E. Bruère, Portland, Oregon; Dr. C. W. Haddock, Beverley, Mass.; Dr. E. S. Thomson, New York City; Dr. Arnold Knapp, New York City; Dr. F. L. Waite, Hartford, Conn.; Dr. E. L. Stieren, Pittsburg, Pa.; Dr. W. G. Craig, Hartford, Conn.

These gentlemen were declared elected to associate membership.

The committee also asked permission to make a supplementary report at the Executive Session to be held on the 14th. Dr. Jackson moved to accept the report and grant the request, which motion was seconded and adopted.

The Secretary read the list of new proposals for membership and the meeting then adjourned.

Executive Session, May 14th.

Dr. Green presented a supplementary report recommending for membership Drs. S. L. Ziegler, Philadelphia, Pa., and J. C. Lester, Brooklyn, N. Y., who were declared elected to associate membership. Upon his motion, several names of candidates were referred to the committee for next year.

The following list of officers was nominated and elected:

President — DR. C. S. BULL.

Vice-president — DR. A. MATHEWSON.

Secretary and Treasurer — DR. S. B. ST. JOHN.

Corresponding Secretary — DR. J. S. PROUT.

Publication Committee — DR. W. S. DENNETT and DR. D. W. HUNTER.

The President announced that a committee had been appointed by the Otological Society to confer with a committee from this Society as to the time and place of next meeting (Drs. Dench, Crockett, and Lewis) and that he would appoint as a committee from the Ophthalmological Society, Drs. John Green, S. O. Richey, and F. B. Loring.

Dr. Green stated that it was the understanding that the Societies should meet in substantially the same way as before, securing to the Ophthalmological Society the same time as heretofore, and that the Otological Society should take as much more time of the week as they saw fit, and, that at that meeting the question of future meetings should be fully considered.

The Secretary read the list of nominations for new members and followed this by the reading of the Treasurer's Report, which was properly signed by the auditing committee, and accepted by the Society and ordered on file. He then presented and read a communication from the Academy of Ophthalmology and Oto-Laryngology. This communication was referred to the Executive Committee with the request that they consider it and present a report at the next meeting of this Society.

Dr. Williams presented the following resolution: That the Secretary be authorized to pay such bills for composition and electrotyping as may be necessary to prepare the standard test-types adopted by the Society, and, that the test-types be furnished to the members of the Society at the cost of printing. The resolution was adopted.

Upon motion of the Secretary the assessment for the next year was placed at $5.

The following rule was then adopted, as an amendment to Standing Rule No. III: "The Secretary shall, six weeks before the date of meeting, send a request to each member to forward within two weeks the titles of such papers as he desires to present at the next meeting, together with a brief abstract of the same. Such papers shall be arranged by the Secretary, and shall have precedence over all others.

Executive Session adjourned.

May 14th.

Called to order at 9.30.

Reading of papers resumed.

12. Intra-capsular injection in the extraction of cataract, Dr. Reik.

Discussed by Drs. Lippincott, Gruening, Holt, Risley, Allyn, Williams, Clark, Buller, St. John, and Wilmer.

13. Case of retinitis pigmentosa, Dr. Pyle.

Discussed by Dr. P. Fridenberg.

14. Leuco-sarcoma of the choroid, Dr. Pooley.

Discussed by Dr. Marple.

15. Type of central choroid degeneration, Dr. Jackson.

16. Retinal hemorrhages from vicarious menstruation leading to retinitis striata vitreous proliferation and detachment, Dr. P. Fridenberg.

Discussed by Dr. Pooley.

17. Case of optic atrophy following intestinal hemorrhage, Dr. Sweet.

Discussed by Drs. Allyn and Sweet.

18. The present status of subconjunctival injections in ophthalmic therapeutics, Dr. Bull (read by title).

19. Are tenotomies for hyperphoria necessarily more uncertain in their results than those for esophoria and exophoria, Dr. Theobald.

Discussed by Drs. Howe, Williams, Duane, Matthewson, Theobald.

20. A prism sequence for measuring heterophoria, Dr. Pyle.

Discussed by Dr. Williams.

21. Suggestions for a uniform nomenclature of the movements and motor anomalies of the eye, Dr. Duane.

22. The correction of 16 diopters of astigmatism by means of the galvano-cautery, Dr. Clark.

23. Case of panophthalmitis following discission of the capsule, Dr. Taylor.

Discussed by Drs. Matthewson, Bruns, Knapp, Risley, Jackson, Theobald, Wilder, Clark, Kollock, Lippincott, and Taylor.

24. Orbital osteoma of ethmoidal origin, Dr. P. Fridenberg.

Society then adjourned to 3 P. M.

Afternoon Session.

Meeting called to order by the Secretary in the absence of the President and Vice-President, and Dr. S. O. RICHEY was elected to preside.

25. Ptosis operated by method of Gillett de Grandmont and Gruening, Dr. Marple (read by title).

26. Case of rupture of choroid, Dr. Kollock (read by title).

27. Interstitial keratitis complicated with ophthalmia-neonatorum, Dr. Hubbell.

Discussed by Dr. Randall.

28. Modification of lantern for testing color perception, Dr. Williams.

Discussed by Drs. Hubbell, Williams, P. Fridenberg, and Randall.

29. Case orbital cellulitis; abscess of temporal lobe, Dr. Gruening (read by title).

30. Case of traumatic optic neuritis; absolute blindness and recovery, Dr. Wilmer (read by title).

31. Skin-grafting in ophthalmic surgery, Dr. Buller (read by title).

32. Exhibition of instruments by Dr. Jackson: (1) for measuring prominence of eyeball, (2) new form of retinoscope, (3) pupil-stop.

Adjourned.

S. B. ST. JOHN,
Secretary.

Members present at the thirty-ninth annual meeting:

Dr. J. B. EMERSON,
A. E. ADAMS,
G. E. DE SCHWEINITZ,
R. L. RANDOLPH,
L. H. TAYLOR,
T. B. SCHNEIDEMAN,
DUNBAR ROY,
D. WEBSTER,
A. A. HUBBELL,
WM. T. SHOEMAKER,
EDW. JACKSON,
ALEX. DUANE,
GEO. STRAWBRIDGE,
F. B. LORING,
L. HOWE,
W. L. PYLE,
P. N. K. SCHWENK,
ANTON COE,
J. A. WHITE,
H. O. REIK,
B. L. MILLIKIN,
H. D. BRUNS,
C. S. BULL,
JAS. SPALDING,
C. W. KOLLOCK,
C. D. WESTCOTT,
H. W. RING,
W. V. MARMION,
E. GRUENING,
H. KNAPP,
GEO. FISKE,
W. B. JOHNSON,
GEO. M. GOULD,
C. M. CULVER,
F. D. SKEEL,
F. M. WILSON,
J. D. RUSHMORE,
H. G. MILLER,
C. F. CLARK,

Dr. PERCY FRIDENBERG,
D. B. LOVELL,
S. M. BURNETT,
H. W. KILBURN,
GEO. T. STEVENS,
JNO. T. CARPENTER,
R. A. REEVE,
A. G. THOMSON,
J. W. INGALLS,
W. H. WILDER,
JNO. VAN DUYN,
F. W. MARLOW,
D. W. HUNTER,
W. B. MARPLE,
A. MATHEWSON,
W. E. LAMBERT,
T. Y. SUTPHEN,
O. F. WADSWORTH,
W. H. WILMER,
F. N. LEWIS,
E. E. HOLT,
C. H. THOMAS,
S. B. ST. JOHN,
W. H. CARMALT,
S. O. RICHEY,
W. S. DENNETT,
HIRAM WOODS,
JAS. THORINGTON,
JNO. GREEN,
JNO. L. ADAMS,
H. F. HANSELL,
HERBERT HARLAN,
W. D. HALL,
C. H. WILLIAMS,
S. THEOBALD,
G. W. ALLYN,
B. ALEX. RANDALL,
S. D. RISLEY,
F. BUTLER.

THE PRESENT STATUS OF SUBCONJUNCTIVAL INJECTIONS IN OPHTHALMIC THERAPEUTICS.

BY CHARLES STEDMAN BULL, A.M., M.D.,
NEW YORK CITY.

In the seven or eight years which have elapsed since the introduction of subconjunctival injections into ophthalmic therapeutics, an army of experimenters have published their experience, either for or against the new method of treatment. As in the case of other remedial measures, either medical or surgical, the advantages claimed for the new method have been beyond all reason. The field for its proper employment has been unwisely extended, and the most extravagant predictions have been made as to its future usefulness. As many of these predictions have not been fulfilled, a general feeling of skepticism is beginning to be developed as to the probability of any good results from the use of subconjunctival injections, which is unfortunate. As time elapses, we may expect the method to find its true and reasonable place in ophthalmic therapeutics.

A glance through the literature of the past seven years will show how contradictory has been the evidence offered of the real value of subconjunctival injections, and a careful study of the various papers on the subject will the better enable us to separate the wheat from the chaff.

In 1897, *Di Lorenzo* and *Bajardi* experimented with sublimate injections, and independently of each other concluded that they were useless in infectious processes, because they showed no antiseptic action.

In the same year *Addario* experimented with sublimate injections, and reported that they acted very beneficially in infectious irido-chorioiditis, especially the acute form, by causing a contraction but not a disappearance of the exudation. Sympathetic ophthalmia required many injections of from ½ to 1 ccm. of a 1

per cent. solution. In the same year, 1897, *Lagrange* recommended a 1 per cent. solution of mercuric cyanide in cases of traumatic infectious panophthalmitis, for cutting short the attack.

In 1897, *Ostwalt* advised the injection of iodoform beneath the conjunctiva and even into the anterior chamber, in all cases of infectious disease or of infection after operation.

In 1897, *Tornatola* and *Alessandro* advanced the claims of sodium chloride. They stated that the usefulness of these injections depended on the artificially excited inflammation and cellular activity. But they also stated that they caused great œdema of the conjunctiva and cornea, and hemorrhages into the uveal tract.

In 1897, *Zehnder*, in an inaugural dissertation, found a 4 per cent. solution of sodium chloride useful in retinitis pigmentosa in improving the vision and widening the field. In detachment of the retina it proved very useful, curing three out of ten cases and causing an improvement in five more. He also found it useful in all diseases of the uvea in 2, 4, and 10 per cent. solutions.

In 1897, *Frommaget* and *Laffay* experimented with mercuric cyanide in 0.10 solution in suppuration of the cornea, and the staphylococci were all killed.

In 1898, *Magnani* advised injections of a preparation called phospholuteina in 10 to 20 per cent. solutions for all scrofulous diseases of the eye.

In 1898, *Tornatola* reported that sublimate injections of a 1 per cent. solution were a powerful and rapidly acting, but painful, derivative in corneal processes, iritis and retinitis.

In 1898, *Petella* recommended sublimate injections of 1-5000, in all diseases of the uveal tract.

In 1898, *Addario* reported that the percentage of sublimate found in the aqueous humor after subconjunctival injections was less than 1 in 10,000, and that in this strength its antiseptic value was worthless, and that therefore the drug must act beneficially in some other way.

In 1899, *Puccioni* published in a monograph his conclusions that in advanced infectious diseases of the eye no injections of any kind were of any value *alone*. After subconjunctival injections of sublimate, neither sublimate nor metallic mercury could ever be found in the aqueous humor, cornea, or other parts of the globe. He found them, however, of value in syphilitic diseases.

In 1899, *Ubry* and *Frézals* reported that in their experiments with potassium iodide and sodium salicylate, neither of the drugs could be found in the aqueous humor after injection, unless at the same time a large dose were given internally, but when they were dropped into the conjunctival cul-de-sac they were later found in the aqueous humor.

In 1899, *Straub* recommended sublimate injections in all cases where it was necessary to produce a rapid effect.

In 1899, *Brunsi* reported that sublimate injections were of use only in infectious keratitis.

In 1899, *Neunhöfer* concluded that the only subconjunctival injections which should be recommended were those of sodium chloride, on account of their power of exciting rapid absorption.

In 1899, *Darier*, in his characteristically enthusiastic way, reported that in cases of chorioiditis, especially of the macular region, subconjunctival injections of sublimate and sodium chloride were more valuable than all other methods of treatment.

In 1899, *Vogel* published the results of his investigations on the entrance of soluble substances into the interior of the eye after subconjunctival injections, which make interesting reading. He did not succeed in finding any K.I. in the interior of the eye by the usual methods of reaction. In injecting solutions of mercurial salts he added a certain proportion of sodium chloride, and a few drops of dilute hydrochloric acid, so as to avoid the deposit of albuminates in the tissues. He found that when any trace of a mercurial salt was discovered in the aqueous humor, it was always less than 1-100,000, which is much too weak to have any therapeutic effect.

In 1899, *Signorino* and *Cattaneo*, independently of each other, reported on the use of subconjunctival sublimate injections. The former found them very serviceable in commencing purulent uveitis, provided the cornea remained intact. If the injections were done early enough, some vision was preserved, and if the purulent process were advanced, panophthalmitis could be prevented. On the other hand *Cattaneo* has seen no good result from these sublimate injections in any form of eye disease, and thinks their use should be discontinued.

In 1900, *Matussowsky* spoke highly of subconjunctival injections of sodium chloride in 3 per cent. solution, for corneal ulcers, mykotic affections of the cornea, and iritis of various kinds.

In 1900, *Morgano* came forward with a new substance for injection in infective processes of the cornea and iris, which he called anticeltina. This consists of a derivate of urea with mercury, and contains 43 per cent. of mercury, is soluble in water in 1 to 1,000, does not precipitate albumen, and does not irritate the tissues. He used from 0.5 to 1 per cent. solutions, injected it warm beneath the conjunctiva, and spoke most highly of its efficacy in shortening the duration of the infective processes.

Somewhat later in the same year, *Morgano* seems to have transferred his faith and devotion to Pohel's "physiological salt solution," a solution of many ingredients, which is supposed to act by increasing the osmotic pressure of the fluids of the tissues, and represents also a bio-chemical effect on the inflamed organs and their exudates, provoking in them histo-biological and chemical changes which favor their absorption. *Morgano* goes on to cite the experiments of Pflueger, Frommaget, Laffay, Lagrange, Addario and others to prove the rapid passage into the interior of the eye of certain soluble substances injected beneath the conjunctiva, and especially of such non-irritating salts as Pohel's solution. He claims that these injections always cause an improvement in the inflammatory processes of the internal coats of the eye, especially of the exudative forms. This improvement sometimes begins after the first injection and pro-

ceeds rapidly. The vision and color sense improve, and the vitreous clears up. He found the improvement inversely proportional to the state of the disease; that is, the more recent the attack, the greater the improvement. The injections cause no pain or reaction, and may be repeated daily. He prefers a 1.5 per cent. solution, which should always be fresh and at a temperature of 37° to 38° C. It should be injected slowly and followed by cold compresses for an hour.

In 1901, *Valenti* recommended a 1 per cent. sublimate solution, and *Angelucci* a mixture of sublimate and salt of the same strength, as particularly useful in septic corneal processes and in syphilitic diseases.

In 1901, *Stasinski* spoke strongly of the very beneficial effect of salt solutions in all cases of acute chorioiditis, stating that the exudation rapidly disappeared and vision was restored to the normal.

In 1901, *Pflueger* published an article in favor of injections of sodium iodide and sodium chloride in a 2 per cent. solution, in cases of chronic chorioiditis, with opacities of the vitreous humor. He, however, combined with the subconjunctival injections puncture of the anterior chamber, which he claims considerably augments the effect. He found that injections of stronger solutions (4 to 10 per cent.) caused severe pain, but were indicated in detachment of the retina.

He subsequently tried another lymphogenous substance, more effective in weak solutions, and at the same time less painful, namely hetol or sodium cinnamate, in solutions of 1 to 5 per cent. He found that this substance produced a leucocytosis and an aseptic inflammation around the foci of disease with envelopment of these foci by leucocytes. The new formation of embryonic tissue caused absorption of the masses of infiltration, which are replaced by solid connective tissue. He thinks that hetol is especially adapted for tuberculous affections, but believes that all diseases in which artificially produced leucocytosis would favor a cure should respond to this treatment. He claims to have brought about a more than usually

rapid healing in corneal herpes, deep corneal ulcers, iridocyclitis, tuberculous uveitis and scleritis, by injections every second day of from 4 to 5 ccm. of a 1 per cent. hetol solution. The pain caused was very slight and brief, and dressings were unnecessary.

In 1901, *Uribe Troncano* vaunted the claims of solutions of mercuric cyanide for all cases of exudative inflammation within the eye.

In 1902, *Hecker* recommended injections of gelatine of 2½ per cent. concentration, carefully steriiized, with a 3 to 5 per cent. solution of salt, for detachment of the retina.

In 1902, *Bourgeois* reported twelve cases of detachment of the retina, in which he injected a concentrated (30 per cent.) solution of salt. One case was cured, three cases were markedly improved, and three cases were slightly improved.

An examination of all the papers published on this subject by the various authors quoted, and a careful study of all the cases of all kinds reported, leads irresistibly to at least one conclusion, viz.: that the efficiency of these various solutions injected beneath the ocular conjunctiva cannot be ascribed to the increased local acceleration of the lymph currents, the so-called leucocytosis, nor to the antiseptic action of the remedies employed, since the presence of such processes cannot be demonstrated in the tissues of the eye, following the injections. The chief change seems to be in the composition of the aqueous humor. This is said to become much richer in albuminoids, due to the irritating action of the injected substances upon the blood vessels. This causes congestion of the vessels and an increased transudation of albuminoid substances from the vessels into the aqueous humor. The physiological chemists have taught us that the protective substances of the blood are always to be found in combination with the albuminoids of the blood. Hence coincidental with the increase of serum albumen in the aqueous humor would be the appearance of various protective substances in the same. If subconjunctival injections of sublimate or sodium chloride be made, it will be found shortly after-

wards that the aqueous humor has become markedly hæmolytic. Hence the action of these subconjunctival injections is to be sought in their local irritating properties.

During the past three years the writer has employed the method of treatment by subconjunctival injections in various diseases of the eye, including different forms of keratitis, chorioiditis, iridochorioiditis, detachment of the retina, cellulitis of the lids and orbit, and panophthalmitis. A number of different solutions were used, sodium chloride, sublimate, mercuric oxycyanide, and hetol, and of varying strength. I have not been able to determine any important difference in their mode of action or effect between salt solutions and solutions of mercuric cyanide, so highly extolled by Darier. I have not had the success which Haitz claims in cases of central chorioiditis and recent opacities of the vitreous with a solution of mercuric cyanide, and I have found this solution very painful to the patient, even when cocaine or acoine was added to the solution before injection. The solution used was 1 to 5,000, with 2 per cent. of a 2 per cent. salt solution added. The injection of this preparation always caused a great deal of reaction, severe pain, and conjunctival inflammation, and was followed by persistent chemosis and hypersensitiveness of the conjunctiva.

Hetol or sodium cinnamate was employed in a 1 per cent. sterilized aqueous solution, of which 0.5 gramme was injected at first every second day, cocaine being first injected. This was used in various corneal affections, herpes, wounds, pannus, interstitial keratitis, and in chorioiditis and scleritis. This solution was less painful than the mercurial preparations and seemed to influence favorably the course of the disease in herpes and parenchymatous keratitis. It seemed to be of benefit in acute inflammation of the uvea in hastening the process of absorption. The beneficial effect seemed to come on sooner if the disease were superficial, as in corneal cases. It was apparently of no use in chronic cases, notably in scleritis. It was used persistently in two cases of tuberculous disease of the iris and choroid, but apparently without the slightest effect.

A careful observation of my own cases, in which various solutions were employed, has not been able to convince me that subconjunctival injections bring about any more rapid or favorable results than other methods of treatment which we have hitherto employed, for affections of the cornea, uveal tract, or retina. In several cases of orbital cellulitis of an infectious character, however, I found that subconjunctival injections of a sublimate solution (1-1000) did exert a very favorable and unusually rapid effect in hastening the suppurative stage, in reducing the dense infiltration of the orbital cellular tissue, and thus aiding in restoring the circulation to the strangulated parts.

My own conclusions, based on observation of my own cases and a careful study of the literature of the subject, are that all reports of the beneficial effects of subconjunctival injections should be carefully criticised and compared with the results obtained by other methods of treatment, before accepting them as of any real value.

CASE OF PULSATING EXOPHTHALMOS, OF TRAUMATIC ORIGIN — LIGATURE OF THE COMMON CAROTID — RECOVERY.

BY CHARLES STEDMAN BULL, A.M., M.D.,
NEW YORK CITY.

The patient was a man, aged 29, a laborer, who, on the night of January 8, 1902, was struck on the top of the head by a bottle. The bottle was full of beer and was not broken by the blow. The patient was not knocked down by the blow nor rendered unconscious, and there was no laceration of the scalp. The next morning he became conscious of a continuous roaring noise in the left side of his head, which rapidly grew louder and extended all over his head. On the second day the left eye began to protrude and the eyelids to swell. Within a week both eyes showed enormously distended conjunctival and subconjunctival veins and engorgement of the subcutaneous veins

Pulsating Exophthalmos. — Arterio-venous aneurism.
Before ligation of common carotid.

of both lids of both eyes, the engorgement and distention of all the vessels being more marked on the left side. There was no pain in the eyes or head, but only a sense of confusion which he attributed to the constant noise. He applied at the New York Eye Infirmary early in February, nearly a month after the injury was received, and the following condition was noted. The *left* eye protruded directly forwards and at least one-half of its antero-posterior diameter projected beyond the plane of the orbit. There was marked chemosis of the conjunctiva, and great swelling of the lids, the œdema extending up under the eyebrow, downwards upon the cheek, and outwards towards the temple. The skin of the lids was of a dusky purplish hue from obstruction to the venous circulation. The chemosis was most marked inwards, downwards, and outwards. The right eye also protruded slightly forwards, but there was no chemosis. The conjunctival and subconjunctival veins of both eyes were greatly engorged and very tortuous. There was a loud bruit heard over the left eye and left side of the forehead and left temple, and this bruit was distinctly audible on the right side of the head, vertex, and occipital region. There was a distinct pulsation of the left eyeball, perceptible to the eye as well as to the finger, but none of the right eye. There was no interference with the motility in any direction of either eye. The tension of the eyes was normal. The pupils were of normal size and the irides of normal reaction. Vision was 20/20 in each eye, and there was no defect nor limitation of the field of vision of either eye. The media were clear, and there was distinct pulsation of the retinal veins, which were greatly engorged, but without any accompanying hemorrhages.

One week later there appeared a greatly enlarged vein, emerging just beneath the superior orbital margin, at the juncture of the middle and inner third, and running up over the forehead nearly to the vertex. Just beneath this vein there was a distinct fissure in the frontal bone, extending from the margin of the orbit nearly to the vertex, and widest at its lower end. This fissure could be traced for some distance backwards along the

roof of the orbit. There seemed no reasonable doubt that there had been a fracture of the skull, beginning at or near the point of the blow at the vertex and extending through the vertical plate of the frontal and the orbital plate of the same bone backward to the optic foramen, and that as a result of the fracture an arterio-venous aneurism had been formed posterior to the orbit and possibly involving the opposite side. The partial protrusion of the right eye and the general marked engorgement of the retinal and subconjunctival veins would be difficult of explanation on any different hypothesis.

The only treatment that promised any satisfactory result seemed to be the ligation of one or more vessels in the neck, and the patient was therefore transferred to the New York Hospital for operation by Dr. Murray.

It was decided to tie the common carotid on the left side. The operation was performed by Dr. Francis W. Murray on March 1, 1902. The artery was ligated just above the omohyoid muscle by two gut ligatures, one-quarter of an inch apart, and the artery was severed between the ligatures. The pulsation, thrill, and bruit in and around the orbit ceased immediately and have not returned. The wound healed by first intention and the patient left the hospital on the tenth day. The swelling of the lids and the chemosis slowly subsided, and the exophthalmos gradually diminished, until there was but little protrusion left. The engorgement of the subconjunctival vessels, however, remained in both eyes, with but little diminution in size, as long as the patient remained under observation.

This patient was last seen and examined on February 17, 1903, about a year after the operation. R. E. V=20/20: L. E. 20/50 unimproved by glasses. He read Jaeger No. 1 with either eye at the normal distance. There was slight divergence of the left eye in the fixation for distance, but not in fixation for the near-point. There was a slight degree of exophthalmos of the left eye, but none of the right eye. Both pupils were normal in size and reaction. The subconjunctival veins of both eyes were still very engorged, and the large vein running vertically

Pulsating Exophthalmos. Arterio-venous aneurism one week after ligation of left common carotid.

over the forehead on the left side was still very much in evidence. There was no apparent change in the fissure through the frontal bone. The media were clear. The retinal veins of both eyes were still engorged and tortuous and all over the retina of the left eye were the remains of numerous hemorrhages.

There was no bruit or pulsation discernible anywhere after the most careful examination, and the general health of the patient was excellent.

CONCERNING A POSSIBLE ETIOLOGICAL FACTOR IN TOBACCO-ALCOHOL AMBLYOPIA REVEALED BY AN ANALYSIS OF THE URINE OF CASES OF THIS CHARACTER.

BY G. E. DE SCHWEINITZ, A.M., M.D.,
AND
DAVID L. EDSALL, M.D.,
PHILADELPHIA, PA.

In recent times the pathogenesis of the toxic amblyopias in general and particularly the alterations which are produced in the ganglion cells of the retina and optic nerve by the action of quinine, methyl alcohol, and filix mas have attracted much attention. For a full consideration of the literature of this subject and the various views of experimenters and observers, the reader is referred to the papers of Ward Holden[1], Drualt[2], Nuel[3], Uhthoff[4], Siegrist[5], Uhthoff and Groenouw[6], Nohl[7], Birch-Hirschfeld[8], de Schweinitz[9], and Schieck[10]. It is not, however,

[1] Transactions of the American Ophthalmological Society, 1898.
[2] Recherches sur la Pathogenie de l'amaurose quinine, Paris, 1900, and Archives d'Ophth., January, 1902, p. 19.
[3] The XIII Congrès International de Médecine, Section d'Ophthalmologie, Paris, 1900.
[4] Ibid.
[5] Archiv. f. Augenheilk., March, 1900.
[6] Graefe-Saemisch, Handbuch der Gesamten Augenheilkunde, Zweite Auflage, 32. Lieferung, 1901.
[7] Beiträge zur Augenheilkunde, Heft 48, 1901, p. 51.
[8] Archiv. f. Ophthalmologie, Bd. 52, 1900, p. 358; ibid, 53, 1901-1902, p. 79; ibid, 54, 1902, p. 68; ibid, 55, 1903, p. 380.
[9] Ophthalmic Record, April, 1902.
[10] Archiv. f. Ophth., 54, 1902, p. 458

the purpose of the present paper to discuss whether the alcohol or the tobacco produçes primarily a lesion in the optic nerve fibers or the ganglion cells of the retina; what significance should be ascribed to the vessel changes which have been demonstrated in the opticus, or whether the inflammation of the interstitial connective tissue of the optic nerve should be regarded as an essential cause of the disease, or only as an accidental condition, that is to say, whether the nerve degeneration in the optic apparatus is a primary one, or whether it is secondary to a proliferation of the interstitial connective tissue; but to attempt to throw some light on what the possible poison is which produces one or other or all of these changes, which in their turn interpret themselves by the clinical symptoms of this well-known form of amblyopia.

Writing on this subject in 1900, one of us (Dr. de Schweinitz)[1] said: "It is quite possible that nicotin, or one or more of the many principles freely present in tobacco smoke, liberates some toxic influence in the system which must be held accountable for the disease, which, in other words, depends upon a species of *auto-intoxication*. Horner long ago contended that neither alcohol nor tobacco, as such, was the direct toxic agent in cases of central amblyopia, but that together these drugs produced chronic gastric catarrh, which in its turn established a chronic anemia of the optic nerve, terminating in the pathological changes which are found in this disease. Sachs maintained that even in the pure tobacco cases certain complex chemical combinations occur in the stomach, and there was a resulting transformation of the normal gastric juices into acids of the fatty type, which combined with nicotin into substances which were more injurious than the simple tobacco bases themselves. This observation is important in connection with certain experimental work under the direction of Dr. Casey Wood, not yet published, which indicates that certain stomachic toxins are capable of causing in animals blindness probably of the type now under consideration."

[1] System of Diseases of the Eye, edited by Norris and Oliver, Vol. IV, p. 183.

It therefore seemed to us that one method to approach this study was to submit the urine of patients suffering from tobacco amblyopia to a thorough analysis, according to the methods of modern physiological chemistry, to regulate the patient's diet according to the findings until the normal standard in the excretions of the body was reached, and to note the effect of such treatment upon the amblyopia from which he suffered. Necessarily, such a research in order to be satisfactory would require the examination of a great number of patients and the observation of the effect of treatment over long periods of time, but even though the present communication is based upon an investigation of few patients of this class, and though the observations cover a comparatively short time, they are reported with the hope that they may stimulate still further research along this line, on the one hand, and on the other, because they at least give an indication that Horner's views expressed years ago were not without foundation.

Case 1. · A. F., male, aged 46, American by birth, a negative retoucher by occupation, applied for treatment on account of failing vision September 2, 1902. There is nothing of importance in the family history, and in general terms he has been a fairly healthy man except for some gastric disturbance, and he is free from syphilis. He has smoked for many years, but, according to his statement, never immoderately. He has been accustomed to drink beer, and occasionally whisky, but has not been dissipated in the sense in which that term is ordinarily used. In the spring of 1902 he noted blurring of vision which seriously interfered with his occupation and which was attributed to refractive error, the correction of which failed to bring about improvement.

Ocular Examination. — V. of O. D. 6/30, D.= 1.50 was read with difficulty with $+2^s$. The pupil reaction was normal, the media were clear, and the optic disc was a vertical oval with distinct pallor on the temporal side, especially in the region of the papillo-macular bundle.

V. of O. S. 6/30, D.= 1.50 read at 25 cm. with +2D with difficulty. The pupil reaction was normal, the media were clear,

the disc was a vertical oval and was distinctly more pallid on the temporal side than elsewhere and more pallid than upon the opposite side. The form fields were normal, there was slight contraction of the red fields, and a faint negative scotoma in the center of each field. The patient was directed to discontinue smoking and drinking and was ordered strychnia. At the end of a month there was absolutely no improvement in vision and also no depreciation, and he was submitted to a thorough *general examination*, as follows:

There was slight dyspnœa, attributable to a moderate grade of emphysema, but otherwise the physical examination by ordinary methods was negative. The blood count showed hæmoglobin 75 per cent., red cells 5,910,000, leucocytes 11,700. The high counts were probably due to a slight cyanosis caused by his emphysema. Stained specimens of the blood were negative. Examination of the gastric contents after the test meal showed no free hydrochloric acid and a considerable amount of tough mucus, indicating the presence of chronic gastritis.

The urine examination was as follows:

	Oct. 6, 1902.	Nov. 8, 1903.
Amount,	2280 cc.	2176 cc.
Indican,	Extremely marked; unchanged by heat.	Negative.
Phenol,	Negative.	"
Acetone,	"	"
Vol. fatty acids,	191.4.	114.8.
NH_3 nitrogen,	0.7404 gm.	0.5115 gm.
Total "	14.946 gm.	13.267 gm.
Preformed sulphates,	2.311 gm.	2.095 gm.
Conjugate sulphates,	0.4249 gm.	0.2897 gm.
Urobilin,	Present upon extracting 15 cc. of urine.	A trace upon extracting 30 cc. of urine.

The patient was placed upon suitable diet, all medication discontinued, and at the end of six weeks, when the last examination was made and when there was practical disappearance of the abnormal conditions revealed by urinalysis, the vision with suitable correction had risen to 6/12 in each eye, and the central scotoma could not be demonstrated.

Case 2. C. H., male, aged 36, American by birth, a merchant by occupation, applied for treatment June 6, 1902, on account of dull vision, which, however, was nearly normal with test types. The optic discs were congested, and there was a small capillary hemorrhage on the edge of the right disc. He was not seen again until the 19th of September of the same year, when there was marked increase in the blurred vision. The family history is unimportant. The patient denies syphilis. He has been an inveterate smoker for years and consumes great quantities of cigarettes. He also drinks freely, especially whisky, and is not above the suspicion of having taken other drugs. In general terms, he has always been dyspeptic, exceedingly nervous, subject to vertigo and violent headaches, and was told that all of his symptoms depended upon uric acid.

Ocular Examination. — V. of each eye 6/12, D.= 0.75 was read with difficulty. The pupil reactions were normal, the media clear, each optic disc was slightly congested, the retinal veins were rather full and the fiber layer of the retinas markedly streaked. A suggestion of pallor in the deeper portions of the optic nerves, especially on the temporal sides, was evident. The visual fields for form and red were normal in extent, and in the center of each there was a small, almost circular, negative scotoma.

General physical examination, which was made by Dr. Alfred Stengel, revealed the following state of affairs: There was slight accentuation of his second heart sound, with some suggestion of beginning arterial change. There was no discoverable kidney change, either in the form of albumin or casts. There was a moderate degree of psoriasis, which was attributed to his general systemic condition. The blood examination was negative.

The urine examination was as follows:

	Oct. 7, 1902.	Oct. 8, 1902.
Amount,	375 cc.	520 cc.
Indican,	Marked; lessened by heat.	Slight.
Phenol,	Negative.	Negative.
Acetone,	"	"

	Oct. 7, 1902.	Oct. 8, 1902.
Vol. fatty acids,	60.	62.4
NH_3 nitrogen,	0.2184 gm.	0.1512 gm.
Total "	4.977 gm.	5.4739 gm.
Pref. sulphates,	1.246 gm.	0.5724 gm.
Conj. "	0.092 gm.	0.0718 gm.
Urobilin,	An intense band on the first washing and first extraction, which persisted to the third dilution.	An intense band on the first extraction, which persisted to the fourth dilution.

Commenting on this examination and others which he made, Dr. Stengel writes as follows: "There is a profound disturbance of food assimilation with reduction of its utilization. There is probably a marked disorder of the liver, which plays an important part in this metabolic inactivity. There is no evidence of any acid intoxication or uric acid diathesis, whatever that term may mean."

The treatment consisted in the regulation of diet and abstinence from tobacco and alcohol. At the end of a week vision had risen in the right eye to 6/6, in the left eye to 6/7.5, and D.= 0.50 could be read at 22 cm. The slight color scotoma was no longer demonstrable. Since this date the patient has not been seen.

Case 3. R. J., male, aged 52, American by birth, a cook by occupation, applied for treatment in the Eye Dispensary of the University Hospital, November 11, 1902, on account of failing vision, which had been particularly marked for ten weeks. In general terms, the patient had been a fairly healthy man; specific taint is denied. On the 8th of July, 1902, his back was injured, although apparently not severely, by a fall, and he maintains that since that time he has had attacks of urticaria which came on in the evening and lasted until early morning. He has smoked excessively since he was fifteen, as much as two ounces *per diem* in a pipe, and has drunk whisky to excess.

Ocular Examination. — V. of O. D. 6/150, V. of O. S. 6/60. Ophthalmoscopically, the media were clear, the optic discs vertical ovals, with marked pallor of their temporal sides; no

changes in the retinal circulation or in the general expanse of the eyegrounds were present. The visual fields for form and red were normal, and in the center of each there was a typical oval scotoma for colors.

The urine examination was as follows:

	Nov. 17, 1902.
Amount,	1675 cc.
Indican,	Moderate.
Phenol,	Negative.
Acetone,	"
Vol. fatty acids,	200.7
NH_3 nitrogen,	0.2998 gm.
Total "	10.5867 gm.
Pref. sulphates,	1.6757 gm.
Conj. "	0.2892 gm.
Urobilin,	Slight band on first extraction.

The patient was exceedingly irregular in attendance; indeed, he returned but once after the urinary examination was made. At that time, namely, on the 15th of November, 1902, vision was slightly better; O. D. 6/45, O. S. 6/22; the scotomas were smaller but present. The patient had not smoked; it is doubtful whether he stopped drinking. He had taken 1/30 of a grain of strychnia three times a day. The effects of diet in this case could not be tried.

Case 4. O. M., aged 51, American by birth, a night watchman by occupation, applied for treatment in the Eye Dispensary of the University Hospital November 17, 1902, for failing vision which he had tried to remedy unavailingly by purchasing various kinds of glasses. In general terms, the family and personal history are negative; specific infection is denied. There was a large scar on the cheek, extending from the margin of the orbit to below the malar bone, which had been produced by the kick of a horse many years ago, and which had caused an ectropion of the right lower lid. The patient had been an incessant smoker for many years. He drank some beer, but, as he expressed it, "spirits mainly."

Ocular Examination.—V. of O. D. 4/60, V. of O. S. 6/30, unimproved by glasses. The media were clear and the pupil

reactions normal. The ophthalmoscope revealed vertically oval optic discs, with marked pallor of their temporal halves. The peripheral fields for white and red were normal, and in the center of each field there was a large typically oval scotoma.

The urine examination was as follows:

	Nov. 24, 1902.	Nov. 28, 1902.
Amount,	720 cc.	1120 cc.
Indican,	Intense; less marked after boiling.	Slight.
Phenol,	Marked.	Negative.
Acetone,	Negative.	"
Vol. fatty acids,	59.	44.9
NH_3 nitrogen,	0.4435 gm.	0.5644 gm.
Total "	6.773 gm.	11.101 gm.
Pref. sulphates,	1.773 gm.	1.401 gm.
Conj. sulphates,	0.2432 gm.	0.2919 gm.
Urobilin,	Slight band on first extraction.	Negative.

NOTE.—Examinations of this man's urine were made every day that he was in the hospital, for another purpose. The volatile fatty acids ran, for the first three days, between 60 and 95. After this they decreased to about 40. There was a constant decrease in the intensity of the reactions for phenol and indican. The total conjugate sulphates did not vary greatly.

The patient was placed upon the proper diet. At the last examination in the Eye Dispensary, namely on December 1, 1902, the vision of the right eye had risen to 6/30 and of the left eye to 6/22; central color perception improved, but not restored. Since this date he has not reported.

Case 5. T. T., aged 55, American by birth, a laborer, applied for treatment in the Eye Dispensary of the University Hospital January 15, 1903, for relief from failing eyesight, which had been particularly marked in the last week. He denied recent illness of any kind and there is no history of specific taint. He has been an incessant smoker for years. He denied the abuse of intoxicating drinks, but not their use.

Ocular Examination.—V. of O. D. 6/45, V. of O. S. 6/30, unimproved by glasses. The pupillary reactions were normal, the media clear, the optic disc of each eye slightly blurred and discolored, especially upon the outer side. The veins were dilated, irregular in caliber, and pressed upon by arteries which

showed the stiffening of beginning endarterial changes. In the right eye below the temporal vein there was a small linear hemorrhage. The conditions of the left eye were similar but no hemorrhages were discovered. The visual fields for form and red were practically normal, and occupied in their centers by negative scotomas, the one on the right side being the larger.

The urine examination was as follows:

	January 22, 1903.
Amount,	900 cc.
Indican,	Extremely intense.
Phenol,	Negative.
Acetone,	"
Vol. fatty acids,	54.
NH_3 nitrogen,	0.5036 gm.
Total "	10.1462 gm.
Pref. sulphates,	Not estimated.
Conj. "	0.3254 gm.
Urobilin,	A distinct band on direct examination of urine.

The patient was advised to stop tobacco and alcohol and was given a regulated diet. At the last examination, namely on January 22, vision in the right eye was 6/45 and in the left eye 6/22; therefore only a very slight improvement.

Case 6. H. F., aged 41, American by birth, a railroad employee by occupation, applied to the Eye Dispensary of the University Hospital on November 15, 1902, on account of failing vision, especially marked for the last week. There is nothing important in the patient's family history. Seventeen years ago he had malaria, but since then no other acute illness. He had hemorrhoids, which were successfully operated upon three months before he applied for examination. He had gonorrhoea many years ago, but there is no syphilitic history. He has used tobacco to excess and also whisky, drinking sometimes as much as a quart a day.

Ocular Examination.—V. of each eye 6/150, unimproved by glasses. Pupil reactions present but light reactions slightly sluggish. Ophthalmoscopically there was evident a low-grade interstitial neuritis with perivasculitis on each side; the veins

were full, uneven, and tortuous, and the arteries streaked with white lines. The visual fields were moderately contracted and there was entire lack of all color perception, so that the presence of scotomas as such could not be demonstrated.

General physical examination failed to reveal any well-marked disease except in so far as the liver was concerned, which was distinctly enlarged. There was also a history of liver trouble for the last three or four years. The blood examination was as follows: Hæmoglobin, 83 per cent.; red blood corpuscles, 5,540,000, white blood corpuscles, 9,600.

The urine examination was as follows:

Amount,	900 cc.
Indican,	Extremely intense.
Phenol,	Most intense ever noted.
Acetone,	Negative.
Vol. fatty acids,	37.2
NH_3 nitrogen,	0.434 gm.
Total "	9.763 gm.
Pref. sulphates,	Record lost.
Conj. "	" "
Urobilin,	A marked band on direct examination of the urine.

NOTE.— Repeated examinations were made during his stay in the hospital, and there was a constant decrease in the intensity of the urobilinuria and of the reactions for indican and phenol. Urobilin nearly disappeared by January 10th, and was quite gone by the 15th. The phenol and indican reactions were still positive when the man left, but less markedly so. The volatile fatty acids varied little, and were always low.

The patient was admitted to the University Hospital on December 18, and remained there until the 4th of February. The treatment consisted in suitable regulation of the diet, and, as required, saline purges and calomel. Visual improvement was manifest at the end of two weeks. By the 10th of January vision had risen to 1/2 of normal, and on the 25th of January, or a few days prior to his discharge from the hospital, it was 6/5 in each eye. The visual fields were practically normal for form and color; no scotomas.

Case 7. T. J. W., aged 54, American by birth, a bookkeeper by occupation, reported for treatment in the Eye Dispensary of the University Hospital July 9, 1901, on account of failing vision,

which was marked for three weeks. His general clinical and family history is unimportant. Specific taint is denied, but the patient had used tobacco and alcohol to very great excess for years.

Ocular Examination. — V. of O. D. 3/150, V. of O. S. 3/150. Media clear, pupils normal, and on each side the optic discs round, the nasal edges hazy, the temporal halves gray, especially at the papillo-macular bundles. There was almost entire lack of color perception, the note on the book being that it was impossible to obtain fields for colors at all.

This patient continued to attend the Dispensary of the University Hospital, and took from time to time bichloride of mercury, iodide of potassium and strychnia, and stopped at once his tobacco and alcohol. There was a slow improvement, and when he first came under our observation, that is, on December 6, 1902, the field of vision of each eye was slightly contracted for form and red, and there was a small central scotoma for all colors. The ophthalmoscope revealed marked pallor of the temporal half of each optic disc, indeed, there was distinct atrophy of the papillo-macular bundle. Otherwise there were no changes. The visual acuity was O. D. 6/30, O. S. 6/15. The patient had not used tobacco or alcohol in any form for seventeen months.

The urine examination was as follows:

	December 10, 1902.
Amount,	940 cc.
Indican,	Moderate.
Phenol,	Marked.
Acetone,	Negative.
Vol. fatty acids,	152.2.
NH_3 nitrogen,	0.4421 gm.
Total "	9.6594 gm.
Pref. sulphates,	2.2458 gm.
Conj. "	0.1748 gm.
Urobilin,	A band on extracting 30 cc. of urine.

NOTE.— A second examination, made December 24, 1902, showed no indican; no phenol; conj. sulphates, 0.1253; volatile fatty acids, 60.4; urobilin, absent.
A third examination, made February 27, 1903, showed normal conditions.

All medication was stopped, the patient placed upon strict diet, and on the 14th of February, 1903, or two months after treatment, the vision of the right eye was 6/12 and that of the left eye 6/15, a slight improvement in the right eye and stationary vision in the left. The patient, however, was quite sure that his vision was better, that is to say, as he walked the streets and in his ordinary occupation, and this improvement in vision corresponded with the restoration of the normal conditions in the urinalysis.

The methods adopted in order to determine whether recognizable signs of any intoxication were present in the first case examined (Case I) were as follows: The blood corpuscles were counted, the hemoglobin was estimated, and stained blood-smears were examined. The blood-pressure was determined with Stanton's modification of the Riva-Rocci instrument. The stomach was inflated and the stomach contents were examined. The feces were examined, and the urine was examined for albumin and sugar. The degree of intestinal composition was investigated by determining quantitatively the preformed sulphates and the conjugate sulphates (Baumann-Salkowski method), the volatile fatty acids (Blumenthal's method), and by determining the intensity of the qualitative reaction for indican (Obermayer's reagent) and for phenol (bromine test of the distillate). Urobilinuria was also looked for, and its intensity was approximately determined by Riva's method. Tests were made for acetone in the distillate and the ammonia nitrogen and the total nitrogen of the urine determined, in order to see whether there was any evidence of acid intoxication. The same methods were subsequently used, as far as possible, in examining all the other cases.[1]

The examinations of the blood and of the blood pressure were wholly negative and need no further comment. The examination of the feces also yielded nothing of consequence. The stomach contents could be examined in only five cases.[2]

[1] All of the chemical examinations and general medical examinations were made by Dr. Edsall, except the general examination of case 2, which was made by Dr. Stengel.

[2] Case 2 was not under Dr. Edsall's personal observation, and case 3 did not return for examination.

All these five cases, however, showed marked evidence of chronic gastritis. Cases 1, 4, 5, and 6 all showed an acidity, with much mucus and very poor digestion of the test meal. Case 7 showed similar conditions, and differed only in that there was a slight acidity (15) and a faint reaction for free HCl. There was no noteworthy disturbance of motility in any of these patients. None had glycosuria. Albumin was absent in all instances, except that Case 6 showed a trace for a time. This disappeared, however, while he was under observation. There was also no evidence of acid intoxication in any instance, so far as exhibited in the results for acetone and ammonia. The determinations of the intestinal decomposition-products and of the urobilin showed much more marked abnormalities. The results are given in the urinalysis appended to each case history, acetone, ammonia, and total nitrogen being included in the tables.

These conditions as compared with the normal, are, in brief, as follows:

In Case 1 there were at first very high figures for conjugate sulphates, but at the second examination nearly normal conditions; intense indicanuria at first, which disappeared; slight urobilinuria at first, which disappeared; the figures for the volatile fatty acids, at first very high, approached the normal at the second examination.

In Case 2 there was an intense urobilinuria. The results for the sulphates and volatile fatty acids were negative, but the figures for the quantitative determinations are unreliable, as they are so low that it is probable that the urine was not carefully saved.

In Case 3 there was moderate urobilinuria and the volatile fatty acids were extremely high.

In Case 4 there was a moderate urobilinuria, a marked indicanuria, and a decided reaction for phenol, all of which disappeared quickly under treatment. The volatile fatty acids tended towards the high limit of normal figures. The conjugate sulphates were constantly somewhat high.

Case 5 showed an intense indicanuria, a moderate increase of the conjugate sulphates, and a marked urobilinuria. He gave no opportunity for a second examination.

Case 6 was not specially examined until he had been in the ward a week, when his vision had somewhat improved. At first he showed intense urobilinuria and indicanuria, and a most intense reaction for phenol. The records for the sulphates have been lost. Under treatment, there was a gradual decrease in the intensity of all these reactions, and some time before he left the hospital the urobilinuria had disappeared entirely. The reactions for indican and phenol, though still present, were much less marked.

Case 7 showed at first a marked reaction for phenol and notably high values for volatile fatty acids, with a slight urobilinuria. Subsequently these abnormalities entirely disappeared.

In three of the cases examined (Cases 1, 3, and 7) the volatile fatty acids were very high. In Case 2 they were relatively high, and if the urine had been carefully saved they would probably have been absolutely high. This made it seem possible that the absorption of excessive amounts of volatile fatty acids had had something to do with the amblyopia, — a suspicion that perhaps might be increased by Kraus's report of retro-bulbar optic neuritis in his two cases of cryptogenic acid intoxication. It is possible that there is something in this view, as the figures in Case 4 are also somewhat high, and the urine of Case 6 was examined only when he had already improved, and it is possible that he would have shown an increase earlier. Case 5, however, definitely showed a normal condition of the volatile fatty acids. The actual results, therefore, are, at best, doubtful as to this point. An experimental study of the effect of the prolonged administration of acids, particularly of some of the fatty acids, might be of value.

The results in general show that there was in all cases (except, perhaps, in Case 2, in which the results are unreliable) an excessive excretion of enterogenous decomposition-products in the urine; and in all there was a more or less marked urobili-

nuria. In all the patients repeatedly examined these abnormalities nearly or quite disappeared under treatment, coincidently with improvement in the eye conditions, as follows:

In Case 1 there was absolutely no improvement in vision under the ordinary strychnia and potassium treatment. At the expiration of six weeks of special dietetic regimen, or when the results of urinalysis approached the normal standard, vision had risen to 6/12, or double that which it was at the first examination, and the scotomas had disappeared.

In Case 2, vision, which had fallen to 1/2 of normal, regained the normal standard at the end of one week of treatment, the patient being confined to a room in the hospital where he was under strict surveillance, and when there had been improvement in the abnormalities revealed by urine analysis. The doubt in regard to this case has been recorded.

Case 3 showed slight improvement in vision at the end of five days, which, however, cannot be attributed to any influence of diet and alteration in the habits, inasmuch as the patient had been exceedingly irregular in attendance and probably did not stop drinking, although he did stop smoking for at least a week.

Case 4 exhibited a moderate improvement in the vision of the right eye and a slight improvement in the vision of the left at the expiration of two weeks under the influence of dietetic management. Since this date he has not reported.

Case 5, who was under somewhat irregular observation for only seven days, showed a very slight improvement in vision.

Case 6, the most noteworthy of the series, regained, with the restoration of a normal urinary analysis, complete visual acuity. It is moreover noteworthy, that although there had been a slight improvement in vision before the urine analyses were made, that is, after one month of dispensary treatment and one week of hospital treatment, during which time the patient probably entirely abstained from alcohol and tobacco, the marked restoration of central acuity of sight exactly corresponds with the restoration to the normal or nearly normal standard of urinary analysis.

Case 7, who had not used tobacco or alcohol for seventeen months before he was submitted to the analyses which have been described, is noteworthy because, although the test-types failed to reveal much improvement in sight, that is, only from 6/15 to 6/12, the patient was so certain that his general vision had improved that he was willing to continue the strict diet on which he had been placed. That he could not expect much improvement was evident from the ophthalmoscopic change of permanent atrophy in the papillo-macular bundle.

In this connection it is proper to refer to a patient with moderate, well nigh stationary optic nerve atrophy who has been coming to the dispensary for years, his original examinations having been made ten years prior to the present time. The etiology of the optic nerve disease could not positively be determined, but apparently it was not due to the abuse of alcohol and tobacco, as the man has been for many years a total abstainer. He therefore was used as a control and showed entirely negative conditions. There was very slight reaction for indican and none for phenol. The volatile fatty acids were 50.4, the NH_3 nitrogen 0.1412 gm. The sulphates were not estimated.

In these cases there were evidences of a marked disturbance of digestion or of metabolism, or of both; furthermore, this disturbance may persist for a long time after the use of alcohol or tobacco has been stopped, as in Case 7, and the study of Case 1 apparently indicates that treatment of this secondary nutritive disturbance will cause improvement in a persistent amblyopia. These facts, we think, give just ground for the belief that toxic substances produced in the digestive tract, or in the course of metabolic processes, have, at least, a certain part in the production of the amblyopia in most of these cases; and that at times they are probably the direct cause of the continuance of the symptoms when the latter do not disappear after alcohol and tobacco have been stopped. We do not think that more should be claimed from these results.

This view is entirely in consonance with the results of investigations concerning the manner in which other toxic effects of

alcoholism are produced, and it also accords with our knowledge of the effects of some other chronic poisonings. There are, for instance, excellent reasons for the belief that many of the cerebral and other nervous symptoms in lead poisoning are not due directly to lead itself, but to nutritive disturbances set in motion by the lead. In the cases herein described it is quite evident that there was a marked disturbance of the alimentary tract; the disturbance was not, however, confined to that tract. Cases 4, 5, and 6 all showed easily recognizable enlargement and some tenderness of the liver; and all had marked urobilinuria. All the others examined likewise had some urobilinuria. In the three cases just mentioned, therefore, and perhaps in others, there was disorder of the liver as well as alimentary tract disturbance.

ON HYPERTROPHY AND DEGENERATION OF THE MEIBOMIAN GLANDS.

I. SUBSEQUENT HISTORY OF THE CASE OF ADENOMA OF THE MEIBOMIAN GLANDS, REPORTED AT THE MEETING OF THIS SOCIETY IN 1901.

BY HERMAN KNAPP M.D.,
NEW YORK CITY.

Two years ago I reported the condition of a patient, 50 years old, whose right upper lid had been the seat of degeneration of the meibomian glands, of which I had, several times previously, removed the most prominent portions. The macroscopic appearance suggested the nature to be a hypertrophy of the meibomian glands, which was substantiated by the microscopic examination. The case, with the addition of six others — all that I could find in literature — is described in the Transactions of the American Ophthalmological Society, Vol. IX, p. 328, supplemented by

II. AN UNPUBLISHED CASE, IN THE CARE OF ONE OF THE ASSISTANT SURGEONS OF THE NEW YORK OPHTHALMIC AND AURAL INSTITUTE, DR. JACKSON M. MILLS.

This case, when I saw it first, had been diagnosticated by Dr. Mills as a sarcoma of the upper lid, but even macroscop-

ically the glandular structure of the growth could be distinctly recognized on the conjunctival surface. It looked exactly as the tumor in my own case, only it was more advanced and there was swelling of the preauricular glands, denoting malignity. Dr. Mills removed the whole upper lid, sparing the eyeball. A relapse followed in the course of several months. Exenteration was then performed, which also was followed by a relapse extending to the adjacent parts of the face, while not only the preauricular but also the submaxillary and cervical glands were greatly swollen. The patient was then operated on by a surgeon of the Roosevelt Hospital. I have no record of the further course of the disease, which, without doubt, ended fatally.

The growth of the pseudoplasm in my patient, Mrs. Mealia, had apparently been arrested by the operation which I had made some months before I reported it before this Society, but it was only a respite. On June 10, 1902, I removed two-thirds of the upper lid, and stitched the edge of the lid to the free edge of the lower lid, in order to prevent the cornea from sloughing. This seemed to enclose all diseased parts.

The growth reappeared, however, and invaded the outer third of the lid. No glands were swollen. The growth extended not only to the remnant of the upper lid, but to the adjacent part of the lower lid, where small glandular tumors appeared on the conjunctival surface. There was no swelling of the adjacent lymph glands.

November 22, 1901, I made an exenteration of the orbit, removing the eyeball and the whole contents of the orbit, leaving only the nasal two-thirds of the lower lid, which showed no sign of disease. In the upper outer corner of the orbit another tumor was found, evidently the *lachrymal gland*. It was also removed, so that in the whole upper and middle portions the periorbita was removed, together with the pseudoplasms. The orbital walls were smoothed and divested of all soft parts. There was no connection with the orbital fissures, but in removing the posterior part of the soft tissue considerable hemorrhage

occurred at the tip, pulsating, but dark in color, which seemed to originate in the ophthalmic vein, with pulsation transmitted to it by the internal carotid in the cavernous sinus. It was stopped by tamponing, without much loss of blood. A small part, 6 mm., was removed from the border of the lower lid.

December 6, 1901. Patient discharged.

There was no sign of disease until she returned, February 5, 1903, when a globular tumor of one inch in diameter had appeared at the upper edge of the orbit. It was removed with knife and scissors in the healthy tissue. Galvano-cautery was applied to the surface. Healing smooth. Discharged February 12, 1903.

February 20, 1903. Patient in good condition.

At the beginning of May, 1903, I wrote her to let me see her again. She came and I found her in good health; no relapse of the tumor. The orbit was cutisized; the nasal two-thirds of the lower lid, which had been preserved, were healthy, forming a little pouch between the conjunctiva and the cutisized surface of the lower lid. There is no secretion, no pain, no swelling of lymph nodes. Apparent recovery. Will it last? I am afraid not.

III. ANOTHER CASE OF ADENO-SARCOMA OF THE MEIBOMIAN GLANDS.

Rose Wollstein, 3½ years old, was taken to my office in May, 1902, for a tumor in the upper lid of the right eye. It had been growing for about a year, steadily, without pain or inflammation. There was complete ptosis of that eye; the lid hung inert over the entire eye. A hard oblong swelling was felt in the lower half. On eversion of the lid a tumor presented itself with smooth conjunctival covering, most pronounced at the upper border of the tarsus, occupying the whole tarsus, as if it were a thickening of it. In the middle, between the lateral ends, there was a wedge-shaped defect, where a piece had been exsected for microscopic examination of its nature. The child had been

seen by several physicians; the last before me was Dr. Grüning, who was in possession of the result of a microscopic examination, which he was kind enough to send me. The microscopic diagnosis was "sarcoma," and the specimen which I received had the structure of the small-celled variety of that pseudoplasm.

There is a very scant literature on the sarcoma of the eyelids. In a few of the text-books which I consulted, I found only a short mention in Fuchs's and de Schweinitz's treatises. Fuchs says: "These rare tumors mostly originate in the tarsus, and, when large, may require an extirpation clear in the healthy surroundings." De Schweinitz states that Veasey and Wilmer have compiled fifty cases in literature. Veasey's paper is the supplement of Wilmer's. In need of information I looked both papers up and was disappointed. They are chiefly bibliographies of the titles, and when I looked the original publications up in different journals I was disappointed again; most of them recorded only one original case and referred to the titles of others. There were but very few cases that had been observed longer than a few weeks after the operation. Dr. Grüning reported such a case in this Society and published it in its Transactions, but, as he told me, he also had lost track of the patient soon after the operation. Traumatic sarcoma of the lids is also rare, yet of that variety I have three personal observations. They have a rapid course and are fatal in a number of months.

I told the parents that this tumor should be removed so far in the sound tissue that the child probably would not be able to raise that eyelid. They told me they would not object on account of that, but Dr. Grüning wanted to remove the lid entirely, and also the eye and everything in the socket of the eye. I was surprised, but instantly replied: "That would be the safest and, therefore, the best operation." They wished me to take charge of the child. I told them I could not do that. They insisted. I asked them to go to Dr. Grüning and tell him that I was entirely of his opinion, and if I had to do the operation it

was under the condition that I was allowed to go as far as I thought it was necessary to secure the child's life, even to take the eye and its surroundings out. They went; came back, and told me Dr. Grüning had spoken very kindly to them, saying he could imagine their feelings, and that arrangement was all right. The next day, when they brought the child to the hospital, they said I could operate as I thought best, but they could not allow me to take the eye out.

I was discontented, but I saw there was no other choice, and *operated* on the child under ether anæsthesia, October 6, 1902. I first enlarged the outer palpebral commissure as far as the temporal limit, in order to have the pseudoplasm well in view; then I enclosed it in a large lid clamp, turned it inside out, circumcised it, first above its upper limit, then laterally, and at last at the ciliary border. The tumor had a sharp and dense boundary, a capsule, all around, not so well pronounced at the ciliary border as on the other sides. There was no bleeding of any account.

After-treatment. There was no reaction, but, November 4th, eleven days after the operation, I found the lower lid indrawn and united to the outer edge of the wound through which the tumor was removed. I severed this connection and stitched the end of the lower lid to its proper place on the upper lid, from which it had been detached at the beginning of the operation. It healed by primary union.

Later on there was a small granulation at the place where the lower lid had been attached to the outer edge of the wound in the conjunctiva.

There was no further trouble in the healing. The wound felt as a little cord through the lid, but a few days ago, when I examined the patient, May 9, 1903, I found the lid without a blemish. The ptosis continued, the lid was thin, no hardness or swelling could be felt, and the wound was united by a tendon-like filiform scar. No glandular swelling.

I am very anxious to watch that case. The examination of this tumor showed it to be a flattened ellipsis. When hardened,

it showed on a longitudinal section, parallel to the plane of the tarsus, a uniform granular surface, surrounded by an unbroken capsule, even on the lower, ciliary, margin. The mass of the tumor consisted of small cells with large oval nuclei and conspicuous nucleoli, with scant intercellular substance, *i. e.*, sarcoma structure. On examining different sections in all their parts it was evident that the sarcoma cells in many places were only infiltrated into glandular structure; the excretory duct, the acini, and their fatty contents were plainly visible. In many places a large duct with smaller ones surrounded on both sides by acini, many of which, being full of sarcoma cells staining well with hematoxylin, were seen among others where the normal acini were still preserved. Most of them, however, were greatly enlarged and homogeneously filled with sarcoma cells. The tumor, therefore, was an *adeno-sarcoma.*

The *tumor* of the former patient (Mrs. Mealia), who had several relapses, and as many operations, showed the same structure (adeno-sarcoma), with many round clusters of *sarcoma and epithelial* cells, showing a more advanced stage of degeneration, viz., *adeno-sarcoma* and *adeno-carcinoma,* both originating in the meibomian glands.

In looking over the collection at the New York Ophthalmic and Aural Institute I found another similar tumor located in the region of the lachrymal gland. It had been removed by Dr. Arnold Knapp, after Krönlein's method, on July 22, 1902. It had encroached upon the bony walls of the orbit. A relapse was operated on by exenteration of the orbit November 21, 1902.

On December 1, 1902, it is noted: Tumor again growing in the depths of the orbit, discharging some purulent liquid.

February 20, 1903 (last note): Patient feels well; no pain; slight discharge. Tumor growing in the depths of the orbit.

I have microscopic specimens, brought with me, which I shall be glad to demonstrate to the gentlemen who take an interest in them, with the specimens of the two other cases. The latter case is an *adeno-carcinoma,* with alveolar structure, yet the glandular structure is still visible.

We have here, in three cases, presented three stages of glandular degeneration into malignant tumors. The primary stage, the *simple glandular hypertrophy*, is probably not so harmless as it is believed. The prognosis in the others is so much worse as the degeneration is advanced.

After-treatment: Removal should be advised as soon as hypertrophy is manifest.

The *prognosis* is always grave, though I would not declare it hopeless in every case. To obtain a more reliable judgment on the prognosis more well-observed and long-enough-followed cases are needed.

DISCUSSION.

DR. MILLIKIN. — I am sure we all feel very much indebted to Dr. Knapp for the report of these cases. There is just one point to which I desire to call attention, in the method of treatment, which it is worth while to consider, not particularly in these cases, but in the treatment of sarcoma. I have had under my care for over two years an old lady of 74 with sarcoma of the choroid, going through the classical stages of treatment up to enucleation, with new developments in the orbit until there was a protrusion the size of the fist. I suggested that the case be sent to the hospital and the X-rays used. This was done by Dr. Corlett, and for a period of three months the treatment was continued with the remarkable result that the swelling gradually subsided until it had disappeared entirely within the orbit. The health of the patient improved also and she went home late in the fall, and, so far as I have heard, there have been no new developments since. The results were so satisfactory that even if nothing more than the comfort of the patient be considered the treatment is worth trying.

DR. WILMER. — I have had occasion to follow the case I reported six years ago to this Society, and I may say that there was no return of the trouble for at least three years. Recently a letter which I had sent the patient was returned to me and so I have lost sight of the case.

DR. KNAPP. — Did Dr. Wilmer see this case himself during those first three years?

DR. WILMER. — No, not since the operation. It was seen by some one in Detroit and a report sent to me.

WHY NOT EMPLOY INTRACAPSULAR IRRIGATION IN CATARACT OPERATIONS?

By H. O. REIK, M.D.,

Assistant in Ophthalmology and Otology in the Johns Hopkins University, Baltimore, Md.

Intraocular irrigation in cataract operations is not a new procedure, but so little has been written about it in recent years and so few and incomplete are the references to it in the recognized text-books that in daring to speak of the matter here one feels almost as much trepidation as he would in introducing an absolutely new and untried modification of this important operation. Although a careful review of the literature fails to reveal any substantial criticism of the procedure or any definite proof that it is a particularly serious or dangerous proceeding to employ, it would seem that there must be some well founded and generally accepted objection to its use to have brought about such a unanimous verdict against it as we find in the writings of our authorities, or, some excellent reason to account for the cold disregard which has been accorded to it by the profession in general. It is with the hope of drawing out whatever adverse criticism we may justly make upon this measure and of securing the record of whatever reasons may exist for opposition to it that I have had the temerity to raise the question, rather than with the idea of adding anything particularly new to what is known in its favor; and in taking the stand of an enthusiastic advocate I do so primarily to present a basis for antagonistic discussion, and only secondarily because I am inclined to believe in its great value. I wish to make it perfectly clear in the beginning that I am not advocating any great alteration in the classical cataract operation of today; I am really seeking information. If irrigation is a useful and helpful adjunct to our present method of operating; if it improves the chances of securing a successful result; if it diminishes the probabilities of con-

current iritis, iridocyclitis and keratitis; if it lessens the number of secondary capsular cataracts, and consequently the number of discission operations; if it only maintains our present high average of successes, but enables us to secure such success in a shorter period of time than when we do not irrigate — then, by all means, let us acknowledge these facts and indorse the measure as a legitimate proceeding and properly a part of the cataract operation for those who choose to employ it. On the other hand, if it accomplishes none of these things; if it neither facilitates a satisfactory outcome, decreases the inflammatory sequelæ, nor reduces the number of secondary operations; or if it adds materially to the operative risks and dangers — then let us, having determined those facts, plainly state our reasons for condemning the procedure. So far as I can learn that sort of consideration has not been given to this question. In such literature as I have discovered bearing upon this subject another curious fact that also commands attention is this: that practically all of those who have employed irrigation in any number of cases, and have published their results, indorse the plan most enthusiastically, while all other writers on cataract operations either entirely ignore this measure, or condemn it with a few words and without giving any reasons for so doing; some of these latter admit that they have not tried it and others show more or less plainly that they did not give it a fair trial, that is, they used inefficient apparatus or, perhaps through fear, failed to use their apparatus properly.

While St. Yves is accredited with being the first to employ irrigation of the anterior chamber for the removal of inflammatory exudates, and Guerin, Sohmer, and others operating in the latter half of the eighteenth century, endeavored to promote its use for the extraction of cortical remnants, it was not until 1884 that the medical world became aware of any serious effort to place this proceeding upon a satisfactory scientific footing. In that year, William A. McKeown read his first paper on "The Treatment of Immature Cataracts by Intraocular Injection and Irrigation," before the Ophthalmological Section of the British

Medical Association. At that time, if not still, McKeown laid more stress upon the value of his method of injecting fluid within the lens capsule to hasten maturity of cataracts, or to facilitate detachment of the cortex from the capsule, than upon intracapsular irrigation to remove cortical remnants after the extraction of the nucleus by the ordinary means. With that part of his work I do not propose to deal at present. It would appear to be the most hazardous portion of his operation, and so far as I am aware no one but its author has employed it, and the success of irrigation without previous injection seems to render the latter an unnecessary procedure.

Judging from the discussion of McKeown's paper and the dearth of British literature upon the subject it would appear that his home confrères never followed his suggestions to any marked extent. On the Continent, however, his message was accorded a hearty reception and the method adopted by the French operators particularly. A series of very instructive and interesting papers were published in the next five years by Panas, De Wecker, Grand-Clement, Chibret, Drausart, Terson, Wicherkiewicz, and Neve. In this country the most prominent advocate of the method has been our esteemed colleague Dr. Lippincott, who in 1891 presented to this Society a report of one hundred cases in which he had employed irrigation as a routine measure.

Interesting as it would be to discuss all the different forms of apparatus and the variety of irrigating fluids that have been employed by different operators, we must avoid that now and let it suffice, for the present, to say that experience has shown that antiseptic solutions are not only unnecessary, but prejudicial, and that normal salt solution, which approaches most nearly the natural contents of the anterior chamber, is the best irrigating fluid; while, as to the apparatus, McKeown's tips connected by rubber tubing with a glass irrigating bottle, so that the flow is obtained by gravity and regulated at the junction of the tubing with the tip by the fingers of the operator, are the most simple and generally useful form.

Before entering upon a discussion of the advantages and disadvantages of intraocular irrigation it would certainly be advisable to consider what we mean by that term and to set forth very clearly the method of procedure that we desire discussed. Even a very cursory investigation will disclose the fact that the term "irrigation," as used in connection with cataract operations, has been very much abused. Ask a number of your friends whether they have ever employed irrigation of the anterior chamber for the removal of the cortical substance remaining after extraction of the lens nucleus. Of those who reply in the affirmative, one will tell you that he has done so with an ordinary pipette, or medicine dropper; another, that he used the small pipette attached to a large rubber hand bulb capable of holding perhaps 50 cc. of fluid; and a third, that he employed the irrigation bottle, with either the simple gravity tube or the pump arrangement, and the glass pipette for a nozzle, but that he never dared introduce the nozzle deep into the anterior chamber, contenting himself with playing a stream upon the sclerotic margin of the wound and hoping that the resulting depression would permit sufficient ingress of water to wash out some of the cortex. Now it is questionable whether any of these operators has really irrigated the anterior chamber, certainly they have not irrigated the posterior chamber. If irrigation means anything it means thoroughly flushing with a quantity of fluid which, in proportion to the size of the chamber to be irrigated, is greatly in excess of what could possibly be introduced by the means described. Certainly the injection of a few drops of fluid with the small pipette does not constitute irrigation in the sense in which we generally use that word. Nor has it ever been claimed by any one that the great benefits attributed to intraocular irrigation could be obtained by such measures, and a protest might well be entered that it is unfair to condemn the operation of irrigation upon the unsuccessful and unsatisfactory results that must follow such inefficient performances. A few attempts in the course of cataract operations, or a few experiments upon animals, will convince anyone of the

utter futility of trying to cleanse the anterior chamber and intracapsular spaces of cortex by these injections. In fact, even with the proper apparatus it often requires a large quantity of fluid, sometimes as much as 200 cc., and a great deal of force to dislodge the sticky remnants, and I have seen some particles that could only be removed by bringing the nozzle tip directly in contact with them. I surmise that it is just these weak attempts or the lack of proper apparatus that has led to discontent with this measure, while the theoretical objections to it have prevented many from trying it at all.

I can perhaps best explain my own idea of what constitutes proper irrigation in cataract operations by describing the apparatus and the method that I personally employ. The McKeown tips seem to me to be the most satisfactory, yet it is perfectly possible to do good work with the ordinary medicine dropper used as a nozzle, if it be slightly modified, that is, if the tip be given a curve to make it easier of introduction into the eye without touching the brow and the point be flattened so as to produce a broad, thin stream. Glass tubes are, however, so easily broken in the course of sterilization that they may present an unobserved rough edge and are therefore not equal to the metal tips. A Florence flask that has an outlet at the bottom, or, better still, a graduated bottle such as is used for intravenous salt injections, is the best form of container for the irrigating fluid and the nozzle is connected with this by several feet of soft red or black rubber tubing; no intervening pump or syringe is necessary, for by elevating the reservoir from twelve to eighteen inches above the head of the patient all the force necessary to be communicated to the flowing liquid will be secured by gravity. A clamp should be placed on some part of the rubber tubing to prevent escape of the solution until the surgeon desires it, but after once opening this the control of the flow rests with the operator, whose fingers compress the tubing over the flange at the proximal end of the nozzle. By doing away with the pump or syringe and utilizing the power of gravity we are enabled to do without an assistant to manipulate

the apparatus. The reservoir may be supported by an upright retort holder, standing near or attached to the bed, or, the nurse or assistant may hold it at the proper height, but *the operator's hand and brain should alone control the irrigation, sharing the responsibility with no one.*

The preparation of patient and surgeon for the operation differs in no respect from the well-recognized rules in vogue today by all who practice aseptic surgery. The instruments, including the nozzle tips, are carefully sterilized in accordance with the custom of the surgeon, and the irrigation reservoir with the rubber tubing and the proximal end of the nozzle (if McKeown's be used) are boiled together. The irrigating fluid, preferably a normal salt solution, is boiled in a separate Florence flask and allowed to cool down to about 37° C. before transferring to the reservoir, a proceeding which is to be attended to by the nurse just before the surgeon begins to operate and when everything else is in readiness. The operation is performed in the usual way according to the predilections of the individual, up to and including expulsion of the nucleus. It matters not whether the simple or combined extraction be performed; irrigation is applicable to either, but it would seem less difficult to secure complete evacuation of all cortical substance where an iridectomy is done. Now, instead of stroking the cornea or using the scoop, a nozzle tip is fitted to the apparatus and the solution allowed to flow for a moment to determine whether everything is working properly and to displace from the tubing that fluid which has become cooled. Letting the solution flow but gently at first it is well to allow it to run over the eyeball for a few seconds to remove any particles of cortex or blood that may be present and to accustom the patient to the sensation, or at least to ascertain how he is likely to behave under the treatment. While the solution flows gently, the tip is introduced between the lips of the wound, and, gradually increasing the force of the flow, is advanced well into the anterior chamber and moved about so that the stream is made to penetrate every hiding place in front of and behind the iris and within the torn capsule. With a quiet patient the point

may be safely conducted behind the iris in the deepest part of the posterior chamber.

Good illumination of the cornea during this process is desirable, and if sufficient light cannot be obtained from the window an electric headlight may be worn by the operator, or some form of portable light can be arranged to illuminate the field of operation. Irrigation should be continued as long as any particles of cortex or hemorrhage may be seen within the eye, and the globe is then thoroughly washed as the tube is withdrawn. The operation is then complete and dressings are applied in the usual way.

It may very properly be asked at once, why should we modify the present classical cataract operation in any way; is it not about as simple and safe as it can be made, and are not our results very satisfactory? It is true that as regards ease and simplicity of operating the present methods can hardly be improved upon, but I think it can be shown that the suggested modification does not lessen the safety of the cataract operation and that it does procure more satisfactory results. Leaving out of consideration, for the moment, the possibilities it affords of operating upon immature cataracts, with all that means in the saving of time, expense, and suffering for the patient who is waiting for a cataract to ripen, and confining our attention to mature senile cataracts, who has not been disappointed to find upon post-operative inspection after a perfectly smooth operation, where all the cortex seemed to have been removed by the aid of spatula or scoop, that a mass of cloudy, cortical substance partially or completely occluded the pupillary area? The disappointment is not only to the surgeon, who knows that as a rule absorption of such masses will occur in time, but the patient, who has been led to expect immediate improvement in vision, finds it hard to believe during the next few weeks that his sight will ever be restored. Unfortunately, too, these masses do sometimes become organized and give both surgeon and patient an endless amount of trouble. Nor is the mere presence of cortex, acting as a mechanical obstruction to the visual axis, the only obstacle to a good result. It will be generally admitted that such cortical masses, through their action as a for-

eign body, tend to produce inflammation of the iris or ciliary body and to excite an active proliferation of the cells lining the posterior capsule, with the consequent production of secondary cataracts. In this connection Dr. Randolph's excellent thesis on the regeneration of the lens is worthy of study.

It will be remembered that he found regeneration of the lens always more rapid and complete when iritis followed the primary extraction and that he believed the factors which tended to the formation of a new lens to be " the hypertrophy of the lens fibres which had been left after the operation and the continued development of the cells of the nuclear zone."

But aside from the disadvantage of a more or less prolonged period of absorption, of the consequent disappointment and delay, of the necessity of dosing the patient with drugs calculated to promote absorption, it should be sufficient argument for instituting some change, to say that we all *acknowledge* the necessity therefore in our *strenuous efforts to get rid of this cortical matter;* and, furthermore, it may be said that in following our present habit of leaving this substance to be absorbed by nature we instance the *only surgical procedure that is knowingly and regularly abandoned in an incomplete stage.*

What are the advantages of intracapsular irrigation? It is claimed by McKeown and others that it will remove every particle of the lens from its capsule at the time of operation; that it completes the toilet of the wound as it can be accomplished in no other way; that it reëstablishes the anterior chamber and causes the iris to resume its proper position, even where a tendency to prolapse has shown itself in the earlier part of the operation; that there are fewer cases of iritis or irido-cyclitis after its use than after operations in which it has not been employed; and that it greatly diminishes the number of cases calling for discission of secondary capsular cataracts. As against this one may array as possible disadvantages, the lengthening of an operation upon delicate structures; the danger of introducing another instrument into the eye; the risk of losing vitreous humor; and the doubt as to whether ultimate results will be improved by its use.

Concerning the possibilities of the complete removal of cortex, McKeown's graphic illustrations* will serve to demonstrate why the ordinary measures employed for this purpose fail and how irrigation succeeds. It is a simple mechanical proposition met and overcome by the simplest and safest mechanical means. When the cortical masses are caught and held at the equator by the inverted elastic margins of the torn anterior capsule, stroking of the cornea serves to imprison them the closer and cannot dislodge anything more than what happens to be free in the anterior chamber, whereas, an active stream of water can be made to permeate every corner and to flow in and out behind the curled up capsule, washing out all loose fragments before it. If our object is to remove the entire cataractous lens and to leave nature the task only of healing the corneal wound, this measure accomplishes it, for I take it there can scarcely be any doubt that it performs a satisfactory toilet of the wound. The promptness with which the iris retracts is one of the prettiest features of the operation and continuance of the irrigation never causes any tendency to prolapse. Operation upon the capsule for secondary cataract is required in only about 10 per cent. of the cases in which irrigation has been employed. As to the frequency of iritis or cyclitis, it would be manifestly impossible to give any conclusive statistics on that point, since the opportunities for differences of personal equation are too great.

The duration of a cataract operation is hardly worth considering. While it is desirable that no operation should be continued a moment longer than is actually necessary to secure a good result, it is equally plain that no sacrifice should be made to undue haste and that the shortening of time at the expense of leaving the work half done is a costly gain. As for the danger of introducing an extra instrument into the eye, in what respect is it more dangerous to introduce an irrigating nozzle than a scoop or a cystotome? If all the instruments employed be absolutely sterile it makes little difference whether you use four or three.

In a very excellent monograph on the Treatment of Immature Cataracts, published in 1898, McKeown has given his rea-

*McKeown's "Unripe Cataracts," Plate 1, figs. 4 and 5.

sons for each of the above assertions and his answers to each of the objections. He gives us the detailed reports of one hundred and forty-six cases in which irrigation was performed, with the immediate complete removal of all cortex in 123 and a slight amount left in the other 23, in the majority of which, for one reason or another, the irrigation could not be continued as long as he wished. In this series of 146 cases, representing all kinds of cataracts, from congenital posterior polar to immature senile, four eyes were lost; one by sepsis, two by uveitis, and one by prolapse of the iris, but neither of the losses could be clearly attributed to the irrigation. This is a very good showing, especially when considered in connection with the evidence that in all the other cases good visual results were obtained and later section of the capsule was performed, or noted as necessary, in but fourteen.

Lippincott in his report of 100 cases had but three losses, two by panophthalmitis and one by occlusion of the pupil, if the latter may be called a loss, very good visual results in the other cases, and only eleven secondary operations.

In the face of such publications as are coming from India, where one surgeon operates on as many as fifty-three cataracts in one day, and another on forty-four on each of two successive days, an American ophthalmologist, and especially one of the younger set, feels a delicacy about quoting figures from his own practice. I think it is only fair, however, that I should be expected to append my own experience with this operation, however small it may have been. I have now used irrigation in twenty cases and with the most gratifying results. These may be briefly stated as follows: No losses; complete removal of the cortex in eighteen and some remnants left in two; but two instances of any marked degree of iritis; good vision in every case, and so far but two have required operations upon the capsule, though some of my cases are very recent.

To judge any operation upon a small number of cases would be very unwise, but if we make a composite study of all the recorded operations of this kind by the various operators, I think

we shall have to admit that the results are better than can be shown for the same operations done without irrigation. Time does not permit me to go into any more elaborate argument, and as my experience with the operation and satisfaction with its results are very thoroughly in accord with the opinions of Dr. McKeown, I could not do better than to present for your consideration now the conclusions that he gave, in so far as they refer to the more limited class of cases we have been speaking of. They are:

(1) That the introduction within the eye of the sterilized saline solution is harmless.

(2) That the removal of cortex is a mechanical process and regulated by ordinary physical laws.

(3) That, from the anatomical structure of the eye, and the conditions existing during the operation, irrigation is more efficient in removing cortex than any other method.

(4) That just as irrigation removes cortex, so it removes blood and bubbles of air. It also shows the condition of the capsule, gives tone to and replaces the iris and is effectual in making the toilet of the wound.

(5) That very free irrigation by the nozzles may be practiced without fear.

(6) That irrigation does not tend to cause prolapse of the vitreous.

(7) That the secondary operations form a small percentage.

DISCUSSION.

Dr. Lippincott. — The views expressed with such commendable reserve by Dr. Reik, and the conclusions quoted from McKeown, accord in all essential points with those which I advocated in three papers read before this Society in 1889, 1890, and 1891, and another in which I described a modification of my anterior chamber syringe, which was published in the Ophthalmic Record in 1895.

For nearly fifteen years I have removed cortical débris by syringing in about 90 per cent. of my cases of cataract extraction, that is, in all except those in which there was either threat-

ened or actual loss of vitreous, or in which the lens emerged in its capsule or in its entirety. As a result of my experience I am free to say that even if there were no special ultimate advantages attending irrigation — granting of course that there were no disadvantages — I should continue this method, because it seems to me more elegant, more satisfying to the artistic conscience than the method by stroking the cornea; just as flushing a street paved with Belgian block seems a more perfect way of cleansing it than scraping it with shovel and hoe. In point of fact, the principle of irrigation is utilized by the most strenuous opponent of the procedure every time he pauses to let a quantity of aqueous accumulate for the purpose of permitting it to gush out, carrying cortical matter with it.

Irrigation, I am convinced, has no appreciable disadvantages. The only objection I ever heard against it was that it necessitates the introduction of an additional instrument into the eye. Some surgeons go farther and object to the use of the cystitome, preferring to make cystotomy with the cataract knife as it sweeps across the anterior chamber; and the Christian scientists go farther still, and object even to the knife. In point of fact, the "additional instrument" argument can hardly be considered as other than academic. I cannot conceive how any sane surgeon could permit himself to be handicapped by such *a priori* considerations.

But the use of an irrigating apparatus is attended, at least in my judgment, by incontestable advantages. It removes not only cortical remains, but blood, and air bubbles promptly, efficiently, and without violence. In this way, in all probability, it lessens the frequency and the thickness of capsular opacities, thus making necessary a smaller number of secondary operations to improve vision. It gently and thoroughly replaces the iris if it protrudes, and it probably, as McKeown claims, gives tone to the iris tissue and so may tend to prevent subsequent prolapse. Furthermore, it perfectly frees the lips of the wound from cortical material and shreds of capsule, and thus permits the accurate coaptation necessary to perfect healing.

It also in those cases in which the cornea remains depressed after the operation like an umbrella turned inside out in the wind, re-establishes the corneal dome, and in this manner mechanically places the wound lips in accurate contact.

I am aware that the value of statistics as bearing on the solution of therapeutical problems in general is limited. In comparing different methods pursued by different operators in the

extraction of cataract, so much depends on a discriminating analysis of every case, and most of us are averse to the labor involved in such an analysis. Then the elements necessary to a correct conclusion — equality of skill, similarity in methods outside of the particular procedure under discussion, and an equal distribution of favorable and unfavorable cases — are never present. Still, statistics have a certain value, and so I have made as extensive an examination of my records as time permitted since Dr. Reik kindly requested me to speak on this topic.

I have taken for analysis the last hundred cases of idiopathic cataract operated upon with irrigation by my partner, Dr. Joseph L. Duncan, and myself, or more strictly speaking the last hundred operated upon a sufficient time to make a report possible.

I have excluded from consideration twenty-five cases operated upon during the same period, of which 17 were traumatic. 2 were due to iridocyclitis with complete adhesion of the iris, 2 were glaucomatous, being operated upon to relieve pain and tension, 3 were complicated with rather dense corneal opacities, and 1 was a case of cataract without light perception, operation being done for purely cosmetic purposes.

The 100 cases are not "selected" in the ordinary acceptation of that term. It was evident in a certain number of them before operation that good visual acuity could not be obtained.

Of the 100 cases I have reports of the visual results in 90 cases. The remaining 10 did not return for glasses, being fitted presumably in their own localities.

Of the 90 cases there was corrected vision of

20/XX	in 34 cases,
20/XXX	in 26 cases,
20/XL	in 12 cases,
20/LX	in 6 cases,
20/LXXX	in 5 cases,
20/CC	in 3 cases,
7/CC	in 1 case,
2/CC	in 1 case,
Light perception (occluded pupil)	in 1 case,
Total loss	in 1 case.

There was therefore good reading vision, 20/XL or better, in 72 cases. This number would of course be greater if we had a report from the 10 cases not heard from.

Discission was done in 14 cases. There was no case of infection.

Seeking for the explanation of the more unfavorable or bad results, I find that of the 6 cases with V'n = 20/LX

2 were complicated with high myopia and post. staph.
1 showed opaque capsule with small post-synechiæ.
1 with opaque capsule, without synechiæ.
2 unaccounted for.

Of the 5 cases with V'n = 20/LXXX

In 1 there was high myopia and post.-staph.
In 1 large physiological excavation. (Fellow eye removed for injury 8 months previously.)
1 was a curious case of black cataract in a myopic albino in feeble health. Media clear, disc pale. (Other eye lost in childhood from a shooting cracker wound.)
1 was that of a physically and mentally decrepit old man. No record of ophthal. examination.
1 was a case of opaque capsule.

Of the three cases with vision = 20/CC

1 was the old man just mentioned.
1 was a case of central scotoma without macular changes that could be made out.
1 was a case of high myopia with marked choroidal changes.

The case with vision = 7/CC was one of very dark cataract, which had been treated for a long time previous to the operation for vitreous opacities. (Other eye sightless from detachment of the retina for 20 years.)

The case with vision = 2/CC was one with high myopia, with large post-staph. and extensive choroidal changes.

The case of light perception was due to post-operative occlusion of the pupil from severe iritis. The man had coloboma iridis downwards on both sides. Iridectomy not done. This is the first case of inflammatory occlusion of the pupil I have seen in many years.

The case of total loss was a case of intraocular hemorrhage, the first I have had the misfortune to encounter.

Like Dr. Reik I use normal salt solution as the irrigation fluid. I have, however, used a weak solution of boric acid, gr. ii ad ℥i with equally good results. My chief reason for preferring normal salt solution is that the latter is probably better to fill up a globe which has collapsed from extensive loss of vitreous, as has been done by Dr. Andrews and by Dr. Knapp,

and as I have done myself; and the solution is thus always ready for such an emergency.

As to the apparatus to be employed, I agree with Dr. Reik that the force of the stream ought to be regulated by the height of the column of fluid, and not by finger pressure, which is necessarily impossible to estimate. I think also that an instrument such as mine, which is held like a penholder, is more under control than any other. An objection to the McKeown instrument appears to me to be that the point where the tube is compressed for the purpose of stopping the flow is too far from the tip. To perfectly control the movements of the instrument the finger ought to be as near the tip as possible.

A point of some little importance relates to shutting off the current. If there is no shut-off there will be a backward flow towards the reservoir, if the latter is lowered before the instrument is emptied. If the eye just operated upon should be infected, infecting material could be drawn into the rubber tube by the backward flow. This would necessitate the reboiling of the whole apparatus before using it on another case, whereas if the backward flow is prevented, all that is required is to heat the tip in an alcohol flame. If care is taken to habitually empty the instrument after using it before lowering the reservoir enough to reverse the current, the shut-off need not be used at all. The backward flow constitutes one of the objections to all instruments of the dropper type.

Of course the entire instrument is boiled (along with other instruments) in an alkaline solution (borax) before beginning to operate.

DR. GRUENING. — I would like to make a few remarks upon this subject. We must certainly be grateful for any improvement in the technique of the cataract operation. The gentleman who read the paper said that it was hardly possible now to improve the technique and I do not think that irrigation is an improvement on the technique of cataract extractions. It never appealed to me and I never adopted it because I did not find it necessary; I can empty the anterior chamber without that, and that there is an extra danger in its use there is no doubt.

I simply arose to speak of another change which I think is an improvement in the technique and for which we are indebted to Professor Angelucci of Palermo. I am exceedingly glad that I became aware this year of this modification of the cataract extraction. It is an important one since it does away with the

use of the speculum and it does away with the command on the part of the operator to the patient to "look down" or "look to the right" or "to the left." In the reports of the Heidelberg Congress last year an operator of Berlin, Dr. Gutmann, said that he had visited Palermo and was surprised to see how Dr. Angelucci worked his unmanageable patients. The modification consists in this: the patient looks down and the operator seizes the conjunctiva and the superior rectus muscle with his forceps and thus holds back the upper lid at the same time, so that the patient can make no pressure on the eye and the operator has absolute control of the eye and can move it as he pleases. The operation is performed with ease — with such ease as I never experienced in my former operations. I have performed ten operations lately in this way and am delighted with the measure, and those gentlemen who saw me are equally pleased with it.

DR. BURNETT. — Incision upward?

DR. GRUENING. — Yes, upward.

DR. HOLT. — I have used irrigation for fourteen years and I cannot agree with Dr. Gruening that it is dangerous. With proper manipulation of the apparatus there is no danger to come from it. I have always used a ring syringe in preference to gravity irrigation because I believed I could control the current very much better, though perhaps my apparatus was not as good as Lippincott's. I remember discussing Dr. Lippincott's paper at the time he read it before this Society and I still think that by the use of irrigation in suitable cases one can secure better results in cataract operations.

DR. RISLEY. — I do not rise for any extended discussion of this admirable paper, but since my friend Dr. Reik extended me the courtesy of sending me a copy of it for study, with the request that I should speak upon it, I cannot refrain from congratulating him upon the careful, dispassionate, and unbiased way in which he has presented his views. I must plead guilty to the charge he has made against some operators to the effect that their method of irrigation was not the method described in the paper. Hence my own adverse criticism of the procedure, made in Dr. Reik's presence in another place, was not entirely just, certainly not as applied to the method so clearly described in the paper. I appreciate any procedure which shall prove to be safer and more efficient than those ordinarily employed for

completing the toilet of the eye in extraction of cataract. My experience has not proved so fortunate in this respect as Dr. Gruening's, for I often find it difficult to safely free the eye from remnants of cortex. I am opposed to any rude manipulation of the globe, or to the frequent introduction of instruments into the anterior chamber for the removal of adherent portions of cortex, believing that it is safer, when all is said, to allow them to remain than to run the risk of loss of vitreous through rupture of the suspensory ligament. But, having heard the claims of this paper and Dr. Lippincott's reiteration of his former claims for its efficiency and safety, I shall certainly try it in a sufficient series of cases to satisfy myself regarding the value of the procedure.

DR. ALLYN. — I wish to add just a word in regard to the method of irrigation after extraction. It has been my practice, following Dr. Lippincott, to use it as a routine measure and I have been greatly pleased with it. To cite a case in which it gave me particular pleasure, I recall one where, on making my capsulotomy, I was surprised to discover a hypermature cataract. I lacerated the capsule freely, and being always provided with my irrigation instrument, I held the tip a slight distance from the cut and let the stream flow over the wound. I then introduced the tip into the opening and easily washed the nucleus into the wound and then out without putting the instrument into the anterior chamber. I thus easily recovered my nucleus and completed the operation satisfactorily. Many times in cataract operations there is a tendency to hemorrhage which may be noticed at the first touch of the conjunctiva. The moment I have made the incision complete, I throw the stream on the eye and into the wound and prevent any coagulation of blood and thus clear the field to continue the operation.

DR. C. H. WILLIAMS. — In June, 1887, I began the use of irrigation after cataract extraction, at the Infirmary. The apparatus was quite simple. A glass tube about three inches long was blown into the side of a glass bulb of one ounce capacity, and on the other end the tube was drawn out to a diameter of a little less than two millimeters, and bent like a cystitome. The free end of the tube was made smooth in the flame, and turned so that the stream of irrigating fluid issued at right angles to the tube. Another short tube was blown into the upper part of the bulb, and to this a small rubber flexible tube was attached, the end being carried to the mouth so that the force of the irrigating

stream could be controlled by the mouth. These bulbs were sterilized, and several were prepared for each operation, in case of breakage, etc. Normal salt solution was used for the irrigating fluid, and before use the bulb and fluid were heated to the temperature of the body. It seemed to me that if the irrigation was continued too long it set up some irritation of the eye. Another unfavorable thing was the possibility of a sudden upward movement of the eye while the irrigation tube was at the lower part of the anterior chamber, and in one case an operation which up to that time had been uneventful was complicated by a prolapse of vitreous, due to such a movement.

DR. CLARK. — I wish to add my testimony in favor of irrigation. For five or six years, following Dr. Lippincott's suggestion, I have used this method with the utmost satisfaction. I think, really, the objections to it are purely theoretical. I have not used Dr. Lippincott's apparatus but the simple dropping tube, drawn down to a fine point, which serves every purpose and I think, in some ways, a better purpose, for you can introduce this well into the eye and get a stream the force of which can be varied to a considerable degree. I cannot recall a single instance in which I can attribute any ill effect to this method. As a rule, I outline a segment of the anterior capsule which I wish to remove and after cutting and washing this out I can, in many instances, irrigate away a great deal of the anterior cortical matter of the lens before extracting the nucleus.

While I am on my feet, if I may follow Dr. Gruening's initiative, I wish to speak of one more point which I consider of great value. While abroad last summer I spent some time in Dr. Snellen's clinic and had the opportunity of witnessing his method of dressing cataracts. Since then I have performed twenty-five or thirty operations and have not seen an instance in which this dressing did not serve most satisfactorily; and it is so radically different from my previous method that I think it ought to be described.

A patch of gauze is placed over the closed lid and pledgets of cotton, very small, dipped in and saturated with a one to 5,000 solution of bichloride, are placed over this, filling in the orbital fossa, and covered with a piece of rubber protective, held in place by strips of isinglass plaster. They told me in Professor Snellen's clinic that they have had but one case of prolapse in two years, and they do the simple operation.

DR. BULL. — The chair will have to remind the members that discussion must be confined to the subject of the paper.

DR. BULLER. — I may say that I have been practicing this operation, suggested by McKeown, for a number of years, and I wish to add that *I give it my most unqualified approval;* I cannot go further than that. I follow as nearly as possible the method described in his monograph. I use the instruments just as they are made for him, but I do not think you can get them in this country. Those which the reader of the paper has shown are not of the same pattern as McKeown's. For two years I have been trying to get a New York instrument maker to make them, but so far without success.

It seems to me that one of the advantages of this method over manipulation through the cornea is that it prevents any contamination of the wound by the margins of the lids. We know that it is impossible to cleanse the edges of the lids, and there is always danger from the friction movement of carrying infection to the wound. I beg of you that if you are inclined to try this method, first secure the proper instruments and then try the operation as McKeown has described it and I feel certain you will then be satisfied.

DR. ST. JOHN. — Ever since Dr. Lippincott introduced this method to our notice I have used it and at the present day I consider the irrigation apparatus an essential part of my cataract outfit. I have taken the handle off the Lippincott instrument and use simply the tip and the tubing so that I can control the flow by simple pressure of the finger. The completeness with which the anterior chamber can be freed of lens fragments, in front of or behind the iris, is very gratifying. I have frequently gone behind the iris after suspected lens fragments, of the kind that steal out a few days after the operation in the way that Dr. Reik has referred to and removed them easily by irrigation. I quite agree with Dr. Buller, and the other gentlemen, that irrigation is a very important addition to our technique, and while it is not to be used in those cases where the cataract comes out clear and leaves no cortical matter, those cases are so few that I feel that irrigation will come to be one of the fixed features of the cataract operation, and I certainly give it my unqualified approval. I have seen one or two cases where I thought a slight striate keratitis might have been produced by the irrigation, but I was not sure of it and it gave no trouble.

DR. WILMER. — I have an instrument made by Lüer of Paris which I think is better than either of those exhibited today. It has a movable, soft metal tip that can be bent or twisted at any angle, while the barrel and piston are made of glass and can be easily sterilized.

Irrigation after extraction in appropriate cases has many advantages. It restores the iris to its proper position immediately; it washes out thoroughly all the cortex, and tends to lessen the chances of secondary cataract. Normal salt solution so introduced is absolutely harmless and the procedure shortens the period required for recovery. Care should be taken to have the solution of the proper temperature, and not to use too much force in irrigating.

ORBITAL OSTEOMA OF ETHMOIDAL ORIGIN, — PERFORATION OF THE ORBITAL ROOF AND EXPOSURE OF FRONTAL LOBE — OPERATION — RECOVERY.

BY PERCY FRIDENBERG, M.D.,
NEW YORK CITY.

(*With drawings by the author.*)

The advance of surgery within the last decade and the application to the removal of orbital tumors of methods with which the names of Wagner-Krönlein, Jansen, Kuhnt, Mikulicz, Gussenbauer abroad, and Knapp, among others, in this country, are connected, have so improved the prognosis in this class of cases that the report of removal of a bony growth, with conservation of the eyeball and of perfect sight and motility, is neither remarkable nor unusual.

This is particularly true of osteomata, of which not so long ago Berlin said that operation was contraindicated for reason of disfigurement alone. The outlook for a cure is, however, disproportionately worse where we have as a complication a perforation of the cranial cavity either by extension of the tumor or by the operative procedure itself. Exposure of the brain has, in many cases, been followed by meningitis or by brain abscess, which were generally fatal.

Chas. A., aged 21, was brought to me by Dr. D. Alexander on September 21, 1902, complaining of a protrusion of the right eye. One year before, while playing football, the patient had been kicked over the right eye, and although stunned for a moment, had not been badly hurt. The vision was not affected. About four months later he began to notice a fullness of the upper lid and a swelling over the inner angle of the right eye, without pain or diminution of sight. This remained stationary until about three months before examination, when it began to increase. On examination of the right eye the following condition was found: In the region just above the inner canthus and below the orbital ridge, a smooth, round protrusion is felt, about the size of a small marble. It is quite hard, not compressible or movable, not sensitive, and gradually merges into the orbital margin above and to the outer side.

The eye protrudes and is dislocated outward and downward. Eye motions are unimpeded, pupillary reaction is normal. With correction of ametropia vision is 20/20—. There are no fundus changes discernible by ophthalmoscopic examination, although the veins on the disc are rather large and dark; there is no pulsation of the retinal vessels. The patient has suffered for many years with a purulent otorrhœa from both ears. The nasal septum shows a localized deflection to the left, amounting to a spur rather than a severe deviation. On the right the inferior turbinate is unusually large; the middle turbinate bends over and touches the septum.

Translumination of antrum and of the frontal sinus is negative and there is no pus or other discharge from the nose. There is no history of ethmoidal trouble, but patient has suffered with nasal catarrh for years and is a mouth-breather. Exploratory operation was advised, but declined, and the patient was lost sight of for some months. On March 12, 1903, he again consulted me. The local condition was very much the same as before, except that exophthalmus had increased slightly. Vision with correction was now 20/30—. Ophthalmoscopic examination showed some engorgement of the nerve head. Since two

Dr. Fridenberg's case of
Orbital Osteoma.

Skull showing location of
Osteoma

days the patient has complained of diplopia with vertical deviation of the double images. There is some headache, more pronounced on the right side, and a feeling of pressure in the brow, occasional slight dizziness, and the patient seems less alert, mentally, than he had been. On the following day the patient was admitted to the New York Eye and Ear Infirmary, and operated upon by Jansen's method. An incision was made down to the bone along the orbital ridge, just below the brow, extending from within one-half inch of the outer margin to the inner end of the brow and thence downward to the lower orbital ridge. On retracting the soft tissues a hard growth, covered with smooth white periosteum, appeared, occupying the upper and inner portion of the orbit. As it was not feasible to strip off the periosteum from this growth, as suggested by Knapp, it was attacked by chiseling, but after several taps with the mallet it was observed that the entire mass rocked with each stroke, and inserting the chisel between the bony tumor and the orbital margin, which latter appeared perfectly normal, it was found possible to pry it out in toto with a very slight effort. Exploration of the orbit showed that the growth had sprung from the os planum of the ethmoid to which it was attached by a rather broad base, approximately circular, and measuring about one and one-half cm. in diameter. The cribriform plate was broken open and no abnormal condition found, although when the tumor was first exposed, a small amount of muco-pus had welled up about its ethmoidal attachment. On exploring the roof of the orbit, an aperture was found, about the size of a 5-cent piece, in which the brain presented itself. The dura had been destroyed over this area. As no sinus disease was present, drainage through the nose was omitted and the cavity was lightly packed with iodoform gauze and the patient put to bed.

In view of the probability of cerebral complications a dubious prognosis was given, in spite of which recovery, somewhat to my surprise, was uneventful, with the exception of an attack of dizziness followed by vomiting, which came on six days after operation, when the patient got out of bed for the first time.

Dizziness persisted after he had gone back to bed, accompanied by roaring in the ears, marked headache and slight rise of temperature (100.8° F.). As a careful search of the wound failed to reveal any cause for these symptoms, examination of the ear was made, which showed that there was retention of pus in the left ear which, up to this time, had been discharging freely. With the relief of this condition the cerebral symptoms, which had been attributed to an extension of inflammation from the orbit, ceased.

The patient was discharged on March 29th, after secondary suture of the wound. At present vision is 20/20 with correction; fundus oculi is normal; there is no diplopia and motility is perfect. The cosmetic result is, as yet, unsatisfactory, as there is some thickening of the tissues just below the brow and in the region above the inner canthus. The growth, which is shown in the accompanying photograph, is the size of a large horse-chestnut, measuring 29 millimetres in its longest diameter; it is 14 mm. high at its thickest point, its free margin measuring 4 mm.; weight is 100 grains. It is continuously covered with glistening periosteum, except at its point of attachment to the ethmoid, where there is spongy bone, and at a point in the posterior margin of its upper surface where it was adherent to the orbital plate of the frontal bone which has been broken off and removed with the tumor.

Microscopical examination of decalcified sections by Dr. Geo. S. Dixon gave no evidence of malignancy. The tumor proved to be cancellous bone covered with periosteum; the internal appearances were simply those of newly formed bone.

Etiologically, the feature of traumatism is of interest, and seems to be frequent, as is shown by the cases of Schuchardt,[1] Moser,[2] and Miodowski,[3] who found a history of injury in 12 of 17 cases reported, the connecting link being probably a localized hyperplastic periostitis. In two the injury, inflicted by a cow's horn, was limited to the region of the inner angle of the eye, and a bony growth developed at this site.

[1] Deutsche Zeitschr. f. Chirurg., vol. LIV, p. 371.
[2] Beiträge z. klin. Chirurg. (v. Bruns), v. XXV, p. 2.
[3] Z. Kasnistik d. Knöchernen Orbital Tumoren, I. D., Breslau, 1900.

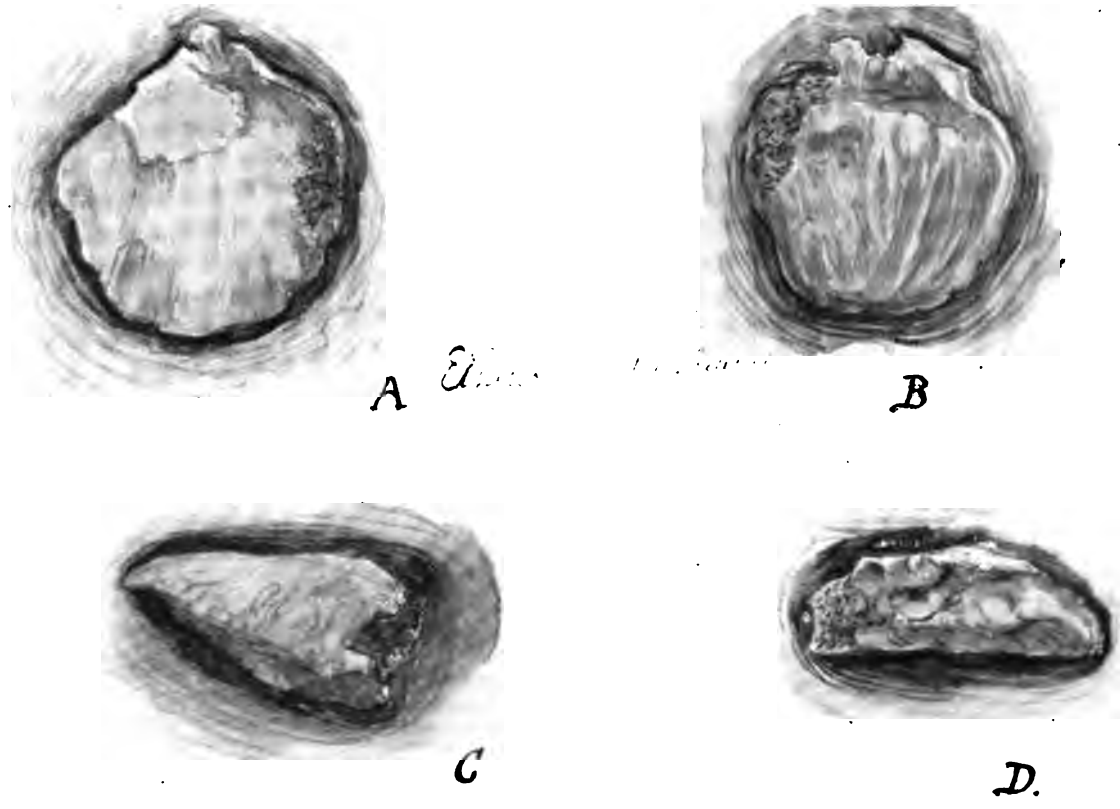

FIG. III. *A*, upper surface. *B*, lower surface. *C*, anterior. *D*, posterior.

A number of cases of distension of the ethmoidal cells have been reported, which closely simulated an orbital tumor, more particularly an osteoma at the inner angle, producing a round, hard growth in the region above the internal canthal ligament, which cannot be sharply defined. Nasal discharge and a history of ethmoidal disease, pain, and other symptoms of inflammation are not always present, and the growth may be entirely incompressible on account of either being covered by a bony plate, or by reason of tension of a fibrous wall by pus under pressure. In a number of cases of osteomata reported, optic nerve atrophy developed and in a certain proportion diplopia and limitation of motility persisted. It is interesting to note that the palpable part of these growths is often disproportionately small, while the amount of exophthalmus may give us a clue — although not an accurate one — to its size. A nodule the size of a hazelnut or a marble may often be all that can be felt of a tumor which, on removal, is found to measure several inches. They have been likened in this respect to icebergs, of which by far the greater portion is submerged.

DISEASES OF THE EYE IN THE WHITE AND THE NEGRO RACES.

BY HENRY DICKSON BRUNS, M.D.,
NEW ORLEANS, LA.

My connection with the Eye, Ear, Nose, and Throat Hospital of New Orleans began in the year 1892. As I did not assume charge of the eye department until December of that year, however, the cases available for study under the methods of case taking then instituted begin with those of 1893 and end with those of 1901 — nine years.

During these years 17,311 cases were treated, more or less accurate histories of them kept, and at the end of each year analytical tables prepared showing the diagnosis, the race, sex, age, vision, treatment, duration of treatment, and the condition on discharge. In all instances the diagnosis, race, sex, age, and the date of discharge have been entered on the history sheet, and

I have every reason to believe that these data are substantially correct. Many patients never returned after the first visit, and in many cases the treatment, its duration, and the condition on discharge have, unfortunately, been imperfectly recorded. Such histories have not been used in this inquiry.

I hope to show that from this large number of tabulated cases valuable facts may be gathered, especially in regard to the relative frequency of certain diseases of the eye among those of Caucasian and those of negro or mixed blood. So far as I know exact and comprehensive knowledge founded upon comparison of large numbers of both races is as yet lacking.

The eye of the white man and that of the negro, both in normal and pathological conditions, present many points of difference. In the black we never see deformities of the lids due to other than traumatic causes, for he is, as is well known, comparatively exempt from trachoma. The conjunctiva of the ball is usually pigmented, either slightly and irregularly or decidedly in a circle embracing the cornea, with the wider portions of the band extending outward and inward. This membrane, too, is usually pale, thin, and dry-looking; rarely injected or suffused, as in the white man. This is probably due to the little use he makes of his eyes for protracted near work and is one cause of the remarkable contrast presented by the "whites" of his eyes to his dark skin. The uniform velvety blackness of the negro iris veils many details of structure and condition that are of service in appreciating the state of this part in the white. The appearance of the fundus oculi as seen with the ophthalmoscope is very different, also, in the two races. In the black the general hue is a rosy slate color, and even in the light mulattoes it is darker than the inexperienced would expect. This causes often a decided difference in the appearance of the same disease as observed in white or black individuals. Finally refractive defects are uncommon and muscular anomalies are almost unknown, so that they cease to play any considerable part in the production of eye strain and consequent pathological conditions.

The social and economic position of the negro in the South has its due effect upon the pathology of his eye. Thus injuries

to the eye by foreign bodies are comparatively rare, because comparatively few of the race are artisans. On the other hand severe traumatism — brutal injury — of the whole globe by purposive violence or gross carelessness is common, and these conditions are usually presented to us in a wretched state owing to callous neglect or profound indifference. Tobacco and whisky amblyopia and its incipient manifestation, or an allied state, as a form of hemeralopia, is quite common; especially among the gangs of railroad and levee laborers, who, working far from bases of supply, are fed almost entirely on salt pork, corn bread, and potatoes, and spend most of their cash for bad tobacco and worse whisky.

Let us pass now to a systematic consideration of the relative freedom from or liability to disease of the various parts of the eye in the two races.

Unfortunately my statistics do not enable me to distinguish between those of virtually pure negro blood and those showing a greater or less admixture with the white — mulattoes and quadroons. This deficiency I hope to supply at some future time by figures now in process of compilation.

DISEASES AND INJURIES OF THE LIDS.

Of my total 17,311 cases, 6,290, or 36+ per cent., were "persons of color." This may be called the fixed or "normal" percentage of negroes in attendance at my clinic. Of the whole 17,311 patients, 1,540, or nearly 9 per cent., suffered from affections of the lids, and of these 610, or 39+ per cent., rather more than the normal percentage, were of negro blood. The commonest diseases of the lids are blepharitis marginalis, chalazion, and stye. They comprise 72 per cent. of all lid diseases; 68 per cent. of all among the 930 whites and 79 per cent. among the 610 blacks. But the liability of the black to these diseases is very different from that of the white. Of the 1,540 cases of lid affections, the whites with blepharitis marginalis formed 19+ per cent., the blacks only 3+ per cent.; the whites with chalazion formed only 15+ per cent., the negroes 25+ per cent.; the whites with styes made up nearly 7 per cent. of the

whole number with diseases of the lids, the blacks only 2+ per cent. Or, to put it in a more striking way, of the 930 whites with disease of the lids, 297, or nearly 32 per cent., had blepharitis marginalis; of the 610 negroes only 51, a little over 8 per cent. Of the 930 whites 234, or 25+ per cent., had chalazion; of the 610 negroes 396, or more than 64 per cent., were afflicted with these lid tumors. Of the 930 whites 102, 10+ per cent., had styes; of the 610 negroes only 38, or 6+ per cent. In other words, chalazion is the only disease of the lid to which the negro is at all liable. If the 396 cases of chalazion were to be subtracted from the total of those of negro blood presenting lid diseases (610) we should have but 214, or 18+ per cent., blacks among the then total (930+214) of lid cases, a percentage only one-half of our normal negro percentage (36+).

Stye is certainly rare in the full-blood black, and my impression is that I have never observed blepharitis (primary) except in mulattoes or those with a greater infusion of white blood. Secondary blepharitis is observed in black children with conjunctivitis, especially the phlyctenular form, to which they are very liable. In speaking of styes, it must not be forgotten that they are so well known and transient a malady it is highly probable the vast majority of cases do not go to clinics for treatment. This, owing to their characteristic indifference, their servile employments, their dread of the knife, would be especially true of negroes. The same probably holds true concerning the milder forms of conjunctivitis.

It is interesting to observe that only 33 whites and 4 blacks, out of the whole 17,311 cases (2/10 per cent. for both races), had ec- or entropion. This not only indicates the immunity of the negro to trachoma, but also the exemption of the white race in this part of our country. As I cannot recollect having seen a person of color afflicted with either ec- or entropion as a consequence of trachoma, I feel quite certain that the 4 cases recorded were of traumatic origin.

The whole number of persons attending my clinic are about equally divided as to sex. Among those with affections of the lids women are slightly more numerous than men.

DISEASES AND INJURIES OF THE LACHRYMAL APPARATUS.

Of the total 17,311 cases only 268 were instances of lachrymal disease — 1½ per cent. Seventy-five of these, or 27+ per cent., were of negro blood, a figure decidedly below the normal (36+ per cent.) for my clinic. The broad short nose and large nostrils of the negro seem, as might be expected, to favor exemption from this class of diseases. Among these thousands of cases but one of lachrymal adenitis was met with, and that in a person of negro blood. Women made up 57+ per cent. of the total number of those with lachrymal affections — a less proportion than I had anticipated.

DISEASES AND INJURIES OF THE CONJUNCTIVA.

There were 5,052 cases of disease of the conjunctiva, or 29+ per cent. of all the 17,311 cases; 2,002 (39+ per cent.), about 3 per cent. more than the normal, being of negro blood. The most common affections of the conjunctiva are catarrhal conjunctivitis, phlyctenular conjunctivitis, purulent conjunctivitis, conjunctivitis neonatorum, trachomatous conjunctivitis, and pterygium. With catarrhal conjunctivitis there were 1,088 whites, or 21+ per cent. of the 5,052 cases of conjunctival disease; of negroes there were 396, or only 7+ per cent. Of whites with phlyctenular conjunctivitis there were 438, or 8+ per cent., of the whole 5,052; of blacks 789, or more than 15 per cent. of the whole. Not quite 1½ per cent. (72) of whites out of the 5,052 had purulent conjunctivitis, while 73 blacks, or a very small fraction of a per cent. more, were so affected. Of whites 130 out of 5,052, or more than 2½ per cent., had conjunctivitis neonatorum, while only 66, or very slightly over 1 per cent., of those of negro blood were treated for this disease. Of trachomatous conjunctivitis there were 293, more than 5½ per cent., among the whites; among those of negro blood only 31 cases, or about 6/10 of 1 per cent., out of the 5,052 conjunctival cases. Finally, of the whole 5,052 there were 186 whites, more than 3½ per cent., with pterygium, and 127 blacks, or more than 2½ per cent.

Considering now the percentage of each race with a principal disease of the conjunctiva in the whole number of that race with conjunctival affections, we find 1,088 whites, or 35+ per cent., with catarrhal conjunctivitis in 3,050 with conjunctival affections, and only 396 blacks, or 19+ per cent., with the same disease in 2,002 cases of conjunctival disease; out of the 3,050 whites with conjunctival troubles 438, or only 14+ per cent., have phlyctenular conjunctivitis, against 789 blacks, or 39+ per cent. of 2,002 conjunctival cases; with purulent conjunctivitis there were 72 whites, or rather more than 2 per cent. of 3,050, and 73 blacks, or more than 3½ per cent. of 2,002; with ophthalmia neonatorum there were 130 whites, or 4+ per cent., in 3,050, and 66 blacks, or 3 per cent, in 2,002; with trachoma there were 293, or 9+ per cent., in the 3,050 whites, and only 31, or about 1½ per cent., in the 2,002 of negro blood; with pterygium there were 186, or 6+ per cent., of the 3,050 whites with conjunctival affections, and 127, or almost identically the same percentage, of the 2,002 negroes. Or, to put it a little differently, although persons of negro blood compose only about 36 per cent. of those who attend my clinic, of all those with conjunctival catarrh the blacks made up about 26 per cent., of those with phlyctenular conjunctivitis about 64 per cent., of those with purulent conjunctivitis a trifle more than 50 per cent., of those with conjunctivitis neonatorum about 33 per cent., of those with trachoma about 9½ per cent., and of those with pterygium about 40 per cent. These figures permit us to say unequivocally that phlyctenular conjunctivitis is *the* disease of the conjunctiva to which the negro is preëminently liable* and trachoma the disease from which he enjoys practical immunity. The difference between the figures 21, the percentage of whites with catarrhal conjunctivitis in the whole number of conjunctival affections (5,052), and 7, the percentage of blacks with catarrhal conjunctivitis in the same, is much reduced when we estimate the percentage of whites with catarrh of the membrane in the number of whites with conjunctival disease (35+ per cent. of 3,050), and

* See Phlyctenular Ophth. in the White and Negro Races, by the writer, in the N. O. Med. and Surg. Journ. for Aug., 1903.

the ratio for the blacks in a like way (19+ per cent. of 2,002). It is not unlikely that the apparent difference in liability between the two races is largely due to the stolidity with which the black race endures disease that does not cause disability or acute pain; conjunctival catarrh when slight is not a condition that would probably lead them to seek skilled medical attention. A degree of redness and discomfort in the eyes that would drive any white laborer to a hospital would probably be passed over by a negro with the remark that he had "cotch cole in d'eyes," and an extempore application of "jew water" or "bress milk" or some more abominable collyrium. Nevertheless these figures lend weight to the strong general impression that marked evidence of conjunctival catarrh is unusual among negroes as we observe them casually in our towns and fields. If this be so it aids in explaining their well-known immunity from trachoma. It is noteworthy too that, though the universal prevalence of gonorrhœa among them is a commonplace of our medical knowledge, they have only .036+ of purulent conjunctivitis as against .023 in the whites, and only .032+ of ophthalmia neonatorum as against .042 in the whites. These facts not only indicate a resistant condition of the conjunctiva but militate against Fuch's view that all trachoma is derived by evolution from blenorrhœa.

Of the 5,052 conjunctival cases 53 per cent. were males and 47 per cent. females.

DISEASES AND INJURIES OF THE CORNEA AND SCLERA.

Of corneal affections there were 2,848, or 16+ per cent. of all diseases; 1,812 white and 1,036 of negro blood. The negroes were in exactly the normal proportion, viz.: 36+ per cent.

Of the 1,812 whites with corneal affections 163, or nearly 9 per cent., were cases of ordinary keratitis; of the 1,036 negroes 118, or a little over 11 per cent., had keratitis. Or of the 281 cases of keratitis 41+ per cent. were of negro blood. Of interstitial or parenchymatous keratitis, nearly always of ascertained syphilitic origin, there were 92, or rather more than five per cent., of the 1,812 white cases and 106, or 10+ per cent., of the 1,036

blacks. In other words, the blacks formed 53 per cent. of the 198 cases of interstitial keratitis. With ulcer of the cornea there were 309, or 17+ per cent. of the 1,812 whites with corneal affections, and 266, or more than 25 per cent. of the 1,036 negro cases. Of the total 575 cases of corneal ulcer 46 per cent. were in those of negro blood.

Of nebulæ, maculæ, and leucomata there were among the 1,812 whites with corneal disease 206, or rather more than 11 per cent.; among the 1,036 blacks 230, or more than 22 per cent. Of the 436 persons with these corneal scars 230, or more than 53 per cent., were of negro blood. Among the 1,812 whites there were 20 cases (1 1/10 per cent.) of anterior staphyloma; among the 1,036 blacks there were 30 cases (2 8/10 per cent.). Of those with anterior staphyloma (50) those of negro blood comprised exactly 60 per cent. Therefore the liability of the negro and those of his blood to all the chief forms of corneal disease greatly exceeds that of the Caucasian. Indeed, in the forms of corneal disease considered, the number of blacks positively exceeds that of the whites, save in ordinary keratitis (whites 163, blacks 118) and ulcer (whites 309, blacks 266), the percentage of those of negro blood being excessive in every case. Yet, as we have seen, in the whole number of cases of corneal affections (2,848) the percentage of persons of color (1,036) is only 36+. How is this accounted for? How is the deficiency of whites with corneal disease made up? Not by the number of those with wounds of the cornea, for turning to this head we find that there were 70 cases of corneal wounds (3 8/10 per cent.) out of the 1,812 white cases and 33, or 3 1/10 per cent., out of the 1,036 blacks — about an equal proportion. Curiously enough it is by the large excess of cases of foreign body on the cornea and abrasions of this membrane among the whites that we find the deficiency supplied. Of cases of foreign body on the cornea (857) there were 704, or 38+ per cent., of all affections of the cornea among the whites, and only 153, or 14 per cent., of all corneal cases among the blacks. Only 17+ per cent. of all cases of foreign body on the cornea were in persons of color. There were in all 148 cases of corneal abrasion, the results for

the most part, of course, of injury by small flying particles. Of these 148 cases there were 122, or 6 7/10 per cent., of all corneal affections in the whites, and only 26, or 2 5/10 per cent., of all corneal diseases in the blacks. Only 17+ per cent. of the cases of corneal abrasion were found in those of negro blood — exactly the same proportion as in cases of foreign body on the cornea. The only explanation of this I can conceive of lies in the fact that only a small proportion of negroes are here employed as mechanics and artisans. It must be admitted, however, that some doubt is cast upon the sufficiency of this explanation when we observe that the negro appears to be little liable to the lodgment of foreign bodies beneath the lid, an accident hardly more peculiar to artisans and mechanics than to other classes of the population. Returning to affections of the conjunctiva we find that 169 persons with foreign bodies under the upper lid applied for relief. Of these 125 were white — 4 per cent. of all the whites with conjunctival affections; 44 were negroes — 2 per cent. of all blacks with such affections. But here again the small proportion of negroes may be due to the great numbers that are engaged in servile occupations in the cities and are, therefore, not greatly exposed to such an accident, or should it occur are immediately relieved by one of the intelligent whites with whom they are constantly in contact. In the country the presence of such offending bodies is probably endured with a mixture of stoicism and dull stupidity until they "work out."

Men being much more liable to traumatism, their excess among those with corneal affections may be attributed solely to this cause; women formed but 32 per cent. of the 2,848 corneal cases. It is interesting to note that of cases of interstitial keratitis, 175 in number, the percentage of girls and women was 62 per cent.

DISEASES AND INJURIES OF THE SCLERA.

Of all diseases of the eye those of the sclerotic coat are rarest. They formed but ¼+ per cent. of the 17,311 cases — 21 whites and 24 blacks; 20 men and 25 women.

True (rheumatic) episcleritis is extremely uncommon with us. The form usually seen is a mild syphilitic variety, which promptly disappears under specific treatment. Occasionally we see a phlyctenular form, hardly to be distinguished from the former save by consideration of the history and age of the patient, and the brief duration under simple local treatment (calomel or yellow oxide of mercury salve). The pathology of this variety is not to be discoyered except by constant comparison with the protean atypical transition forms of phlyctenular ophthalmia constantly met with in the black race. I am inclined to think this must be identical with Fuch's ephemeral recurrent episcleritis.

AFFECTIONS OF THE IRIS, CILIARY BODY, AND CHOROID.

The 1,206 cases of disease or injury of the iris form 6 9/10 per cent. of the 17,311 cases of eye disease. Of these iritic cases 519 were of the white and 687, or more than 56 per cent., were of the negro race. Out of the 1,206 iritic cases 820 (336 white, 484 black) were acute nontraumatic iritis. This disease, therefore, comprised 64+ per cent. among the whites and 70+ per cent. among the blacks of all affections of the iris. Of the 820 cases of acute nontraumatic iritis 59+ per cent. were of negro blood, and only a little over 31 per cent. were women.

Affections of the ciliary body numbered 75; only a little over 4/10 per cent. of the 17,311 cases. Of the 75 cases, 41, or 54+ per cent., were of negro blood; 26, or 34+ per cent., were women.

Among the 17,311 cases there were 406, or 2 3/10+ per cent., of choroidal disease and injury. Of these 278 were whites and only 128, or but 31+ per cent., negroes. With plastic choroiditis (various forms) there were 196 whites and only 78 persons of color. Whites with plastic choroiditis, therefore, formed 48+ per cent. of all cases of choroidal affections and negroes but 18+ per cent. Or of all white persons with choroidal affections those with plastic choroiditis comprised 70+ per cent., and of all those of negro blood with choroidal affections those having plastic choroiditis comprised but 60+ per cent. From these

figures then we learn that the negro is especially liable to disease of the anterior portion of the uveal coat. Although his race forms but 36 per cent. of all who attend my clinic nevertheless there was an actual majority of those of negro blood among the cases of disease of the iris and of the ciliary body. It is surprising, therefore, to find, on the other hand, this people enjoys a relative immunity from disease of the posterior portion of this same coat — the uvea. When in 1896 I tabulated the cases treated in my clinic during the two years 1895-1896 and published the results in the American Journal of Ophthalmology for July, 1896 (p. 198), I found exactly the same state of facts. In that paper I said: The percentage of blacks falls very low in diseases of the choroid (16 per cent., the "normal" percentage of the race for these two years being 26.75 per cent.). That this should be true of choroidal diseases is a surprise, and until I can gather together larger figures, I have no explanation to suggest. I must now confess, however, that having the larger figures in hand I am as far as ever from having any rational explanation to offer. My tables for 1902, just completed, show 28 cases of choroidal affections — 17 white and 11 (or 39+ per cent.) persons of color. Of plastic choroiditis there were 16 cases, 5, or 31+ per cent., being of negro blood, although the normal percentage of the race visiting my clinic during this year must be in neighborhood of 40.

AFFECTIONS OF THE LENS.

Diseases and injuries of the lens, embracing 946 cases, formed 5 4/10+ per cent. of all diseases of the eye (17,311 cases). Of the 946 cases, 643 were white and 303, or 32+ per cent., were black persons. Of the 946 cases of affections of the lens, 667, or more than 70 per cent., were senile cataract. Those of negro blood with senile cataract numbered 206, or 67+ per cent. of the 303 with lenticular affections; the whites 461, or 71 per cent. of the 643. Of the whole 946, 386, or 40+ per cent., were women. It would seem, therefore, that whites and blacks, men and women, are all about equally liable to cataract. The

number of cases of zonular cataract (38), of traumatic cataract (82), and other affections are too small to permit of reliable conclusions.

AFFECTIONS OF THE OPTIC NERVE AND RETINA.

Of affections of the optic nerve and retina there were 532 cases, or just about 3 per cent. of the whole 17,311 cases. Of these 305, or 57+ per cent., were white, and 227, or 42+ per cent., black. By far the greater part of these cases were optic nerve atrophy in its three stages of incipient, partial, or total destruction of the nerve. Of this disease there were 117 whites, or 37+ per cent. of the 305 cases of affections of the nerve and retina in Caucasians, and 104 blacks, or 45+ per cent., of all of negro blood with such diseases. Next in frequency were cases of retinitis or neuro-retinitis; 56, or 18+ per cent., of the 305 whites, and 31, or 13+ per cent., of the 227 blacks. This discrepancy in the relative frequency of neuro-retinitis and optic atrophy in the two races I can only explain by supposing that, as the negro habitually puts off seeking medical assistance, we comparatively seldom observe in him the early and acute stage of nerve disease. For, whatever may be the reason, I feel quite sure that "spinal atrophy" is decidedly uncommon in my clinic. Renal retinitis (the few cases of diabetic being grouped with the commoner albuminuric) furnishes but 33 cases; 22, or 7 2/10+ per cent., of the 305 whites, and 11, or 4 8/10+ per cent., of the 227 blacks. Here the figures for comparison are so small that I do not feel confident they express any truth. Of toxic amblyopia (tobacco and alcohol) there were 49 cases, or 16+ per cent., among the 305 whites, and 23, or 10+ per cent., among the 227 blacks. Torpor retinæ (hemeralopia) furnished 12 cases, of which only one was in a white man. Improper diet and habits have already been ascribed as the cause of this affection. It is not infrequently associated with a form of conjunctival xerosis (described by Kolloch). Of this curious affection 8 instances are noted among our 5,052 conjunctival cases; all in negroes, and all but one, a child of four years, males.

Finally, reviewing all the figures and making our comparisons in a somewhat different way, we find that of retinitis and neuro-retinitis 35 per cent., of renal retinitis 33 per cent., of toxic amplyopia 31 per cent., but of optic atrophy 47 per cent., of the cases were in those of negro blood. Remembering that the "normal" percentage of negroes in my clinic is about 36 per cent., we see that the negro is specially liable to atrophy of the optic nerve, but neither especially liable to, or exempt from, the other affections of these tissues. This I believe to be due to the saturation of the race with syphilis, the line of argument employed in considering diseases of the iris holding good. The same etiological factor appears conspicuously, it will be seen, when we reach the external ophthalmoplegias. The confirmatory fact that the disease is commoner in men than in women holds good of iritis, of ophthalmoplegia, and optic atrophy, there being but 28+ per cent. of women with affections of the nerve and retina.

DISEASES AND INJURIES OF THE WHOLE GLOBE.

This subdivision includes microphthalmus, phthisis bulbi, panophthalmitis, traumatic destruction of the globe, foreign body in the eyeball, etc. There were 297 such cases, or only 1 6/10 per cent. of the whole 17,311 cases; 167 white and 130 black, or 43+ per cent. The comparatively large number of blacks is not to be wondered at, for, on account of their rude labors, morals, and manners, and on account of the neglect or impropriety with which they treat their maladies, they are likely to present this class of injury and disease. Although the number of cases (50) is so small as to afford no basis for certainty, it is interesting to consider here the curious phenomenon of sympathetic inflammation and irritation. Of sympathetic irritation there were 22 cases — 17 white and 5, or 22+ per cent., black; 16 men and 6, or 27+ per cent., women. Of sympathetic inflammation there were only 7 cases — 5 white and 2, or 28+ per cent., black; 6 men and 1 woman (16+ per cent.). It would seem, therefore, that these conditions are less common in the

negro race and the female sex. Sympathetic irritation and sympathetic inflammation, it will be observed, form but little over 1/10 per cent. of the whole number of cases.

GLAUCOMA.

Glaucoma comprised but 157 cases, or only 9/10 per cent. of the 17,311 cases. Of these 88 were white and 69, or 43+ per cent., of negro blood. Ninety-five of the cases (60 per cent.) were women. My impression is that negroes are more often affected by the non-inflammatory type, and this is borne out by these 157 cases; 66 of them, with a percentage of 39+ of negroes, were inflammatory, and 76, with a percentage of 46+ of negroes, non-inflammatory.

REFRACTION.

There were 2,747 cases of errors of refraction among the 17,311 cases (15+ per cent.). Of these, 2,212 were white and 535, or only 19+ per cent., were of negro blood. Of the 2,747 cases, 505 whites and 117 negroes were diagnosticated simply "error of refraction," because they left the clinic before any thorough examination under atropine could be made. Of H., there were 1,074 cases, 215, or just about 20 per cent., being negroes. Of H.As. and H.H.As., 421 cases, 71, or 16+ per cent., being negroes. Of M. there were 179 cases, 25, or 13+ per cent., being negroes. Of M.As. and M.M.As., 77 cases, 12, or 15+ per cent., being negroes. Of anisometropia, 77 cases, 8, or 10+ per cent., being negroes. This is nothing more than might have been expected in a race so recently brought under the influences of civilization. Women predominated decidedly among these cases. However, it must be remembered that women are more readily irritated by such defects, more prone to complain of the discomforts of asthenopia and to seek relief than men; that the women of the class who come to our clinics have a much greater tax put upon their eyes by near-work (reading and sewing) than men of the same class, and I therefore do not believe that these figures afford any reliable basis for the conclu-

sion that women are more liable to refractive errors than men. The same reasoning applies in considering anomalies of the extrinsic muscles.

Persons who gave their occupation as housework (domestic sewing, etc., etc.), schoolgirls, schoolboys, and seamstresses composed the vast majority of our cases.

ANOMALIES OF THE EXTRINSIC MUSCLES.

These troubles formed 2+ per cent. (440) of all our cases. Of these 85, or 19+ per cent., were negroes. Of esotropia there were 231 cases in whites and only 19 in persons of color. While the majority of these were mulattoes or quadroons some were blacks. Of exotropia there were 12 cases in whites and only 2 in persons of negro blood. On the other hand of 141 cases of ophthalmoplegia externa 57, or 40+ per cent., were negroes. Knowing the saturation of the blacks with syphilis, these figures are eloquent as to the etiology of these affections.

The remainder of the 17,311 cases are classified under the heading "miscellaneous," embracing cases belonging to other departments or clinics, cases that left the clinic before a diagnosis was made, malingerers, those having nothing the matter, hysterics, etc., etc.

DISCUSSION.

Dr. Kollock. — Dr. Bruns' experience is exactly in line with my own. What he says about chalazion is particularly in accord with my observations, and tumors often appear multiple in this race. In tobacco-amblyopia it is interesting to note that it occurs even among colored women, particularly those who work on the farms, where they smoke the commonest form of plug tobacco in clay pipes. I have usually found that those women did not drink and that the amblyopia was due simply to the tobacco and that they get well quickly when the tobacco is withdrawn. Hemeralopia is very common, especially among the negro children. They are frequently brought to the hospital because they are blind at night and fall over objects.

Follicular conjunctivitis is seen but is not very common among them, and I have noticed that they do not have gonor-

rhœal ophthalmia as often as the white man does, although the gonococcus is present with them frequently enough. Interstitial keratitis is seen more frequently in the mulatto than in the pure black. So far as treatment is concerned I think Dr. Bruns will agree with me that we have to use mercury in some form because syphilis is so prevalent among them.

DR. HOWE. — Some years ago, when attention was first called to it, the opportunity occurred and I made a number of sections of the lid, sections which I still have, and I would like to have anyone look at them who is interested in the matter, and if they can see any difference between those of the colored and of the white race, they can do more than I can. Anatomically, the structure is absolutely the same.

SUGGESTIONS FOR A UNIFORM NOMENCLATURE OF THE MOVEMENTS AND MOTOR ANOMALIES OF THE EYE.

BY ALEXANDER DUANE, M.D.,

NEW YORK CITY.

The suggestions regarding nomenclature here proposed are in most respects the same as those that I put forth in an article in the Ophthalmic Record for February, 1899. Essentially the same plan, with some slight modifications, was advocated by Dr. Ellett at the meeting of the American Medical Association last year — the principles underlying the nomenclature in both cases being identical, and the terms, too, being generally the same.

The importance of having some uniform plan of terminology seems so patent as hardly to require argument. At present we have several terms, *e. g.*, abduction and adduction, which are habitually used in two senses, essentially different. This confusion in expression begets confusion in ideas; and, as I pointed out in the article already referred to, may lead to quite erroneous conclusions. To quote further from the same article: "It is better always to use terms that shall be free from ambiguity, and particularly to use different expressions for actions that are essen-

tially different in nature. Our nomenclature, therefore, should be such as to clearly differentiate (1) the individual movements of each eye by itself, (2) the associated parallel movements of the two eyes together, and (3) the associated disjunctive movements of the two eyes."

The principles which should govern any classification of the sort may be, I think, stated as follows:

1. As far as possible to use words already employed, and in the ordinary sense in which they are employed.

2. To use a word in but one sense.

3. When a word, *e. g.*, abduction, is already used in two significations, to retain it, but restrict it to that signification which agrees best with analogy and general anatomical usage.

4. To avoid binomial expressions when a single word, not too cumbrous, can be used as well.

5. To prefer words which form convenient adjectival and verbal derivatives.

6. To follow analogy, so as to make words that denote analogous functions have analogous forms. This rule should not, however, be followed pedantically; not, for instance, to such an extent as to lead us to replace well-established terms by ones of our own invention, just because the latter are more in accordance with analogy.

7. To follow carefully etymological principles, avoiding hybrid expressions, and attending carefully to the precise meaning of the Latin and Greek originals.

TERMS USED IN DESCRIBING THE OCULAR MOVEMENTS.

To illustrate the way in which these principles are applied. We have already the terms abduction, adduction, divergence, and convergence. Abduction and adduction are used in at least two senses, *i. e.*, abduction denotes (*a*) the movement of either eye outward from the middle line and (*b*) the amount by which the two eyes can be made to diverge when overcoming prisms, base in. The former application of the term agrees best with anatomical usage and should therefore be retained (Rule 3).

We have then two terms, adduction and abduction, denoting the movement of one eye outward and inward respectively. Then by analogy (Rule 6) all other movements of either eye individually would be denoted as *ductions*, the appropriate prefixes being used to indicate the direction of the movement.

In accordance with this plan, I proposed in the paper before mentioned to use *sursumduction* for a movement upward and *deorsumduction* for a movement downward. These terms seemed better than Maddox's *superduction* and *subduction*, since the former etymologically means "a drawing over" rather than "a drawing up," and subduction means "a drawing up from below," *i. e.*, really the precise opposite of the signification intended.

All four terms, however, are needless since we have already in *elevation* and *depression*, terms which are well established and perfectly satisfactory, and which should not, therefore, be displaced from any pedantic adhesion to analogy (Rules 1 and 6).

Just as we have abduction and adduction to denote movements of either eye separately, so we have *divergence* and *convergence* to denote two varieties of disjunctive movement. If we follow this analogy, the disjunctive movements in general then will be known as *vergences*.* The tendency or ability of the two eyes to diverge in a vertical plane will, in that case, be called *supravergence*. This seems decidedly better than the term *sursumduction* hitherto employed, which, if used at all, should designate a movement of either eye alone upward (*i. e.* elevation), and better also than *sursumvergence*, which I have elsewhere† proposed. For the tendency is one by which one eye does not simply go up (*sursum*), but gets above (*supra*) the other.

The terms thus far given, which are all, with one exception, in common use, satisfy our Rule 5 in that they all form satisfactory derivatives or cognate expressions. Thus, corresponding to abduction, adduction, elevation, and depression, we have the

* Duane, loc. cit.

† Motor Anomalies of the Eye.

verbs abduct, adduct, elevate, and depress, and the nouns abductor, adductor, elevator, and depressor. So also corresponding to divergence, convergence, and supravergence, we have the verbs diverge, converge, and supraverge, and, if we choose, the nouns diverger, converger, and supraverger.

For the parallel movements of the eyes I have proposed* the term *version*, which Ellett has also adopted. By means of appropriate prefixes the individual movements, right, left, up, and down, are denoted. And, just as corresponding to abduction we have abduct and abductor, so corresponding to these terms ending in *-version* we have a series of words ending respectively in *-vert* and *-verter*. Thus, if *levoversion* is a movement of both eyes to the left, we may say that the right internus and the left externus *levovert* the eyes, or are *levoverters*.

The various terms thus formed may be stated as follows:

PARALLEL MOVEMENTS OF EYES — VERSIONS.

Movement of both eyes laterally: *Lateriversion.*
  Includes —
    Movement of both eyes to right: *Dextroversion.*
    Movement of both eyes to left: *Levoversion.*
Movement of both eyes up: *Sursumversion.*†
  Includes —
    Movement of both eyes up and to right: *Dextro-sursumversion.*
    Movement of both eyes up and to left: *Levo-sursumversion.*
Movement of both eyes down: *Deorsumversion.*‡
  Includes —
    Movement of both eyes down and to right: *Dextro-deorsumversion.*
    Movement of both eyes down and to left: *Levo-deorsumversion.*

*Motor Anomalies of the Eye; Oph. Record, February, 1899.

†Better on etymological grounds than either *superversion* or *supraversion.* The former would mean "a turning over or beyond", the latter "a turning above" (something else).

‡Much better on etymological grounds than *subversion* or *infraversion.*

For the tilting of the vertical meridians of the eye — the wheel rotation (Raddrehung) of Helmholtz — we have no expression quite free from ambiguity. *Declination*, used by Stevens, is perhaps the best of the terms proposed, but *torsion*, while not in itself a fortunate designation, is the one most generally employed, is well understood, and besides lends itself better than declination to the formation of derivatives. Thus we have formed from it *intorsion*, or rotation of the vertical meridian inward, and *extorsion*, or rotation of the vertical meridian outward. These terms are already in use, being employed by Maddox, who proposed them, and by others. Similarly, we have the nouns *intorter* and *extorter*, and the verbs *tort*, *intort*,* and *extort*.*

So also, as I have elsewhere suggested,† a rotation of the vertical meridian to the right corresponding to Helmholtz's positive Raddrehung and Stevens's positive declination, is appropriately called *dextrotorsion*, and a rotation to the left, *levotorsion*.

It might seem useful to have terms that would distinguish the torsion movements of each eye separately from the associated torsion movements of the two eyes; *i. e.*, just as we use words ending in -duction to denote the side-to-side movement of each eye separately, and words ending in -version to denote the parallel movements of the two eyes together, so we might restrict the term torsion to designate a tilting of the vertical meridian of either eye by itself, and apply some other word to denote a tilting of both vertical meridians. Such a word might be appropriately derived from the Latin *clinare*, to incline, and we should then have

Dextroclination, tilting of both vertical meridians to the right.
Levoclination, tilting of both vertical meridians to the left.
Conclination, tilting of the top ends of the vertical meridians toward each other.
Disclination, tilting of the top ends of the vertical meridians away from each other.

*Maddox.
†Loc. cit.

We may not care to multiply terms to this extent. In that case, the terms dextrotorsion and levotorsion, which are already used to signify a tipping of one eye to the right and left, may, without much confusion, be employed to denote a tipping of both eyes simultaneously, and so replace dextroclination and levoclination. In that case, the terms *contorsion* and *distorsion*, elsewhere suggested,* would be rather better than conclination and disclination.

TERMS USED IN DESCRIBING THE TESTS.

When we get a patient to overcome prisms, base in, we usually say that we are testing his *abduction*, and, if he just overcomes a prism of 8°, we say he has an abduction of 8°. Really, however, his abduction, *i. e.*, his ability to move either eye outward, is from 40° to 45° of arc, corresponding to the deviation produced by a prism of 70° or 80°. What we are actually testing is his divergence or diverging power, and what we should say is that his *prism-divergence*,† or simply his *divergence*, is 8°. So also the ability to overcome prisms, base out, does not measure *adduction*, but *convergence*, and the amount of prism thus overcome constitutes the *prism-convergence*.† In like manner, the ability to overcome prisms, base down, before the right eye, or base up before the left, should not be called right *sursumduction*, but right *supravergence*. Right sursumduction, if used at all, should denote the absolute power that the right eye has to go upward, just as abduction denotes its power to go outward. It would then be measured by a prism of some 40° or 50°. Supravergence, on the contrary, is the ability of the two eyes to diverge in a vertical plane; an ability which is measured by a prism of 2° or 3°.

In describing diplopia, we have already in use the words *homonymous* and *heteronymous* (or *crossed*). These terms differentiating the two varieties of laterial diplopia are very useful and convenient. It would seem equally convenient to have terms

* Duane, loc. cit.
† Duane: Motor Anomalies of the Eye.

differentiating the two varieties of vertical diplopia. Hence I have for a long time advocated the use of *right diplopia** to denote vertical diplopia with the image of the right eye below (corresponding thus to right hyperphoria), and *left diplopia** to denote the reverse condition. These terms are particularly useful in describing paralytic cases. By doing away with a clumsy periphrase, they make decidedly for brevity and clearness. We would not think of saying "lateral diplopia with the image of the right eye on the right hand." Why then should we feel ourselves compelled to say "vertical diplopia with the image of the right eye higher," when the simple expression "left diplopia" will express the same idea more compactly and more lucidly, and will at the same time suggest the underlying condition, *i. e.*, a left hyperphoria?

TERMS USED IN DESCRIBING DEVIATIONS.

The terms applied in describing deviations are in general so well established and adequate as to need no modification.

Stevens's terms *esotropia, exotropia, hypertropia*, already long in use and increasingly current, much surpass in convenience and simplicity the older binomial expressions, strabismus convergens, divergens, sursumvergens, and deorsumvergens. It is to be hoped that their use will become universal and that to effect this end this Society will give them the stamp of its approval.

We often describe squint and other deviations as *concomitant;* or we say that the movements of the eyes are concomitant. A better term is *comitant*; first, because it is briefer; second, because comitant is classical Latin, whereas concomitant is Neo-Latin; and lastly, because in concomitant the con- is as redundant as "with" is, in the phrase "accompanying with."

The word *constant*, as applied to squint, is at present used in two senses. First, as opposed to *intermittent*, it denotes a squint that is present all the time. In this sense it would seem proper to retain it. Again, as opposed to *periodic*, it designates a squint,

* First suggested in N. Y. Med. Journ., Aug. 3, 1889.

which, whether present all the time or not, is, at all events, present equally for distance or near. In this sense, in order to avoid confusion with the first meaning, it is preferably replaced by some other term. *Continuous* suggests itself as an appropriate substitute.

To keep to our principle of unity of definitions, and thus avoid confusion, it will be better for us to discard, whenever possible, the terms *divergence* and *convergence* used as expressions of a pathological state. Thus the expression "convergence of 10°," meaning an inward deflection, manifest or latent, of that amount, is better replaced in all cases by esophoria or esotropia, as the case may be; the term convergence being used to denote only the physiological act of turning both eyes in so as to fix a near object.

A term which seems of some utility is *dyskinesis*. It denotes that condition, not infrequently encountered, in which the movements of parallel rotation, of divergence, and of convergence are of normal extent, and yet some or all of these movements are associated with pain and a sense of strain and cannot therefore be maintained for any length of time.

The suggestions here proposed are merely tentative. Doubtless others, as good or better, can readily be devised. But the advantages of precision and uniformity in practice in this matter are so great that it is to be hoped that this Society will now or at some time in the near future take action to establish a nomenclature, which, being authoritative, will be universally received.

REPORT OF A CASE OF ACUTE GLAUCOMA INCITED BY THE USE OF EUPHTHALMINE FOR DIAGNOSTIC PURPOSES.

BY H. W. RING, M.D.,
NEW HAVEN, CONN.

Euphthalmine hydrochlorate, a synthetic product said to closely resemble Eucain "B," was brought to the attention of ophthalmologists by B. Treutler in 1897. He found it to be a

strong mydriatic, brief in its action, and producing no unpleasant effects.

The invention of a mydriatic having a rapid and brief action without in any way affecting the power of accommodation is still a desideratum to be realized; but it was thought euphthalmine might be the drug *par excellence* for this purpose and extensive and varied experimentation resulted.

Treutler's own experimental results were summarized as follows, viz.:

1. The instillation of euphthalmine solutions into the eye cause only very slight and temporary inconvenience.

2. Euphthalmine is a powerful mydriatic. A 5 to 10 per cent. solution produces a maximum dilatation of the pupil in about the same time as does 1 per cent. homatropine solution.

3. Its action is less intense and prompt in the aged than it is in younger individuals.

4. Euphthalmine has the advantages over cocaine as a mydriatic that it is more powerful in its action, and that it does not damage the corneal epithelium. On the other hand, the mydriasis that it occasions is somewhat slower of development.

5. Euphthalmine affects accommodation less than does homatropine.

6. Both the mydriasis and the accommodation paralysis disappear much more quickly after its use than after that of homatropine.

7. No unpleasant effects upon the organism have so far been observed from its use.

His observations were confirmed in the main by Ball, Schneider, Vossius, Winselmann, Vinci, Woskessensky, and Darier during 1898, and since that time I presume there are few ophthalmologists who have not used the drug enough to form their own conclusions as to its limitations and value.

Knapp, in 1899, after nine months' use was very favorably impressed with it as an aid in ophthalmoscopic examinations.

In two cases he received the impression that " euphthalmine, like atropine, had a tendency to increase the eyeball tension. In many later cases had not seen this effect any more."

In the same year Jackson wrote: "The claim that euphthalmine is free from danger of causing glaucoma should be met with skepticism. The claim has been put forward for duboisin, and homatropine, and has for them proven false. No one has yet reported a glaucomatous attack following the use of euphthalmine; but the report will undoubtedly come later, if the drug is widely used. It has this advantage over the stronger mydriatics, that the brief mydriasis that it produces may not so often last long enough to develop increased ocular tension. But its mode of action seems quite similar to that of atropine and homatropine; and it is possible that the relatively greater mydriasis it produces, as compared with the cycloplegia, may be fraught with correspondingly greater danger. At any rate, without wide and prolonged experience with it, we are not justified in ranking euphthalmine with cocaine as a comparatively safe mydriatic to use in cases of impending glaucoma."

In the Ophthalmic Record for May, 1902, Dr. Myles Standish reports a compilation of thirty-two cases of glaucoma reported to the New England Ophthalmological Society since its foundation. In an analysis of these reports he found that glaucoma was precipitated in nine cases by atropine, two cases by homatropine, one case by cocaine, one case by scopalamine, and one case by duboisin — an array which to his mind tends to establish the fact that it is the mydriasis itself, and not the drug used, which produces the disastrous result.

Of these fourteen cases twelve were cured by the use of myotics alone, and he is of the opinion that, "in a person over 40 years of age, when the pupil is dilated for the purpose of examining the fundus or refraction, the instillation of a myotic before the patient leaves the office, as a matter of routine, would, in all probability, prevent the supervention of acute glaucoma in cases predisposed thereto."

Previous to the introduction of euphthalmine it was my habit to use cocaine to dilate the pupil for diagnostic purposes. My patients did not like the sensation of stiffness of the eyeball and lids caused by its use, but this was of minor consequence.

A not at all infrequent cause of complaint, however, was a more or less serious interference with the accommodation, and, where the accommodation was practically abolished by age, with the general near vision. The time of the visual disturbance ranged from six to twenty-four hours.

During the past three or four years I have entirely displaced cocaine by euphthalmine for simple dilatation of the pupil, using a 5 per cent. solution, and I simply know that I have little or no complaint from patients as to any prolonged disturbance of vision.

I have never assumed that the drug was not capable of causing increased tension and possibly exciting a glaucomatous attack in an eye predisposed thereto, and have therefore made it a custom before using in a patient beyond middle life to take the tension of the eyeball, examine the eye by oblique illumination and make some inquiries as to glaucomatous symptoms. I have never had occasion to regret its use but in one instance, and the history of that case is as follows, viz.:

February 14, 1902. Mrs. H., residing in a nearby town, was sent to me by her family physician. She was a well-to-do housewife, aged 56. At the age of 8 she was very ill with rheumatism followed by erysipelas and since then has never been in vigorous health. Attacks of articular rheumatism have been common, but there is no marked enlargement of the joints. Headaches in the frontal and occipital region have been a source of affliction many years. In the autumn of 1901, she began to have periods of pain in the left eye and supraorbital region, and these attacks had been increasing in frequency and severity, and when an acute stage was reached the vision of this eye was so much reduced that she avers her inability to distinguish objects. The eye would be mildly congested and she could get relief from hot applications and anodynes, and then the usual sight would be restored. Recently these attacks had become so frequent and severe that her physician wanted my opinion as to the condition of the eye. He had assumed up to this time that the eye pain was an exhibition of her general neuralgic and rheumatic condition.

I first took her refraction, which was

O.D. 20/70 — ; 20/20 — +1.0 ⊂ +.5 ax. O.
O.S. 20/70 ; 20/20 — +1.0 ⊂ +.5 ax. O.

She read J. 1 with each eye with +4.5 ⊂ —.5 ax. V.

Macroscopically the eyes seemed normal, and after finding the tension and field (taken roughly) the same I instilled two drops of 5 per cent. euphthalmine solution into the left eye, as the pupil was small and I felt the necessity of a thorough examination of the interior of the eye. In about a half hour the pupil was well dilated and the ophthalmoscope revealed no abnormal condition sufficient to account for her pain. The outlines of the nerve seemed a trifle hazy and there was a single spot of retinal exudation near the papilla at the nasal side.

I gave her correction for distance as she had not been wearing any, changed her reading glasses slightly, ordered phosphonux, and asked her to let me see her if possible while she was in the midst of another attack.

I did not see her until fourteen days later, and the history of the case during that time was furnished by the patient. Within a few hours after she left my office there was a renewal of the pain in the eye and the left side of the head and during the next two weeks she had but few intervals of relief except when under the influence of opiates.

The eye soon became inflamed and tender and the vision much impaired. She was so weak and prostrated that she did not feel able to come to my office until February 28th, when I found a typical case of acute glaucoma.

Vision reduced to distinguishing objects, T+1½, eyeball injected and tender, cornea dull and anæsthetic, anterior chamber shallow, pupil dilated and fixed, no view of fundus possible. The right eye was not involved.

Within four hours I did an iridectomy, ether being used as an anæsthetic. The iris was very rotten and I was obliged to pick it out in strands. After this operation she was compara-

tively free from pain for the first time since the instillation of euphthalmine.

I used eserine in the good eye the day of the operation and several succeeding days.

March 5th the tension was normal, field of vision (not taken by the perimeter) very good, eye white and quiet and vision very fair, but I have no exact record of it. She went to her home and returned to me on the 15th, ten days later. There had been no recurrence of trouble, and I found Tn. media clear, only slight cupping of disc, V. L.E. 20/50+20/20— +1.12 ⊂ —1.0 ax. V., and reads J.2 with +4.0 ⊂ —1.0 ax. V.

During the next four months she would have occasional shooting pains through the left eye and the head, but only such as she had been having for two years or more. She had rarely seen halos and the field in each eye was little if any impaired. She was disturbed about the possibility of the disease attacking the good eye and July 2d she elected to have an iridectomy on the right, which I did, using cocaine as an anæsthetic.

She has had a very comfortable winter and her vision is normal with correcting lenses. The eyes are free from tension, cupping of the discs, or pulsating veins.

DISCUSSION.

DR. KNAPP. — I have used euphthalmine and still use it daily. I have seen three cases of acute glaucoma following it, and I mention them here although I have previously reported them before the ophthalmic section of the American Medical Association when it met in Saratoga last year. Those cases all occurred in my office and they were all restored to health by the immediate application of a 1 per cent solution of eserine. As I have a suspicion that it may occur I now always ask such patients if they have time to remain in my office a half hour or more after its use so that I may see that no trouble arises. Even with this experience I believe that euphthalmine is a much more manageable mydriatic than homatropine for such examinations.

DR. POOLEY. — I have a case of unusual interest to report though I did not use the same preparation. The mydriatic produced a dilatation of the pupil above and revealed a broad syne-

chia below and an atrophy of the optic nerve. The case is interesting because there had been no suspicion of increased tension and there was a very marked myosis.

I cannot see how we can accomplish much by keeping the patients waiting in the office for a half hour, as the trouble usually appears only after a much longer period.

DR. KNAPP. — I have never seen a case of glaucoma from this cause that did not arise in my office.

DR. PYLE. — On the morning of April 28, 1903, I was consulted by a woman of 50, in good health, but of rheumatic tendency, with a vague history of periodic ocular neuralgia. The eyeballs were not congested, the tension was about normal and the anterior chamber of moderate depth. The pupils were active to light and accommodation, and so small that a satisfactory view of the fundus was not obtainable. One drop of a mixture of homatropine and cocaine, 5 grs. of each to the ounce, was instilled in each eye. Complete mydriasis occurred in about thirty minutes. No cupping of the discs was seen, no arterial pulsation and no fundus changes noted, although there was some peripheral lenticular segmentation. The ametropic correction was: O.D. — Sph. 0.75 ⌒ — cyl. 0.25 ax. 120°; O.S. — Sph. 0.75 ⌒ — cyl. 0.25 ax. 60°. V.= 6/6.

The patient left my office without complaint of pain or discomfort and I saw her the following morning with no ominous symptoms. At 2 A. M. of the morning of the following day she was awakened by violent pain in the eyes, followed by intense retching and vomiting and a rapid failure of vision. I saw her about noon and found a typical attack of acute glaucoma in each eye. The tension was +2 or 3. The cornea was hazy, rendering the fundus-view very unsatisfactory in the right eye, but enough could be seen to show that there was no cupping of the disc, although there was marked arterial pulsation. The left cornea was so hazy as to obscure even the red fundus-reflex. The vision fell to counting of fingers in the right eye, and doubtful light perception in the left. The pupils were widely dilated and inactive, the anterior chamber abolished, and there was intense conjunctival and ciliary congestion. Eserin and massage were immediately applied and local heat, diaphoresis, and anodynes ordered. Sodium salicylate in 10-gr. doses was given every two hours, tincture strophanthus in 5-drop doses every four hours, and mercurial inunctions were instituted every three

hours. The condition continuing to grow worse, I performed posterior sclerotomy with a valve-like conjunctival flap, in both eyes. The following day ocular massage was again instituted and alternate instillations of the following solutions applied every three hours:

℞

Eserin salicylate,	0.02
Pilocarpin hydrochlor.,	0.05
Sol. adrenalin (1-5,000),	10.00

℞

Dionin,	0.10
Pilocarpin hydrochlor.,	0.05
Aqua Dest.,	10.00

The pain was relieved immediately by the incision, the tension rapidly fell, the anterior chamber deepened, the pupil began to contract, and the normal visual acuity was established in 72 hours. I have not yet taken the fields with the perimeter, but when I left the patient last Saturday there was every reason to believe that the recovery was complete. The question of iridectomy in the interval of quiet is now an open one.

VICARIOUS MENSTRUATION INTO THE RETINA FOLLOWED BY DETACHMENT AND RETINITIS STRIATA.

BY PERCY FRIDENBERG, M.D.,

NEW YORK CITY.

(*With illustrations by the author.*)

The correlation existing between the sexual function of females and disorders of the visual apparatus in its various aspects is mentioned in most treatises on ophthalmology, in reports of numerous cases and in several monographs, among which those of Salo Cohn and Knies are the most complete. One aspect of this subject, that of intraocular hemorrhage occurring with the first menstruation, has recently been brought to my attention. As these cases are rare and the fundus changes

FIG. I. Upright image. Hemorrhage from inferior temporal vein.

FIG. II. Upright image. Sub. hyaloid hemorrhage at site of venous clot. Macular changes.

were observed and followed from beginning to end with the ophthalmoscope, some interest may attach to the report of this case.

Mary N., aged 15 years, was brought to me on February 3, 1902, for the relief of a disturbance of vision of the right eye, which had come on a week or two before, in connection with first menstruation. The previous history was negative; there had been no ocular disturbance whatsoever. About this time, the patient, an anæmic, undersized girl, began to complain of constant headache, on the top of the head and across the eyes. Vision in the right eye had become suddenly worse and black spots appeared before the eye for some days. On examination the following ocular condition was found: Right eye V. 3/200, unimproved by correction of 2½ D. hypermetropia; reads Jäger No. 6 at 3 inches. Left eye, V. 20/20 with cyl. +1/2 axis 90°, reads Jäger No. 1 at 6 inches to 36 inches. Ex. of the fundus O.D. showed the following condition: Disc margin blurred, best seen with 3D.+; veins tortuous, and on those running to the inferior nasal quadrant, white striations are seen, rather broad and of a fatty, glistening color. At about 2 P.D. from the disc, a hemorrhage was seen situated on the vein running to the lower temporal quadrant, and another, smaller, on the same vein nearer the periphery. In the macular region one or two small, white, glistening dots are seen arranged around the fovea (Fig. 1). Physical examination, for which the patient was referred to her family physician, proved negative, particularly as regards the heart and renal secretion. Gymnastic exercise which, up to this time, had been partaken of continuously, was stopped. Atropine, 1 per cent., was instilled every second day into the right eye, which was protected by a shade. Light diet was ordered and Fl. Extr. of hydrastis with ergot, one-half teaspoonful, given before meals. Sodium iodide was given in increasing doses with the intention of causing absorption of the hemorrhage. The condition remained practically unchanged until June 16th; V. O.D. then 10/200. There was a small, paracentral scotoma.

On July 8, the patient again presented herself. Menstruation, which had been expected on June 9, had not appeared. There had been marked headache and vision seemed diminished. The patient had been taking hot hip-baths morning and night and had also been treated with potassium permanganate, one grain every four hours, and manganese biniodide, two grains every four hours. Vision was now 3/200. Ophthalmoscopic examination shows a fresh hemorrhage on upper temporal vein, a large, subhyaloid effusion in the inferior temporal quadrant, where the venous hemorrhage had originally been seen. The outlines of the disc are more blurred than at the last examination and the perivascular striæ more marked in number and extent; a few punctate hemorrhages are seen in the neighborhood of the subhyaloid effusion and the white dots at the macula have the appearance of a star figure and seem increased in number (Fig. 2).

On September 1, the ophthalmoscopic picture shows the following remarkable change: There is a detachment of the retina limited to the inferior and temporal quadrant. In the portion nearest the disc, the retinal vein appears indistinctly through the detached membrane, and at a point on its upper border, about corresponding to the macula, a small bright red spot is seen surrounded by detachment. The perivascular striæ have developed above into organized strands of tissue of a pearly white hue which, in places, shades into a grayish-green. Some retinal striations of a glistening white appearance are seen in the nasal part of the retina near the disk (Fig. 3). V., fingers at three feet toward temporal side only. Perimetric examination shows a large defect in the nasal half of the visual field.

On December 29, detachment has progressed so that it now occupies the entire temporal half of the fundus, although it is not complete above, but allows the retina to show through in the form of several bright red sectors. In the direct line of the macula a small clear red spot, about half the size of the disc, is seen at the bottom of a tunnel of detached retina. Under the detachment numerous silvery white proliferations are observed branching

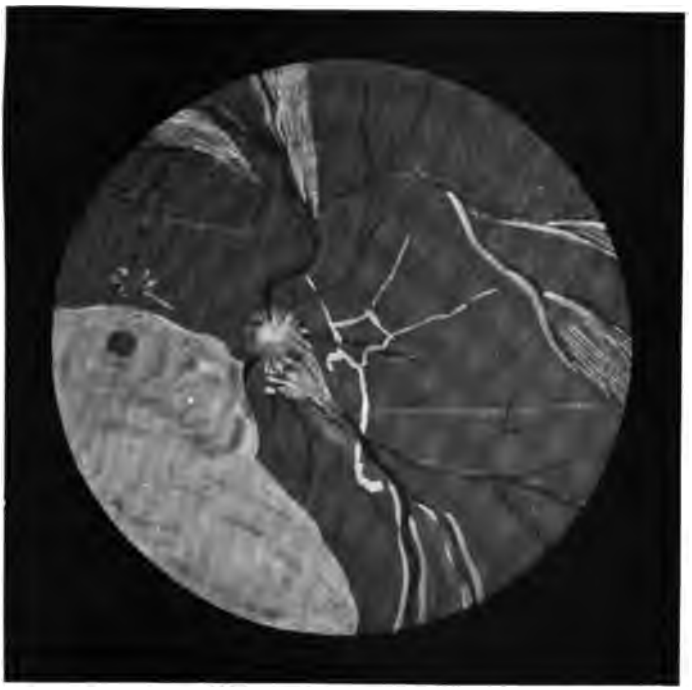

FIG. III. Upright image. Detachment limited to inferior temporal quadrant. Beginning retinal striations : perivascular striae.

FIG.IV. Upright imago. Detachment involving temporal half of retina. Advanced retinal striations in clear retina and in detached portion. Connective tissue proliferations about vessels.

off in different directions in company with retinal vessels. The retinal striations in the clear retina have increased in number to a marked extent, and are not only linear, but also — especially in the periphery — of a membranous appearance (Fig. 4). The detached area could be seen best with spher. +22D. the rest of the fundus with +4. Vision had not improved. The defect in the visual field has covered its entire nasal half.

At the request of her parents, who were very eager that nothing that could possibly improve the condition of the eye should be left undone, a trial was made with subconjunctival injections of salt solution. The patient was admitted to the New York Eye and Ear Infirmary on January 13, 1903, and a series of injections, six in number, of a 20 per cent. solution, was carried out, alternating with hypodermic administrations of pilocarpine, 1/12 grain. On the 31st of January the patient was discharged. The perimetric examination showed the same limitation of the field of vision as before. Vision now: F. at 3 feet in the temporal half of the field only. The summit of the detached area could now best be seen with +18D. Since this time the patient has been under continuous observation at intervals of two weeks. There has been absolutely no change in the condition from that found at the last ophthalmoscopic examination, which is shown in Fig. 4. Vision in the left eye remains normal and there are no intraocular changes. Menstruation, which became established in September, has shown no irregularity up to the present time. The patient's general condition is good.

In a search of the literature of this subject I have found but few cases which were similar to that just reported, in presenting (1) a previously normal eye; (2) an attack coincident with the first menstruation; (3) a typical, vicarious character; (4) recurrence; and, lastly, (5) cessation with the establishment of a normal monthly flow.

One of the earliest recorded cases, that of Power,* is however so well described and so characteristic of this type of affection, that I shall quote it in detail. The drawings of the fundus

* St. Barth. Hosp. Rep., 1871, Vol. VII, p. 193.

are particularly instructive, and as they are valuable pendants to those of my case, I have made copies from the original colored plates.

Sophia MacK., aged 16 years, was admitted to St. Barth. Hosp. on February 11, 1871. She complains of diminished vision, O.D. since a fortnight. There is now perception of light only; no pain, but occasional headaches. The patient is small, anæmic, looks to be about 12 years old, and has not menstruated. Urine sp. gr. 1,015; no albumin, acid. O.D. cornea clear; T. +o minus zero, eye quiet.

February 13th, ophthalmoscopic examination: Media clear; veins distended and tortuous, being interrupted at spots, with whitish-yellow patches; arteries of large size, some of them having hemorrhages running from them into the substance of the retina (Fig. 5). On tracing these arteries towards the periphery of the fundus many profuse hemorrhages were found to proceed from them running into one another. Fine, jagged, but continuous whitish lines, united into a kind of plexus, were seen traversing these patches, running, or rather, branching off from the main trunk. The choroid around the yellow spot appeared very deep in color and the yellow spot itself had the peculiar appearance depicted in Fig. 5. White, glistening, radiating lines issue from a common center formed by the macula lutea, giving it the appearance of a glistening star.

The bowels were opened freely by the administration of aloes and myrrh and warm hip baths given to induce menstruation.

October 19th, all the vessels appeared much larger, having numerous hemorrhages along their course. The hemorrhages previously present are much increased, while small and minute hemorrhages from smaller vessels are visible on the disc and one large, cone-shaped one with base above, appeared immediately over the macula lutea, covering it and hiding vessels where at some distance from the spot it crosses their track. The peripheral hemorrhages are much increased (Fig. 6). There is no pain; total loss of sight. Urine negative. Treatment continued.

February 27th, no changes were found during daily examinations up to date, and the following appearance was noted:

The lower triangular portion of the hemorrhage has disappeared, while a whitish line runs around the apparent inner edge (Fig. 7) of the remains of the hemorrhage at the site of the triangular patch which has disappeared. The retina is hazy and clouded, media hazy (vitreous?) Liq. ferri. per-chlor. m. 5 and liq. strychnia 1 m. t. i. d. Meat diet and one-half pint of porter are now given.

March 1st, the hemorrhages over the optic disc and along the course of the vessels absorbed; the vessels less distended, peripheral hemorrhages much fainter; large central hemorrhage growing fainter and more transparent. The fundus remained the same until April 6, the lower corner of the hemorrhage having been absorbed, when there was an attack of conjunctivitis in the right eye with lachrymation and pain in the globe and in the head. This decreased on the 6th, but on the 21st the conjunctivitis came on again with general inflammation of the whole globe and great pain in the eye. A central opacity was forming over the right cornea. More nutritious diet, beef essence and wine and milk were now ordered.

May 1st. Head on the right side very painful; eyeball very much congested and in great pain; tongue furred (brownish) P. 108, T. 99° F. Patient very restless; veins on the right eyelid tortuous and much swollen and congested.

May 12th. Symptoms continue; pain has increased, the patient eating nothing and complaining of pain in the left temporal region. The child's health was clearly suffering from local disease. She got little sleep, had become very pale and thin and was in a state of great depression of spirits. It was decided to excise the right eye, which was done on May 12th. On removal, the eye was divided equatorially. The hemorrhagic spot was very distinctly visible, together with the remains of the hemorrhage in other parts of the fundus. The globe was placed in alcohol to harden and, subsequently, in chromic acid solution which was, unfortunately, made far too strong and no satisfactory sections could be made.

A second case, dating from pre-ophthalmoscopic times, is quoted by Cohn* in the original Latin, from the observations of Pechlinus.† This interesting case, the oldest that could be found, was one of blindness, occurring in a 16 year old girl, which the author attributed to difficulty in menstruation and cured by the establishment of the normal flow.

Gynæcologists are familiar with cases of so-called vicarious menstruation where there is absence of uterine flow. These periodic hemorrhages may take place from the nasal mucosa, or that of the bronchi, stomach, from hemorrhoids, old ulcers, etc., but are of course particularly ominous when, as in the cases mentioned above, they take place in the interior of the eye.

As to the mechanism by which these vicarious hemorrhages are brought about, the subsequent general account‡ may be in place of the development of the normal menstruation at puberty.

The first menstruation is generally accompanied or preceded by phenomena of the most varied character, not infrequently combined in an irregular manner (molimina menstrualia). In the great majority of cases these symptoms are those of pain of a drawing character in the back and abdomen, feeling of heaviness and warmth in this locality, tenesmus, disturbance of defecation (constipation rarely, more frequently diarrhœa). In a word, symptoms which are to be found in every active (inflammatory) hyperæmia of the pelvic viscera. These changes in the circulatory conditions are by no means limited to the pelvis, but draw other regions into their sphere of activity. Among the commoner symptoms are, swelling and tenderness of the breasts, digestive disturbance, rushes of blood to the head, headache, and various changes in the skin (blue rings about the eyes, erythema, erysipelas, urticaria, hemorrhages, etc.), as well as nervous and psychical hyperæsthesia and irritability. Of these symptoms, one or the other, or a combination of several at the same time, is generally present, if only slightly indicated,

* "Uterus und Auge," Wiesbaden.

† Pechlinus, Jo. Nicol. Observationum Physico-Medicarum Libri III, Hamburg, 1691.

‡ Greulich, Eulenburgs Real-Encyclop., Art. Menstruation.

from which the conclusion is to be drawn, that the process of menstruation is by no means limited to the generative sphere, but affects the whole organism in a reflex manner and by sympathy.

In many cases disturbances of menstruation are present from the very first. A large number of young girls suffer, for instance, with the first appearance of menstruation, which is generally scanty. The symptoms are more or less severe and generally disappear in course of a few months, although at times they may persist. Gusserow* explains this in the following manner.

At the time of puberty and beginning menstruation the most developed follicles are still in the depth of the ovary. When they ripen and progress toward the surface of the organ, they meet and have to overcome a greater resistance on account of the greater thickness of the tissues which they have to penetrate, particularly as these tissues are much tougher than they will be later on. While the tension and stretching of the ovarial stroma is apparently marked, the uterine hemorrhage which tends to diminish the hyperæmia of this organ is, on the other hand, generally slight. In course of time, with the repetition of the catamenia, sexual excitement, and other occasions of fluxion the stroma of the ovary becomes softened by transudation, follicles begin to ripen in larger number and to progress toward the surface. The resistance is decreased and menstrual pain disappears, particularly when hemorrhage becomes profuse.

In the case reported, the possibility of an ætiologic influence of systemic disorders — such as Bright's, diabetes, pernicious anæmia or cardiac disease — was excluded by the negative physical examination and, to a certain extent, by the fact that absolutely no disorder of vision had been observed until the time of the menstruation.

The unilateral appearance and course speak against systemic disease of the usual sort, as renal disease rarely produces such marked changes as copious hemorrhages, detachment, etc., until after cardiac complications have become manifest, in which

*Menstruation v. Dysmenorrhœa, Volkmann's Hefte, No. 81.

event they are generally bilateral; whereas in my case the other eye has remained perfectly well up to the present time. It is to be noted that, as in Powers's case, the result of energetic treatment was practically nil, and the question arises whether other treatment would have been followed by a cure.

Restoration of normal menstruation, the reëstablishment of the physiological safety valve, as it were, offers the only rational cure, and that is not always possible. Fortunately, nature herself often finds a means to this end. In our case the spontaneous cure took place only after irreparable damage had been done to the eye. This being so, the prophylactic point of view remains as the important one, and that from which some results may be expected. Knowing that the organism at puberty is particularly susceptible to injurious influences, — that the first menstruation with its molimina represents a critical stage, — that vicarious hemorrhages may supplant it, and that those affecting the retina and the vitreous are by no means trifling, but may lead to complete loss of sight; knowing, further, that mental exertion has a twofold deleterious influence, in that, like physical overwork, it suppresses and tends to retard the menses, while it implies near work, and often a vicious posture in school children, with the inevitable result of eye-strain, congestion, and tendency to intraocular hemorrhage, and that all physical strain adds to these dangers, we should insist on a reduction to a minimum of school work, at least during the month or two in which normal menstruation is established, and absolute cessation of gymnastic or other violent exercise at this time.

DISCUSSION.

Dr. Pooley. — I want to express my very keen appreciation of the value of Dr. Fridenberg's drawings. It seems to me that any communication, no matter how carefully written, has its value enhanced by such illustrations and I hope these drawings may be included with the publication in the transactions.

THE CORRECTION OF SIXTEEN DIOPTERS OF ASTIGMATISM BY MEANS OF THE GALVANO CAUTERY.

BY C. F. CLARK, M.D.,
COLUMBUS, OHIO.

In the case which I present for your consideration an astigmatism of twenty-two diopters with uncorrected vision only sufficient to enable the patient to count fingers at four meters was reduced by means of the galvano cautery to about six diopters, and this latter correction brought the vision up to normal.

The case is of interest as a study of one of the phases of acquired astigmatism and, while perhaps suggestive of what may be practically accomplished in the modification of astigmatism in the rare instances which would justify resort to such a method of treatment, is reported somewhat in detail merely as an illustration of the change of form which may be effected in the cornea as a result of the contraction of a concentric linear cicatrix. In post operative astigmatism, such as is often seen after cataract extraction, we also have cicatrization tending to correct the error in the corneal curvature which is noted during the first few weeks after operation; but the degree of the deviation from normal after cataract extraction, even when the incision is located well within the cornea, is far less than that which occurred in the following case.

Mr. E. M. T., 42, a locomotive engineer, who was, as far as could be learned, free from other disease, consulted me on June 21, 1900, on account of gradual failure of vision which he said had made its appearance in association with, and apparently as a result of a peculiar, grayish-white, groove-like line of what appeared to be calcareous degeneration in the superior segment of the left cornea. This line was about two millimeters in width, quite uniform in its outline, parallel with and about three millimeters from the corneal margin and was almost a complete

semicircle. The edge of the groove on the side toward the center of the cornea was slightly elevated as compared with the peripheral edge. The whole seemed to be covered with epithelium but to have in its depth a grayish substance which suggested calcareous degeneration. There was no injection nor pain, nor did it, on close inspection, though somewhat similarly situated, present the appearance of an arcus senilis. Its outlines, both on its edges and at the ends, were quite sharply defined and its general appearance strongly resembled that of a groove-like marginal ulcer, the depth of which had been filled in by a grayish deposit which was covered with epithelium. That there had been no active ulceration, however, was apparent, and the patient did not complain of the slightest irritation or discomfort. Other portions of the cornea were clear and transparent and all other parts of the eye seemed perfectly normal, there being nothing in the history of the case to indicate that there had ever been any active inflammatory process, and the patient stated that the vision had formerly been good, and he had successfully passed examinations as a locomotive engineer.

There was an obscure history of a cinder having lodged in the eye some six years before he reported for treatment, but no causative relation between this and the formation of the groove could be traced, though from that time he noticed gradually increasing failure of vision in the affected eye, and for a year or more he had been conscious of the existence of a small narrow groove about five millimeters long, of the same character, and occupying a corresponding position in the superior nasal quadrant of the right cornea. This also seemed to be slightly increasing.*

* In discussing the above-described case with my associate, Dr. W. K. Rogers, and considering the advisability of cauterization, he mentioned the fact that he had quite recently written a review for the Journal of Ear, Nose, and Throat Diseases, for Jan. and Feb., 1900, of what appeared to be a very similar case reported in the Recuille d'Ophthalmologie, for Dec., 1899, by Rochon-Duigneaud, which was termed by that writer, "symmetrical marginal dystrophy of both corneæ with consecutive regular astigmatism, overcome by actual cautery."

To Rochon-Duigneaud, therefore, so far as I can learn, belongs the credit of first applying this means in the reduction of excessive astigmatism.

"The disorder occupied the superior segment of each corneal limbus and was characterized by infiltration hyperplasia deposits, having a calcareous appearance and points

While recognizing the fact that the vision of his left eye was very defective and gradually becoming worse, the patient, having been told some three years before by one of the oculists of the company for which he was working that nothing could be done for him, had despaired of obtaining relief though he was willing to resort to any treatment or submit to any operation that offered promise of improvement.

The vision, on the occasion of his first visit, was R.E. 5/5, accepting no glass. L.E., fingers counted at about 4 meters —8 cyl. axis 85° ⊃ +4 cyl. axis 175° gave V. 5/12. The ophthalmometer revealed in the right eye: 0.25D. axis 175°, and in the left 22.5D. axis 175°. The readings being as follows: Right eye at 85° :: 23D. at 175° :: 23.25D. Left eye, 85° :: 12.5D. at 175° ::35D.

If we assume the normal corneal refraction for the left eye to be the same as the right, 23D., the refraction of the vertical meridian was deficient by 10.5D., and the horizontal meridian excessive by 12D.; or, if we compare the refraction of the two meridians by comparing the radii of curvature expressed in millimeters, as read from the Javal scale, the right eye had a radius of about 7.85 mm. in the vertical, and 7.8 mm. in the horizontal meridian, while the left eye had about 10.4 mm. in the vertical, and 6.13 mm. in the horizontal meridian.

The groove, which lay about 3 mm. from the corneal margin, was quite symmetrical in form and parallel to the limbus, and the astigmatism appeared to be quite regular when measured in the center of the cornea.

It has seemed to me that the action of the cornea in such a case as this is similar to that noted after cataract extraction before the wound has firmly cicatrized, namely: There is a tendency to

---

resembling ulcers but which did not react to fluorescine. No cause could be assigned. Other tissues were normal, and visual disturbances were attributed solely to consecutive astigmatism. Eleven diopters in the worse eye and one and five-tenths in the other. Terrien failed to find any similar case.

"Six applications of the galvano cautery were made to the worse eye, resulting in a reduction of eleven diopters mixed astigmatism to one diopter simple astigmatism. The vision equaled 1/3."

In the Klinische Monatsblätter fur Augenheilkunde, Oct., 1899, there is a review of the results obtained in reducing corneal astigmatism by means of incisions.

flatten in the vertical meridian, which action naturally tends to shorten the arc of curvature in the horizontal meridian.

I would call attention at this point to the interesting fact that, while the degree of deviation from the normal curvature was far greater in this case than in a slowly cicatrizing cataract wound, the lesion did not appear to involve the internal elastic layer of the cornea, which, of course, is involved in the cataract section; tending to prove that the layer of Bowman (with, perhaps, the substance proper of the cornea), but especially Bowman's layer, is the most important factor in maintaining the true curvature of the cornea. This has, I think, generally been conceded, but I have seen little evidence that was based on a demonstration.

As nothing short of operative interference offered any hope of relief, I advised curettement and the application of the galvano-cautery to the corneal grooves, and this was undertaken on June 15, 1900. The grooves were thoroughly curetted and, as the galvano-cautery was found to be out of order, I used pure carbolic acid. Within a few days, under the influence of ice applications, the reaction had subsided, and on June 27th a measurement with the ophthalmometer revealed a reduction of three diopters in the astigmatism.

Javal, R. about as above.

L. at 90° : :14.5D., at 180° : :33.5D.=19.D.

The patient returned to the hospital and on the afternoon of the twelfth day after the first cauterization both grooves were, under the influence of cocaine, thoroughly cauterized with the platinum point brought to a cherry red.

Ice applications were used, followed after a few days by hot fomentations, and recovery was rapid and uneventful.

On July 12th, fifteen days after the operation, only slight injection was to be noted and the astigmatism was found to have been reduced 16.25D., while vision had correspondingly increased so that with : —4 cyl. axis 85° ⌣ +2 cyl. axis 5° V.= 5/9.

Javal, R. about as above.

L. at 85° : 22.25D., at 5° : 28.5D.= 6.25D.

The cornea at this time was still slightly striated.

On June 24th, examination with the ophthalmometer revealed a very low degree of slightly irregular astigmatism in the right eye:

Javal, R. at 85° : :23.75D., at 65° : :24.5 =.75D.
L. at 90° : :22.75D., at 180° : :28.75D. =6 D.

The slight striation of the cornea had now cleared and vision had correspondingly improved.

V. R. 6/6.
L. 6/50 —6.c. axis 75° = 6/6—.

On September 8, 1900, three months after operation, a slight increase in the astigmatism was noted in the left eye, while in the right vision was normal without a correcting lens.

V. R. 5/5+ unimproved by glass.
L. —7.c. axis 75° ⊃ +2.5 c. axis 165° = 5/5—.

On March 16, 1901, nine months after the operation, there had been no further change in the refraction and vision in each eye was 5/4—.

From the above it will be seen that, as a result of the contraction of cicatricial tissue following cauterization in a semicircle parallel with the limbus which extended, perhaps, to a depth of one-half the thickness of the cornea, the curvature of the vertical meridian was increased from 12.5D., with a radius of 10.4 mm., to 22.75D., with a radius of 7.9 mm., which, if we may judge by the fellow eye, is practically the normal curvature. The curvature of the horizontal meridian, on the other hand, was reduced from 35D. with a radius of 6.13 mm. to 28.75D., with a radius of 6.95 mm.; this being an increase in the vertical meridian of 10.25D. and a decrease in the horizontal meridian of 6.25 D.

While these figures reveal an increase in the refraction in the vertical meridian and a decrease in the horizontal, the two effects do not balance one another and the total effect is an increase in the average refraction of the cornea.

By adding the refraction in the vertical meridian expressed in diopters to that of the horizontal, and dividing by two, we may be said to obtain the average refraction of the two meridians.

The sum of the refraction of the two meridians: 12.5+35.=47.5; this divided by two gives us the average refraction before operation as: 23.75D., not greatly in excess of the average refraction of the fellow eye which may be said to be normal.

After cicatricial contraction had ceased, the sum of the refraction in the two meridians, 22.75+28.75=51.50, which, divided by two, gives as the average refraction after operation: 25.75D., an increase of two diopters.

A CASE OF ACUTE PANOPHTHALMITIS FOLLOWING DISCISSION OF THE CAPSULE.

By LEWIS H. TAYLOR, M.D.,
Wilkes-Barre, Pa.

It is always interesting and perhaps instructive to present to a scientific body like this a report of successful cases in practice. It is not so interesting, however, and requires much more courage, to report cases of failures, especially if there be a lingering suspicion in the mind of the operator that he is in some way responsible for such failure.

But we learn from our disasters as well as from our successes, and, believing the former should be noted as well as the latter, I desire to present briefly to the Society the history of a case of panophthalmitis following opening of the capsule, that has very recently fallen to my lot.

W. J., aet. 36, a discharged soldier, came under my care on November 1, 1899, with the statement that the right eye had been struck at Fortress Monroe in December, 1898, "by powder, or something that flew back" when he fired a rifle.

The right eye showed fairly well developed cataract, but not fully mature. In the left the lens was clear but fundus somewhat cloudy. The left selected +1.50 cy. axis 150° against, making V. 20/XXX; the right selected no glass. I did not see him again until Oct. 8, 1901, when he came for special pension examination

with a history of suspected venereal trouble. Vision had now fallen to mere waving hand in the right and to 20/CC in the left. The right had well developed cataract. On Nov. 15, 1901, I operated on the right eye, which healed readily and he left the hospital at the end of twelve days.

There were no complications whatever either in the operation or subsequent healing, but the best vision obtainable was 20/C.

He came to me a year later, Oct. 1902, with cataract fairly well developed in the left eye also, but I thought possibly not fully hard. I delayed operation until March 14, 1903, when I extracted the cataract from the left eye. It was not fully mature and a little lens substance remained, but this cleared up and on March 21 the vision in this eye was 20/CC. On April 28, 1903, about six weeks after the cataract operation, I operated in my office on the capsule. This was done in the usual way under cocaine anæsthesia, using a Knapp knife needle. I have done this operation frequently in my office and never before with any unpleasant results. On this occasion I sterilized all instruments myself, with usual care, by boiling. I even sterilized the cocaine and the dropper with which it was instilled. I applied a compress bandage and the patient went to his home. The next day to my surprise the lashes were adherent with a muco-purulent discharge and the cornea quite cloudy. Two days later, on May 1, the cornea was completely yellow, anterior chamber full of lymph and the iris could not be seen at all. I applied silver nitrate to the lids, gave mercury internally, and ordered frequent irrigation with boracic acid solution. The following day I sent him to the hospital and continued irrigation every hour, the eye being greatly swollen and painful and all vision gone.

On May 3, the eye was enormously swollen, tension greatly increased, and it had the general appearance of panophthalmitis from gonorrhœal ophthalmia.

I told him I would probably have to enucleate and he was sensible enough to accept the inevitable philosophically. On May 5th, seven days after the discission, the condition was such that enucleation was unavoidable and under ether the eye was

removed. Notwithstanding the very bad condition the patient was doing very well when I left home a few days ago. Your natural criticism of this case would be, that I failed at some point in the technique. I had, of course, heard of serious results following this simple operation, but I always thought they were unnecessary, and I confess the result in this case was a great surprise and shock to me. And looking back upon it I do not yet see at what point my technique was at fault.

DISCUSSION.

DR. MATTHEWSON. — I had an experience somewhat similar, some years ago, and without any reason therefor that I could ever determine.

DR. BRUNS. — I think I can say a word that may be of some consolation to Dr. Taylor, because a similar accident occurred to me, but checked itself up on the question of technique. I had been operating upon a child for congenital cataracts, and as the parents were poor and lived some distance away, when the child was brought to the city for the second eye to be operated upon, I broke my rule and cut the capsular membrane of the first eye at this same visit. The second eye was lost by panophthalmitis, although operated upon with the same needle that I had just used to cut the capsule of the first eye, without so much as laying it down for a moment. The parents were sensible enough to understand the unavoidable nature of the calamity.

DR. KNAPP. — Those who do any work in laboratories know that they must always be perfectly sure of the sterilization, not only of the needle, but of the point of entrance for their needles, and we must remember that there may be on the cornea, at the point of entrance for the needle, some pathogenic germs which are liable to be carried in by a clean needle. I have made hundreds and hundreds of needle operations without one infection that I know of, but I know well that my next discission may be followed by that complication.

DR. RISLEY. — I believe that in my experience the infection that has occurred has begun almost invariably at the point of entrance of the needle.

DR. JACKSON. — There is one thing that ought to be mentioned in connection with such an accident, although it may have no

bearing on this particular case, and that is that the entrance of the needle through vascular tissue greatly lessens the danger of such infection. I have for years been entering the needle through the vascular margin of the limbus, pretty well back. I noticed that someone recently reported something like 250 cases where this operation was done without any serious infection. We may get some, even free, bleeding by going through the limbus, but that does no harm.

DR. THEOBALD. — I think we ought to remember another thing in connection with this case of Dr. Taylor; and I have one similar experience, and that is, that we may have an auto-infection and that the trouble is not always a matter of the entrance of germs from the outside.

DR. WILDER. — I would like to mention an experience I had some years ago in which a nurse had apparently failed to sterilize the instruments. The case was one of congenital cataract in a child, and within twelve hours after the operation of needling I could see a distinct line of infection just such as you get in a stab culture of agar in the laboratory. A vigorous use of bichloride solution checked the inflammation. I think in many of these cases we do not have ourselves to blame, for infection may occur even though we make the most thorough efforts to sterilize the instruments and field.

DR. CLARK. — I have been strongly impressed with the fact that an eye which suggests the presence of any form of inflammation, such as glaucoma, iritis, etc., is much more dangerous for a secondary operation than for the primary extraction. I just had in charge the case of a young man with a cataract such as I have at times refused to operate upon, but which in this instance I operated upon successfully, where there was some anterior uveitis producing a deposit upon the posterior surface of the cornea. Later I divided the membrane at his request and in a few days he developed glaucoma with a little clouding that suggested the idea of infection, but which yielded to eserin. This strongly inclined me to the view that a secondary operation in such a case, in which the wound is firmly closed, stirs up trouble in an eye that cannot resist the tendency to glaucoma as well as it did at the first operation, in which the wound does not close so quickly.

DR. KOLLOCK. — I dislike to ask Dr. Taylor, lest it might seem to imply that his technique was not right, but I think we

must consider whether the passage from the lachrymal sac may not have been overlooked. One may have an œzena without any apparent discharge from the sac, but which would still be a source of danger to the operation.

DR. LIPPINCOTT. — Some of these cases of infection, in my judgment, come from the nose, and that is the reason we cannot sterilize the conjunctiva; because we do not close the puncta. If the puncta be closed by an ointment of bichloride of mercury, melted and dropped into the eye immediately after the operation, the canaliculi are closed, and the entrance of germs from the nasal cavities is prevented, and my experience teaches me that this is a very valuable means of preventing infection in any case in which the eyeball is to be opened.

DR. TAYLOR. — In this case I thoroughly sterilized as I always do, the patient had no œzena, and I had operated on him on each eye for cataract with good results. He was not a well-nourished patient, however, and was suspected of having a venereal taint.

ABOUT SKIN-GRAFTING IN OPHTHALMIC SURGERY.

BY F. BULLER, M.D.,
MONTREAL, CAN.

We all know that ophthalmic surgery presents many opportunities for the useful application of skin-grafting in both mucous and cutaneous surfaces, and that our work in this field necessitates extreme accuracy in order to insure reasonably good results. In any event, it will be conceded that upon this subject the last word has not been said. It is often desirable, I may say, indispensable, that we employ as much of the skin texture as possible in order to minimize the tendency to subsequent shrinking and loss of pliability. This is a totally different matter to the mere restoration of epithelium to a wide denuded surface, which may be accomplished by the use of extremely thin shavings from the skin surface, or even by scrapings from the same, but for such a purpose ophthalmic surgery has no use, since there is always a necessity for the transference of skin of substantial quality and thick-

ness. This necessity carries with it all the elements of failure just in proportion to the size and thickness of the graft; we cannot, however, afford anything less than complete success at the first attempt, because the parts are not likely ever again to be in a condition so favorable for obtaining a perfect result as they are the first time the operation is performed.

By complete success I mean re-covering of entire raw surface with integument which unites immediately and permanently without the slightest flaw or loss. Judging from the published records of such work the difficulties in the way of obtaining satisfactory results are very great and failures have been many. The causes of failure may be summarized as follows: (1) The size and thickness of the graft may be so great that it fails to become nourished sufficiently and so perishes through lack of vitalizing power. (2) Imperfect coaptation, so that some part of the new skin fails to secure nourishment. (3) An imperfectly prepared surface, especially as to arrest of bleeding. (4) The parts may not be sufficiently aseptic. (5) Accidents or injury before healing is well advanced. Failure from the first of these causes can fairly be attributed to an error of judgment on the part of the operator; failure from the third and fourth implies an error in technique; from the fifth, a want of proper care in the after treatment. There remains for consideration only No. 2, and this is by far the most important of all. The problem to be solved is How can perfect coaptation best be secured? In this connection the fact must be recognized that every skin-graft consisting of more than mere epithelial shaving, tends to roll in upon itself towards the cut surface. This tendency cannot be controlled by merely laying the graft upon a raw surface, nor can it be perfectly overcome by fastening the graft in its place with stitches, since the intervening portions between each stitch will continue to turn inwards. Now this unfortunate tendency becomes a fatal obstacle to union at the edges of the graft, and in addition a sort of sulcus is formed in which fluid exudate collects and readily becomes septic, besides separating the graft more from its base and source of nourishment. In order to overcome the difficulties aris-

ing from this peculiarity of the skin, I sought for some means to make it stay in position with an absolutely perfect spread throughout. For this purpose I found ordinary silk isinglass plaster entirely satisfactory; some experience is required in order to secure the maximum adhesive quality of the plaster just at the right moment. I find it best to have the plaster cut in convenient strips, a certain area of which is carefully moistened just enough to make it very sticky, then the graft, cut as nearly as may be to the size required, is transferred dry from the razor with its epithelial surface on the plaster, then with a silver curette it is stroked and spread until completely adherent. When this is done, both skin and plaster may be trimmed with sharp, straight scissors exactly to the size and shape desired. If the surface be large it may be covered by several neatly trimmed pieces of skin prepared in this way. Over the whole I next place a piece of cargile membrane, dust with finely powdered iodoform, pad with cotton wool in such a way to secure gentle but tolerably firm and uniform pressure. Skin-grafts applied in this way, after Thiersch's method, even when large, do not fail; they all survive and adhere perfectly to the surface, this, too, when applied where mucous secretions may be present and would otherwise lead to infection and destruction of the graft. There are two distinct classes of cases in which skin-grafting is required in ophthalmic surgery: The first of these, and by far the more common, is where the skin of the eyelids is deficient and the defect may best be repaired in this way, that is to say when sliding flaps are not available; the second is where the conjunctiva is at fault and requires to be repaired by some sort of integument, either skin or mucous membrane. Such a requirement occurs in certain cases of traumatic origin in which the palpebral and ocular portions have become adherent, and also in cicatricial contraction of the conjunctival sac, such as takes place from persistent wearing of an artificial eye, long after it has become roughened by continued use. The method is applicable in all cases suitable for this form of plastic surgery. There are one or two points in regard to preparing the surface to be grafted upon that invite further remarks. In

the first place, it is entirely essential that all bleeding has ceased before the grafts are applied; strict asepsis at every step is also indispensable. Then again, the surface should be put upon the stretch if need be by sutures through adjacent parts which may be attached to adhesive plaster on the surrounding surface, an arrangement, of course, of a temporary character; for instance, in repairing contractions of the empty conjunctival sac, it may be necessary to do a canthotomy at the outer canthus, and draw the loosened lids strongly upwards and downwards by sutures passed through them and attached as indicated. Lastly, when the grafts are in place great care is necessary in applying a bandage with the double purpose of protection and of making gentle and uniform pressure so as to prevent the hemorrhage of reaction.

There is nothing in ophthalmic surgery, at least in the writer's experience, more gratifying than the perfect results obtainable from skin-grafting carried out in the manner just described.

A CASE OF LEUCO-SARCOMA OF THE CHOROID.

By THOMAS R. POOLEY, M.D.,
New York City.

This case is reported because of the comparative rarity of non-pigmented sarcoma of the choroid, as well as on account of some points of interest in its clinical history and anatomical findings.

The patient, a man aged thirty-five, came under my care on December 12, 1902, in my clinical practice. He was possessed of very limited intelligence and could give but little account of his symptoms. About three weeks before I saw him he thought he had gotten something in his left eye, and, as his eye continued irritable, and he found that he could not see with it, he applied for treatment. He did not complain of severe pain in the eye at any time, and is sure that before the time referred to he saw very well with it.

When I examined him, this eye showed the typical features of absolute glaucoma: Circumcorneal injection of a venous charac-

ter, hazy cornea, wide, immovable pupil, shallow anterior chamber, anæsthesia of the cornea, +T 3; entire absence of reflex with ophthalmoscope, and no perception of light. I made the diagnosis of absolute glaucoma, probably caused by tumor of the choroid, and thought enucleation should be done forthwith. Yielding, however, to the opinion of several of my colleagues, that it might be primary acute glaucoma, or due to a hemorrhage, I consented to first try iridectomy, which operation I did the same day. The operation, with the patient under ether, was successfully accomplished and resulted in a large coloboma; the anterior chamber, however, immediately filled with blood.

On December 14th there was some diminution in the tension of the eye, but hardly any absorption of the blood. By December 17th, however, the blood in the anterior chamber was diminished, when, on the 18th, a fresh hemorrhage took place nearly filling the anterior chamber and accompanied by pain and increased tension. There was again an attempt by nature to absorb the blood, but fresh hemorrhage always took place, and, on January 3, 1903, I got the patient to consent to enucleation of the eye, which was done without any mishap, and, because of my belief that there was a tumor, I divided the optic nerve as far back in the orbit as I could. The healing was uneventful and the patient was discharged a few days later.

After being hardened in 10 per cent. formalin for a week, the eye was examined by Dr. Edward B. Colburn, pathologist of the New Amsterdam Eye and Ear Hospital, whose report is as follows:

Macroscopically. — Shallow anterior chamber. Iris atrophic, with coloboma (from iridectomy) upward and adherent to the lens capsule. Lens appears swollen as though forced into the space of the coloboma. The retina is detached and extends like a flattened cord from the optic nerve to the posterior surface of the lens. One side of this retinal cord is attached to the apex of the tumor. The tumor lies between the detached retina and the sclera and arises from the choroid in its postero-temporal portion, about on a level with the external rectus muscle and just behind the

Photograph of horizontal section of leucor sarcoma of choroid, made by DR. E. B. COBURN. *a*, two portions of tumor connected by a constricted part of the tumor.

equator. The tumor presents two parts — a flattened, somewhat extended portion, about 1 cm. wide and about 2 mm. high, connected by a narrow constricted portion, about 4 mm. wide, to a spherical part, about 7½ mm. high and 9 mm. wide, lying in the vitreous. The tumor is white in appearance, with only a few blood vessels and small pigment spots visible.

Microscopically. — The conjunctiva is congested and slightly infiltrated.

The cornea is apparently normal.

The anterior chamber is practically abolished, only a small layer of blood cells lying between the iris and the cornea.

The iris is thin and atrophic.

The angles of the anterior chamber are closed, the iris being adherent to the cornea at its periphery.

The lens capsule shows pigment spots on its anterior surface. Beneath the capsule there is some albuminous fluid and there is a breaking down of the lens fibres in a few places, indicating an incipient cataractous change.

The ciliary processes are attenuated and dragged forward with the lens, on one side being compressed between the lens and the iris.

The retina is a flattened, cone-shaped mass extending from the optic nerve head to the posterior surface of the lens and continuing around to its attachment at the ora serrata. The retina is disorganized in the manner common to retinas detached in this manner.

Only a small portion of the tumor appears in the sections and that is taken from the side of the spherical portion lying in the vitreous. This consists of small round cells, with a slight amount of intercellular substance. The blood vessels, which are small, have walls of a single layer of cells. A few pigment granules and pigmented cells appear in the peripheral portion of the tumor. The flattened part of the tumor between the lamina vitrea and the sclera does not appear in the sections.

Diagnosis. — Small, round-celled leuco-sarcoma of the choroid.

Remarks. — The flattened part of the tumor is probably caused by the resistance of the lamina vitrea on the one side and the sclera on the other. At one point the lamina vitrea had yielded and through the perforation the tumor has grown unrestricted in the vitreous, assuming the spherical form. The constriction is caused by the non-yielding character of the lamina vitrea as compared with the looser and less resistant character of the choroid and retina. The vitreous lies between the retina and the choroid, and an interesting question arises how the vitreous assumes this position — whether it is filtered through the gradually contracting and detached retina or whether it passes through a rent in the retina.

It is not my purpose to go into the literature of these tumors, for which I have neither time nor desire; I may, however, say that according to Griffith in his chapter on Diseases of the Choroid in the Norris-Oliver System, non-pigmented sarcoma is said to be more frequent in the younger patients, and in the middle or anterior parts of the choroid; which, so far as age is concerned, is confirmed by our case, but the growth developed from the posterior temporal portion of the choroid. The proportion of cases of leuco-sarcoma, according to the same author, is one for every ten or fifteen of the pigmented variety.

Although the case presented the usual appearance of final glaucoma, yet according to the patient's statement, there had been only slight pain, not of the severe kind usually associated with acute glaucoma. When increase of tension exists with retinal detachment, with the eye in a state of acute glaucoma and there is no translucency, there need be no longer as a rule any hesitation in pronouncing the case one of choroidal tumor, and such, indeed, was my diagnosis notwithstanding that I first made an iridectomy. That this course is open to criticism I freely admit, for, while iridectomy is strongly indicated in acute primary glaucoma, it is objectionable in choroidal sarcoma, because it delays the enucleation and may give rise to infection of the neighboring tissues. Griffith (*l. c.*) gives some important differential symptoms between glaucoma due to an intraocular growth and the primary form,

i. e., the sight is lost for a considerable time before the acute symptoms set in, and further that the prodromi usual in primary glaucoma are often wanting. Another very important point in the differential diagnosis is that there are no remissions in the symptoms, such as we see in primary glaucoma. Retinal hemorrhage is sometimes quickly followed by glaucoma, and if this occurs with a large blood clot may lead to an erroneous diagnosis. Such a case is recorded by Griffith (*l. c.*) and Webster reports a similar experience. It is interesting to observe, as suggested by the case reported, that the size of the tumor does not seem to be the most important factor in awakening a glaucomatous attack, but rather the changes to which it gives rise in the other tissues of the eye, especially of serous effusion, causing not only detachment of the retina but crowding it close to the posterior surface of the lens, the angles of the iris being obliterated and the iris adherent to the cornea at its periphery. This serous effusion seems to be an almost constant accompaniment of choroidal tumor.

DISCUSSION.

DR. MARPLE. — In regard to the statement of Griffith, just quoted by Dr. Pooley, as to the location of the neoplasm and age of the patients, I simply want to say that I saw one case last year in which the leuco-sarcoma was only about one or two papilla diameters from the papilla, that is in the posterior segment of the eye, and the patient was only about 35 years of age.

TUBERCULOSIS OF THE EYE — TWO CASES: ONE AT THE HEAD OF THE OPTIC NERVE, THE OTHER AT THE EQUATOR.

BY J. A. SPALDING, M.D.,
PORTLAND, ME.

Case 1. A. B., a healthy boy of eight years, with a family history free from tuberculosis, fell from an express wagon twelve weeks before I saw him, hitting his head and elbow, but escaping without any serious injury. He limped about for a day or two,

but nothing more was heard of the accident. Four weeks later on he fell again, this time from the high seat of a water-sprinkling cart, but on being brought home had no recollection of hitting either his head or his eye. There was no visible scar anywhere about his head. Two days later, after his second fall, and without any intervening symptoms, he was suddenly seized with an intense chill, headache, pain in the left temple, and vomiting. His temperature arose that afternoon to 104 degrees and his pulse to 103. This condition persisted about one week; that is to say, the temperature was abnormal every morning at 8 o'clock, while every afternoon about 6 it rose quite suddenly to 101° or 102°, while his pulse remained about 120, day in and day out. He was totally unconscious for a period of twenty-four hours, directly after the first chill. When he regained consciousness he complained of constant pain in the left temple and right cervical region and occasionally in the right temple. His head was drawn backward noticeably on the sixth day and remained so for several weeks; his throat was dry nearly all the time. He was constantly dull and apathetic despite the alleged violent pain. When roused he would complain of pain all over his head. He did not vomit again, except once, some days later, after drinking copiously of water during a feverish attack in the evening.

The medical men in attendance during this time — and there were several called in consultation — could not agree on a diagnosis. One suggested scarlatina, on account of a suspicious rash; another typhoid, on account of pain in the back and evening rise in temperature; a third diagnosticated meningitis, owing to the localized pain over the head and constipation. No positive diagnosis could be made.

At this time ten days had elapsed since the first unconsciousness, when the parents one morning observed in the pupil of the left eye a yellowish reflex, with an apparent reduction in size, total loss of sight when the right eye was covered, and intense redness of the eyeball. As none of the physicians had observed these symptoms before, it is probable that they must have developed suddenly on the day stated; moreover the upper lid began to swell

and renewed pain was complained of, localized chiefly in the left eye and orbit.

After a few days more, all of this train of local and special symptoms decreased in intensity; the temperature fell to and remained nearly normal, the pulse remained at about 100, the inflammation in the eye decreased in severity, and the general bodily condition improved for a period estimated by the parents at about one week. Suddenly a second chill ensued with a recurrence of all the symptoms as before, as to temperature and pulse, but without any nausea, and without increased ocular symptoms, although the reflex from the eye remained the same and was easily seen by inspection on placing the boy in a good light.

This condition lasting, without much change, the boy was brought to Portland at the end of seven weeks after the second fall.

Present state: Well nourished child, dull and somnolent, paying no attention to inquiries except temporarily when roused. Right eye normal; left eye smaller than normal, soft, painful to the touch, circumcorneal injection, dense circular iritic adhesions, iris discolored, media sufficiently clear to see the retinal vessels arising above a yellowish tumor in the interior of the eye.

Diagnosis was made of probable purulent meningitis or else of a glioma of the retina. Advice, enucleation of the eye. The patient had a pulse of 80 in the morning, 100 to 110 at night; temperature, A. M., subnormal, 96.6° to 97.5°,=100° to 102.5° in the afternoon.

After several days of hesitation, the parents consented to removal of the eye, although, to tell the truth, none of us (and again several physicians saw this patient in consultation) could make anything definite of the curious condition, nor did anyone believe that the operation would do more than to relieve the local pain in the eye.

Enucleation was finally performed with the surprising result that every symptom ceased as if by magic, and by the time that the patient recovered from the ether-narcosis he was, practically speaking, cured. The temperature and pulse became normal,

the pain in the head ceased and he went home in a few days. Later he reported for an artificial eye, has worn one ever since, and for more than four years has had no trouble whatsoever.

Macroscopically, the globe and cornea are smaller than normal; lens partly absorbed, vitreous fluid and dirty colored; retina shows a funnel-shaped detachment, and the vitreous chamber is one-third filled with a moderately firm yellowish tumor arising from the optic papilla, but more from the outer circumference all around than from the center of the nerve.

Microscopically, the tumor consists of a large amount of necrotic tissue, small-cell infiltration mingled with giant cells characteristic of tubercular construction throughout. Staining for tubercle bacilli was positive. There was also noticed small-cell infiltration along the sheath of the optic nerve so far as it remained attached to the globe.

How any such fall as this patient suffered could produce the set of symptoms described, or why these symptoms should excite the presence of tuberculosis inside the eye of a healthy boy with no tuberculous history, or whether the fall had anything at all to do with the formation, must always remain enigmatical.

Ehrenroth, however, has shown by his experiments on rabbits that a blow on the head of one predisposes to infection of the brain membranes when bacterial cultures had previously been injected intravenously. The temporary traumatic hyperæmia, venous obstruction and hemorrhages in the brain membranes from the blow on the head are essential to the experimental infection. If this boy had any focus of infection beforehand, the injury might have excited traumatic meningitis, whereupon the infection of the eye could have taken place along the meninges and optic nerve sheath. Still, all is conjectural.

Case 2. A puny boy of seven with a father who, as a child, was weak and puny up to the age of 18, but who by the age of 40 was a vigorous man without any tuberculous family history, was brought to me in February last. This child, at the age of two weeks, or possibly before, had a severe attack of double infantile ophthalmia, terminating in the loss of sight in the left

eye, the right eye remaining normal. On examination I found the right eye healthy in every respect; the left eye was larger than its fellow, with circumcorneal injection first observed that morning on awakening, slight pain, a dense leucoma of the entire cornea, no vision of any sort, tender to the touch but tension normal. A weak eye lotion of two per cent. boric acid was prescribed and in a week the eye seemed well again. While considering the advisability of tattooing the leucoma, a second attack of pain and congestion set in suddenly in the left eye as before. As this did not yield to the same treatment that had been used before, or to various other remedies, and as additionally the right eye began to show symptoms of sympathetic irritation, and a visible hyperæmia of the papilla, enucleation was advised. However, to save the eye for a possible tattooing, which is so eminently proper in many a case in which enucleation once used to be promptly done, a delay was advised and consented to. At the end of three weeks, as there was no improvement in the left eye, and the threatening condition of the right eye did not change in the least, the left eye was removed. The result of the operation has been a constant improvement in the appearance of the boy, who, from a pale-faced weakling creature, has in a single month become lively and ruddy.

Macroscopically, the eye shows total leucoma of the cornea, traces of former iritis, lens calcareous, vitreous transparent, retina and choroid apparently normal, except as hereafter mentioned, and optic nerve entrance very pale and atrophic with the vessels very attenuated. At the equator of the eye, on the nasal side, a small nodule the size of a pea, yellowish, firm, and encapsulated in a gelatinous membrane, with the retina just beneath it.

Microscopically, the tumor was found to spring from the choroid, both this and the retina being thickened by inflammatory pressure, while the structure itself was tuberculous throughout with the same characteristics as described in the previous case, and with a positive stain for bacilli. This case was probably one of endogenous infection of the posterior chamber of the eye, the latter being a better nidus for bacillar infection than the anterior chamber, but the position of the nodule was peculiar.

Cases of this sort are very rare, but might possibly be observed more often if we took greater care to examine microscopically all tumors of every sort and size occurring within the eye. A similar case of localized tuberculosis within the eye may be found mentioned in a recent paper by Arnold Knapp in the January number of the Archives of Ophthalmology for 1903, together with a list of the few others previously reported.

TUBERCULOSIS OF THE CONJUNCTIVA.

By EDWARD JACKSON, M.D.,
Denver, Colo.

The case herewith reported illustrates certain difficulties in the diagnosis of this affection, and the accompanying water color sketches may be worthy of reproduction because there seem to be few good illustrations of the appearances the conjunctiva assumes in this disease. There is a picture by Wurdemann of one of Burnett's cases in the System of Diseases of the Eye, edited by Norris and Oliver. In the recent work of Ramsey no attempt is made to represent it. The same is true of Haab's Atlas of External Diseases of the Eye. Moreover, the appearances here represented differed materially from those reproduced by Wurdemann, and which are more commonly encountered in this condition.

E. L., aged 10 years, a girl who had previously enjoyed good health, was brought to me January 2, 1903. Six weeks previously it was noticed that her left cheek was swollen, the swelling extending down the neck. She had fever and vomiting, and was decidedly ill. Two weeks after that it was noticed that the lids of the left eye were slightly swollen, and two weeks later she was taken to an oculist of large experience, who made the diagnosis of syphilis and placed her upon the use of mercurial inunctions. Meanwhile the vomiting had ceased, the fever had diminished, and her general condition had improved so that she was thought to be in almost her ordinary health. But she had continued

Tuberculosis of the Conjunctiva. The upper figure represents the earlier; and the lower figure the later appearances.

BINNER-WELLS CO.

to lose weight, and the swelling of the neck, cheek, and lids continued about the same.

Vision was R. 4/4 mostly, L. 4/4 partly. The right eye was normal in all respects, and has so continued. There was marked swelling of the lower lid of the left eye and slight swelling of the upper. The whole cheek on that side was slightly swollen, and there was a swelling which in location and extent would be well represented by placing the child's hand spread, with the center of the palm just behind the angle of the jaw. The swelling was composed of enlarged lymphatic glands rounded out by œdema. The separate glands could be readily recognized, although they were comparatively soft.

There was very little pain or soreness either about the eye or in the swelling at the angle of the jaw. There was no photophobia or excessive lachrymation. The eyeball was free from hyperæmia. The patient was rather anæmic and was losing weight, about two pounds a week. There was no enlargement of lymphatic glands in other parts of the body, and no history or other symptoms pointing to syphilis. The family history was good, except that the mother suffered from scrofulous glands in childhood, and presented extensive scars therefrom upon her neck.

Upon everting the lids the appearances shown in Fig. 1 were exhibited. In the upper lid there was general hyperæmia and slight thickening of the conjunctiva, with numerous points like minute trachoma granules. But the surface was generally smooth. Such appearances might be presented during an acute catarrhal conjunctivitis.

The changes in the lower lid were very striking. The thickening was greater. Towards the margin of the lid there were masses like large trachoma granules and toward the retro-tarsal fold much apparently fatty, necrosed, almost white tissue. The granules when looked at closely bore some resemblance to miliary tubercles. Each had a gray translucent center with minute vessel entering it from a surrounding vascular zone. Between the granules and on the surface of the white tissue lay a slight gray,

sticky discharge. No tubercle bacilli were found in it. One week later this discharge seemed to be less.

January 16th the discharge was again examined, and upon one cover glass two typical tubercle bacilli were found, by Dr. W. C. Mitchell, city bacteriologist. After this bacilli were found repeatedly, but never more than three on one cover glass, and in about half the preparations none at all were discovered. January 17th the patient was shown at the meeting of the Colorado Ophthalmological Society.

The appearances presented changed very slowly. February 17th, it is noted, there was less swelling of the lower lid, less white on its conjunctival surface, and the granulations of the tarsal portion were smaller. By March 11th the patient had stopped losing weight and had gained a little. The swelling of the glands had diminished and the glands were firmer to touch.

April 20th. The lower lid is still less swollen. There is much less of the white, necrosed tissue on its inner surface. The granules are smaller and look more like those of trachoma. The upper lid contains a few larger granulations. Both lids continue soft. The lower lid when fully everted presents a distinct ridge formed in the sulcus between the lid and eyeball. In two cover glass preparations I found but a single tubercle bacillus. The appearances at this time are shown in Fig. 2 of the colored plate, and the individual granules are somewhat shrunken and firmer and decidedly more vascular. The patient has gained but little in weight, but seems in every other way better, although still easily tired and irritable.

The local treatment has been confined to the use of a wash of trikresol 1 to 1,500, and iodoform ointment, 25 per cent. The general treatment has been that for tuberculosis, rest, abundant food, out-door living, cod-liver oil and tonics.

The swelling of the glands was discovered two weeks before it was noticed that anything was wrong with the eye. But the condition of the lids when first examined, and their very slow change while under observation, make it certain that the conjunctival lesions had existed many weeks or perhaps months before

the swelling of the glands was noticed. It is probable that the conjunctival lesion was primary, but remained unnoticed until the invasion of the lymphatics gave rise to rather acute symptoms.

Of the diagnosis of syphilis in this case, little need be said. The lesions did not resemble syphilitic disease of any kind; and the glandular enlargement was strictly confined to the group immediately connected with the lid.

When first seen there was little reason to mistake the condition for trachoma. But at the present time there is quite a good deal of resemblance to trachoma, and such a mistake would be very likely to be made, if the glandular swelling and general condition were not taken into account. When the case was first seen and the history taken (before the lids were everted) the swelling of the lids, the swelling of the glands, and the acute sickness very strongly suggested Parinaud's conjunctivitis. The everted lids presented a picture quite different from that disease. But if they had shown the large granulation masses, frequently seen in conjunctival tuberculosis, it would have been quite impossible on first seeing the case to exclude Parinaud's conjunctivitis.

Indeed, since we are still ignorant of the cause and essential character of this last disease it might be worth while to consider the possibility that it may be a form of tuberculosis of the conjunctiva. Its monocular character, the glandular enlargement, the fever and acute general disturbance, all accord with such a supposition.

The uniformly favorable prognosis for Parinaud's conjunctivitis may be held to negative such a hypothesis. But the prognosis of conjunctival tuberculosis is by no means uniformly unfavorable, and it is quite possible that a particular form of it may usually end in recovery.

DISCUSSION.

Dr. Burnett. — I have had quite a number of cases of tuberculosis of the conjunctiva under my observation, particularly among colored children. In some I had no difficulty in finding the bacillus; in others it was not possible to find them, but that

should not militate against the diagnosis in the face of other characteristic symptoms.

As regards treatment, I have found that curettage nearly always effects a cure. In one case, that I remember particularly, at my clinic, a boy 6 or 7 years of age with deep ulceration of the upper lid extending from the edge back to the fornix and occupying about the middle third. The bacillus was found in this instance. I curetted the ulcer thoroughly and applied formalin (1 to 60) and it healed with much less deformity than I had expected. The cure of the local disease was absolute, and it remained so for three or four years, when the patient disappeared from observation.

A TYPE OF DEGENERATION INVOLVING THE CENTRAL ZONE OF THE CHOROID AND RETINA.

By EDWARD JACKSON, M.D.,
Denver, Colo.

Miss K. B., aged 35 years, is the oldest of her family. She had two brothers who died, one in infancy of diphtheria, and the other at seven years, probably of some pulmonary inflammation. She has five sisters, four of whom have good sight, one of them wearing glasses for headaches. The next to the youngest of her sisters, aged 23, has eyes like her own. Dr. Gratiot of Dubuque, Iowa, who has seen both sisters, writes that the younger is "suffering from the same condition, only more marked." No history is obtainable of other members of the family having defective sight. My patient had measles when 7 or 8 years old, the only time she ever had "chills." She never had scarlet fever, typhoid, or other serious illness, is now apparently in good health, and shows no characteristics of inherited syphilis. There was no nearer consanguinity between her parents than "third cousins."

Her sight has always been defective, and has slowly grown worse. When she came to me, August 21, 1902, she believed it had grown worse within the last year. It was then 4/40 in each eye. It certainly has not grown worse since then, and appears to be slightly improved.

DEGENERATIVE CHANGES INVOLVING THE CENTRAL ZONE OF THE CHOROID AND RETINA.

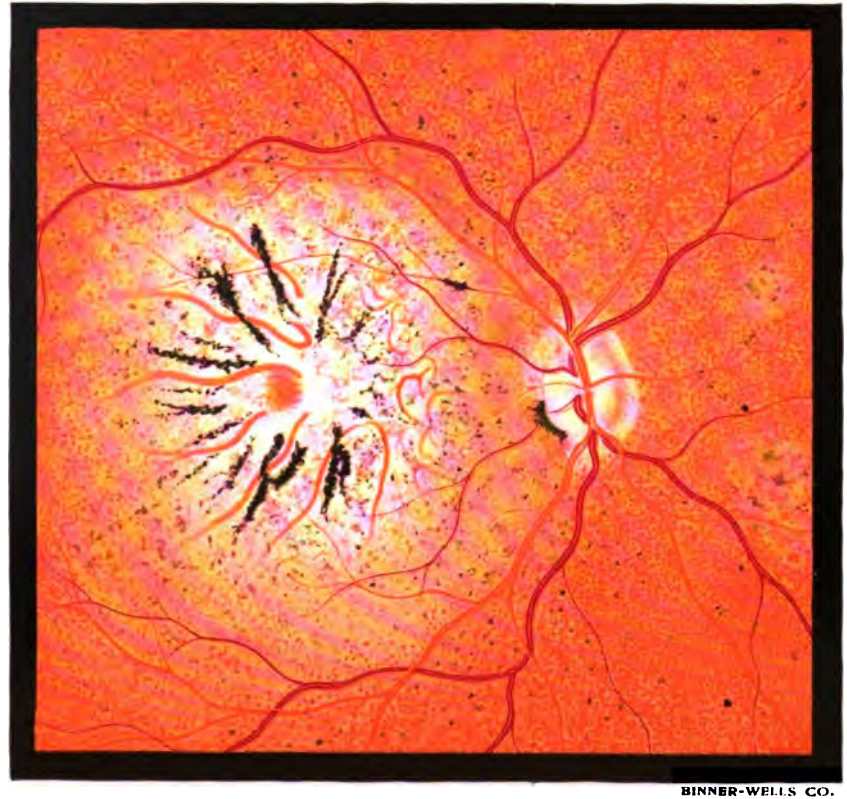

BINNER-WELLS CO.

RIGHT EYE.

Her fixation is always eccentric and quite variable. Most frequently she used the portion of the retina just to the temporal side of the disc in one eye, and to the temporal side of the scotoma in the other. There has been no night blindness. Change of illumination produces the normal change in acuteness of vision. The periphery of the field is normal in each eye. The size of the central scotoma depends on the intensity of the light used. I am not sure that the blindness is absolute at any point of the field in either eye, although it is very nearly so over an area some 20 degrees in diameter.

The ophthalmoscopic appearances are shown in the accompanying plate, which represents the fundus in the right eye. In the left eye they are similar, except not quite so extensive. The media are clear, except a few very small shreds of opacity in the posterior portion of the vitreous.

The optic discs protrude slightly, not over 1D. The margin of each is largely hidden by opaque tissue, so that the disc appears extended. This is the case in all directions in the right eye, except at the lower temporal quadrant where it is bounded by a pigment crescent. There is no appearance of choking of the disc. The retinal vessels are rather small, but not narrower than in many normal eyes.

The whole central portion of the fundus shows choroidal atrophy, and disturbance of pigmentation, shading gradually from complete atrophy at the center to practically normal fundus at the periphery. There are large pigment patches near the center, and minute brown specks are found throughout the fundus. There is no appearance of the atrophic patch having been formed by a coalescing of smaller diseased areas. Of the pigment blotches some lie in front of the retinal vessels, while others, including the largest ones, are as deep as the choroidal vessels. The distribution of the larger pigment patches, radiating from the center of the macula, is a striking characteristic. Some of these patches appear to be related to choroidal vessels of medium size, and all have a shape suggestive of a relation to the radiating trunks, that emerge from the sclera in this region. The very center of

the macula is occupied by a small patch of comparatively unchanged choroid. The walls of such vessels as remain appear healthy.

The correcting lenses, determined by skiascopy, were:

R $+0.75 \supset +1$. Cyl. axis 50° = 4/30 partly.
L $+1$. $\supset +1.25$ Cyl. axis 130° = 4/30 partly.

These were given for near work.

The patient has been placed upon the use of mercury and potassium iodide. Her general health continues good, but no change has occurred in the appearance of the fundus. Locally a solution of dionin, 1 : 300, has been used each night, for the last four months. Vision has improved to 4/20 partly.

The striking points about this case are:

The condition has existed from very early childhood. It is probably congenital, although for a time progressive.

A sister is similarly affected.

The lesions are remarkably symmetrical in the two eyes. They present a symmetry only equaled by that of retinitis pigmentosa, amaurotic family idiocy, and a few other conditions of that class.

The part of the fundus affected is the posterior polar zone — the zone which longest escapes the characteristic changes of retinitis pigmentosa.

The affected zone is very poorly supplied with blood vessels, both retinal and choroidal vessels being few and small. But whether this is a primary or a subsequent change, we have no means of knowing.

The lesions differ essentially from those of central coloboma of the choroid on the one hand, and from central choroiditis or chorio-retinitis, on the other. No similar case is figured in the atlases of Jaeger, Liebreich, Oellers, Frost; or elsewhere that I know of.

It seems probable that the case belongs to a type, and that others presenting the same characteristics will be noticed and described, if they have not been previously.

In a very suggestive article, "On the Distribution of the Choroidal Arteries as a Factor in the Localization of Certain Forms of Choroiditis and Retinitis" (Royal London Ophthalmic Hospital Report, January, 1903), E. Nettleship points out that "In retinitis pigmentosa the ophthalmoscopic changes are often most conspicuous at, and sometimes confined to, the equatorial belt, ceasing not only behind it but in front also. In these cases the field shows a belt or portions of a belt of blindness, between the seeing center and the seeing periphery. In syphilitic retinitis, too, such a ring scotoma or blind belt can not infrequently be found if sought for.

"It is impossible to explain this feature of these two diseases by anything in the structure of the choroid or retina. But it might be explicable if we could show that the supply of blood to the choroid was less efficient at the equator than either at the posterior or anterior parts of the fundus; and I think that this is the case. The posterior part of the choroid is supplied, and well supplied, by the posterior ciliary arteries; the anterior part is supplied to a great extent by recurrent branches from the long posterior ciliary and anterior ciliary arteries. The terminal twigs of these anterior and posterior systems meet, and to a certain extent anastomose at the equatorial region. The equator seems to be a sort of 'divide' between the two systems, and to be not very efficiently served by either, while the current must be slowed or reversed in many of the anastomosing twigs."

In the case here reported, we may suppose instead of the failure of the circulation, where the two systems come together near the equator of the eyeball, that there has been a failure, more or less complete, of the posterior blood supply, and that the defect has not been made good by collateral circulation.

ARE TENOTOMIES FOR HYPERPHORIA NECESSARILY MORE UNCERTAIN IN THEIR RESULTS THAN THOSE FOR ESOPHORIA AND EXOPHORIA?

By SAMUEL THEOBALD, M.D.,
Baltimore, Md.

The question mark after the title of my paper is not without significance. It is intended to indicate that I am in search of information upon the subject to which it relates.

I may state at the outset that I have had no experience with so-called "graduated" tenotomies — that is to say, with tenotomies that are pretenses, and not actual tenotomies; in the next place, that before making a tenotomy I consider it essential in every case that a careful determination of the refraction should be made; and, further, that I never perform a tenotomy unless there exists a decided muscular fault.

My tenotomies for esophoria and exophoria have been, as a rule, very satisfactory, and those performed upon the vertical muscles have been measurably so; nevertheless, my experience has been such that when I operate for hyperphoria I do not feel that measure of assurance as to the outcome of the procedure which I should like to feel.

One reason, it would seem, why tenotomies upon the lateral muscles are more satisfactory in their results than those upon the vertical muscles is that we can obtain more aid from the use of glasses. Another is that the lateral muscles are more fully under the control of the will; so that, if we have a moderate over or under correction, the eyes come to our assistance, and help us greatly. On the other hand, in operations upon the vertical muscles the eyes afford us much less help, and about all that we can do with glasses, apart from the assistance gained from prisms, is to correct any considerable amount of anisometropia that may be present.

One trouble that we meet with in tenotomies for hyperphoria is that a slight over-correction, amounting, perhaps, to less than a third of the original defect, seems, at times, to cause the patient more annoyance that the much greater defect for which we have operated.

Another difficulty which besets us is that when we operate upon the inferior rectus we may secure just the balance we want for distant vision, but find things are not right in near vision; while, on the other hand, when we divide the superior rectus the result may be all that could be desired in near vision, but when the eyes, in distant vision, come to a higher plane there is trouble.

Still another difficulty is that the effect of a definite amount of muscle cutting varies so greatly in different cases — varies, indeed, from not more than 4° or 5° in some instances to as much as 15° or 20° in others.

A few cases may be cited in illustration of these points:

A guarded tenotomy — of the L. inferior rectus — is made in the case of Miss X, who exhibited a R. hyperphoria varying from 4½° to 5°. A L. hyperphoria of less than 1½° results; but this slight over-correction causes her more discomfort than the original defect.

The R. superior rectus is divided for 13° of R. hyperphoria in the case of Mr. W. A residual R. hyperphoria of 7° to 8° is left, but he is afforded complete relief.

In each of these cases a complete but guarded tenotomy of one muscle made a change of about 6° in the vertical balance of the eyes. In the case of Mrs. Z, on the other hand, a tenotomy of similar character upon the L. inferior rectus converted an original R. hyperphoria, varying in amount from 8° to 13°, into a L. hyperphoria of 8°, that is to say, made a change of from 16° to 23°. Similarly, in two cases of hyperphoria of high grade recently operated upon the division of a single muscle — the superior rectus in one case, the inferior in the other — gave a correction in each of about 23°.

I should state that all my tenotomies upon the vertical muscles have been what may be termed "guarded" — that is, the

tendon is divided completely, but the incision is not extended into Tenon's capsule, as in cases of squint and of marked exophoria and esophoria.

In conclusion, I may mention two points upon which, especially, I should be glad to have light shed: Is it possible to gauge, in advance, with any considerable measure of accuracy, the effect of a tenotomy performed for the correction of hyperphoria? In operating for hyperphoria, is it, as a rule, better to divide the inferior or the superior rectus muscle?

DISCUSSION.

DR. HOWE. — First I think we should correct our nomenclature and distinguish between a graduated tenotomy and a partial tenotomy. We all attempt to make a graduated tenotomy, as Dr. Theobald describes it. We have learned to secure the effect desired by making as many tests as we please, carrying the operation and tests over a period of one-half or three-quarters of an hour if necessary. As to the question of vertical muscles, we have left two things out of account: First, the anatomy. A photograph which I have made shows very nicely the relation of the levator to the superior rectus. These are in apposition at the posterior part of the orbit, and the fibres can be seen blending again as they come over the eyeball. When we operate on the inferior rectus we must remember that the inferior oblique is in apposition with it and the connective tissue holds them together so that we really operate upon the two. Second, from the physiological aspect, it strikes me that we should use the perimeter carefully in these cases, just as Stevens has shown, and, while there are a great many faults to find with his tropometer, still we ought to measure what the excursions of the eyes are and find out whether we have to deal with an imperfect movement in one or the other direction. Another point to consider is the relation between accommodation and convergence, an important question which I cannot go into now. The superior and inferior recti are almost as essential to convergence as the internal rectus.

DR. WILLIAMS. — At the last meeting of this Society I showed an apparatus for measuring the position of the axes at a distance of 5 or 6 metres, with red lines, green figures, etc., and since then I have made a modified form of the same instrument, to be used

at the reading distance. The amount of heterophoria for distance is not always the amount you get in the reading position. In order to test the thing carefully we should make our tests for both distances. These cases of Dr. Theobald's bring to mind this point particularly, that before operating we ought to try the effect of prismatic correction and muscle exercises. Heterophoria is a very variable quantity, and the correction by prisms can be changed as needed; but this cannot be done by operations.

DR. DUANE. — In regard to operations upon the vertical muscles I think two factors are to be considered. The first concerns the method of operating. This point, particularly with regard to the advantages of the button-hole operation and the necessity of carefully gauging the operation, has been well covered by Dr. Howe. The second point is that what we shall do depends somewhat, too, upon the amount we have to do. If we have hyperphoria of 4° or 5° only, it seems that we can safely do a single tenotomy and get our entire effect from it, or even safely overcorrect somewhat, but when we have a deviation of more than 7° it is unsafe to try to get the whole correction by tenotomy of a single vertical muscle; it may work very well in some cases, but in others it does not, and while we may have a pretty good immediate effect we often have a marked alteration of this condition during the next few weeks. The result obtained after three weeks is apt to be permanent.

With regard to the question of the muscle to be operated upon I think that depends in the first instance upon what condition we are dealing with and that we must go carefully into the question of the excursions of the eyes to determine whether we are dealing with an insufficiency of an elevator or a depressor. If we are dealing with an insufficiency of the elevator it would be highly injudicious to try to remove that by operating upon the inferior muscle. Then, I think operations upon the inferior muscles are to be avoided whenever we can, and that also we should avoid operation upon the antagonist of a muscle that is already paretic, either from previous operations or otherwise.

I may say one word in regard to the lateral attachments of the muscle tendons. Owing to them, disagreeable by-effects are sometimes produced by operations upon the muscles, as when an advancement of the superior rectus is followed by a drawing down of the upper lid, or a retraction of the lower lid occurs after a tenotomy of the inferior rectus. One may then get the impression that an operation has been overdone simply because the eye

appears to be more open or more closed than its fellow, although the tests show that the eyes are in reality perfectly on a level.

DR. THEOBALD. — I have not used the prisms for gymnastic exercises in these cases, but I have always limited my operations to the pronounced cases, and, in the lower grades of hyperphoria, such as many men would operate for, I have been disposed to use vertical prisms, and have gotten pretty satisfactory results in this way. Dr. Howe suggested careful testing at the time of operation to find out, as they say in the senate, "where we are at." This I have been in the habit of doing and of controlling the effect produced, to some extent, by the placing of my stitches.

INTERSTITIAL KERATITIS, COMPLICATING OPHTHALMIA NEONATORUM.

BY ALVIN M. HUBBELL, M.D.,
BUFFALO, N. Y.

Harry C—— was born March 23, 1893. Six days after birth moderately severe purulent conjunctivitis developed in the right eye. A most competent practitioner, Dr. C. C. Frederick, having charge of the case, treated it properly, as I believe, by applying a three per cent. solution of nitrate of silver once a day to the conjunctiva, and by having the eye cleansed frequently with boric acid solution, and a one-fourth per cent. solution of nitrate of silver instilled every four hours. On the fourth day of the disease he noticed a slight cloudiness at the center of the cornea, and at once called me to the case. I found the cornea distinctly hazy at its center, but there was no abrasion or loss of epithelium. There was some swelling of the conjunctiva, and free purulent secretion. At first it was feared that the cloudiness was due to the silver instillations, and these were discontinued, and other remedies substituted. Notwithstanding this, it continued to deepen and spread.

On the twelfth day after birth, and the sixth after the right eye became affected, conjunctivitis began in the left, and this,

too, in spite of precautions taken to prevent it. The disease assumed about the same type as that of the right eye. No instillations of nitrate of silver were used, and yet on the fourth day of the conjunctivitis, the center of the cornea began to cloud, the same as in the right eye, and also without loss of epithelium or purulent infiltration.

The opacities continued to extend and deepen, until, in the course of three or four weeks, each cornea was almost entirely involved. The purulent secretion gradually lessened in each eye after the disease had run about two weeks, and at the end of five weeks the conjunctivitis had quite subsided, leaving both corneæ deeply opaque, with some circumcorneal congestion which did not disappear for many weeks.

It did not take long to eliminate from the diagnosis of the corneal trouble the action of drugs or the presence of a preulcerative infiltration of the corneal tissues, and to determine that the pathological process was that of interstitial keratitis in a most typical and even severe form. The keratitis seemed to reach its climax in about two months. Both corneæ remained densely opaque for six months to a year. From that time they began to clear up slowly, more particularly at the upper margins. This process was so slow, however, that at the end of two years pronounced improvement was noticeable only in the left eye. After four years, the mother says, the right cornea had just begun to look less white. From that time the opacity has grown less and less, and the boy has been able to see sufficiently with his left eye to learn to read, and in fact is quite as far advanced in his school work as other boys of his age. He now reads ordinary print with the left eye at five or six inches, and Snellen type No. 60D. at two meters. With the right eye he counts fingers at one-half meter. I have not tried to adjust glasses.

Nystagmus developed early, and the right eye became strongly convergent. As he has grown older and has been able to see better, both the nystagmus and convergence have diminished. At the present time the right eye is still somewhat con-

vergent, and there is a large dense opacity extending through the lower half of the cornea, nearly to the margin. The upper part of the upper half of the cornea is quite clear, while its lower part is considerably nebulous. The iris and pupil, which can be seen through this transparent and semi-transparent portion of the cornea, appear normal and without synechiæ.

The opacity of the left cornea is dense at its lower third, while the upper two thirds are quite transparent, down to near the center of the cornea, where it is somewhat nebulous. Here, however, it is sufficiently clear to enable the boy to see as above noted. The iris and the pupil of this eye, also, seem to be normal.

The patient was a well developed and healthy baby, and now, at ten years of age, is a strong and healthy boy. He has never had sickness of any consequence, and comes from apparently healthy parents. A brother, however, two years older (twelve), apparently in good general health, has, during the past three or four months, had almost total loss of accommodation in both eyes. His eyes are nearly emmetropic (H. = 0.50D., each) and require, R. and L., +2.50D. glasses for reading and study. This condition in the brother may be suggestive, although I cannot elicit any history of syphilis in either the mother or father.

I submit this case as one of interstitial keratitis, complicating ophthalmia neonatorum. I believe it to have been initiated by the conjunctivitis. It is unique in my experience, and I have not discovered a parallel case in literature, although I have searched considerably for it.

DISCUSSION.

DR. RANDALL. — I had the unfortunate opportunity to report, ten years ago, to this society, a case of double ophthalmia neonatorum in which the sight of both eyes was lost, and in one of those eyes the condition presented paralleled to a certain degree the condition reported by Dr. Hubbell. Later on there was a recurrence of the trouble during a dysenteric attack at the age of six or seven years. In that case there was this intersti-

tial involvment but no suggestion of syphilis in the family history and no other stigmata of inherited syphilis. I suppose it was an infection of the neuro-paralytic type and not a typical syphilitic form.

ARGYROSIS OF THE CONJUNCTIVA AND LACHRYMAL SAC FOLLOWING THE PROLONGED INSTILLATION OF A FIVE PER CENT. SOLUTION OF PROTARGOL—MICROSCOPIC EXAMINATION OF THE EXCISED SAC.

BY G. E. DE SCHWEINITZ, A.M., M.D.,
PHILADELPHIA, PENN.

A number of microscopic examinations of the conjunctiva from cases of argyrosis, or argyria, have been made, and it is well known that silver is deposited there in the form of an oxid or an albuminate, especially on the elastic fibers. So far as I am aware, however, microscopic examination of the lachrymal sac under these same circumstances has not been reported, and therefore a brief reference to the case described in the title of this paper may not be uninteresting.

A married woman, aged 33, applied for treatment in the Eye Dispensary of the University Hospital on August 10, 1901, and gave the following history: She had always been a healthy woman, except that four years prior to her visit in a difficult labor complicated by placenta prævia she had lost a great quantity of blood. From this accident she seems to have recovered entirely until three months before her visit to the hospital, when she began to manifest the symptoms of lachrymal obstruction. It is probable, however, that nasal-duct stricture had existed for some years prior to this date and that what she really suffered from at that time was an acute exacerbation in the form of a dacryocystitis. The duct had been slit at some other hospital, and the usual treatment of passing probes carried out. This was continued at the University Hospital and the patient given a 5 per cent. solution of protargol and instructed to report daily

at the dispensary. She failed to follow these directions and did not again visit the dispensary until eight months later, in the meantime having daily instilled the protargol solution into the right conjunctival sac. A pronounced argyrosis of the conjunctiva of the right eye was evident. The protargol was discontinued and the duct probed from time to time.

When I took charge of the service in October, 1902, I found this patient with the following conditions: Vision of the right eye 6/30, of the left eye 6/15, myopia of 3D., a conus surrounding each optic nerve, and general choroidal disturbance. From the right lachrymal sac pus exuded freely, and the conjunctiva was stained in the most remarkable manner. Up to the very margin of the lid, both bulbar and tarsal conjunctivæ were deeply pigmented, the pigmentation of the retrotarsal folds being almost chocolate in color, while that of the bulbar conjunctiva was a yellowish-brown. The caruncle was deeply colored, as was also the slit canaliculus. The palpebral edges were free from the stain.

She was admitted to the hospital January 21, 1903, and on the following day the lachrymal sac was excised. Its exposure was unusually easy, as it presented itself after the ordinary dissection as a densely pigmented sac, almost bluish-black in color.

After hardening in formalin serial sections were made, for the preparation of which I am indebted to Dr. E. A. Shumway, and the following lesions found:

The pigment is not deposited in the epithelium, but in the submucous tissue along the elastic fibers which make up the meshes of the tissue. The epithelium lining the sac consists of tall cylindrical cells, below which two rows of polygonal cells are evident resting upon a basement membrane. The latter is densely covered with the pigment patches. In addition to uniform incrustation around the elastic fibers, some pigment grains are deposited free in the tissue, although many of the apparently free particles should be regarded as cross sections of the incrusted fibrils. The pigmentation extends to a depth of three-quarters of a millimeter below the basement membrane and out-

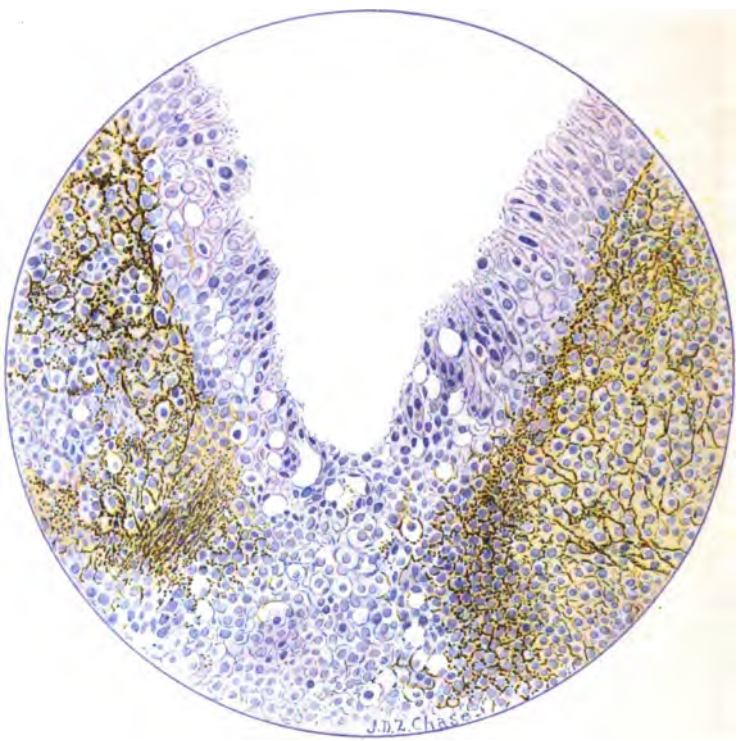

ARGYROSIS OF THE WALL OF THE LACHRYMAL SAC. INCRUSTATION OF THE ELASTIC FIBERS WITH THE SILVER SALT.

lines the meshwork of the tissue with beautiful distinctness. The surface of the sac is denuded in many places and the number of lymphoid cells greatly increased, so that the wall of the sac is greatly thickened and all structures of the submucous tissue obscured. In addition to the pigment around the elastic fibers, it may be seen outlining the inner wall of the capillaries. It is brownish-yellow by transmitted light. The accompanying drawing by Mrs. P. P. Chase very accurately illustrates the lesions which have been described.

The whole subject of the clinical and anatomical investigation of argyrosis has recently been reviewed by Hoppe.* He found in his case that the epithelium was practically free from pigmentation, an observation which corresponds with that made by Grossmann,† who failed to observe any trace of pigment in the epithelium, the coloring being exclusively confined to the elastic fibers. Hoppe further notes that in the already well-known manner the elastic fibers were colored and also the cement substance of the muscle cells of the vessel walls. In addition, there were found coarse granules scattered throughout the tissue, and by the application of concentrated sulphuric acid the pigment became free and changed into yellow granules, although it was not mechanically isolated from the tissue elements to which it clung. In general terms, the coloration consisted of a fine granular precipitate of albuminate of silver, which appeared at or after the diffusion of the nitrate of silver lotion through the epithelial layer, and as soon as it came in contact with the alkaline tissue fluid. Gradually pigmentation of the superficial layers took place by a process of reduction.

As is evident from the specimens which I have exhibited and the description which I have given of them, the same condition of affairs applies to the present instance, and the process of staining in the lachrymal sac, as well as the method of the deposition of the pigment, is the same as in the conjunctiva. Moreover, this occurred under the action of protargol and not

*Archiv. f. Ophth., 48, 1899, p. 660.
†Ophthalmic Review, Vol. VII, 1888, p. 167.

under that of nitrate of silver. Therefore the two in this respect are identical in their effects.

It may not be out of place to call attention to the fact that there seems little doubt that protargol is capable of very rapidly, perhaps more rapidly than nitrate of silver, producing argyrosis. This is doubtless true because it may be used with such freedom as a lotion, as it is almost unirritating in its qualities. The practice of allowing patients to have solutions of this character is greatly to be deprecated.

Pergens* has called attention to the danger of protargol from this standpoint, and has observed argyrosis after fourteen weeks' use of this medicament. He also quotes the observations of other surgeons. Exactly how long a time elapsed before staining of the conjunctiva began in my patient I cannot say, but probably not more than three or four months, and I am quite sure that I have seen cases in which the duration has been a much shorter time than this. In our own country Dodd† has directed attention to the ease with which protargol may produce argyrosis in cases of trachoma.

DISCUSSION

DR. PERCY FRIDENBERG. — I would like to say that nitrate of silver makes a very similar stain in the lens. I examined a number of sections a few years ago and found just the condition that Dr. de Schweinitz describes; that the epithelium was not changed, but the incrustations were shown in the fibrous structure, and the striæ of the lens star could often be demonstrated.

* Monatsbl. f. Augenheilk., 1900, p. 256.
† Ophthalmic Record, Vol. X, 1901, p. 47.

REPORT OF A CASE OF DOUBLE TRAUMATIC OPTIC NEURITIS FOLLOWED BY ABSOLUTE BLINDNESS AND RECOVERY.

BY WM. HOLLAND WILMER, M.D.,
WASHINGTON, D. C.

E. H., a strong, healthy girl of 8 years, was brought to my office on March 24, 1903. The following history was given: Nine days before, while playing ball, was struck on the left side of the nose with a baseball bat. Was not knocked down or rendered unconscious, but there was a good deal of bleeding from the nose. There were no further immediate bad symptoms until three days later, when she awoke and found that she could not see with the right eye. The sight of the left eye began to fail the following day — fourth from accident.

Present condition. — Pupils widely dilated and immovable; exophthalmos of both eyes, but more pronounced in the right eye. Motility of eyes not impaired. Palpebral fissure of right eye 14 mm. wide and the left 13½. A decided swelling over the left nasal bone, a spot of ecchymosis of the conjunctiva of the left eye 5 mm. in diameter and 5 mm. from the temporal margin of the cornea. V. in each eye 0.

No fracture could be discovered either externally or by nasal examination. The ophthalmoscope showed a marked double optic neuritis, but no other change in the interior.

After repeated use of eserine (gr. 1/20 to ounce) for one-half hour, the pupils contracted a trifle in bright light.

The patient was seen by several of my colleagues at the Episcopal Eye, Ear, and Throat Hospital.

The accompanying picture of the child, unfortunately, was taken several days after my first examination. But it still shows a slight proptosis, swelling over the nasal bone, and the small spot of ecchymosis of the left conjunctiva. The pupils had, however, contracted very much.

The child was put to bed in the hospital; calomel (gr. 1/10) was given every half hour until it acted, and constant ice applications were made externally.

In four hours the child could locate the bright light from a window.

March 25, good perception of light in each eye. Ice continued and potas. iod. ordered.

March 28, still only perception of light, swelling over nose and exophthalmos less.

March 31, V. = 1/200 in each eye.

April 5, V. = 3/200 in each eye; no projection of eyes; fields contracted; in right eye, central scotoma — papillitis less.

May 13, V. = 20/20; fields for form and colors normal; reads J. 1 at 4″ with ease. Papillitis entirely subsided; nerves normal, except a trifle paler than usual towards temporal side.

The cause of the papillitis in this case seems to be a possible fracture without displacement, extending into the middle fossa, with consequent hemorrhage pressing upon the optic chiasm and involving the orbits. There was also, probably, a certain amount of pressure from the localized periostitis about the seat of the fracture.

From the rapid recovery, it is probable that there was no direct injury to the optic nerves by projecting spicules of bone.

In the brief time at my disposal, I have been able to look over the reports of 168 cases of atrophy or partial atrophy following direct injury to the optic nerve or indirect violence about the face or head.

Moumale has collected 124 cases, of which 37 were injuries by a sharp body entering the orbit, or injuring its contents. Of these, 31 lost all sight and 6 suffered great impairment of vision. There were 37 cases of gunshot wound, 35 resulting in complete blindness, and 2 in partial blindness.

There were 15 cases of injury to the orbits by dull objects, such as pitchers, etc., 14 of which were absolutely blind and 1 partially so.

There were 35 cases by indirect violence. Of these, 23 were blind and 12 partially so. Only one case of a preceding papil-

Case of Double Optic Neuritis.

litis is mentioned. In this case, a fork penetrated the orbit and directly injured the nerve.

The reports of 8 of his own cases have been examined, and in this number there was no record of a papillitis. Of the 8 cases, 4 were caused by indirect violence, 1 resulting in absolute and 3 in partial blindness.

I found also thirty-six cases reported by other authors. Of these, 20 were from indirect violence, 12 of which resulted in complete and 8 in partial amaurosis. In the above 36 cases there were mentioned only 5 cases of papillitis preceding the atrophy. In brief, in only 6 cases of the 168 was there any record of an actual papillitis (3.57 per cent.).

In addition to the case reported in full, the following cases have recently come under the writer's observation:

(1) J. C., male, 55, fell in dark, striking right temple. Three months later there was complete atrophy of the right optic nerve.

(2) W. B., a young man, fell from his wheel three weeks ago, striking the left temple. Vision of left eye 20/100; fields for colors and white contracted, color sense of left eye defective; ophthalmoscope showed an incipient optic atrophy.

(3) Miss E. P., one year ago thrown from horse, striking right side of her head. Vision of right eye, with refraction error corrected, 20/50, central color sense perfect; but field contracted for form and colors. Ophthalmoscope showed partial atrophy of optic nerve.

(4) R. F., male, 53, three months ago fell, striking back of head. Sight began to fail a few days after fall. Sight in each eye 20/100; fields for white normal, color sense defective. Ophthalmoscope showed a partial optic atrophy. Nine months later, V. = 20/30 in each eye. A colleague who examined the patient shortly after the fall tells me that at that time there was a mild papillitis.

(5) This case came under the observation of my associate, Dr. L. S. Greene. Girl, aged 12, struck on left temple by rolling log. Unconscious. Sight began to fail three days after injury.

Four weeks after injury L. E. V. = perception of light. Three months later V. = 0. Diagnosis, atrophy without visible papillitis.

LITERATURE.

Spaulding (J. A.). "Optic atrophy from blows on the forehead and temple." Trans. Am. Ophth. Soc., IX, Part 1, 83-89.

Vernon. "Double optic neuritis and detached retina, following a fall upon the head." Med. Exam., Lond., 1876, I, 30.

Taylor (S. J.). "A case of probable rupture of the optic nerve." Tr. Ophth. Soc. U. Kingdom, 1893, XIII, 155-159.

Nettleship (E.). "On cases of injury to the optic nerve." St. Thomas's Hosp. Rep., Lond., 1882, XI, 113-122.

Williams (R.). "Neuro-Retinitis from a blow on the forehead." Brit. M. J., Lond., 1882, I, 157.

Scott (K.). "Traumatic division of both optic nerves." Tr. Ophth. Soc. U. Kingdom, Lond., 1899, XIX, 151-154.

Henry (R. W.). "Injury of the optic nerve." Brit. M. J., Lond., 1896, I, 843.

Williams (E.). "Probable trauma of the optic nerve." Cincinnati Lancet and Observer, 1861, N. S. IV, 401.

Benson (A.). "Injury to the optic nerve without injury to the globe, followed by sudden amaurosis with subsequent optic atrophy." Brit. M. J., Lond., 1882, II, 1085.

Shaw (C. E.). "Case of optic neuritis after perforating wound of the eyeball." Ophth. Rev., Lond., 1897, XVI, 107-109, 1 pl.

Pentcheff (D.). "Contribution à l'Etude des blessures du nerf optique." Thèse Inaug., 44 pp. 1 L. 8° Genève, 1895.

Gayet. "Blessure du nerf optique par une buche de paille." Bull. Soc. de Chir. de Lyon, 1901-2, V, 40.

Bruhn (C. A.). "Ein Fall von Verletzung des Sehnerven, Blutung in die Orbita und Opticusscheide und directer Zerreissung der Choroidea." Inaug.-Diss., 11 pp., 2 L, 8° Kiel, 1889.

Berlin (R.). "Ein Fall von Verletzung des Sehnerven bei Fractur des Canalis Opticus." Ber. n.d. Versamml. d. Ophthalmol Gesellsch., Stuttgart, 1881, XIII, 81-100.

Caspar. "Zwei Fälle von Verletzung des Sehnerven." Arch. f. Augenh., Weisbaden, 1900, XLI, 188-197.

Moumale (J.). "Zur Casuistik der Sehnerven verletzungen." Inaug.-Diss., 71 pp., 8° Giessen, 1901.

Köhler (A.). "Krankenvorstellung, Schussverletzung des Sehnerven." Verhandl. d. deutsch Gesellsch. f. Chir., 1888, XVII, 97.

Blessig. Vestnik Oftalmol. Kiev. 1900, XVII, 629.

CASE OF TRAUMATIC PTOSIS OF THE LEFT EYE OPERATED UPON WITH MOST SATISFACTORY RESULT ACCORDING TO THE METHOD OF DR. GRUENING OR GILLET DE GRANDMONT.

BY W. B. MARPLE, M.D.,
NEW YORK CITY.

The result in this case was so satisfactory that it seems worthy of recording so as to make better known this most excellent method of dealing with these cases of ptosis.

The patient, R. B., kindly referred to me by Dr. Walter B. James of this city, a lad from Albany, N. Y., 16 years of age, gave the following history: Two years ago he pitched forward from a shelf and struck against a gasburner projecting from the wall, producing a bad laceration of his left upper lid. He says it required seventeen stitches to close the various rents in the lid at that time. Subsequently (February, 1901) considerable granulation tissue was removed from the inner surface of the lid.

He was first seen by myself the end of January of this year and his condition at that time was as follows: He has almost complete ptosis of the left eye, as is shown by the accompanying photograph. There is a good deal of fullness of the ptotic lid, which hangs in folds, and there are a number of irregular scars across it. When the lid is everted, it is seen that the cartilage has been lacerated badly and to the nasal side there is no cartilage

left at all. Measured by the method of Gillet de Grandmont (from lower border of upper lid in each eye to upper margin of eyebrow) the ptosis amounts to 5 or 6 mm., the nasal end of the lid drooping 1-2 mm. lower than the temporal, as is shown in the photograph; the palpebral fissure is only about 1 or 2 mm. broad in this eye. The absence of so much cartilage in the lid made it somewhat uncertain whether this form of operation would succeed or not, and a somewhat guarded prognosis was given, but the result could scarcely be improved.

Dr. Gruening very kindly consented to be present at the operation and I am greatly indebted to him for several suggestions made at the time.

The method employed was that described by Dr. Gruening at the last meeting of this Society. At his suggestion, one or two sutures were introduced through the upper part of what took the place of the cartilage, before the latter was incised, as it was thought possible that the upper part might retract out of sight. It showed no disposition to do this, however. There was a dense fibrous or connective tissue filling in the parts formerly occupied by the cartilage which served the purpose of the latter. A strip of this 3-4 mm. broad was excised. Then a second piece 2 mm. broad was removed at the nasal end of the lid where the ptosis was most marked. I then introduced three black silk sutures as in the manner described by Dr. Gruening. The cutaneous wound was not closed.

The sutures were removed in four days, during which time there was some œdema of the lids and the line of incision hung down below the lid margin. But the œdema rapidly disappeared when the sutures were removed and the effect became daily more satisfactory. The patient left the hospital on the fifth day and returned to his home on the tenth day. He could close his eye readily.

Six weeks after the operation the photograph which is here shown was taken and sent to me. This will show the result much better than any description. An ordinary observer would scarcely notice that there was anything peculiar about the eye at

R. B. — Taken the day before operation.

R. B. — Taken six weeks after operation.

all, and the contrast with his appearance before the operation is most striking.

As to the technique of the operation there does not seem to be any essential difference between that described by Gillet de Grandmont and that by Dr. Gruening. While the description of his operation by the former seems quite to warrant the statement of Dr. Gruening that "he does not confine his operation to the cartilage, as I did in my cases, but removes the upper edge of the tarsus together with as much of the tarso-orbital fascia and the levator muscle as he may find requisite," it is evident that at least in some cases Gillet de Grandmont must confine his incisions to the tarsus. His description of his first incision through the cartilage locates this "parallèlment au bord libre de la paupiere à une distance de 2 à 4 mm. de ce bord." So that (although his subsequent language is ambiguous) unless the ptosis was of very high degree his second incision would be in the tarsal cartilage.

As to the method of introduction of the sutures, our French confrère closes the opening of the cartilage by direct sutures with catgut, not introducing any cutaneous sutures. Dr. Gruening uses a thread armed at each end with a needle, passing the needle through the orbito-tarsal fascia and then through the edge of the upper lid behind the lashes, knotting them at the free edge of the lids. This latter method I employed in my case and the result was most satisfactory. But in the next case I have I shall try Gillet de Grandmont's method with catgut. It seems a priori that with this method of introducing the sutures there would be less tendency of the edges of the cartilages to override.

Another great advantage which the method possesses is the accuracy with which we can graduate the effect to be secured. In the case described above, the ptosis was much more marked in the nasal half of the lid. Accordingly, after excising a piece of cartilage 3-4 mm. broad along the entire length of the lid, a second piece 2 mm. broad was excised along the nasal half of the lid, with the result that the ptosis was perfectly corrected and the border of the lid occupied the normal position.

Finally, the very slight reaction following the operation is one of its desirable features. What slight reaction there is disappears promptly when the sutures are removed on the third or fourth day.

In conclusion I would say that Gillet de Grandmont's article can be found in the *Receuil d'ophthalmologie*, 1891, p. 267, and Dr. Gruening's description is in Vol. IX of the *Transactions of the American Ophthalmological Society*, p. 574.

AN INTERESTING CASE OF PIGMENTARY DEGENERATION OF THE RETINA (RETINITIS PIGMENTOSA).

BY WALTER L. PYLE, M.D.,
PHILADELPHIA, PA.

The patient is a man of fifty-four, above average size and height; and, with the exception of his ocular affection, apparently in the best of health.

Ocular Condition. — The fundus of both eyes presents the characteristic signs of pigmentary degeneration of the retina. Except in the exact macular region, there are scattered over the whole fundus pigment-masses with interlacing processes resembling the Haversian canals of bone. The long continued absorption of retinal pigment has rendered plainly visible the choroidal vessels, giving the familiar "wainscoted" effect. The retinal blood-vessels have undergone hyaline thickening, reducing the size of the blood-column, but apparently not interfering with the transparency. They are outlined with whitish streaks. The optic discs are uniformly dull, pale gray — waxy or parchment-like in appearance, with but little blurring of their margins. Contiguous to the center of the posterior capsule of the lens there is a small opacity in each eye, but otherwise the media are clear. The fields of vision are reduced to within the five-degree circle for white, and within the three-degree circle for red, but the central acuity of corrected vision and color per-

ception remain remarkably acute. There is very little nystagmus. The pupils react to light and accommodation. Station is good, and the patient walks steadily, forward or backward, with the eyes closed. The knee-jerk reflex is normal. The ametropic correction in the right eye is — Cyl. 1.50 ax. 90, giving vision of 6/7½?; that of the left eye is — S. 0.75 — C. 0.50 ax. 90, giving vision of 6/9?. Additional convex spherical lenses of 2.50D. are used in hook-fronts for near vision. With his correction he reads 0.50D. type with ease. The rod-test for muscle-balance shows 3° of exophoria.

A careful family history, extending over a century, shows tendency to long life, and, with the exception of a brother of fifty, an alcoholic, who was afflicted with a retinal hemorrhage, there is no record of serious ocular disease in all his family. Nor is there any history of consanguinity.

The patient has always been well and strong. He first noticed night-blindness at about the age of eleven, but he pursued his studies for two years longer, working strenuously and late at night by dim light. After leaving school, he was two years in a country store, and from sixteen to twenty-one years of age he alternated between clerkship in a shoe-store and substituting as a mail-carrier between Dover, Del., and Philadelphia. From twenty-one to thirty-one he sold sewing machines, traveling in buggy or saddle through Delaware and the eastern shore of Maryland. During this time, night-blindness became so marked that he had to forego travel after dark, but apparently his visual acuity was normal, for he was an expert operator in fine work on the sewing machine, in adjusting which he required keen sight and touch.

He first consulted an oculist in Philadelphia when about twenty years of age; again in Baltimore when about twenty-five; and again in Philadelphia when about thirty. This latter examination was made by a former boyhood acquaintance, the late Dr. E. O. Shakespeare. All of his oculists pronounced his case one of pigmentary degeneration of the retina, and, beyond the prescription of strychnia, no treatment was advised. When

he was twenty-five years of age a Baltimore specialist gave a prognosis of practical blindness within three years.

From thirty-one to forty-one years of age, he traveled as a salesman for a well-known Philadelphia manufacturer of paints. During this time he noticed no difference in the night-blindness.

While selling paints he could separate on a card containing six strips, ¾ inch by 2½ inches, shades of green and vermilion differing very little in the amount of pigment used, as will be seen by the samples that I have brought for exhibition. He could also distinguish perfectly and name sixty samples of different colors on a larger color card.

The patient states that his sense of touch is very fine in judging textile fabrics and leather. By touch alone he can tell the difference between French and American kid. His sense of hearing is equally acute and he can distinguish the different kinds of trees at night by the rustle of their leaves.

His sense of smell is very defective. He is unable to appreciate the perfume of flowers, and has never been conscious of the noxious odors of excreta; but fortunately pungent odors, such as ammonia and illuminating gas, he can detect. The patient has never used alcohol nor tobacco, and has avoided highly seasoned food. With the exception of the night-blindness and the necessity for very bright artificial light, and temporary blindness on entering a building from an outside bright light (which he notes is increasing in the last four years), the patient has maintained his earning ability and his capacity for enjoyment in a manner most remarkable.

His sense of location is extraordinary, and in familiar places he experiences no difficulty in finding his way in the dark.

He experiences but little difficulty in traveling through the crowded cities by daylight, and he is ever ready with an apology for bumping into people, and pardons with a smile those who jostle him. Street cars and wagons he avoids by careful deliberation and inspection before crossing a street, aided by his wonderfully acute hearing.

In concluding this remarkable history, it is appropriate to add that the patient attributes his long retention of vision to his

own mental attitude, and his avoidance of worry over his condition. Despite the oft-repeated prognosis of inevitable blindness, he has simply made the best of his circumstances; and, with an almost unparalleled strength of will and nobility of character, he has surmounted his physical infirmities, and for over forty years has supported himself, his wife, and mother, and has aided in numerous ways several other members of his family.

DISCUSSION.

DR. PERCY FRIDENBERG. — In connection with the histological study of this question I would like to report a case of double optic neuritis in which there was a deposit of pigment arranged in the fundus along the retinal vessels as very fine branching lines. They were so small as to be overlooked unless carefully pointed out to you (passing drawings). They were not seen at the periphery, but around the disc, and had the characteristic appearances of the finer Haversian canal lines of retinitis pigmentosa.

A CASE OF ORBITAL CELLULITIS, WITH EMPYEMA OF THE ETHMOID AND FRONTAL SINUSES — ABSCESS OF FRONTAL LOBE — PNEUMOCOCCÆMIA — DEATH.

BY E. GRUENING, M.D.,

NEW YORK CITY.

The patient whose case is here related suffered from chronic suppuration of the ethmoid labyrinth and the frontal sinus. He became infected by a pneumococcus invasion, the portal of infection being the nose. From here the infection traveled to the ethmoid cavities, the orbit, and the brain, the frontal sinus being passed over. Clinically this fact was demonstrated by the absence of tenderness in the region of the frontal sinus, and bacteriologically by the sterility of the purulent contents of the sinus. The pus taken from the nose, the ethmoid cavities, and the brain contained the pneumococcus. If in the descrip-

tive title of the paper " orbital cellulitis " occupies the first place, it may be explained by the circumstance that it was this affection with its inherent protrusion of the eyeball that caused the patient to be admitted to the eye wards of the Mount Sinai Hospital and brought him under my care.

L. S., 26 years of age, a butcher, was admitted to the Mt. Sinai Hospital on March 29, 1903. His left eye was markedly chemotic and both lids were swollen. The motility of the eye upward was impaired and the globe was forced downward and forward. The pupil of the left eye was slightly larger than that of the right. Ophthalmoscopic examination negative. Marked tenderness over ethmoidal sinus; no tenderness over frontal sinus. Between the middle turbinated body of the left side and the outer wall of the nose a layer of white pus. Temperature 103.8. Pulse 76. Respiration 26. Lungs, heart, spleen, ears normal. The patient was in a stuporous condition and could not be questioned as to the history of his disease, but his relatives stated that six days ago he woke in the early hours of the morning with much headache, and pain in the left eye. The first three days he had chills and fever and a copious discharge from his nose. The pain in the left eye persisted and the patient was at times unconscious and at other times delirious.

On the day of admission, March 29, 1903, the patient was anæsthetized and operated upon. An incision down to the bone was made along the upper and inner orbital margins. The periosteum of the os planum and of the roof of the orbit was discolored, softened, and perforated at several points. The entire os planum was carious; the cavities of the ethmoid bone were full of pus and granulation tissue and communicated with the orbital cavity, which likewise contained much pus. The lachrymal gland was displaced downward and lay in a pool of pus. The roof of the orbit was also diseased. The bone, *i. e.*, the outer table of the orbital process of the frontal bone, was softened and discolored. It was therefore removed and the frontal sinus was thus opened from below. The cavity of the sinus contained thickened mucous membrane, a quantity of pus, many

mucous polyps, and an exostosis springing from the roof of the frontal sinus, *i. e.*, from the inner table of the frontal process. The contents of the frontal sinus were removed and the remaining bony walls appeared sound and no communication seemed to exist with either the sinus of the other side or the cranial cavity. At the termination of the operation the frontal sinus, the ethmoid sinuses, and the orbit were one large cavity. This was loosely packed with moist iodoform gauze. A rubber tube was carried through the nose and a moist dressing applied. The following day, March 30, the patient was but little improved. He was still stuporous at times, at others delirious. The pulse ranged from 101.8 to 103.6. The packings were removed and renewed moist.

March 31. Patient delirious the greater part of the day. At times he is quiet and answers questions rationally. In the course of the day the temperature rose to 105.4, with pulse 90 and respiration 28. He had a severe chill lasting twenty minutes. Leucocyte count 33,000.

Lumbar puncture; 55 cc. obtained. Fluid clear. Spreads negative. Culture negative.

Late in the evening the patient had another chill. The temperature rose to 107.2. Pulse 124. R. 34. Sponge bath reduced the temperature to 105.8.

Packings removed and renewed.

Sero-purulent discharge from wound.

Culture from pus of orbit, ethmoidal cells, and nose: Pneumococcus.

Culture from frontal sinus: No growth.

April 1. Involuntary urination and defecation. Temp. 106. Pulse 96. R. 34. Patient in deep coma. Ophthalmoscopic examination. Redness of left disc and considerable dilatation of retinal veins.

In view of the negative character of the spinal fluid it was decided to explore the brain.

Osteotomy for exploration of the brain. No anæsthesia. The original incision along the inner margin of the left orbit

was continued upward through skin and periosteum and the flap was turned back. The inner plate of the orbital process was found softened. An opening was made through the bone and when the dura came into view a stream of foul smelling pus flowed from the cranial cavity into the orbit. The entire inner table of the orbital process and a part of the anterior wall of the frontal bone were removed, exposing the dura covering the anterior and inferior surfaces of the left frontal lobe. The dura was discolored and perforated on the under side of the frontal lobe and from the hole in the dura foul pus continued to flow. The opening in the dura was enlarged so that the finger could be introduced into the large pus cavity of the brain. The cavity had no definite walls. A dressing forceps was carried into the abscess cavity and opened at various points, and a number of pus pockets were emptied. The outer wound was then flushed, but the abscess cavity was not irrigated, but drained by narrow strips of moist iodoform gauze.

Culture from brain abscess: Pneumococcus.

Immediately after the operation the patient answered questions slowly but rationally. The temperature fell to 103.4, and in the course of the night to 99.6. But early in the morning of the following day the patient had a violent chill and lost consciousness. Temp. 105.8. Pulse 164. Respiration 50. Involuntary urination. Pulse very weak. Subcutaneous injection of salt solution ℥xvi. In the afternoon the patient had a general convulsion lasting two minutes and later another lasting one minute.

Blood culture taken.

April 3. Temperature 106. Comatose. Involuntary urination. General convulsion lasting five minutes. The wound discharges purulent material and necrotic brain tissue.

April 4. Deep coma. Temp. 106.2. Pulse 168. Chill, lasting ten minutes. Subcutaneous infusion of salt solution. Respiration rapid, but lungs negative. Had five convulsions today. Foul smelling pus and necrotic brain tissue removed from wound.

Report of blood culture taken April 2. Pneumococcus in plates and flasks.

April 5. Coma persists. Had thirteen convulsions today. Total time thirty-one minutes. White blood count 20,000. Unable to swallow. Fed by gavage.

Temp. from 102.8 to 105.

Respiration from 50-60.

At right base of lung large area of dullness. Bronchial voice and breathing. Mucous subcrepitant râles. At 10 P. M., pulmonary œdema. Cups applied. Œdema less marked. Foul discharge from wound.

April 6. Five convulsions since midnight. Pulse at times imperceptible. Ceased to breathe at 7.30 P. M. No autopsy.

CASE OF SPONTANEOUS PROLAPSE OF BOTH LACHRYMAL GLANDS.

BY DUNBAR ROY, M.D.,

ATLANTA, GA.

The case here reported is anomalous in character rather than of any practical interest. In looking up the number of similar cases which had been reported, and also any other literature bearing upon the subject, I was surprised to find that spontaneous prolapse of the lachrymal gland could be placed in the category of rare affections. Several cases of traumatic prolapse have been reported, also one or two cases of spontaneous prolapse of one lachrymal gland, but nowhere can I find the report of a case where both lachrymal glands have become spontaneously detached.

Mary M., colored, age 27, and unmarried, presented herself at the clinic of the College of Physicians and Surgeons in September, 1902. She came with the complaint that both upper eyelids had remained swollen since an attack of bronchitis, three weeks previously. There was no pain and no interference with vision — practically no discomfort from the present condition.

On casual inspection the upper lids gave all the appearances of œdema, especially on the temporal sides. By palpation I found a well-defined glandular body just beneath the border and at the outer edge of each orbital ridge. It was especially prominent when the patient looked down and held the head forward. Both sides had absolutely the same objective appearances and symptoms. It was freely movable under the touch and could be pushed up underneath the orbital rim. The patient was perfectly positive that there was nothing wrong with the eyes up to three weeks previously. No enlarged glands could be found in any other portion of the body. As the condition was giving the patient no trouble she refused any operative interference, leaving out of question its advisability.

When last seen there were no changes visible.

I was very confident, as were also my colleagues, that the body felt was the lachrymal gland, but we could in no wise account for this dislocation. There was no history of traumatism to which it could be traced, nor any severe straining on the part of the patient except the previous cough. In this latter respect, as well as in several others, the case is similar to the one reported by Snell in 1881.

Anatomists tell us that the lachrymal gland is enveloped in a capsule which, by its attachment to the periosteum of the orbital cavity, retains it in place. In a case of this kind we can but surmise some anatomical malformation or some relaxation of the surrounding tissues as a cause of such a pathologic condition.

In looking up the literature of this subject, but few cases could be found recorded, although I am confident that there are many other cases which have never found their way into the medical literature. Two cases only of spontaneous dislocation of the lachrymal glands have been found reported and fourteen cases where the cause was due to traumatism.

The diagnosis of these cases of dislocated lachrymal glands is apparently easy, and especially so when there is any incised wound permitting inspection in addition to palpation.

Double dislocation of lachrymal gland.

In all of the cases reported, except the ones by Mittendorf and Noyes, the deformity was noted externally rather than internally beneath the upper lid. In my own case nothing abnormal could be seen by the closest inspection beneath the lid.

Cases of spontaneous dislocation of the glands will, of course, present but one or two symptoms which are found when the condition is due to trauma. With the exception of the deformity due to swelling and a possible limitation in the raising of the lid, these spontaneous cases cause no inconvenience to the patient.

It is a noteworthy fact that in none of the cases recorded has the lachrymal function of the gland been impaired, for in my own case neither an increase nor a decrease of the moisture could be noted. Another remarkable symptom mentioned only in the case reported by Haltenhoff, where even a greater portion of the gland was removed, was the fact that there was no difference in the moisture in the two eyes.

The question of treatment must of course vary according to the character of the case. In those dependent upon traumatism, where there is a contused or incised wound complicating the condition, operative intervention must always be considered. In those cases where there is no wound or in the so-called spontaneous dislocations, the question of operation must be decided by the character of the individual case.

Mechanical compression is difficult of application. If the deformity is not marked and there are no uncomfortable symptoms, I do not see why it is necessary to do anything whatever. If there is ptosis from the presence of the gland, or if the latter should be painful and of great discomfort to the patient, fixation of the gland should first be attempted, and if that fails there is no reason why the gland should not be removed.

DISCUSSION.

Dr. Randolph. — I would like to ask Dr. Roy how he would differentiate this condition from mumps of the lachrymal gland, the nonsuppurative dacryo-adenitis. The diagnosis may

be all right in this case, but he has not made it clear how to distinguish condition.

DR. ROY. — There was no infiltration, there was a looseness of the skin and through this the gland could be recognized; there was no tenderness on pressure on the gland, which could be taken between the fingers, and there was no swelling except just where the gland was felt beneath the orbital ridge. Of course I am not perfectly sure, but with the symptoms and with the concurrence of my colleagues I thought it was a dislocation without any inflammatory condition.

DR. TAYLOR. — I have been much interested in Dr. Roy's paper as it recalls vividly a case of prolapsed lachrymal gland which I treated in the early years of my practice. A lady, aet. 32, came under my care on April 5, 1886, when I took charge of her at the request of her family physician. She was suffering with iritis and scleritis in the right eye only, with intense pain and profuse lachrymation. The chief trouble was in the region of the lachrymal gland where there was considerable swelling. Upon everting the lid, the lachrymal gland presented swollen and tense. I used leeches to the temple, atropia and cocaine, with bromide and chloral internally and morphine as necessary. I treated her for ten days with only slight alleviation of the intense pain. Finally ether was administered and I incised the lachrymal gland freely and scarified the conjunctiva. This I did, Mr. Chairman, because I did not know what else to do, and her condition and complaints were such that something radical was necessary. From this time on she steadily improved and had only one severe attack of pain afterward, which came from exposure to draft. Intense lachrymation followed the incision of the gland for several days, but this gradually subsided.

In the latter part of the following month, that is, May, 1886, she came to my office for fitting of glasses and with proper correction vision was 15/XV in each, and she had no subsequent trouble.

DR. WADSWORTH. — I have seen a considerable number of cases of prolapse of the lachrymal gland, and I do not think any of them have been traumatic, nor have any been inflammatory, except perhaps one case. There has been a distinct edge to be felt beneath the outer part of the orbit, and the gland could be pressed back quite easily. I recall one case in which there was marked fullness of the upper lid of both eyes, in a man in mid-

dle life, and according to the man's statement the trouble had existed since childhood without giving any inconvenience. In another case a prolapse came on during an attack of iritis, and the prolapse disappeared when the iritis subsided. This last winter I saw a child with an extensive œdema of the upper lid of one eye following grippe, and as the œdema subsided a prolapse of the lachrymal gland became evident, but this also soon disappeared. In none of my cases has there seemed to me to be any indication for interference.

OPTIC ATROPHY FOLLOWING INTESTINAL HEMORRHAGE.

BY WILLIAM M. SWEET, M.D.,
PHILADELPHIA, PA.

Atrophy of the optic nerves following acute anemia is of sufficient rarity to warrant the presenting of a case which has been under observation for the past four years.

D. C., aged 55, a healthy robust individual, driver of a dray, was attacked by vertigo while going to his work on the morning of April 25, 1899. This was associated with extreme muscular weakness, especially of the lower extremities, which was sufficient to compel him to return home and go to bed. He could not raise his head from the pillow without a return of the vertigo, and there was also slight nausea but no vomiting. The next day found his condition unchanged, except that he complained of being weaker and unable to get up. Towards evening, thinking that a movement of the bowels might improve his condition, he took a full dose of calcined magnesia. During the night he had one large movement of the bowels. The niece stated that in the morning the chamber was full almost to the top with dark clotted blood. Towards evening there was another hemorrhage from the bowels, almost equal in quantity, but the blood was brighter in color.

The attending physician saw the man shortly after the second hemorrhage, and found marked anemia, with the pulse rapid

and shallow, and extreme muscular weakness. Consciousness was preserved. Temperature normal and urine normal.

The condition of the man showed no change until the morning of the sixth day, when he found that objects about the room seemed to be in a haze. This gradually increased until, by evening, light could only be recognized in a small area towards the right side. During the six days intervening between the second hemorrhage and the decline in vision he stated that the sight was as good as ever before.

I first saw the case three days after failure of vision, and found absolute blindness, even to strong illumination, in the left eye, while in the right eye there was loss of light perception in all portions of the field except in a small area to the temporal side of the fixing point, where the movement of the fingers could be distinguished. (Chart 1.)

In the left eye the pupil was oval, with the long axis at 60 degrees, measured 6x5 mm., and did not react to light stimulus, but reacted to convergence and consensually. The media were clear, the optic nerve pale, with the margins of the disc slightly hazy; the retinal arteries moderately contracted; the veins of normal calibre and not tortuous; and the retina edematous, particularly towards the foveal region. No hemorrhages, nor any retinal or choroidal deposits.

In the right eye the pupil was round, 5 mm. in diameter, and reacted sluggishly to light. The media were clear, and the fundus presented practically the same condition as noted in the left eye. From the lower portion of the disc, a short distance from the margin of the nerve, a cilio-retinal artery passed towards the fovea.

Examination of the abdomen failed to show any areas of dullness or tenderness to account for the hemorrhages. A blood examination made at the laboratory of the Jefferson Medical College, five days after the failure of sight, gave the following result:

Hemoglobin, ...	38 per cent.
Erthrocytes, ...	2,088,000
Leucocytes, ...	20,900

Fundus of R. E., showing cilio-retinal artery.

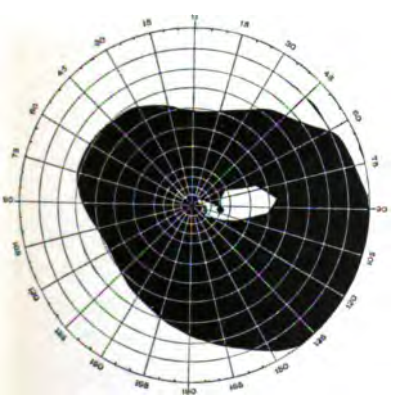

CHART I. Visual field of R. E. nine days after profuse intestinal hemorrhage.

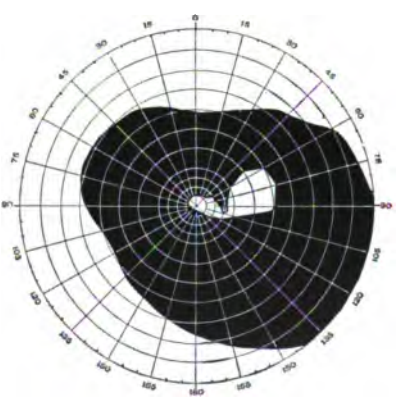

CHART II. Visual field of R. E. four years after failure of vision.

Differential count of Leucocytes:

Finely granular oxyphile cells,	78	per cent.
Lymphocytes,	13	" "
Hyaline cells,	8	" "
Coarsely granular oxyphile cells,	1	" "

Erthrocytes are quite well formed and slightly smaller than normal, and stain well with eosin.

The previous history of the man was good. He occasionally drank malted liquors, was a moderate smoker, never had any serious illness, and denied any specific disease. There was a history of hemorrhagic diathesis in the family.

Treatment by nourishing food, iron, and arsenious acid, followed by large doses of strychnia and iodid of potassium, was unavailing. The left eye remains absolutely blind. During the following three months the field in the left eye gradually increased in size to include the fixing point. At the present time vision equals 20/20, and with the presbyopic correction No. 2 Yaeger can be read. The field made one week ago is shown in Chart 2.

Amblyopia from excessive hemorrhage is a rare affection, as is shown by the investigation of Fries and Pergens. Haab failed to find one unquestioned instance of the affection in 60,000 clinic and private cases. The older theories advanced to account for the blindness were based upon pathological studies made before the introduction of modern methods of determining nerve degeneration, and are therefore unsatisfactory. The explanation most generally accepted was a thrombus or an effusion or hemorrhage into the optic nerve or its sheath.

In Ziegler's opinion the abnormal changes in the composition of the blood following the anemia caused a vasomotor constriction of the retinal arteries with subsequent nerve degeneration. Absolute proof of the degeneration in the ganglion cells and nerve fibres after profuse bleeding has been shown to occur in animals by the experiments of Ward Holden. These slowly progressive nutritive changes most satisfactorily explain the symptoms in the case here reported — the late appearance of

blindness, the slight constriction of the retinal arteries, the moderate retinal œdema, and the absence of tortuosity of the retinal veins and of other signs of interference with the return of the venous blood.

Every case of excessive hemorrhage is not followed by ocular changes. This would seem to strengthen the theory of Ziegler that in certain individuals the anemia causes abnormal changes in the character of the blood, which, acting on the vasomotor system, results in the constriction of the retinal arteries, and subsequent degeneration of the retinal elements. To this extent the condition resembles in many points the retinal changes which follow poisoning by toxic agents.

The appearance of the fundus of the right eye is shown in the drawing reproduced from the water color sketch made one week ago by Miss Washington. The fundus of the left eye is similar, although the nerve is slightly more atrophic, and the cilio-retinal artery present in the right eye is absent.

The cilio-retinal blood vessel through its anastomosis may have contributed to the nourishment of the retinal elements in its vicinity, although the factors which caused the constriction of the main retinal vessel and its branches would apparently have exerted a similar influence upon this artery. This vessel appears from its situation to supply only the area between the disc and the fovea, whereas the preserved field extends beyond the fixing point to the temporal side.

DISCUSSION.

DR. ALLYN. — The only remark I would offer would be a suggestion in regard to the treatment in such an emergency. We have all had the experience and know that with profuse hemorrhage there is often a sense of darkness coming on and have noticed that intravenous injection restores the vision, hence the question arises whether injection would be of service here.

DR. SWEET. — I have thought of that and had I seen the man at first would have given such an injection, but I did not see the patient until the ninth day.

RED
GR.
RED
GR.
SMK
GR.
RED
BL.
GR.
PUR
WHT
RED
RED
BL.
RED
PUR
GR.
YEL

AN IMPROVED LANTERN FOR TESTING COLOR PERCEPTION.

BY CHARLES H. WILLIAMS, M.D.,
BOSTON, MASS.

Further experience with a lantern as a means of testing the color sense, especially when the tests are to be made by railway officials, has shown that the simpler the lantern, without lessening its efficiency, the better will be the results obtained.

In a former paper before this Society, a lantern was described with two discs, the lower carrying thirteen colors and the upper disc having three empty spaces and five modifying colors, to be used in combination with the colors of the lower disc. In practice, usually only the colors in the lower disc were used, and the upper disc added an additional expense and complication to the lantern.

This year when some lanterns were ordered for use on the Northern Pacific, and the Canadian Pacific roads, a new model was made, which seems to be better than the old. The cut shows the front of this model, with one disc carrying eighteen colors, seven shades of red, five of green, two of blue, and one each of yellow, smoke, purple, and colorless glass. Under each color is an illuminated number, screened from the man examined, but easily seen by the examiner, by means of which the record of the examination can be easily made as it proceeds. Inside the lantern is a shutter which can be moved vertically so as to show either two or one colored light at a time, and with either the full opening, the medium sized, or the smallest opening, representing lights at different distances from the observer. In case an electric current is available, the electric lamp with two lights and a small rheostat in its base, by which the intensity of the lights can be regulated (as described in the report of 1901), gives the best results, but where this cannot be had, an oil lamp with two burners does very well.

More extended use of the lantern test is showing a larger number of cases where the worsted test has been passed satisfactorily, but who fail with the lantern, or when tried with distant signal lights. The rule, first adopted on the Dutch railways, providing that in every case the test for color perception is to be made both with the colored worsteds and with the lantern, is the only safe one to follow.*

DISCUSSION.

DR. HUBBELL. — I have been in the habit of using the worsteds in the examination of railroad employees and have never used the lantern, my theory being that while the lantern may serve the purpose for which it is designed, yet the worsteds answer every practical purpose so far as the necessity of the railroad is concerned. If the candidate fails to match the worsteds properly he is rejected, and I would like to ask if that is not sufficient.

DR. WILLIAMS. — In answer to that question, the lantern is designated to be used in addition to the worsted test. The latter gives you in some respects more information than the lantern; you get more confusion colors and can find out whether there is a greater loss of color-sense for red or for green; but the worsted test does not give you an absolute answer to the question whether the man is a safe one, or not, for the service; he may pass the worsted test and yet fail on the lantern test, and when tested with signal lights may fail to recognize the difference between a red and a green light. The men recognize the fact that this lantern test is more like the conditions under which they work in reading distant signals, and they make less objection to it on this account.

DR. PERCY FRIDENBERG. — I would like, in this connection, to show you a little hand apparatus for testing the central color perception. It is arranged like the ophthalmoscope and gives the patient but a small area for perception, and this may be shown or covered quickly. It often detects a central color defect when the patient would pass the worsted test because the area covered by the examination is so much larger.

DR. RANDALL. — I have used a similar arrangement, that of Dr. Noyes, for the past fifteen years and find it exceedingly valu-

*The Southern Pacific Company has recently ordered twenty of these improved lanterns for testing the color sense of the railway employees of that company on its different divisions; in addition to the tagged Holmgren worsteds.

able; it differs in mechanism but not in theory. It certainly seems possible that we shall by the lantern test detect some of these cases which would be extremely dangerous if allowed to go on the basis of the worsted test alone. I have spoken before of a point that was brought out by Dr. Thomson many years ago, of making the color examinations in the presence of a group of men so that the rest act as a jury to see how the man makes his mistakes. It is an easy method of securing the support of the employees themselves, and when they see a fellow engineer, for instance, trying to match wrong colors they are very firm in their own minds that he is not a safe man to run an engine.

REPORT OF THE COMMITTEE ON STANDARD TEST-TYPES, AND ON READING-TESTS.

Your committee beg leave to submit:

1. That the standard of normal acuteness of vision assumed by Snellen, namely, the ability to recognize isolated capital letters whose height subtends a visual angle of five minutes (5′) and the width of whose component lines subtends an angle of one minute (1′), also Snellen's notation embodied in the formula, $V=\frac{d}{D}$, as used by him to record the observed acuteness of vision, ought to be definitively retained.

2. That a gradation of the several sizes of test-letters in geometrical progression, conserving as many as may be of the numbers included in Snellen's series, is to be preferred to the sequence of unequal ratios adopted by him and still in general use. Two geometrical series, based on the common ratios, $1 : \sqrt{2}$ and $1 : \sqrt[3]{2}$, respectively, as explained in detail in an appendix to this report, are recommended.

3. That the simplified form of capital letters known to American printers and sign-painters as "Gothic" is to be preferred to the "block-letter" employed by Snellen.

4. That for reading-tests (following Jaeger) ordinary print

of uniform character and gradation in size, as far as practicable, should be used.

5. That the standard, in reading, should be the ability to read print in which the height of the short "lower-case" letters subtends a visual angle of five minutes (5′). To record the observed reading power, it is recommended that Snellen's notation be employed in the slightly altered form, $L = \frac{d}{D}$, in which L (*lectio*) represents the reading power, d the greatest distance (in *decimetres*) at which the print is read, and D the distance (also in *decimetres*) at which it subtends the standard angle of five minutes.

Series of test-types and reading-tests, embodying these recommendations, are now in course of preparation; from the material at hand it is believed that standards more perfect than have been hitherto produced may be arranged.

CHARLES H. WILLIAMS,
Chairman;
WILLIAM THOMSON;
WILLIAM S. DENNETT;
JOHN GREEN.
Committee.

APPENDIX TO THE REPORT.

BY DR. JOHN GREEN, ST. LOUIS, MO.

The publication of the Test-Letters (*letterproeven*) of Snellen (Utrecht, 1862) marks the beginning of the systematic testing of the acuteness of vision in clinical work. Capital letters of simple form, made up of lines whose thickness (equal to one-fifth the height of the letter) subtends an angle of 1′ at the distance at which the particular size of letter is intended to be viewed, afford the best means at our disposal for a quick and practically accurate determination of the acuteness of vision, and also for observing the modifying effect of lenses. Snellen's notation, also, as expressed in the formula —

$$V = \frac{d}{D},$$

in which V (*visus*) represents the acuteness of vision, d the distance at which the letters are viewed, and D the distance at which the smallest size of letter correctly named is recognizable by an average normal eye, has commanded universal acceptance. With the exception of changes in the sequence of the letters in successive editions, and the change (1875) from the Paris foot to the *metre*, as the measure in which d and D are expressed, Snellen's Test-Letters, as printed today under the direction of their inventor, remain the same as when they were first published forty-one years ago.*

The height of the letter which subtends an angle of 5′ at any distance D and the thickness of the lines composing the letter are, respectively,

$$D\ (2 \tan 2.5'),$$
$$D\ (2 \tan 0.5').$$

Similarly, for a letter subtending an angle of 60′ at the distance d, the height of the letter and the thickness of its component lines are, respectively,

$$d\ (2 \tan 30'),$$
$$d\ (2 \tan 6').$$

For angles of such small magnitude the tangents are practically proportional to the angles; the ratio (1 : 5) of the thickness of the component lines to the height of the letter and the desig-

*The late Dr. Ezra Dyer, one of the founders of the American Ophthalmological Society, then entering on the practice of ophthalmology in Philadelphia after a prolonged period of study in Europe, the last months of which were passed at Utrecht, printed (1862) for private use a small number of impressions of a sheet of letters embodying the theory which he had learned from Snellen. Although anticipating by a few months the actual publication of Snellen's standard Test-Types, Dyer made no claim to priority, but always referred to Snellen as the inventor. In this sheet, letters of different patterns were used in juxtaposition, but the plan was wholly that of Snellen. The credit due to Dyer in this connection is for his prompt recognition of the importance of Snellen's invention, and for making it known to his colleagues in America in advance of its general promulgation in Europe. This estimate of the part taken by Dyer in the introduction of the new method is based on his own statements, as made to the writer in 1862.

It is on record that Snellen first evolved the principle expressed in the formula given in the text, but that he made successive trials of different forms of letters before the definitive selection of his "Block-"letter capitals (see Donders: Accommodation and refraction of the Eye, pp. 32, 97, and 189, London, 1864.)

nation of the several sizes of letters by numbers proportional to their height (Snellen) are, therefore, correct in principle.†

From their first publication Snellen's test-letters have appeared to the writer to be susceptible of improvement, both as regards the construction of the individual letters and the adoption of a uniform gradation in size. A sheet of letters based on the simplified form known to printers and sign painters as "Gothic" was drawn on wood blocks by the writer and contributed, together with other illustrations, to Dr. H. W. Williams's "Recent Advances in Ophthalmic Science"; Boston, 1866. A paper entitled "Test-Letters in Geometrical Progression" was presented the next year (1867) at the Fourth Annual Meeting of the American Ophthalmological Society, and a sheet of "Gothic" letters, printed from stone, was published in the Transactions of the Society for 1867-68.

In this communication two different ratios of progression were proposed, giving two descending series with the common ratios, $r=\sqrt{\frac{1}{2}}$ and $r=\sqrt[3]{\frac{1}{2}}$, respectively. In order to retain as many as possible of the numbers of Snellen's scale and, at the same time, to make the transition from any line of letters to the next line small enough to meet the stricter requirements of clinical work, the second of these two ratios was adopted in the construction of the engraved sheet of letters. The letters in this sheet range from CC to VIII of Snellen's original scale.

Substantially the same series, in a modified form of "block-" letter, was presented to the Fourth International Ophthalmological Congress, and was published, engraved on wood, in the Transactions of the Congress (London, 1873). In this sheet only a single letter was given for each gradation in size, an arrangement which has been found to be saving of time and especially useful in making preliminary tests. A reproduction of this series, with a different sequence of the letters, was con-

† The expression

$$V=\frac{d}{D}$$

is to be taken in the sense that the letters designated by D are the smallest correctly named at the distance d. For this reason (following Snellen) the fractional expression should not be reduced either to lower terms or to the decimal form.

tributed to the American edition of "Carter on the Diseases of the Eye" (Philadelphia, 1876).

The abandonment, by Snellen, of his original scale based on the Paris foot for a new scale based on the *metre* (*Optotypi ad visum determinandum*, Utrecht, 1875,) suggested a revision of the two series in geometrical progression, in order to adapt them to the metric notation. A collection of new test-letters was accordingly engraved, on separate blocks of type-metal, in 1885. The special form of "block-"letter, used first in 1872, was retained, and the letters were arranged both in lines (after Snellen) and as single letters of progressively decreasing size (as in the sheet published in the Transactions of the Fourth International Ophthalmological Congress). A specimen sheet of "block-"letters from this collection was published in Dr. A. H. Buck's "Reference Handbook of the Medical Sciences," vol. V, article Optometry (Wm. Wood and Company, New York, 1887).

In these series, in metric notation, an alternative notation was given in feet, assuming one-third of a *metre* in the place of the somewhat smaller Paris foot originally employed by Snellen.

The construction of series in geometrical progression, as applicable to test-letters and other equivalent characters, is shown as follows:

Let

$$a,\ b,\ c,\ d,\ e,\ \text{etc.}$$

represent a series of numbers in geometrical progression based on the common ratio r; the ratio of any term of the series to the next higher term will then be $\frac{1}{r}$.

$$\text{Let} \begin{cases} r=2 \\ \frac{1}{r}=\frac{1}{2} \end{cases} \quad . \quad . \quad . \quad . \quad . \quad . \quad . \quad . \quad . \quad . \quad [1]$$

$$\text{Let} \begin{cases} r=\sqrt{2}=1.4142, \text{ or approximately } 1.4 \\ \frac{1}{r}=\sqrt{\frac{1}{2}}=0.7071, \text{ or approximately } 0.7 \end{cases} \quad . \quad . \quad . \quad [2]$$

$$\text{Let} \begin{cases} r=\sqrt[3]{2}=1.2599, \text{ or approximately } 1.26 \\ \frac{1}{r}=\sqrt[3]{\frac{1}{2}}=0.7937, \text{ or approximately } 0.8 \end{cases} \quad . \quad . \quad . \quad [3]$$

Taking any term of the series =10, we obtain the numbers:

[1] 2.5, 5, 10, 20, 40, 80, etc., [i]

[2] 2.5, 3.5, 5, 7, 10, 14, 20, 28, 40, 56, 80, etc., [ii]

[3] 2.5, 3.15, 4, 5, 6.3, 8, 10, 12.6, 16, 20, 25.3, 32, 40, 50.6, 64, 80, etc., [iii]

The approximate ratios, $r = 1.4$ and $\frac{1}{r} = 0.7$ [2], are almost exactly 1% less than the true ratios.

The simplified ratio, $r = 1.26$ [3], is practically exact; the approximate ratio, $\frac{1}{r} = 0.8$ [3], is a little less than 0.8% in excess of the true ratio.

In engraving the several sizes of letters the attempt has been made to construct them as accurately as possible in true geometrical progression; using the approximate numbers in the notation only, with a view to reducing the use of fractions to a minimum in the record.

Series [ii] and [iii] expressed in terms of *metres* and of feet (assuming 1 foot = $\frac{1}{3}$ *metre*) are given in the following table:

GEOMETRICAL SERIES [ii]			GEOMETRICAL SERIES [iii]		
IN METRES.		IN FEET.	IN METRES.		IN FEET.
Exact.	Approximate.	Approximate.	Exact.	Approximate.	Approximate.
2.5	2.5	7.5	1.9842	2.	6.
3.5355	3.5	10.5	2.5	2.5	7.5
5.	5.	15.	3.1498	3.15	9.5
7.0710	7.	21.	3.9685	4.	12.
10.	10.	30.	5.	5.	15.
14.1421	14.	42.	6.2996	6.3	19.
20.	20.	60.	7.9370	8.	24.
28.2842	28.	85.	10.	10.	30.
40.	40.	120.	12.5992	12.6	38.
56.5684	57.	170.	15.8740	16.	48.
80.	80.	240.	20.	20.	60.
			25.1984	25.2	75.6
			31.7480	32.	96.
			40.	40.	120.
			50.3968	50.4	151.
			63.4960	64.	192.
			80.	80.	240.

Series [iii] has been employed by the writer for test-letters in "Gothic" or in "block-"letter capitals; series [ii] has been adopted in the case of letters in German text, in arrangements of Snellen's character E turned in four different directions, and in the very practical test-characters especially designed for children and illiterates by Dr. A. E. Ewing, — all included in the collection of 1885.

The "block-"letters used by Snellen approach very closely the so-called Boston "block-"letter of the sign painters in the United States. The so-called New York "block-"letter, in which the terminal cross-strokes of the individual capitals measure only two squares instead of three squares, affords a somewhat larger number of different letters of approximately uniform legibility, and has been preferred and used by the writer since 1872.* The "Gothic" capitals, as employed in 1866 and 1867, were adversely criticised at the time, as having an "unfinished" appearance, and as departing too widely from Snellen's standards. The adoption of the "Gothic" letter by Monoyer in his series of test-letters, in arithmetical progression, (1877) and the steadily growing use of that form of letter in printing and in sign painting during the past thirty years, have gone far to remove former prejudice against it, and it is the opinion of the committee on standard test-types that the "Gothic" letter is, on the whole, to be preferred. It is therefore recommended that a renewed attempt be made to produce an acceptable series in this form of letter, to be presented at a future meeting of this Society; it is hoped that such a series may be shown at the next annual meeting.

The selection of such letters of the alphabet as are best adapted to use as visual tests turns somewhat on the kind of letter, but much more on the form and construction of individual letters. Rejecting I J, as too narrow; — M W, as too wide; —

*The evolution of the forms of individual letters in sign painting has been determined mainly by the necessity of securing the greatest possible legibility at a distance, whereas in designing type for use in printing the purpose has been mainly for "display." A study of the practice of sign painters is, therefore, especially suggestive of forms suitable for use as tests in distant vision.

G Q, as unsatisfactory in their "block-"letter and "Gothic" forms; — K X, on account of their oblique lines; — B S, by reason of too great preponderance of horizontal or approximately horizontal lines; — L, as more easily recognizable than the other letters made up of rectangular lines; — R, as liable to be confounded with N or P; — Y, as often miscalled T or V; — and Z, which is found to be a stumbling block to many children and half-illiterates; — there remain five square letters — E F H N T; — two letters of triangular form — A V; — and five round or half-round letters —C D O U P. Of these it has been found that A and V, although of somewhat smaller area than the square letters, are of nearly equal legibility; but that the round letters are somewhat less easily recognized. C D O, — F P, — H N, — and U V — also form minor confusion groups or pairs, which must be taken into account in interpreting and recording individual tests made with persons of more or less accurate habits of observation.*

The modern method of dry printing from wood or type-metal blocks, or from electrotypes made from such blocks, may be made to yield very clear and black impressions, besides doing away with the distortion incident to the unequal shrinkage of different kinds of paper when the printing has been done from a lithographic stone or from copper or steel plates engraved with sunken lines and surfaces. In this manner of printing it is also practicable to mount each letter on a separate block, and thus to vary the sequence of the letters on different sheets.

* The observations upon which the selection of letters suggested in the text is based have been made almost exclusively on the "block-"letters used by the writer since 1872. The very striking differences in legibility of unselected letters of the "Gothic" form have been especially investigated by Dr. W. S. Dennett (Trans. Am. Ophth. Soc., 1885).

TRANSACTIONS

OF THE

AMERICAN

OPHTHALMOLOGICAL SOCIETY.

Fortieth Annual Meeting.

ATLANTIC CITY, N. J., 1904.

Vol. X, Part II.

HARTFORD:
PUBLISHED BY THE SOCIETY.
1904.

4621

PRESS OF THE CASE, LOCKWOOD & BRAINARD COMPANY.

TABLE OF CONTENTS.

	PAGE.
Members of the society,	201
Minutes of the fortieth annual meeting,	205
Operations upon the eyeball in the presence of an infected conjunctival sac; Dr. C. S. Bull,	212
Concerning certain non-traumatic perforations of the macula lutea; Dr. G. E. de Schweinitz,	228
Conjunctivitis nodosa, with histological examination; Dr. G. E. de Schweinitz and E. A. Shumway,	237
Intra-ocular tuberculosis with report of two cases; Dr. W. C. Posey,	244
Case of conglomerate tubercle of the choroid; Dr. T. R. Pooley,	256
A case of congenital intra-ocular tumor containing epithelium and cartilage; Dr. A. N. Alling,	265
A severe case of uveitis treated with radium; Dr. C. H. Williams,	269
Some observations on the prognosis and treatment of hypopion-ulcer of the cornea; Dr. C. J. Kipp,	275
An uncommon congenital anomaly in the vitreous chamber and the inner membranes of both eyes; Dr. C. J. Kipp,	279
The bacteriological diagnosis of the diphtheria bacillus especially in conjunctivitis; Dr. A. Knapp,	283
A case of mind-blindness unique in that the entire mesial surface of both occipital lobes and both optic radiations were preserved; Dr. W. A. Holden,	286
The cortical fusion of some color sensations; Dr. C. H. Williams,	290
A case of ophthalmoplegia-externa bi-lateral; Dr. W. E. Lambert,	294
A case of simple glaucoma with some unusual features; Dr. W. E. Lambert,	297
Prism exercises, their indications and technique; Dr. A. Duane,	300
The pathologic results of dextrocularity and sinistrocularity; Dr. G. M. Gould,	306
The muscle of Horner and its relation to the retraction of the caruncle after tenotomy of the internal rectus; Dr. L. Howe,	319
Cystadenoma of the lachrymal gland; Dr. E. Stieren,	323
Traumatic emphysema of orbit and lids; Dr. H. F. Hansell,	326
The act of winking and its photographic measurements; Dr. L. Howe,	332
Sympathetic neuro-retinitis and serous uveitis following enucleation with implantation of glass globe, resection of optic nerve — recovery; Dr. R. Sattler,	337

PAGE.

Angelucci's modification of the technique of the cataract operation — fixation of superior rectus and completion of entire operation without speculum or aid of assistant; Dr. R. Sattler, . . 342

A rare tumor arising from the pars ciliaris retinæ (terato-neuroma) of a nature hitherto unrecognized, and its relation to the so-called glioma-retinæ; Dr. P. H. Verhoeff, ... 351

The importance of testing the ocular muscle-balance for *near* as well as for distant vision; Dr. S. Theobald, ... 377

Observations of a case of bi-temporal hemianopsia with some unusual changes in the visual fields; Dr. C. A. Veasey, . . . 383

Report of two cases of family macular degeneration of the cornea; Dr. C. A. Veasey, ... 387

Symmetrical enlargement of parotid and lachrymal glands — nodular iritis; Dr. C. W. Cutler, ... 390

Excision of the superior cervical ganglion of the sympathetic for simple glaucoma; Dr. C. W. Cutler, ... 397

Report of the Committee on Standards, ... 403

Improvements in the refractometer for the correction of ametropia described in the Transactions of 1902; Drs. Wm. and A. G. Thomson, ... 409

MEMBERS

OF THE

American Ophthalmological Society.

1904-1905.

ACTIVE MEMBERS.

The (*) indicates *Associates.*

NAME.	RESIDENCE.	PLACE.
Dr. A E. ADAMS,	44 Grand Street,	Newburg, N. Y.
*Dr. J. L. ADAMS,	38 East 51st Street,	New York, N. Y.
Dr. L. A. W. ALLEMAN,	64 Montague Street,	Brooklyn, N. Y.
Dr. A. N. ALLING,	199 York Street,	New Haveh, Conn.
Dr. G. W. ALLYN,	515 Penn Avenue,	Pittsburg, Pa.
Dr. A. ALT,	3036 Locust Street,	St. Louis, Mo.
†Dr. J. A. ANDREWS,	107 Madison Avenue,	New York, N. Y.
Dr. S. C. AYRES,	4 West 7th Street,	Cincinnati, Ohio.
Dr. WM. T. BACON,	75 Pratt Street,	Hartford, Conn.
Dr. H. W. BRADFORD,		Wolfboro, N. H.
*Dr. GUSTAVE E. BRUÈRE,	413 Oregonian Building,	Portland, Oregon.
*Dr. H. D. BRUNS,	830 Canal Street,	New Orleans, La.
Dr. CHARLES S. BULL,	47 West 36th Street,	New York, N. Y.
Dr. F. BULLER,	123 Stanley Street,	Montreal, Canada.
Dr. SWAN M. BURNETT,	916 Farragut Sq. (17th St.),	Washington, D. C.
Dr. PETER A. CALLAN,	35 West 38th Street,	New York, N. Y.
Dr. F. P. CAPRON,	118 Angell Street,	Providence, R. I.
*Dr. W. M. CARHART,	252 Madison Avenue,	New York, N. Y.
Dr. W. H. CARMALT,	87 Elm Street,	New Haven, Conn.
*Dr. JOHN T. CARPENTER, JR.,	1419 Walnut Street,	Philadelphia, Pa.
*Dr. BURTON K. CHANCE,	1405 Locust Street,	Philadelphia, Pa.
Dr. H. B. CHANDLER,	34½ Beacon Street,	Boston, Mass.
*Dr. J. W. CHARLES,	211 Vanol Building,	St. Louis, Mo.
Dr. WM. CHEATHAM,	303 West Chestnut Street,	Louisville, Ky.
Dr. F. E. CHENEY,	126 Commonwealth Avenue,	Boston, Mass.
Dr. J. H. CLAIBORNE,	39 West 36th Street,	New York City.
Dr. C. F. CLARK,	188 East State Street,	Columbus, Ohio.
Dr. DAVID COGGIN,	7 Chestnut Street,	Salem, Mass.
*Dr. WM. G. CRAIG,	75 Pratt Street,	Hartford, Conn.
Dr. C. M. CULVER,	36 Eagle Street,	Albany, N. Y.
*Dr. C. W. CUTLER,	52 West 53d Street,	New York, N. Y.

†Temporarily residing at Santa Barbara, Cal.

NAME.	RESIDENCE.	PLACE.
Dr. W. S. DENNETT,	8 East 49th Street,	New York, N. Y.
Dr. HASKET DERBY,	182 Marlboro Street,	Boston, Mass.
Dr. RICHARD H. DERBY,	9 West 35th Street,	New York, N. Y.
Dr. LEWIS S. DIXON,	232 Clarendon Street,	Boston, Mass.
*Dr. ALEXANDER DUANE,	49 East 30th Street,	New York, N. Y.
Dr. J. B. EMERSON,	20 East 30th Street,	New York, N. Y.
Dr. ARTHUR E. EWING,	2670 Washington Avenue,	St. Louis, Mo.
Dr. T. H. FENTON,	1319 Spruce Street,	Philadelphia, Pa.
Dr. GEORGE F. FISKE,	100 State Street,	Chicago, Ill.
*Dr. W. H. FOX,	1826 Jefferson Place,	Washington, D. C.
*Dr. PERCY FRIDENBERG,	114 West 120th Street,	New York, N. Y.
Dr. H. FRIEDENWALD,	1029 Madison Ave.,	Baltimore, Md.
Dr. B. F. FRYER,	Cor. 9th and Cherry Streets,	Kansas City, Mo.
Dr. G. M. GOULD,	119 South 17th Street,	Philadelphia, Pa.
Dr. H. Y. GRANT,	414 Delaware Avenue,	Buffalo, N. Y.
Dr. JOHN GREEN,	2670 Washington Avenue,	St. Louis, Mo.
Dr. EMIL GRUENING,	36 East 57th Street,	New York, N. Y.
*Dr. C. W. HADDOCK,		Beverly, Mass.
Dr. G. W. HALE,	Wilcox Building,	Nashville, Tenn.
Dr. WM. D. HALL,	4 Arlington Street,	Boston, Mass.
Dr. H. F. HANSELL,	1528 Walnut Street,	Philadelphia, Pa.
Dr. GEORGE C. HARLAN,	1515 Walnut Street,	Philadelphia, Pa.
*Dr. HERBERT HARLAN,	516 Cathedral Street,	Baltimore, Md.
Dr. DAVID HARROWER,	9 Elm Street,	Worcester, Mass.
Dr. N. D. HARVEY,	262 Benefit Street,	Providence, R. I.
*Dr. H. H. HASKELL,	34 Commonwealth Avenue,	Boston, Mass.
Dr. GUSTAVUS HAY,	383 Marlborough Street,	Boston, Mass.
Dr. NEIL J. HEPBURN,	317 West 23d Street,	New York, N. Y.
Dr. WARD HOLDEN,	43 West 48th Street,	New York, N. Y.
Dr. E. E. HOLT,	723 Congress Street,	Portland, Me.
Dr. LUCIEN HOWE,	87 West Huron Street,	Buffalo, N. Y.
Dr. A. A. HUBBELL,	212 Franklin Street,	Buffalo, N. Y.
Dr. D. W. HUNTER,	80 West 40th Street,	New York, N. Y.
Dr. J. W. INGALLS,	874 Lafayette Avenue,	Brooklyn, N. Y.
Dr. E. E. JACK,	215 Beacon Street,	Boston, Mass.
Dr. EDWARD JACKSON,	McPhee Building,	Denver, Col.
Dr. B. JOY JEFFRIES,	15 Chestnut St., Beacon Hill,	Boston, Mass.
Dr. W. B. JOHNSON,	170 Broadway,	Paterson, N. J.
*Dr. H. W. KILBURN,	192 Marlborough Street,	Boston, Mass.
Dr. CHARLES J. KIPP,	560 Broad Street,	Newark, N. J.
*Dr. ARNOLD KNAPP,	26 West 40th Street,	New York. N. Y.
Dr. H. KNAPP,	26 West 40th Street,	New York, N. Y.
Dr. CARL KOLLER,	681 Madison Avenue,	New York, N. Y.
Dr. CHAS. W. KOLLOCK,	Cor. Wentworth & Com'g Sts.,	Charleston, S. C.
Dr. W. E. LAMBERT,	8 West 35th Street,	New York, N. Y.
*Dr. W. B. LANCASTER,	101 Newbury Street,	Boston, Mass.
*Dr. J. C. LESTER,	179 Schermerhorn Street,	Brooklyn, N. Y.

NAME.	RESIDENCE.	PLACE.
Dr. F. N. LEWIS,	35 W. 36th Street,	New York City.
Dr. J. A. LIPPINCOTT,	Arrott Bdg., Wood St. & 4th Av.,	Pittsburg, Pa.
Dr. F. B. LORING,	1420 K Street,	Washington, D. C.
Dr. D. B. LOVELL,	32 Pearl Street,	Worcester, Mass.
Dr. F. W. MARLOW,	731 University Block,	Syracuse, N. Y.
Dr. W. V. MARMION,	1110 8th Street, N. W.,	Washington, D. C.
Dr. W. B. MARPLE,	35 W. 53d Street,	New York, N. Y.
Dr. ARTHUR MATHEWSON,		South Woodstock, Ct.
Dr. CHAS. H. MCILWAINE,	264 Willis Avenue,	New York, N. Y.
Dr. R. J. MCKAY,	Cor. 9th and Market Streets,	Wilmington, Del.
Dr. C. S. MERRILL,	23 Washington Avenue,	Albany, N. Y.
Dr. B. L. MILLIKIN,	278 Prospect Street,	Cleveland, Ohio.
Dr. HORACE GEO. MILLER,	262 Benefit Street,	Providence, R. I.
Dr. J. LANCELOT MINOR,	14 Randolph Building,	Memphis, Tenn.
Dr. W. F. MITTENDORF,	140 Madison Avenue,	New York, N. Y.
Dr. RUSSELL MURDOCH,	418 Cathedral Street,	Baltimore, Md.
Dr. CHARLES A. OLIVER,	1507 Locust Street,	Philadelphia, Pa.
Dr. H. S. OPPENHEIMER,	16 E. 32d Street,	New York, N. Y.
Dr. R. J. PHILLIPS,	123 So. 39th Street,	Philadelphia, Pa.
Dr. THOMAS R. POOLEY,	107 Madison Avenue,	New York, N. Y.
Dr. WILLIAM C. POSEY,	1831 Chestnut Street,	Philadelphia, Pa.
Dr. M. H. POST,	Beaum't St., cor. Wash. Av.,	St. Louis, Mo.
*Dr. L. A. PREFONTAINE,	15 Fuller Building,	Springfield, Mass.
Dr. H. R. PRICE,	1290 Pacific Street,	Brooklyn, N. Y.
Dr. J. S. PROUT,	29 Schermerhorn Street,	Brooklyn, N. Y.
*Dr. WALTER L. PYLE,	1806 Chestnut Street,	Philadelphia, Pa.
*Dr. ALEX. QUACKENBOSS,	71 Newbury Street,	Boston, Mass.
Dr. ALEX'R RANDALL,	1717 Locust Street,	Philadelphia, Pa.
Dr R. L. RANDOLPH,	816 Park Avenue,	Baltimore, Md.
Dr. WILLIAM RANKIN,	23 Cedar Street,	Newark, N. J.
Dr. J. M. RAY,	423 West Chestnut Street,	Louisville, Ky.
*Dr. R. G. REESE,	58 East 25th Street,	New York, N. Y.
Dr. R. A. REEVE,	22 Shuter Street,	Toronto, Canada.
Dr. O. H. REIK,	412 Cathedral Street,	Baltimore, Md.
Dr. STEPHEN O. RICHEY,	732 17th Street,	Washington, D. C
Dr. CHARLES E. RIDER,	53 South Fitzhugh Street,	Rochester, N. Y.
Dr. WHEELOCK RIDER,	53 South Fitzhugh Street,	Rochester, N. Y.
*Dr. G. O. RING,	1900 Chestnut Street,	Philadelphia, Pa.
Dr. H. W. RING,	187 Church Street,	New Haven, Conn
Dr. SAMUEL D. RISLEY,	1824 Chestnut Street,	Philadelphia, Pa.
Dr. EDMUND C. RIVERS,	1632 Welton Street,	Denver City, Col.
Dr. WM. K. ROGERS,	188 East State Street,	Columbus Ohio.
Dr. D. B. ST. JOHN ROOSA,	20 East 30th Street,	New York, N. Y.
*Dr. DUNBAR ROY,	Grand Opera House Block,	Atlanta, Ga.
Dr. JOHN D. RUSHMORE,	129 Montague Street,	Brooklyn, N. Y.
Dr. ROBERT SATTLER,	7th and Race Streets,	Cincinnati, Ohio.
Dr. T. B. SCHNEIDEMAN,	1831 Chestnut Street,	Philadelphia, Pa.

NAME.	RESIDENCE.	PLACE.
Dr. G. E. DE SCHWEINITZ,	1401 Locust Street,	Philadelphia, Pa.
Dr. P. N. K. SCHWENK,	810 North 7th Street,	Philadelphia, Pa.
Dr. HENRY L. SHAW,	19 Commonwealth Avenue,	Boston, Mass.
*Dr. WM. T. SHOEMAKER,	2031 Chestnut Street,	Philadelphia, Pa.
*Dr. WM. A. SHOEMAKER,	1006 Carlton Building,	St. Louis, Mo.
Dr. F. D. SKEEL,	58 E. 25th Street,	New York N. Y.
Dr. J. A. SPALDING,	627 Congress Street,	Portland, Me.
Dr. MYLES STANDISH,	6 St. James Avenue,	Boston, Mass.
*Dr. E. W. STEVENS,	421 McPhee Building,	Denver, Col.
Dr. GEORGE T. STEVENS,	22 East 46th Street,	New York, N. Y.
*Dr. EDW. STIEREN,	Westinghouse Building,	Pittsburg, Pa.
Dr. SAMUEL B. ST. JOHN,	68 Pratt Street,	Hartford, Conn.
Dr. GEO. STRAWBRIDGE,	202 So. 15th Street,	Philadelphia, Pa.
Dr. T. Y. SUTPHEN,	999 Broad Street,	Newark, N. J.
Dr. WM. M. SWEET,	1205 Spruce Street,	Philadelphia, Pa.
Dr. J. OSCROFT TANSLEY,	28 West 43d Street,	New York, N. Y.
Dr. LEWIS H. TAYLOR,	41 South Franklin Street,	Wilkes-Barre, Pa.
Dr. SAMUEL THEOBALD,	304 West Monument Street,	Baltimore, Md.
Dr. CH. HERMON THOMAS,	3634 Chestnut Street,	Philadelphia, Pa.
Dr. A. G. THOMSON,	1426 Walnut Street,	Philadelphia, Pa.
*Dr. EDGAR S. THOMSON,	19 E. 44th Street,	New York, N. Y.
Dr. WILLIAM THOMSON,	1426 Walnut Street,	Philadelphia, Pa.
Dr. JAS. THORINGTON,	120 South 18th Street,	Philadelphia, Pa.
Dr. JOHN VAN DUYN,	111 South Salina Street,	Syracuse, N. Y.
Dr. C. A. VEASEY,	116 South 19th Street,	Philadelphia, Pa.
Dr. O. F. WADSWORTH,	526 Beacon Street,	Boston, Mass.
*Dr. F. L. WAITE,	68 Pratt Street,	Hartford, Conn.
Dr. LEROY P. WALKER,	26 West 91st Street,	New York, N. Y.
Dr. DAVID WEBSTER,	327 Madison Avenue,	New York, N. Y.
Dr. J. E. WEEKS,	46 East 57th Street,	New York, N. Y.
*Dr. CASSIUS D. WESTCOTT,	31 Washington Street,	Chicago, Ill.
Dr. J. A. WHITE,	200 E. Franklin Street,	Richmond, Va.
Dr. W. H. WILDER,	103 State Street,	Chicago, Ill.
Dr. CHAS. H. WILLIAMS,	1069 Boylston Street,	Boston, Mass.
Dr. WM. H. WILMER,	1610 I Street N. W.,	Washington, D. C.
Dr. F. M. WILSON,	834 Myrtle Avenue,	Bridgeport, Conn.
*Dr. WILLIAM L. WOOD,	412 Oregonian Building,	Portland, Oregon.
Dr. HIRAM WOODS,	842 Park Ave.,	Baltimore, Md.
Dr. J. P. WORRELL,	20 South 7th Street,	Terre Haute, Ind.
*Dr. S. LEWIS ZEIGLER,	1700 Walnut Street,	Philadelphia, Pa.
Total, ...		165

HONORARY MEMBERS.

Dr. C. SCHWEIGGER, ...		Berlin, Prussia.
Dr. F. P. SPRAGUE, .	229 Commonwealth Avenue,	Boston, Mass.
Whole number, ...		167

MINUTES OF THE PROCEEDINGS.

FORTIETH ANNUAL MEETING.

HOTEL CHELSEA,

ATLANTIC CITY, N. J., July 13, 1904.

The fortieth annual meeting of the Society was called to order at 9.40 A. M. by the President, Dr. C. S. BULL, who announced the following committees:

On Bulletin: Drs. W. E. Lambert and R. G. Reese.

On Membership: Drs. Jno. Green, W. H. Carmalt, Geo. E. de Schweinitz, S. Theobald, and H. B. Chandler.

Auditing Committee: Dr. W. L. Pyle.

Drs. Mary Buchanan of Philadelphia and F. M. Spalding of Boston were invited as guests of the Society to attend the meetings.

The Committee on Bulletin reported and the following papers were read:

(1.) Intraocular tuberculosis, with report of two cases. Dr. W. C. Posey.

(2.) Case of tuberculous tumor of the fundus oculi. Dr. T. R. Pooley.

Discussed by Drs. de Schweinitz, Pyle, Hansell, Fryer, Mittendorf, Pooley and Posey.

(3.) Intraocular tumor containing hyaline cartilage. Dr. A. N. Alling.

Discussed by Drs. Fryer, Randall, Verhoeff, Alleman, and Alling.

(4.) A severe case of uveitis treated with radium. Dr. C. H. Williams.

Discussed by Drs. Theobald, Williams, Pooley and H. W. Ring.

(5.) Operations on the eyeball in the presence of an infected conjunctival sac. Dr. C. S. Bull.

Discussed by Drs. Kipp, Fryer, Pooley, Pyle, Duane, Theobald, Lambert, Standish, Risley, A. Knapp, H. Woods and Bull.

(6.) Some observations on progress and treatment of hypopion ulcer. Dr. Kipp.

Discussed by Drs. Andrews and Kipp.

(7.) An uncommon congenital anomaly. Dr. Kipp.

(8.) The bacteriological diagnosis of the diphtheria bacillus, especially in conjunctivitis. Dr. A. Knapp.

Discussed by Drs. Verhoeff, Randall and H. Woods.

(9.) Histological examinations in a case of ophthalmia nodosa. Drs. G. E. de Schweinitz and E. A. Shumway.

(10.) Report of a case of symmetrical enlargement of both lachrymal and parotid glands (Miculicz's disease) associated with iritis, possibly tubercular in nature. Dr. C. W. Cutler.

Adjourned till 2.30.

Afternoon Session.

Called to order at 2.45. Reading of papers resumed.

(11.) A case of mind blindness unique in that the entire mesial surface of both occipital lobes and both optic radiations were preserved. Dr. Ward Holden.

(12.) The blending of color impressions in the cerebral visual centers. Dr. C. H. Williams.

(13.) Report of a case of ophthalmoplegia externa totalis with complete recovery. Dr. W. E. Lambert.

Discussed by Drs. Dennett and Randall.

(15.) Prism exercises: their indications and technique. Dr. A. Duane.

(16.) The pathologic results of dextrocularity and sinistrocularity. Dr. G. M. Gould.

Discussed by Drs. Pyle, Lambert, Fridenberg, Callan, Howe, Williams, W. Rider, Standish, Alleman, Verhoeff, and Gould.

(17.) On the muscle of Horner and the operation for advancement of the caruncle. Dr. L. Howe.

Discussed by Dr. S. Theobald.

(18.) A case of cystadenoma of the lachrymal gland. Dr. E. Stieren.

(19.) Simple glaucoma in a young adult, a deep physiological excavation having been noted for years. Dr. W. E. Lambert.

Discussed by Drs. Callan, Risley, Bull, Kipp and Lambert.

(20.) Report of cases of glaucoma treated by sympathectomy. Dr. C. W. Cutler (by title).

(21.) Some improvement upon the refractometer described in 1902. Dr. Wm. Thomson.

Adjourned to executive session at 8.30 o'clock.

Executive Session.

Called to order at 8.45.

The Committee on Membership reported favorably on the following names: Dr. J. W. Charles, St. Louis; W. H. Fox, Washington, D. C.; Burton K. Chase, Philadelphia; H. H. Haskell, Boston; W. M. Carhart, New York, who were declared duly elected associates. The committee also reported a number of names to be referred to the committee for 1905. The chairman of the committee read a letter from Dr. McCormack, representing the American Medical Association, inviting the Society to affiliate itself with that body, and said the committee offered a resolution declining the invitation, which resolution was passed. The committee also presented some correspondence regarding the next meeting of the Congress of American Physicians and Surgeons, and upon vote of the Society the matter was referred to our delegates, with full power to act.

Dr. Green, chairman of the Committee on Time and Place of Meeting, explained the action taken by the American Otological Society at its recent session and offered an amendment to Art. 3 of the By-Laws, so that similar action might be taken by this Society.

Dr. Pooley offered an amendment to Article 2 of the By-

Laws, and Dr. Howe offered a further amendment to Article 1, and an adjournment of five minutes was ordered.

On reassembling these amendments were taken up. Dr. Green's amendment was to substitute for Section 3 the following: "The determination of the time and place of each annual meeting shall be entrusted to a standing committee of three members to be appointed at each annual meeting, and that in the case of the appointment of a committee of similar character and powers by the American Otological Society the two committees shall act together as a committee of conference, with a view to selecting such time and place of meeting as shall best subserve the convenience of members desirous of attending the meetings of both societies." This amendment was carried unanimously.

Dr. Pooley's amendment to Art. 2 was to insert after the words "one year" the following: "But that the President shall not be eligible for re-election to the same office at the expiration of his term of service." This amendment was adopted.

Dr. Howe's amendment was to Art. 1 by inserting after the words "Committee on Membership consisting of five" the following: "One of whom shall be appointed annually and for a term of five years. This new member shall not have served in that capacity within three years previously." This amendment was adopted.

Dr. Howe offered the following resolution: "That the Society hereby extends an invitation to the International Congress of Ophthalmology to hold its next meeting in this country." This was carried, as was also a motion that a committee of three be appointed by the chair to convey this invitation to the proper authorities.

Several names of candidates for membership were then read by the Secretary.

The Treasurer's report was read and reported by the Auditing Committee as correct and was accepted, and an assessment of $5.00 was voted for the ensuing year.

Adjourned to 9.30 A. M. July 14th.

July 14th.

Meeting called to order at 9.45. Reading of papers resumed.

(22.) Traumatic emphysema of orbit and lids. Dr. H. F. Hansell.

(23.) Report of Committee on preparing Test Types. Dr. C. H. Williams.

(24.) On the act of winking, its photographic measurement and diagnostic value in paresis of the motor oculi. Dr. L. Howe.

(25.) Concerning certain non-traumatic perforations of the macula lutea. Dr. G. E. de Schweinitz.

Discussed by Drs. Kipp, Friedenwald and Gould.

(26.) Sympathetic neuro-retinitis and serous uveitis following enucleation and implantation of glass globe; removal of glass globe and resection of optic nerve; recovery; Dr. R. Sattler.

Discussed by Drs. E. S. Thomson, Sutphen, Lambert, Fridenberg, de Schweinitz, and Theobald.

(27.) Cataract extraction as performed after the method of Angelucci of Palermo, by fixation of the superior rectus and without aid of assistant. Dr. R. Sattler.

Discussed by Drs. Pooley, Callan, Theobald, Fridenberg, Ingalls, Williams, St. John, and Sattler.

(28.) Malignant tumor of the pars ciliaris retinæ (neuro teratoma) of a nature hitherto unrecognized. Dr. F. H. Verhoeff (by invitation).

(29.) The importance of testing the ocular muscle balance for *near* as well as for *distant* vision. Dr. S. Theobald.

Discussed by Drs. Posey, Williams, Randall, Theobald and H. Woods.

(30.) Observations on a case of bi-Femporal hemianopsia, with some unusual changes in the visual fields. Dr. C. A. Veasey.

Discussed by Drs. G. C. Harlan and Posey.

(31.) Report of two cases of family macular degeneration of the cornea. Dr. C. A. Veasey.

The Society then went into executive session.

Dr. Williams presented the following resolution: "That the test types for reading distance, as presented by the committee,

be electrotyped and printed at the expense of the Society, and that one set of these test types be sent to each member, with the "Transactions" of this year, and that if any additional sets are desired they be furnished to members at cost." This resolution was carried.

The Committee on Membership for the ensuing year was announced by the President as follows: Dr. Jno. Green, S. Theobald, W. H. Carmalt, Geo. C. Harlan, and Myles Standish (the latter to serve for five years). The President also announced as the Committee to decide Place and Time of next Meeting: Drs. R. Sattler, P. A. Callan, H. B. Chandler; and as Committee on Invitation to International Congress of Ophthalmology Drs. G. E. de Schweinitz, S. D. Risley, and L. Howe. It was afterward voted that this committee have power to add to their number such other members as might be present at the meeting at Lucerne.

Adjourned.

S. B. ST. JOHN,
Secretary.

Members present at the fortieth annual meeting:

Dr. S. D. Risley,
S. B. St. John,
L. Howe,
W. L. Pyle,
W. E. Lambert,
W. T. Shoemaker,
W. C. Posey,
A. Mathewson,
C. E. Rider,
C. S. Bull,
Edw. Stieren,
J. W. Ingalls,
T. Y. Sutphen,
W. H. Carmalt,
R. G. Reese,
H. F. Hansell,
T. B. Schneideman,
C. J. Kipp,
J. A. Andrews,
A. N. Alling,
P. Fridenberg,
B. E. Fryer,
S. Theobald,
W. F. Mittendorf,
G. M. Gould,
T. J. R. Pooley,
A. Duane,
Wm. Thomson,
A. G. Thomson,
G. W. Hale,
H. Friedenwald,
H. Y. Grant,
H. Woods,

Dr. R. G. Phillips,
T. H. Fenton,
W. A. Shoemaker,
J. L. Adams,
L. A. W. Alleman,
E. S. Thomson,
W. S. Dennett,
W. K. Rogers,
A. Knapp,
D. Harrower, Jr.
H. W. Ring,
Myles Standish,
C. W. Cutler,
W. A. Holden,
C. H. Williams,
A. Quackenboss,
F. E. Cheney,
C. H. McIlwain,
G. E. de Schweinitz,
P. A. Callan,
W. M. Sweet,
H. O. Reik,
G. C. Harlan,
B. A. Randall,
G. O. Ring,
Jno. Green,
R. Sattler,
C. A. Veasey,
H. B. Chandler,
W. Rider,
W. G. Craig,
L. A. Prefontaine,
L. S. Dixon.

OPERATIONS UPON THE EYEBALL IN THE PRESENCE OF AN INFECTED CONJUNCTIVAL SAC.

BY CHARLES STEDMAN BULL, A.M., M.D.,

NEW YORK CITY.

Since bacteriology has become a science the ophthalmic surgeon has learned that bacteria play an important part in all forms of suppuration following operations on the eye, for, as a rule, the infection comes from without. We all recognize that infection of the wound may occur during the operative act, as well as afterwards. It may come through the air, from the hands of the operator, from the irrigating solutions employed, or from the instruments used. It may be due to the conditions of the edges of the eyelids, or of the conjunctival sac, or of the lachrymal passages. The danger from aërial infection may be sufficiently guarded against during operations on the eye, to make it of secondary importance. The hands of the surgeon may be made aseptic by careful cleansing and scrubbing of the fingers, and the danger from this source is always slight, because in operations on the eyeball the fingers rarely come in actual contact with the tissues involved in the field of operation.

It is to be assumed that the greatest care is exercised in maintaining the absolute sterility of all fluids used in irrigating before, during, and after the operation, and of all collyria used. These, as well as the pipettes, should be boiled before using.

It is not always possible to be absolutely sure of the aseptic condition of our instruments, either because the fluids used for disinfecting them have not recently been sterilized, or because they may have become infected by the hands of the surgeon or assistants. This more especially applies to operations done at the residence of the patient.

This brings us to a consideration of the most important sources of infection, the edges of the eyelids, the conjunctival

sac, and the lachrymal canaliculi and sac. Here is undoubtedly found the most frequent source of infection, for we never can be sure that the edges of the lids and the conjunctival sac are non-infected and sterile. They are the most dangerous sources of infection, for while it is possible that there may be no pathogenic germs in a normally appearing conjunctiva, we know that sometimes, even in apparently sound lids and conjunctiva, the most virulent germs have been found. We have learned that we cannot with *certainty* make the edges of the lids and the conjunctival sac sterile.

The question, then, whether we shall operate on the eyeball when the conjunctival sac is infected is one of great importance to both surgeon and patient. At the first glance the subject would seem to occupy but a very narrow field, and not to admit of much discussion, but a closer study of the subject opens up the very wide field of bacteriology, which is practically limitless. One of the important facts taught us by modern bacteriology is that a normal conjunctival sac, free from noxious bacteria of all kinds, practically does not exist, or at least does not come within the ken of the ophthalmic surgeon. As far back as 1894 *Gayet* found, after disinfecting the conjunctival sac of his cataract patients, that microbes remained in 75 per cent. of them, and from a study of 213 test-tube cultures he concluded that antiseptic fluids have very little influence over germs in the conjunctival sac.

Rymowicz has given us a still more interesting report on the same subject. He investigated the conditions in one hundred healthy eyes. The conjunctival sac was cleansed with a sterilized physiological salt solution, and then the fluid from the sac was inoculated on agar with coagulated glycerinized beef serum. The conjunctival sac in every case was infected as follows: in 94 cases by the bacillus pseudo-diphtheriticus; in 9 cases by the pneumococcus; in 5 cases by the streptococcus; in 6 cases by the Morax-Axenfeld bacillus; in 6 cases by the staphylococcus aureus; and in 8 cases by the staphylococcus albus.

Another fact that the study of bacteriology has taught us is

that the pathogenicity of micro-organisms is by no means a constant quantity, but differs directly with their capacity to manufacture disease-producing toxins and tox-albumins. This capacity to manufacture toxins is influenced by certain natural and artificial agencies. Such agencies, for example, are unfavorable culture-media in the body, or conditions of life in which the germs are compelled to exist. Within the influence of such agencies these toxins become attenuated or are not manufactured at all. Among the natural attenuating agents sunlight is most powerful, and among the artificial attenuating agents cleanliness in the widest sense is an all-important factor.

Fick (Ueber Mikro-organismen im Conjunctival Sack, 1887) found in fifty cases of apparently normal eyes only twelve per cent. without bacilli. He enumerates seven different varieties of bacilli and three kinds of cocci, among them the staphylococcus aureus and pyogenes.

A microscopical examination of the contents of the conjunctival sac should always be made before operation, as various micro-organisms may cause very similar symptoms. For instance, the presence of disease of the lachrymal passages does not necessarily lead to the conclusion that the acute conjunctivitis is due to the presence of streptococci. Any pathogenetic bacillus of the conjunctival sac may become virulent when the conditions favor its development. But even after a careful microscopical examination, we are not always sure of our results, for the different bacilli vary in their destructive effects at different times. For example, the Koch-Weeks bacillus is apt to cause a distinctly contagious conjunctivitis with severe symptoms, while the conjunctivitis due to the diplococcus is usually not severe, and the conjunctivitis due to the diplo-bacillus of Morax-Axenfeld generally runs a mild and subacute course. Yet not infrequently these conditions are all reversed. The conjunctivitis caused by the staphylococcus and streptococcus is almost always marked by severe symptoms, among them the formation of a pseudo-membrane, which is often with difficulty to be distinguished from a diphtheritic membrane, in spite of microscopical examination.

A brief study of a few of the more common forms of infection of the conjunctiva may help us to a conclusion as to when to operate, if at all, in the presence of infection.

There are several forms of conjunctivitis due to the streptococcic infection. The most common form is distinguished by a marked engorgement of the conjunctival and subconjunctival vessels, slight secretion and slight swelling of the lids. Another form, due to the same microbic infection, shows a thin membrane or pellicle and is called pseudo-membranous. The common name of streptococcic conjunctivitis depends upon the abundant presence of the streptococcus in the secretion, and the impossibility of explaining the clinical symptoms without its intervention, though there may be other microbes associated with it, which do not explain the gravity of the inflammation. The false membrane is not always present, and is generally of extreme tenuity. There is always some swelling of the lids, and almost always a preauricular adenitis. The presence in the secretion of cocci disposed in chains does not prove it to be the streptococcus, for the pneumococcus does the same thing. The bacilli occur more frequently as disseminated diplococci, not to be distinguished from the staphylococcus and pneumococcus. There is no pathognomonic symptom, but the general complex of symptoms will aid in the diagnosis, while a full demonstration is only furnished by cultivation and inoculation, and the bacilli should be numerous in the secretion and cultures. It should not be forgotten that the streptococcus, the staphylococcus, and the diphtheria bacillus may exist in the conjunctival sac without exciting any reaction, and infection can only occur in the presence of traumatism.

In operative cases the streptococcic infection is very grave, and generally leads to rapid perforation of the cornea and general suppuration of the eyeball. It is always difficult to trace the way in which this infection has occurred, or to determine the conditions which have facilitated its development. It is certain that in many cases the infection is developed in pre-existing forms of conjunctivitis, and it is probable that it would not have occurred without a preceding loss of epithelium. It is very doubtful if a

streptococcic infection could be developed in a healthy conjunctiva, and we must regard it as a secondary inflammatory process.

Most of these cases doubtless come from the lachrymal sac, for there is usually slight redness and swelling over the sac and tenderness on pressure, and more or less swelling of the preauricular gland, and more rarely of the parotid and submaxillary glands.

The conjunctivitis due to pneumococcus infection is much rarer than that due to infection by the streptococcus or staphylococcus. It occurs mainly in young persons, and seems to be most prevalent in spring or autumn. Its appearance may be either sporadic or epidemic. It is sometimes met with in children with measles and broncho-pneumonia, and here the symptoms are very severe, especially on the side of the cornea, which rapidly ulcerates, becomes deeply infiltrated, perforates, and ends in panophthalmitis and sometimes in the death of the patient. The pneumococcus seems to occur more frequently in certain localities. For instance, *Rymowicz* reports that in Kasan the pneumococcus conjunctivitis ranged from 18 per cent. to 36 per cent. of the cases, and was often accompanied by iritis and cyclitis, probably from development of toxins. In all the cases reported the pneumococcus has been found in great abundance in the secretion. At other times the symptoms are slight, the cornea is not involved, or, if so, only superficially, and the pneumococci are few in number.

In the case of an infected lachrymal sac, the condition is somewhat more grave. The contents of a suppurating tear-sac are extremely infectious. It needs but a small wound in the cornea, the slightest injury to the corneal epithelium, to set up that most destructive process, ulcus serpens. Yet it is a well-known fact that many patients have suffered for years from suppuration of the lachrymal sac without any infection of the conjunctiva or cornea. Some two years ago *Stock* (Klin. Mon. f. Augenheilk., 1902, p. 116) instituted some experiments on rabbits. The lachrymal sac was infected by the bacillus pyogeneus, bacillus prodigiosus, and the staphylococcus aureus, and he

watched the animals for a varying length of time without result. He satisfied himself that the normal uninjured conjunctival sac of the rabbit could not be infected, and that if the lachrymal sac were extirpated or the lachrymal puncta cauterized by the galvano-cautery, no germs could enter the conjunctival sac from the nose.

Hirota (Centralbl. f. Bakteriologie, 31, Heft 6) carried out similar experiments about the same time. He found that the bacilli of septicæmia and of hen-cholera and the pneumococcus, introduced into the conjunctival sac of the rabbit, only succeeded in infecting it when traumatism was present. He also incidentally demonstrated the influence of the lid action upon the germ contents of the conjunctival sac, by finding that bacteria introduced into the sac all disappeared within ten minutes after the use of irrigating fluids.

In the light of our past experience and of the knowledge gained from the numerous experiments instituted and carried out on animals, it becomes absolutely important that all diseases of the eyelids, edges of the lids, conjunctiva and lachrymal passages, whether suppurative or not, should be treated and cured before undertaking any operation on the eyeball or conjunctiva. Chronic dacryocystitis is the most dangerous source of infection, and if a persistent inflammation of the lachrymal sac resists treatment, the puncta must be obliterated by the actual cautery, or the lachrymal sac must be excised. We have learned by experiments that the bactericidal properties formerly attributed to the natural lachrymal secretion, the tears, do not exist. It is true that successful operations on the eyeball have been performed in the presence of chronic dacryocystitis, but the risk is too great to countenance such unwise action, and the same may be said of operations on the eyeball in the presence of trachoma with purulent discharge. It is by no means safe or wise to be guided in our decision as to operating by the appearance and secretion of the conjunctiva, even when the mucous membrane is smooth and merely red and swollen, for an inflamed conjunctival sac is never to be trusted. Even after a careful bacteriological examination

has been made with negative results, all the steps of an operation should be carried out with the least bruising and violence, in order to avoid preparing a soil in which germs tend to multiply, and we should not operate, where avoidable, in cases in which unfavorable constitutional conditions exist, as they may indirectly be provocative of pathogenetic germ growth.

All this brings us round again to the ever present question: how can the danger of infection be best avoided? From the bacteriological standpoint it would seem that the most favorable results are to be gained by mechanical cleansing of the eyelids and lid-margins and simultaneous irrigation. I do not believe that anything is to be gained by using concentrated antiseptic solutions over indifferent fluids like normal salt or boric-acid solutions for purposes of irrigation. Repeated mechanical cleansing with warm water and soap may do for the region surrounding the eyes, the forehead, eyebrows, temple, and cheek, and the external surface and edges of the lids, but the delicate conjunctiva will not bear such rough handling, and is positively injured by the loss of its epithelium, thus leaving openings for the free entrance of germs.

After the forehead, temple, cheek, external lid surfaces and edges of the lids have been mechanically cleansed in the way mentioned, the conjunctival sac should be repeatedly irrigated with some indifferent sterilized irrigating fluid, and then the fluid collected in the conjunctival sac should be mopped up with sterilized moist cotton pads, before beginning the operation. Operating in this so-called dry manner prevents the entrance of this fluid into the wound, and thus the danger of actually pressing any possibly existing germs into the lips of the wound is avoided.

If care has been taken to avoid operating in the presence of a positively infected conjunctival sac, and if no infection has been introduced during the operation, we may almost with certainty expect rapid and favorable healing of the wound. The rare occurrence of infection after operation may perhaps be explained by the fact that toxic-bacteria are not always present, and that, when present, they are not met with in great numbers, and conse-

quently their virulence is slight, for the danger of infection increases with the number of bacteria present in the sac and in contact with the wound.

It has been thought by some skilled operators that we have another means at our command for preventing infection after an operation, by doing away with the ordinary protective bandage, and protecting the eye merely by the mask, on the principle that the natural motion of the lids is a valued factor in the normal cleansing of the conjunctival sac. From a bacteriological standpoint, this is theoretically correct. But the nature and temperament of the patient must always be considered. In a patient of quiet, equable temperament it might be entirely safe to close the lids by a strip of adhesive plaster and protect the eye from external injury by a mask, but in the majority of cases the writer is convinced that the risk of such a procedure would be too great, owing to the restlessness and irresponsibility of the patient.

Summary. I. A careful microscopical and bacteriological examination should be made of the contents of the conjunctival sac in every suspected case, carrying the examination as far as the cultivation of the bacteria in a proper medium and the subsequent inoculation of the germs.

II. If toxic germs are found in great numbers, no matter what their varieties, no operation on the eyeball should be undertaken until the germs have disappeared, and the conjunctival sac has been rendered as sterile as we can hope to make it.

III. If there be suppurative disease of the lachrymal passages, whether of canaliculi, sac, or nasal duct, all operations upon the eyeball are positively contra-indicated. The lachrymal sac must be excised and the lachrymal puncta must be obliterated by the galvano-cautery, before any operation on the eyeball is undertaken. In the case of a catarrhal dacryocystitis or of mucocele of the sac, both canaliculi should be incised, and the sac injected daily with an antiseptic astringent solution, and free irrigation through the nasal duct carried out until all secretion has ceased. Even in cases of great urgency, as, for example, acute inflammatory glaucoma, the writer would not feel himself justified in modifying the above statement.

IV. If the secretion of the conjunctival sac, on examination, is found to be infected, but the bacteria are few in number and of slight toxic variety, operations may be done on the eyeball when necessary, but these eyes should be opened and examined twice in the twenty-four hours, and the conjunctival sac gently irrigated with warm normal salt solution, or warm sterilized boracic acid solution, and then the eye should be immediately rebandaged.

V. In operating upon the eyeball in the presence of an apparently normal, sterile conjunctival sac, the following steps should be taken:

1st. The forehead, eyebrows, temple, cheek, bridge of the nose, and external surface of the lids should be carefully cleansed with hot water and soap, and dried with aseptic cotton pads.

2d. The margins of the lids should be carefully, but gently, rubbed with sterilized moist cotton pads, and simultaneously irrigated with a warm sterilized physiological salt solution.

3d. Careful irrigation of the conjunctival sac with the same sterilized normal salt solution, and then closing the lids with a moist sterilized cotton pad. The lids should remain closed in this way until the speculum is introduced.

VI. In all cases the bandage should be removed and the eye examined under the strictest aseptic precautions, as strict as those employed at the time of operation.

VII. On the first sign of infection of the wound, the edges of the lids are to be thoroughly cleansed in the same manner as at the time of operation, the conjunctival sac is to be thoroughly irrigated with the sterilized normal salt solution, the wound is to be reopened and cauterized through its entire length with the galvano-cautery, and the anterior chamber is to be gently but carefully irrigated with a sublimate solution (1-5000), and then the conjunctival sac must be again irrigated and the lids must be closed simply under a moist sterilized pad.

DISCUSSION.

Dr. C. J. Kipp. — While I fully agree with the rules laid down by Dr. Bull, there are certain exceptions in which we have to

operate without them. I had a case a couple of years ago of a very old man with but one eye. He came to me with eczema of the lids and cataract. The puncta had the appearance of blenorrhœa of the sac, but no secretion could be pressed out. I treated this man for a while in the ordinary way and finally operated. As I said before, he was old and feeble. Immediately on making the corneal incision there was collapse of the cornea, so much so that I had difficulty in seeing the lens. I performed an iridectomy and succeeded in evacuating the lens. By that time the corneal wound had separated to the extent of 1 mm. and the edges had turned in. I had no syringe with which to inject the anterior chamber. I left the eye alone, simply applying a mask, as I usually do. On the fourth day after the operation he developed a severe conjunctivitis, with very profuse muco-purulent discharge. The wound healed by first intention. I should have said that I tied the puncta, both upper and lower lid. I made a subsequent discission of the capsule and there was again collapse of the cornea.

It shows that, though desirable to take these precautions, there are cases where you can operate with great success.

Dr. B. E. Fryer.—I consider this paper a very, very admirable one, and it should interest everyone who operates. I believe, however, that we can produce an aseptic interval, but that many of the efforts of the ophthalmic surgeon are not on a par with those of the general surgeon; they do not, and in many instances cannot, make the same results as the general surgeon. It must be borne in mind that these bacteria are not alone on the surfaces, but deep in the epithelium. I think it was Dr. Kelly who made some experiments in general surgical work, in which he scraped the epithelial cells off from a site to be operated upon to which had been applied the strong bichloride solutions, putting these cells as they were taken in culture tubes, with the result that no growth was found, but upon making a second and crucial test by precipitating the bichloride with sulphide of ammonium, he obtained immense cultures.

I believe that we can, with proper preparation, make an aseptic interval in the eye long enough to obtain immediate union. Most operators overlook the fact of the relatively deep site of these bacteria. I am in the habit of preparing, where I have the time, by applications of carbolic acid to the lid surfaces, 1-100, for several days, and of using for a week or ten days instillations of a 30 per cent. argyrol solution into the conjunctiva. In the

last fifty cases of extraction I have had but one infection, and that, I believe, was due to the patient having removed the dressing.

One other point is as to the reference that is made to the lachrymal glands. Most of the gentlemen will recall Alt's work on the histology of the lids, and remember that we should not overlook the fact that the lids contain some accessory glands and follicles, and these ducts may contain these bacteria. The penetrating power of argyrol is hardly understood and appreciated, I think. Certainly it will not injure either conjunctiva or cornea while it is a perfect microbicide.

DR. T. R. POOLEY. — I wish to relate a case of late infection, which did not prove disastrous, and I desire to do so with the view of getting the writer of the paper and others to state what they think.

The patient had chronic dacryocystitis and at the same time bilateral cataracts. It became necessary to operate. The first step was extirpation of the lachrymal sac, which was done. On removal of the sac there was found to be necrosis of the lachrymal bones, and curettment became necessary, which extended to breaking into the nasal fossa. After complete healing from this an extraction with iridectomy was done. The patient was dismissed from the hospital absolutely well in eight days. There was no reaction whatever. The vision, however, after a few months, was not satisfactory, being only 20/100. There was a capsular membrane, which was divided with a Knapp's needle knife. This was followed by no reaction. In three or four weeks following this, however, there was considerable reaction, well marked circumcorneal injection, and cloudiness of the aqueous and vitreous. Under rest and antiphlogistic treatment and local blood-letting this subsided. Again I did a discission, followed by exactly the same sequence of events.

I should like to know if the reaction in this case was a traumatic reaction, or possibly an auto, or late infection.

Just one other remark. While there is much danger of infection from trachoma where there is secretion, I think chronic cases are singularly immune to infection after operation.

DR. WALTER L. PYLE. — In the light of modern research we know that our greatest safeguard against postoperative infection is a healthy conjunctiva and intact corneal epithelium. Many investigations have shown this. R. L. Randolph has demonstrated the apparent harmlessness of germs if the epithelium is not

broken. After the precautions Dr. Bull has so graphically given us, the most important thing is to prevent destruction of the corneal epithelium. We should avoid too energetic measures and employ the greatest care in applying in the speculum and using the fixation forceps. Bruising the conjunctiva with fixation forceps that tear and mutilate is one of the common causes of reaction and subsequent infection. I see such vicious-looking fixation forceps offered by the instrument-makers that I cannot help speaking of this. I have always avoided the rat-tooth forceps. The teeth should not be sharp and should not bite through the conjunctiva, and they should be as small as possible. In fact, it would be well if we could avoid the use of fixation forceps entirely, as a few of the British operators do. To summarize, I would dilate upon the avoidance of too energetic mechanical measures in cleansing the conjunctival sac and the development of a high order of operative dexterity as the chief safeguards against infection.

Dr. Alexander Duane. — I saw one case that illustrated the inefficiency of the bacteriological diagnosis and the advantage of protargol or argyrol in checking the infection. I had an old man come for cataract operation, and for several reasons it seemed desirable to do a preliminary iridectomy, which was performed. On the third day he developed a purulent conjunctivitis and there was considerable discharge. All dressings were removed, and the case was treated with frequent irrigations and later with protargol (10 per cent.). The case healed promptly and satisfactorily. Warned by this I deferred the subsequent operation for some months and treated the sac carefully and had bacteriological examinations made. The first showed a scanty amount of staphylococcus albus, only one or two specimens in the culture. The sac and also the nose were treated and after another month an examination was made which was absolutely negative. The conjunctiva looked a trifle red, but there was no secretion. The operation was done under careful aseptic precautions and after rigid preliminary treatment, and on the third day a purulent conjunctivitis developed. The dressings were taken off, the conjunctival sac washed out three times a day, and protargol used freely in the sac. The conjunctivitis gradually disappeared, everything went on nicely, and the result was very satisfactory. I believe all that has been said about argyrol in these cases is true. Its penetrating action renders it very valuable, both in preliminary preparation and as a treatment after infection has occurred.

DR. SAMUEL THEOBALD. — There has been one point made by Dr. Bull to which I am inclined to take exception: that is as to his unwillingness to operate even for acute glaucoma if there is evidence of the lachrymal sac being infected. It seems to me this is an extreme position, and I should be very sorry to have the many who look to Dr. Bull for instruction accept this as a dictum to be followed. The danger of infection — and I think everyone will bear me out — in iridectomy for glaucoma is small, while, on the other hand, the danger of loss of the eye from acute glaucoma is great indeed. So, from my point of view, I should not hesitate to iridectomize an acute glaucomatous eye, even though there were blenorrhœa of the sac, rather than postpone it, in view of the extreme liability of the eye being lost because of the postponed operation.

I think we get rather an exaggerated idea of the danger involved when we talk about the presence of bacteria in the conjunctival sac. The probabilities are that bacteria are present oftener than not when we operate on the eye, and yet we all know how seldom we get infections, even after our extractions. We know, too, that not so many years ago bacteriology did not exist, and no precautions against infection were taken, and that though the percentage of infections was somewhat larger than now, yet it was not so much larger. We secured almost as good results as now. So that to assume that because of the *possibility* of infection occurring in acute glaucoma we should allow the eye to go on in that condition while we treat a blenorrhœa of the lachrymal sac would, I think, be distinctly wrong.

Another point that I would allude to is that in any discussion of infection of the eye by bacteria we should not lose sight of the possibility of auto-infection. I think it plays a larger part than most of us imagine. Infections do not always come from bacteria in the conjunctival sac at the time of operation, nor from bacteria introduced during the operation; the infectious material may be in the system, especially in the alimentary canal.

DR. W. E. LAMBERT. — It has been my practice to have the patient admitted a day or two before operation, in order to have a bacteriological examination made. In reference to Dr. Theobald's remark that we do not look upon these operations (discisions) with any fear, I had a case this winter where an extraction had been made some months previously and there was a dense membrane, for which I advised a secondary operation. I divided it with the De Wecker scissors. The next day the anterior cham-

ber had formed and there was no indication of any disturbance. That was on Friday and I told him he could go home on Sunday. On Saturday I looked at the eye and found a very slight infiltration. He was put upon atropin, argyrol, and hot bathing, but on Monday the eye had gone on rapidly to panophthalmitis, and, to make a long story short, the eye was lost. The argyrol had no effect in this case, although I believe it is one of the most useful applications, and have often had great success with it in chronic dacryocystitis. It shows, I think, that we cannot be too careful in making our examinations and preparations, even for discissions.

DR. MYLES STANDISH. — I want to say a word as to Dr. Theobald's question of infection in iridectomy for acute glaucoma. Dr. Bull's paper is one with which I heartily agree; nevertheless, according to my experience, the danger of infection in a glaucoma operation is very much less than in an operation for cataract extraction. There we remove the lens, and that space becomes filled with fluid immediately after the operation, part of which, at least, comes from the conjunctival sac, and the chances for infection are greater. In glaucomatous cases, on the contrary, the flow is the other way and there is less danger of infection. I myself have never seen an infection in a glaucomatous case, and I have understood from many gentlemen that they have not, but just now for the first time I have discovered a gentleman who has. Such cases must be exceedingly rare. I remember a case I operated upon away from home, where vision had been lost in the previous twenty-four hours from acute glaucoma, and where there was a profuse muco-purulent conjunctivitis, in which at the close of the operation the eye was filled with iodoform, and did well. I think we should draw a strong line between the operation for cataract and for glaucoma, as to the liability of post-operative infection. With regard to infection in cataract cases, of course it did not follow every case before we had modern methods, as has been noted. I remember when I was a house surgeon a gentleman, who is a member of this Society, who used to come up from the out-patient department and perform cataract operations without even washing his hands. It is a fact that in his last one hundred cases of cataract operations before he retired from the staff of the hospital, he had had no infection, and that he was the only man on the staff who had not, although the majority of his colleagues used rather elaborate antiseptic precautions. That gentleman had a set of instruments which he used solely for uncomplicated cataract operations, and it was his habit to never put his

fingers into the eye, nor to use any cotton in the eye, nor did he permit any of his assistants so to do. He did not operate where there was a complication; he picked his cases. The moral is: the mildest sort of irrigation, the least amount of handling that will remove extraneous matter, providing our tear-sac is not a point of infection, is all that is necessary in normal cataract cases.

As to the tear-sac I have a word to say, and that is a report of progress in tying the canaliculi, as suggested by Dr. Buller. I have tied off a number of canaliculi, putting in a probe and tying down on it, then slipping it out and tightening the knot. In these cases there has been streptococci in the sac, but no infection has followed the operation.

DR. S. D. RISLEY. — I will not undertake to discuss this paper, the tenets of which I agree with in almost every respect, but I would like to ask Dr. Lambert whether he has observed any profound reaction, high temperature, and symptoms of systemic reaction, in these cases of infection following operation. In my own experience, which has fortunately not been very large in that respect, I have three times, at least, seen the condition ushered in by marked general symptoms: rapid elevation of temperature, abdominal pains, a restless, feverish night; and on looking at the eye the following morning found the lids puffy and red, a condition finally leading to panophthalmitis and destruction. The wound is filled with a gray membrane twelve hours after the operation, which had been smooth and without accident, and within twenty-four hours these streamers of gray membrane have penetrated the anterior chamber. In these cases the onset was with pain, temperature of 102-3, rapid pulse, and abdominal pain.

DR. ARNOLD KNAPP. — The systematic bacteriological examination of the conjunctiva before the cataract operation can hardly be practically carried out, for the following reasons: An exhaustive examination is quite laborious; the presence of pathogenic bacteria necessitates a knowledge of their virulence; as in all bacteriological investigations a negative examination does not prove a sterile condition.

I should like to ask Dr. Bull's opinion on the preparatory syringing out of the lachrymal sac before operation.

DR. HIRAM WOODS. — I hope Dr. Bull will, in closing, go a little more fully into the treatment of post-operative infection after its occurrence. He advises in his paper the routine use of one

method — heat cauterization. Dr. White of Richmond read a paper upon this subject at the recent meeting here of The American Medical Association. Though there was a long discussion upon preventive methods, practically nothing was said about stopping the destructive process when once started. At the New Orleans meeting of the association in 1903 the subject was also considered, and the use of iodoform discs advocated by Gifford, Ellett, and others. The only case of the kind I ever saw manifest improvement was treated with iodoform. Thirty-six hours after an easy, simple extraction, the corneal wound presented a gray appearance, there was commencing œdema of the lids, and I felt the case was lost. The corneal wound was reopened, and very fine iodoform powder sprinkled along its edges and introduced with a fine spatula into the anterior chamber. The cornea was saved. I have seen the actual cautery used without the least benefit, and have come to regard these cases as hopeless, or next to it.

Dr. Bull. — This paper and discussion has taken up so much time that I will endeavor to be as brief in closing as possible. Several of the gentlemen have brought to my mind the remark made by one of my cynical colleagues, that the science of bacteriology had largely increased the number of suppurative cases following operation.

As to the last question, that of Dr. Woods, perhaps I was a little too brief in the method I described of treating post-operative infection, and, perhaps, that brevity was due, unconsciously, to the fact that almost all these cases of post-operative infection are lost in spite of everything one can do. But, while I have seen the cautery fail completely in arresting the process, I have also seen it succeed by one application. In that case, of course, the patient and operator are both fortunate. I have seen a number of cases within the past year in which, in addition to the opening of the wound and its cauterization, the introduction of iodoform discs into the anterior chamber has assisted in arresting the process. I have also seen three cases within the year of suppuration, in which neither the use of the cautery nor the application of iodoform produced the slightest effect. In addition to these two methods I always employ cleansing applications and moist heat.

One point made by Dr. Pyle I consider of importance; that is as to the care to be exercised in the various steps of the operation, the choice of fixation forceps, and, wherever possible, avoiding

the use of the forceps absolutely. For instance, where we find it necessary to do a discission after extraction, and where the capsule is thin, I never use the needle; I use the slender cataract knife, and without fixation forceps. Refraining from the use of the fixation forceps, and using the narrow, slender knife, plus our modern cleanliness, are what have changed my view as to the dangers of the secondary operation. I was taught that it was more dangerous than the first operation, the extraction.

I believe in the existence of an autointoxication, but we have no positive evidence of such a thing, for the only proof would be the existence of an absolutely sterile conjunctival and lachrymal sac. I have seen cases in which it seemed to me absolutely certain that the infection came from within.

I approve of what Dr. Fryer has said about the deep penetrating action of argyrol, especially upon the ducts of the glands in the lids. If we can use argyrol for a number of days previous to operating, it does go deep into the conjunctiva.

I have noticed during the past few years in my own practice that the cases of suppuration, not only after extraction, but after other operations, occur more frequently in private patients, where the operations were done at the residence, than in hospital patients, or where the patients were removed from the hospital after the operation. So impressed have I been with this fact, not only in my own experience, but in that of my friends, that I have almost come to the conclusion to refuse to do a capital operation unless the patient will take a room in the hospital.

CONCERNING CERTAIN NON-TRAUMATIC PERFORATIONS OF THE MACULA LUTEA.

By G. E. de SCHWEINITZ, A.M., M.D.,
Philadelphia, Pa.

Traumatic perforation of the macula, or, to use the name which is employed in England, "hole in the macula," is a lesion to which in recent years a good deal of attention has been directed. Almost always it has followed the blow of some hard body, for example, a fragment of wood, a piece of stone, a bullet or a ball, which has struck an eye previously healthy. We are particularly

indebted to Kuhnt,[1] Haab,[2] and M. F. Ogilvie[3] for studies of this affection, the last-named writer having analyzed fifteen cases and having reviewed the literature. A good many examinations indicate that the lesion under these circumstances is a fairly constant one, being confined to the central region, and characterized by a slightly punched out hole, either circular or oval in shape, with sharply marked edges and stippled bottom, crossed, it may be, with pigment lines. It is permanent, and may be noted years after the original blow has been struck. Sometimes the vision is surprisingly good, sometimes defective; sometimes a scotoma is demonstrable, sometimes it is not. According to Mr. Ogilvie, in a certain number of cases there is obvious detachment of the retina, while in others transparent retinal detachment is not demonstrable.

I give this brief description of this well-known affection to introduce the subject to which I would like to call attention, namely, that under certain circumstances we may find an exactly similar change in eyes that have not been subjected in any manner to traumatism. That such may be the case has not escaped the attention of that singularly acute clinical observer, Professor Haab. Describing perforations of the macula lutea after contusion of the eyeball, he remarks:[4] "It is probable that openings of this kind in the fovea may appear spontaneously in advanced age without any traumatism, probably owing to arteriosclerosis. In a case of this kind I saw such a perforation in both eyes in a woman sixty-four years of age, with marked arteriosclerosis and some albuminuria." Kuhnt, who first noted this type of macular change in 1891, but did not describe it in detail until 1900, records four examples of a peculiar change in the retina in the macula, for which he suggests the title *retinitis atrophicans sive rareficans centralis,* which corresponds to the description already given, namely, the presence of a red, exactly cir-

[1] Zeitschr. f. Augenheilk., III, 1900, p. 105.

[2] Ibid, p. 113.

[3] Trans. Ophth. Soc. U. K., Vol. XX, 1900, p. 202.

[4] Atlas and Epitome of Ophthalmoscopy, Authorized Translation from the Third Revised German Edition, edited by G. E. de Schweinitz, A.M., M.D., Figure 47.

cular spot in the macula. Searching for an etiological factor, he found in one case trauma, in two cases nothing which could account for the condition, and nothing also in a fourth case, the patient having consulted him simply on account of reduced visual acuity. Two of his patients had reached such years (fifty-nine and sixty-one respectively) when the possibility of circulatory disturbances brought into existence by senile changes was suggestive. In this connection I wish to report the following case as illustrating the senile type of this affection:

Case I. *Macular Lesion exactly resembling the so-called Traumatic Hole in the Macula in a Patient the Subject of Chronic Heart Disease and Arterio-Sclerosis.*[1] — A woman, aged sixty-six, consulted Dr. Robert Saunders in April, 1895, in the hope of obtaining glasses for improving her defective vision, which in the right eye amounted to 6/12 and in the left eye about 6/60 eccentrically. The right eye, after the correction of a hyperopic astigmatism, regained normal vision, and was in itself without notable ophthalmoscopic changes. In the left eye Dr. Saunders discovered the appearances shown in the watercolor by Miss Washington, which I exhibit, and brought the patient to me in consultation. The ophthalmoscopic conditions were as follows: The optic disc was circular and exhibited along its lower and outer border a broadened scleral ring, beyond which was a slight area of pigment disturbance. The papillo-macular bundle was a little paler than the rest of the surface of the disc. The blood-vessels were about normal in their distribution, but both systems somewhat smaller than is natural and the finer twigs markedly tortuous, as one is accustomed to see them in the subjects of arterio-sclerosis. Directly in the center of the macular region was an oval area of reddish color, its border being more sharply marked and of deeper tint than its center, in which were a few white dots. The halo which surrounded the macular region, that is to say, the macular reflex, was unusually distinct, and beyond it was a delicate fringe of faint pigment markings. The central

[1] This case has been briefly reported in the American Journal of Ophthalmology, Vol. XIII, 1896, p. 46.

lesion, or hole, appeared to be slightly deeper than the surrounding eyeground, the difference in refraction being half a diopter. Vision was unimproved by glasses. The peripheral visual field was normal, and there was a central scotoma five degrees on each side of the fixing point and three degrees above and below it. Physical examination revealed that the patient was the subject of chronic heart disease, with a well-marked aortic, obstructive murmur; for years she had been afflicted with rheumatism. I saw the patient only once, and it is my impression that Dr. Saunders told me that a subsequent examination of her urine proved this to be normal, although I have not made note of this in my case book. The superficial arterial system, radials, temporals, etc., gave the usual indications of arterio-sclerosis.

This form of macular affection is not to be confounded with localized changes in this region, as they occur in myopia (myopic central retino-choroiditis), or, for example, secondary to choroidal tears or hemorrhage as dark and light stipplings and spots, or as the result of nephritis, diabetes, anæmia, organic stomachic disease, etc., or finally, in ordinary senile macular disease in which there is a considerable area of yellowish-white spots interspersed with pigment dots and small round hemorrhages, or irregular areas of erosions which may go on to atrophy of the elements and pigment heaping. It is probable that the lesion is one of the types of senile macular change to which Haab[1] made reference years before he especially investigated the traumatic perforations of the macula, and which he thought might account for the diagnosis of "Amblyopie ohne Befund" then often made in elderly patients, because the condition was not readily recognized except through a dilated pupil. His description is as follows: Usually smaller or larger, at times as large as the papilla, yellowish-red or whitish, or else darkly pigmented spots are evident which are confined solely to the territory of the macula, choroiditis elsewhere in the fundus not being present. I say the lesion which I here describe and picture, and which Kuhnt and Haab have also described, may belong to this class, but evidently it presents

[1] Bericht der siebenter Ophthalmologisch Congress, Heidelberg, 1888, p. 429.

marked differences, already sufficiently detailed. It is, in short, a congener of the traumatic hole in the macula, and may therefore be called *non-traumatic perforation of the macula,* arising in the eyes of subjects of arterio-sclerosis.

Not only is this lesion liable to result from injury and to appear in the eyes of elderly subjects, but it may follow non-traumatic forms of irido-cyclitis. By way of illustration I cite the following case:

Case II. *Macular Lesion exactly resembling Traumatic Perforation of the Macula following Iritis.*[1] — A woman, aged fifty-five, in good general health except for occasional seizures of rheumatism, had a severe attack of influenza in January, 1895, followed two weeks later by severe bilateral iritis of the so-called serous type. The disease gradually yielded to treatment, and at the expiration of three months the visual acuity was in each eye 6/9. Pigment was present on the capsule of each lens, and there were floating vitreous opacities; otherwise no changes were noted. The patient was not again seen until nine months later, or just one year after the iritis had first appeared, when she returned with the statement that for three weeks the vision of the right eye had been noticeably failing, and that she was conscious of a scotoma in her visual field "looking like a plate with dark center and greenish edges." Examination yielded the following results: O. D. 4/60, O. S. 6/15. Exactly in the center of the right macular region was an oval, red-brown area, about one-third the size of the papilla, containing in its center two yellowish-white dots and a few fine white stipplings. This spot was surrounded by a greenish-white ring, somewhat raised, so that the red portion appeared as if at the bottom of a small pit, the sides of which were composed of the border just described. The macular reflex was unusually distinct. The accompanying watercolor by Miss Washington gives the appearance of this lesion. The optic disc, the retinal circulation and blood-vessels, and the general eyeground exhibited no abnormalities. The visual field was slightly contracted and contained a central scotoma. The opposite eye

[1] This case has been partly described in the Philadelphia Polyclinic, Vol. V, 1896, and in the Ophthalmic Record, November, 1898.

MACULAR REGION OF THE RIGHT EYE CONTAINING LESION EXACTLY RESEMBLING TRAUMATIC PERFORATION OF THE MACULA FOLLOWING IRITIS.

exhibited no similar conditions. Practically no favorable result was reached by treatment, although the various alteratives — mercury, iodide of potassium, arsenic, etc. — were tried in succession. A little more than a year after the appearance of this lesion, namely, on March 1, 1897, the spot was still distinctly visible and presented the characteristics already described, except that the greenish ring was no longer manifest, and the reddish part, which had occupied the center of the circle, was not quite so distinct.

The vision of the left eye remained as good as ever it had been after the original attack of iritis, namely, 6/12, until this date, when it began to fail, and became 6/45. There were some vitreous opacities, one large, semi-transparent one closely resembling a huge epithelial cell, but these opacities had been more or less constant ever since the original attack of iritis. On the 23d of the same month an area of macular degeneration exactly like that which occurred in the right eye began to be visible, and in a few days assumed the characteristics which belong to the one upon the opposite side, so that the illustration then made is an equally good picture of the present lesion. Vision, however, on this side never sank quite as low as it did on the other, and at the last examination, about half a year ago, was 6/60, medication, as in the former instance, having had practically no effect upon the area of degeneration. The lesions were therefore exactly symmetrical.

When the patient was last seen, on October 24, 1901, or five and one-half years after the lesion appeared in the right eye and four and one-half years after it had developed in the left eye, with the exception of the absence of the greenish-white border and a somewhat greater expanse of the reddish areas, the conditions were unchanged. The accompanying watercolor, made from the left eye by Miss Washington, illustrates the state of affairs.

Evidently the lesions in this case exactly resemble the one previously recorded, and in turn are closely analogous to those which are caused by concussion injuries of the eye. The ophthalmoscopic picture is very like those depicted by Kuhnt and Haab,

and somewhat like several of those given by Ogilvie, although in most of his the red color of the center of the spots is made darker than those which I present, being more nearly a blood color, and not the brick red which these watercolors indicate. Also in his cases there was more evidence of change, œdema, etc., of the immediately surrounding retina than in those at present under discussion.

In the absence of exact microscopic examination of such lesions, their pathogenesis is to some extent obscure. Naturally, hemorrhage in this region has been suggested; indeed, I adopted this explanation when I first described briefly my cases. But the entire behavior of these macular defects differs from that of those which are hemorrhagic in origin, chiefly in their unchanging character, lasting, as they do, without notable alteration for months and even years. Moreover, I had the opportunity of seeing one develop, beginning at first with great depreciation of vision, without distinct ophthalmoscopic change, to be followed by the gradual appearance of this oval or circular lesion. Circular macular hemorrhage, moreover, after iritis, in association with glaucoma and in arterio-sclerosis, presents totally different ophthalmoscopic appearances, as may be seen in the accompanying watercolor, which, as time goes on, give rise to a spot of atrophy which includes all tissues to the sclera and is associated with surrounding disturbance of pigment lining.

Kuhnt, as may be inferred from the descriptive title which he suggests — *retinitis atrophicans sive rareficans centralis* — leans to the opinion that the condition represents a peculiar genuine retinitis of the posterior pole, which tends to central atrophy of its tissue. He points out that as the fovea is entirely devoid of capillaries and radial fibers, while the innermost portions of the macula possess them only in insignificant degree, the hypothesis is not far-fetched if one assumes that only those portions of the retina which are directly nourished by capillaries and bound together by Müller's fibers can withstand this inflammatory condition which tends to tissue disappearance, while the other portions are adapted to a melting away of their structure. Recently C. Harms[1] has

[1] Klin. Monatsbl. f. Augenheilk., XLII, Bd. I, 1904, p. 488.

described in great detail the microscopic lesions which he found in an eye of a seventy-seven-year-old man with senile macular changes — dark areas and light-colored spots. In general terms the lesions, consisting of atrophy and disappearance of the involved tissues, were confined to the macula and affected chiefly the neuro-epithelial layer. His measurements indicate that the lesion would have been clinically represented by a central scotoma about seven degrees in the horizontal and three degrees in the vertical meridian. He points out that such a condition does not correspond with those already found in central choroido-retinitis, but justifies Haab's assertion that there is a pure retinal senile affection.

In this conection the interesting observations of E. Fuchs[1] are important. He found in an eye blinded by irido-cyclitis following a blow by a piece of wood cavities in the outer reticular layer, partly filled with coagulated fluid, which communicated with similar cavities in the nuclear layers. Disturbances of the pigment epithelium and traces of previous hemorrhage were lacking; the choroid was practically normal; there was moderate round-celled infiltration of the iris and ciliary body. He regards the condition as due to an inflammatory œdema, a transudation of serum from the retinal vessels, resulting from the low-grade inflammation of the ciliary body and iris. He has seen similar cavities in other injured eyes and thinks they account for the formation of "holes in the macula" after concussion injuries. Naturally the thought arises that similar cavities might explain the "hole in the macula" which I have described as a sequel of non-traumatic iritis.

Finally, it is to be remarked that degeneration of the ganglion cells, as it has been found by Ward Holden, Shumway, and others, in the macular changes in amaurotic family idiocy, has been suggested as an explanation of the affection I have been describing; indeed, I have myself advanced this hypothesis as a possible one. But the more one thinks of it the less suitable this theory becomes. The ophthalmoscopic signs are greatly different, not

[1] Zeitschr. f. Augenheilk., VI, 1901, p. 181.

to mention the absence of any anatomical foundation for this idea in the examinations with the microscope which have thus far been made in analogous cases.

Evidently, then, the ophthalmoscopic appearances to which the term "hole in the macula" has been applied may arise from a concussion injury and then represent the usual type of traumatic perforation of the macula. Precisely similar lesions may follow an iritis or irido-cyclitis of non-traumatic origin and occur in the eyes of elderly persons, particularly if they are the subjects of arterio-sclerosis. Pathologically it would seem that the condition in so far as the last class is concerned depends upon a pure location of the disease in the macula, especially affecting the neuro-epithelial layer, and results in a form of atrophy or melting down of the tissues, the rest of the eyeground and the other coats of the eye being unaffected. Inasmuch as it has been demonstrated that traumatic irido-cyclitis and other injuries of the eye may be followed by a transudation of serum from the retinal vessels as the result of a low-grade inflammation of the anterior uveal tract and eventuate in cavities located particularly in the outer reticular and nuclear layers, a similar explanation is applicable to the "holes" which I have described as the result of non-traumatic iritis.

DISCUSSION.

Dr. C. J. Kipp. — I can add to the case of Dr. de Schweinitz one which differs somewhat from his — a young woman, who had never had iritis, nor cyclitis, nor any inflammatory disease. She had had for two years greatly impaired sight, and on examination the condition was found of which this is a representation. She had, beside this so-called hole in the macula, some pigment deposited in the disc itself; everything else was normal. She had a central scotoma, but the field was not contracted for white or colors. It shows that we can have the so-called holes in the macula without inflammatory conditions, or traumatism.

Dr. G. M. Gould. — I add an analogous case to the list, that of a patient whom I saw about six or eight years ago, a Japanese, who had central choroiditis with a pigmentary degenerative process arranged in concentric rings, looking as if made with India ink. There was this same punched-out perimetric hole in the

macula. I could not determine that the man had ever had any specific disease, nor what was the cause of the condition. It puzzled me, and all I could do was through systemic treatment. I advised his going on a ranch out West. He could not, of course, read. In both eyes there was definite beginning formation of new maculas above. By putting on heavy prisms, bases down, I could get much better fusion with the apparently beginning new maculæ above. It seemed such an anomalous condition that I thought Dr. de Schweinitz might like to add it to his list.

CONJUNCTIVITIS NODOSA, WITH HISTOLOGICAL EXAMINATION.

BY G. E. DE SCHWEINITZ, A.M., M.D.,

AND

E. A. SHUMWAY, M.D.,

PHILADELPHIA, PA.

As is well known, the first case of ophthalmia nodosa, a name suggested by Saemisch, was described by Pagenstecher[1] in 1883 before the Heidelberg Ophthalmological Society. Since this time numerous cases have been reported, in many of which positive proof has been given that the condition was caused by irritation of the hairs of certain species of caterpillar, which had found lodgment in the conjunctiva, cornea, or iris. We are particularly indebted for studies of this subject to Baas, Wagenmann, Hillemanns, Krüger, Hanke, Lawford, Stargardt, and others, and a complete analysis of the literature of this subject in condensed manner will be found in the works of Ginsberg,[2] Greeff,[3] and J. Herbert Parsons.[4] It does not seem, therefore, necessary to do more than mention these authors, in whose writings full bibliography will be found. In our own country we have not noted the reports of many examples of this affection, although George Knapp[5] has described three cases, and Colburn one case. Our own case is as follows:

[1] Klin. Monatsbl. f. Augenheilk., XXI, 1883.

[2] Grundriss der pathologischen Histologie des Auges, Berlin, 1903, p. 68.

[3] Pathologische Anatomie des Auges, p. 70.

[4] The Pathology of the Eye, Vol. I, Part I, London, 1904, p. 84.

[5] American Journal of Ophthalmology, Vol. XIX, 1897, p. 247.

Theresa C., a negro girl, aged fifteen, an inmate of the Asylum for Colored Orphans in Philadelphia, came to the hospital of the University of Pennsylvania on the 20th of July, 1903, for relief from an inflammatory condition of the left eye.

History. — The patient stated that while playing in the yard attached to the asylum a few days prior to her entrance into the hospital her eye became inflamed, owing, as she expressed it, to "something getting into the eye." At that time she gave no intimation of what that something might have been. The girl was a well-formed negress, healthy in all respects, and having no ordinary intimations of general disease.

Examination. — Vision of O.D. 6/9, the ocular structures normal, and the depreciation in vision due to slight refractive error. Vision of O.S. 6/12; the conjunctiva of the lids, especially in the lower retrotarsal fold, was slightly congested and velvety in appearance. There was marked pericorneal injection downward and inward, and an area of patchy congestion with faint nodes at the lower and inner portion of the bulbar conjunctiva. The case books do not record any more accurate description than the one that we have given at this time, and the eye was treated with the usual antiseptic lotions, the patient reporting with a good deal of irregularity during the next six weeks, and apparently without benefit from whatever treatment was applied. The case was then referred to me for more particular examination, and the following conditions were evident: The cornea and iris were unaffected and the deeper media clear. Downward and inward on the bulbar conjunctiva were a number of flattened, grayish-yellow nodules, between which was a marked congestion of the conjunctival and episcleral vessels. Twenty-seven nodules could be differentiated, those directly in the center of the collection being somewhat confluent and assuming a crescentic and circular appearance. The whole condition strongly suggested tubercle of the conjunctiva, and, indeed, this was the tentative diagnosis at the time, as there was not then the least suspicion of the true nature of the case.

The patient was admitted to the wards of the hospital on the 20th of September, 1903, chloroformed, and the greater portion

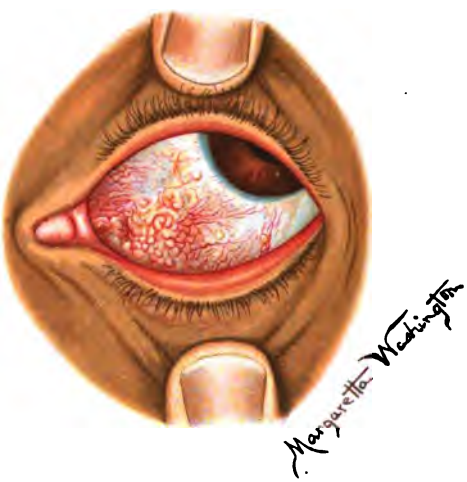

FIG. 1.—CONJUNCTIVITIS NODOSA.

of the nodules excised, those failing to come away with the strip of conjunctiva thus removed being touched with the actual cautery. The surface was dusted with iodoform, the eye bandaged, and the patient treated as after an ordinary operation. The healing was kind and the patient was dismissed in a few days with a good deal of congestion remaining, but no distinct nodules. She came somewhat irregularly to the dispensary, and then disappeared. We have ascertained that subsequently she went to another hospital, where the nature of the case was not suspected, and where, with some local treatment, which included the usual antiseptic lotions and dilatation of the punctum, the remaining congestion disappeared.

Microscopic Examination. — A portion of the strip of conjunctiva was introduced into the anterior chamber of a rabbit's eye through a corneal incision. The remainder was placed in formalin and imbedded in paraffin. The wound in the rabbit's eye healed promptly, and the eye showed very little reaction. The bit of tissue lay on the iris below, and was slowly absorbing, when the rabbit unfortunately developed a purulent infection of the air passages three weeks afterward, which commenced in the nose and produced a purulent pleuritis and pericarditis, to which the animal succumbed within two days. The infection proved to be due to the bacillus pyocaneus and was, of course, accidental, and not connected with the inoculation of the eye. The eyeball was removed, fixed in formalin, and imbedded in celloidin. Sections passing through the tissue introduced into the anterior chamber show that this has been partially included in the iris tissue, and is reduced to a condensed mass of connective tissue. The eye itself shows very little reaction. The iris contains a moderate round-cell infiltration, but there is no sign of miliary nodules, so that the tubercular character of the tissue may be excluded.

The sections of the original strip of conjunctiva reveal the presence of numerous nodules beneath its surface. The conjunctival epithelium is very greatly thickened and contains leucocytes. Beneath the epithelium the tissue is composed of coarse bundles of connective tissue, which contain a great many round

cells and numerous distended blood-vessels. The nodules measure about .25 mm. in cross diameter and from .4 to .6 mm. in their long diameter. The outer portion of each is composed of a layer of spindle cells and round cells arranged concentrically, outside of which the tissue is condensed into a capsule. The interior consists of epithelioid cells, between which there is considerable intercellular substance. Each nodule contains a number of giant cells, the nuclei of which are irregularly distributed through the body of the cell instead of being marginal. Directly in the center of a certain number of the nodules is the section of a hair. When this is evident in longitudinal position, as may be seen in the accompanying drawing, or in the microscopic sections which are herewith presented, it consists of a long cylinder with moderately refracting walls, and in the center contains a somewhat brownish-yellow broken material. Irregular crosshatching of flat sections is visible. In one section, at least, what at first appears to be a notching of the edge is really a slight, spike-like prolongation into the surrounding tissue, and represents, we think, the remnant of the long spines which form so conspicuous a component of caterpillar hairs. Each hair is surrounded by a mantle of small round cells. No micro-organisms could be discovered, and the nodes must therefore be regarded as typical foreign body tubercles, produced by the presence in the tissue of the fine hairs. The histological appearances which we have described closely correspond to those already recorded by Wagenmann, Krüger, Hanke, and others, although we have not noted anywhere in the drawings which accompany the papers of these authors so typical an example of the hair shaft as we here picture, nor have we seen anywhere described an appearance which suggests at least the remnant of the spines on caterpillar hairs.

If we come to consider the previously reported cases of this affection, the records of which may be found in the literature to which we have already made reference, and particularly in Mr. Parsons' admirable résumé of the whole subject, we find that ophthalmia nodosa, or, as Wagenmann prefers to call it, pseudo-tuberculosis of the conjunctiva, has been caused by the irritation

of certain species of caterpillar, particularly Lasiocampa or Bombyx (B. *rubi,* B. *pini.*), Liparis (L. *monacha,* L. *dispar.*), etc.; other species, *e. g., Cnethocampa* (C. *processionæ*), also cause conjunctival irritation, but it rarely becomes so severe as with the other species, nor are the deeper parts of the eye (iris, etc.) affected (Baas, Wagenmann). Particularly interesting studies of the caterpillar species concerned in this affection have been made by Mr. Lawford with the aid of Lord Walsingham. The affection has been seen as early as the month of June, but more commonly appears in August, September, and October, when caterpillars are more common and are at the period of their greatest activity. Our case began in July. As is well known, the nodules in this disease may be present in the conjunctiva, episclera, and even in the iris, but most often are found in the bulbar conjunctiva in the position in which they are shown in the accompanying watercolor by Miss Washington. In general terms, they resemble very much real tubercle of the conjunctiva, not only on external examination, but in minute microscopic investigation. The hairs when imbedded in the conjunctiva are surrounded by round-celled infiltration, which is a conspicuous element in the sections we present. Frequently numerous giant cells and lymphocytic infiltration are present, and the giant cells are of the foreign body variety. Spindle cells, which we also have described, have been noted in a number of instances, and sometimes a fibrous capsule seems to be present, as, for example, in one of Krüger's sections, as it may also be seen in those which we exhibit.

There is much difference of opinion as to whether the irritation is mechanical, or whether it is due to some constituent of the hairs. Stargardt thinks that the first irritation is mechanical, but that this is followed by a chemical irritation to which the pseudo-tuberculosis formation is due. As is well known, formic acid is present to a considerable extent in the hairs of caterpillars. The hairs, encouraged by frequent rubbing of the lids, can travel, base forward, very deep, but probably owing to the presence of the spines, which come off from the hair shafts at

acute angles, are prevented from making a return journey. They may penetrate the cornea, enter the iris, and there form the nodules which have been described. It is probable that they may even reach the choroid, if we may trust a case reported by Reis. Bacterial infection seems absent. Micro-organisms have not been found, either in our own, or in other cases in which search was made for them. Experiments on animals by Krüger and others have not led to definite results, and implantation of the excised tissue in the anterior chamber of a rabbit has not led to the development of similar nodules, as is evident from our own experiments. Greeff maintains that according to his researches the caterpillar hairs do not produce this condition by virtue of a mechanical irritation, but by reason of the presence of a toxic substance, and further declares that if the hairs are dried and then introduced into the tissues the nodules do not develop. Parsons believes, however, that the innocuousness of dried hairs requires confirmation.

A somewhat similar disease clinically resembling trachoma has been described by Markus[1] as the result of the implantation of plant hairs, and it is possible that some of the reported cases of ophthalmia nodosa may have been due to this type of irritation, and not to caterpillar hairs.

Referring again to our own case, when the diagnosis by virtue of the microscopic examination became evident, the interesting problem presented itself, whether we could prove or not what species of caterpillar had produced this conjunctivitis. The diagnosis was not made until long after the caterpillar season, and therefore a search in this respect had to be postponed until the present time. Therefore, a few days ago one of us (Dr. de Schweinitz) went to the yard in which the children of the Colored Orphanage are accustomed to play, and make a search for the caterpillars then present. The date of this visit was July 5th. The following interesting facts were developed: Children are much accustomed to playing with caterpillars, and are in the habit, as one of the children stated, "of scaring the young ones

[1] Zeitschr. f. Augenheilk., 1899, II, p. 34.

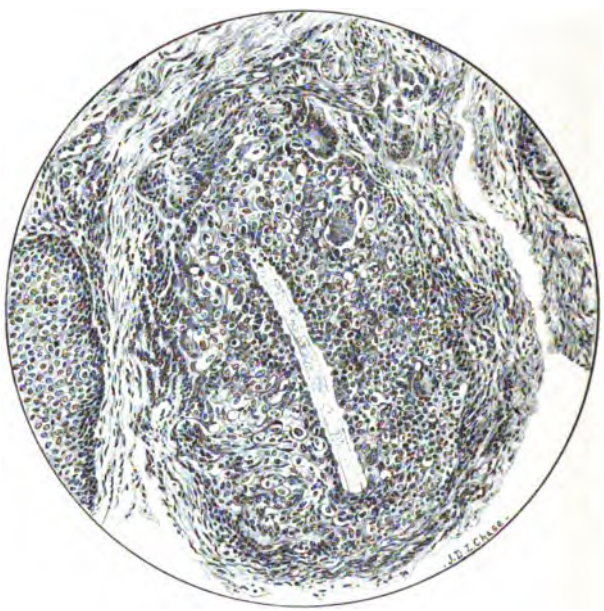

FIG. 2.—MICROSCOPIC APPEARANCE OF SECTION OF A CONJUNCTIVAL NODULE. IN ITS CENTER IS A CATERPILLAR HAIR, SURROUNDED BY ROUND CELLS AND GIANT CELLS; EXTERNALLY, SPINDLE CELLS AND CAPSULE.

by throwing caterpillars at them. The caterpillar which is most used in this playful proceeding I found, or rather, the children found it for me, and is here exhibited. It is the *Spilosoma virginica,* or the yellow, woolly bear caterpillar. Three other varieties are common at this season in the region named, the *Orgya leucostigma,* that is, the tussock moth larva, and the *Empretia stimulea,* or the saddleback caterpillar of common parlance. One last variety, which the children of the home call the doctor caterpillar, we could not find and therefore cannot give its true name. In determining these varieties of caterpillars we are indebted to Dr. Henry Skinner, the distinguished editor of the *Entomological News* and a member of the Academy of Natural Sciences of Philadelphia. He has examined the sections and believes there is no doubt that the hairs are caterpillar hairs, but said that no one could positively determine from what species they came with no more to guide him in his investigations than the hairs which are imbedded in the tissues. He suggested that as the saddleback caterpillar is notoriously irritating and produces even on the skin a stinging sensation followed by large welts, this might be the caterpillar that had produced the mischief. We do not think so, however, because the children are well acquainted with this caterpillar and call it the nettle caterpillar, know that it stings, and never touch it. The *Orgya leucostigma,* or tussock moth larve, belongs to the group of the Bombyces of the family Liparidæ, and, as we have seen from the European investigations, the Liparians may cause conjunctival irritation, but they apparently do not produce the severe types of ophthalmia nodosa, certainly not those in which the iris is involved, and probably not such as we have exhibited today. Now the yellow, woolly bear caterpillar, or the *Spilosoma virginica,* belongs to a family of the Bombyces called the Arctiidæ, derived from a Greek word meaning bear, so given on account of the thick hairs which cover their body. This caterpillar, which the children call the pussy, is used in their sports and they constantly throw it at one another. We could not positively prove that the child who had the conjunctivitis had been struck with this caterpillar, although this

was the opinion of the children who knew about her ocular afflictions.

While this case does no more than add another example of this interesting affection, it is, so far as we know, the first American instance of the disease in which, in all probability, he species of caterpillar concerned has been identified. Doubtless, however, the hairs of any caterpillar of the various species named could produce an analogous if not exactly identical disease. It is further interesting because the implantation of the tissue into the anterior chamber of the rabbit was negative in its results.

Finally, we should call attention to an observation of Markus, namely, that there is only one certain criterion upon which a differential diagnosis between a nodular conjunctivitis caused by caterpillar hairs and by plant hairs can be made. According to him, longitudinal and cross sections of plant hairs show strong polarization, which is not the case with the caterpillar hairs. We have submitted our sections to the professor of physics in the University of Pennsylvania, who has examined them in this respect and reports the entire absence of any signs of polarization. We have therefore, we think, definitely shown that the case reported should be properly classified as a conjunctivitis nodosa due to the introduction of caterpillar hairs, in all probability the hairs of the *spilosoma virginica*, into the conjunctiva of this patient.

INTRAOCULAR TUBERCULOSIS, WITH THE REPORT OF TWO CASES.

BY WM. CAMPBELL POSEY, M.D.,

PHILADELPHIA, PA.

CASE I: TUBERCLE OF THE IRIS.

R. B., colored, aged six years, was brought to the Howard Hospital three years ago, on account of an inflammation in the left eye, which his mother said had been of three weeks' standing and for which he had received no treatment. The inflammation

had occurred during the latter part of a slight attack of bronchitis, but the patient's health was stated to be otherwise good. The father and mother were both living, aged thirty-eight and thirty-two years respectively, and were apparently in robust health; of four offspring, however, the patient was the only one living, two having died of consumption and one of an intestinal disturbance.

At the time of the consultation, photophobia, lachrymation, and injection of the left eye were quite marked; the cornea was densely hazed, presenting more or less of a needle-stuck appearance, and here and there, scattered throughout the substantia propia, there were little particles of yellowish white infiltration. Of chief interest, however, was a small, yellowish white nodule the size of a very small pea, which projected from the root of the upper inner quadrant of the iris into the anterior chamber. The summit of this body was yellowish white, its base reddish brown, this coloration being due not to vascularity, but to a layer of pigment which gave the impression of having adhered to the mass as it had pushed its way up through the stroma of the iris. The iris itself was thickened and discolored, and but a partial dilatation of the pupil followed the instillation of a mydriatic, the membrane being bound down by synechiæ, especially in its inner half. No view of the fundus was obtainable, upon account of the haze of the media. Tension was normal. There was but little ocular pain, though the patient complained of headache upon the affected side. The right eye was healthy.

The suspicion of tubercle being awakened by the appearance of the mass upon the iris, the patient was sent for a general examination to Dr. S. M. Hamill, the physician in charge of the children's department of the hospital, who reported that although there were some signs of pulmonary involvement, it was impossible from the physical examination to say definitely that the child had any form of tuberculosis. Cod-liver oil and inunctions of mercury were prescribed, and the mother instructed regarding proper dietetics. Atropine, boracic acid, and heat were ordered locally.

Notwithstanding this treatment the tumor grew rapidly, until it equaled the size of a large pea, while in addition a mass of lymph appeared in the anterior chamber, which was thought to be evidence of the disorganization of the tubercle. In view of these facts, and as the ciliary injection had become more and more marked, and the anterior chamber deeper, enucleation was finally determined upon, and the consent of the parents being obtained, this operation was performed, the globe being given to Dr. E. A. Shumway for pathological study.

PATHOLOGICAL REPORT.

The eyeball, after enucleation, was thoroughly washed with distilled water, wrapped in sterilized gauze, which was moistened with distilled water, and was taken to the Pepper Laboratory. Here, under careful aseptic precautions, an incision was made into the globe, at the position of the inflammatory nodule, and a portion of the whitish mass was introduced through corneal incisions into the anterior chambers of a rabbit and two guinea pigs, by means of a fine grooved director.

The child's eyeball was then placed in a ten per cent. formalin solution, gradually hardened in alcohol, and divided into halves by a horizontal section through the nodule in the iris. The half was imbedded in celloidin, for microscopical section, and the other half was mounted in glycerine jelly.

The microscopic half (exhibited) shows a whitish mass, occupying the position of the iris on the temporal side, filling up the anterior chamber, surrounding the ciliary processes, and displacing the crystalline lens backward and to the nasal side. The posterior half of the eye is apparently normal.

Sections stained with hæmotoxylin-eosin (Fig. 1) show that the mass is a new formation, inflammatory in type, which has sprung from the iris, and has entirely destroyed its structure. Only a few traces of pigment, in front of the center of the lens, remain to denote the position of the pupillary margin. The main portion of the growth is composed of epithelioidal cells, and small mononuclear round cells, which include many unusually long

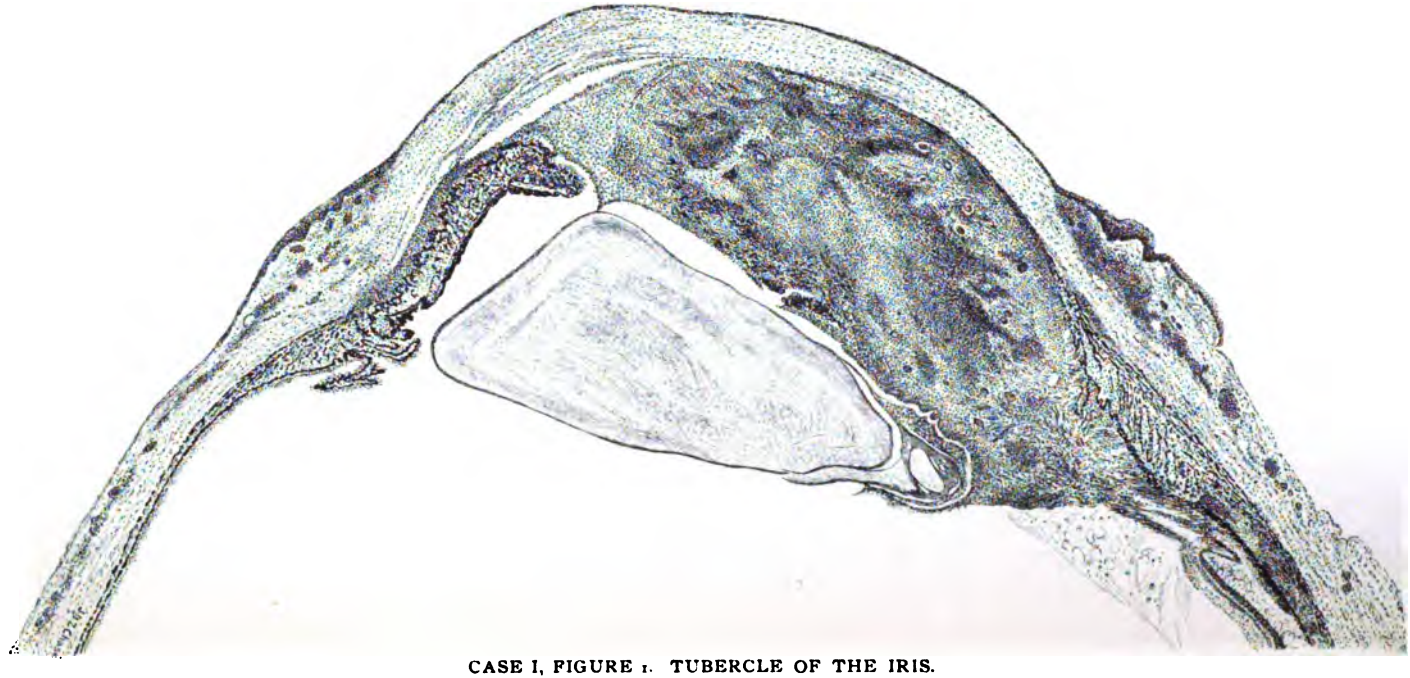

CASE I, FIGURE 1. TUBERCLE OF THE IRIS.

giant cells. Some of the microscopic fields, under low power, contain as many as eight to ten of these multinucleated cells, the nuclei being arranged in the periphery of the cell. At one point there is an area of necrosis, the tissue showing no cellular elements, and containing small round fat droplets. The mass is infiltrated throughout with polymorphonuclear leucocytes. In places these are packed together, and show advanced degeneration of the cells, with fragmentation of the nuclei-pus formation. Its surface is covered with these cells in a loose-meshed, fibrinous exudate, which extends onto the anterior surface of the iris on the nasal side, filling up the angle of the chamber, and unites the iris to the posterior surface of the cornea. The stroma of the iris is here widely separated by masses of small mononuclear round cells. The main mass surrounds the ciliary processes, forcing its way between them and the lens, which it has flattened, and displaced backward, and is beginning to infiltrate the vitreous, lines of exudate extending backward as far as the ora serrata. The ciliary body is infiltrated with mononuclear cells, which have forced its layers apart. The lens shows commencing cataract formation, particularly in the temporal portion, and at the point of contact with the tubercular mass, its capsule has been eroded, and the subcapsular space has been invaded by round cells, which have organized into connective tissue. The cornea is slightly infiltrated, and is vascular at the periphery. The retina shows beginning detachment anteriorly, as a result of the contraction of the organizing exudate. Posteriorly, the central vessels are surrounded by round cells, but the retina and optic nerve are otherwise normal.

On staining the sections with carbol-fuchsin, a *few typical tubercle bacilli were found* in the portion of the mass which contained the giant cells.

The corneal incisions in the animals' eyes healed promptly, and apart from a traumatic cataract, produced at the time of operation in one of the guinea-pigs, no reaction appeared. Twenty-five days later, both guinea-pigs were found dead in the cage, and although careful post-mortem examination was made, no

cause for their death could be found. The eyes were both examined microscopically, but except for the traumatic cataract above mentioned, they were entirely normal. At the same time, the rabbit's eye began to show infiltration of the corneal wound and of the iris, which was adherent at this point. The infiltration gradually increased in amount, and was accompanied by a slight ciliary injection. In the course of two weeks this infiltration had increased to a diameter of two mm., and close examination of the iris revealed the presence of a number of minute nodules scattered throughout the stroma, chiefly in the neighborhood of the wound. (Fig. 2.) There was also a broad posterior synechia on the temporal side of the pupil. Six weeks after inoculation the rabbit was killed and the eyeball was removed and placed in formalin. Microscopic sections showed infiltration of the lips of the corneal incision, and of the iris and the ciliary body; well advanced necrosis of the central portion of the infiltrating mass, and great numbers of long tubercle bacilli, especially numerous in the areas of necrosis. Besides this main mass at the site of the wound, the iris, in other places, contained nodules of small mononuclear round cells, which projected above its surface, but which showed no necrosis. The lungs showed also minute foci of round cells, surrounding the peripheral bronchioles, but no tubercle bacilli. The rest of the organs were free.

The case shows, then, a typical solitary tubercle of the iris in the child, in which it was possible to demonstrate a few tubercle bacilli. From this nodule inoculations were made in the eyes of two guinea-pigs and of a rabbit, with negative results in the former, but with the production of a typical tubercular iritis in the latter, which, in microscopical examination, showed the presence of the bacillus tuberculosis in large numbers at the site of the inoculation.

CASE II. TUBERCLE OF THE CHOROID.

In December, 1898, W. E., a carpenter, æt. thirty years, was sent to the writer by Dr. D. P. Rettew of Coatesville, Pa., upon account of an inflammation in the left eye of two months' stand-

CASE I, FIGURE 2. MILIARY TUBERCLE IN THE IRIS OF A RABBIT FOLLOWING INOCULATION.

CASE II, FIGURE 1. MACROSCOPIC APPEARANCE OF TUBERCLE OF CHOROID.

ing, which had affected the sight and had caused the eye to be red, watery, and sensitive to light. The patient was robust and muscular, and said that he had always been in excellent health; venereal disease was denied, and there was no history of traumatism. The family history was negative. Upon examination, it was found that the left eye was the seat of marked tarsal and ciliary injection; the cornea was very hazy, presenting a ground-glass appearance, which upon close inspection was found to be due to numerous nodules of yellowish infiltration, which were scattered throughout the substantia propia. The pupil was oval, 3 by 4 mm. in size, and did not react to light. Tension was somewhat elevated. Fingers could not be counted, but light perception and projection were excellent in all parts of the field. The right eye was normal, vision equaling 5/5.

The patient was sent to the Howard Hospital, where he was placed in bed and given appropriate local treatment, and notwithstanding his assertions regarding the absence of syphilis, mercurial inunctions were prescribed. The eye, however, failed to improve; the center of the cornea became infiltrated by a ring-like zone of lymph, which was densest at the periphery, though the entire membrane was hazy, the epithelium being roughened and elevated in places. A distinct swelling appeared, too, in the scleral tissues, at the equator of the globe, at a point about 10 mm. distant from the corneal limbus, up and out, between the insertion of the rectus externus and the rectus superior muscles. The anterior chamber was quite deep, the pupil large, and the tension elevated. A provisional diagnosis of gumma of the choroid was made, and as symptoms of ptyalism had manifested themselves, potassium iodide was substituted in ascending doses. After two months of active local and systemic treatment, during which time the patient's general health continued excellent, the signs of active inflammation in the eye gradually subsided and the swelling at the equator became less pronounced. The patient was accordingly discharged from the hospital, but injunctions were given to continue the same treatment. This was persisted in for another six months, at the end of which period the eye had

become almost quiet, there being still some slight ciliary injection excited by handling; the anterior chamber had grown somewhat shallow and the swelling in the equator had almost entirely disappeared. Vision equaled 3/4/60; that of the right eye was normal. At the end of another six months the eye was still slightly irritated, but the cornea had cleared, save for a triangular area of opacity which still persisted, the apex of the triangle occupying the pupillary area, the base the lower corneal limbus. Tension was somewhat plus; vision equaled 1/60; the pupil was 3 mm. in size, and the iris reacted well to direct light stimulus. The patient was seen from time to time, and it was noted, at the expiration of another six months, that the ciliary injection still remained much the same, but that the anterior chamber had grown very shallow, that the lens was cataractous and the tension elevated; the swelling in the sclera had entirely disappeared; vision was reduced to light perception. Upon account of the persistence of the inflammation over such a long period (two years), the presence of increased tension and the shallow anterior chamber, enucleation of the globe was deemed advisable, and after consultation with Dr. George C. Harlan, who concurred in this opinion, this operation was performed without accident under ether narcosis. Four years have now elapsed since the operation. The socket has continued healthy throughout and the general condition of the patient has remained excellent, no symptoms of tuberculosis elsewhere in the system having manifested themselves. As in the preceding case, the enucleated globe was given to Dr. Shumway for examination, whose report is as follows:

Pathological Report. — The eyeball was placed in 10 per cent. formalin, hardened in alcohol, and was subsequently divided in a horizontal plane, into two halves. The upper half showed (Fig. 1) an irregular pigmented area, directly in the median line, in which both choroid and retina were apparently destroyed. Beginning 14 mm. from the optic nerve entrance, it extended nearly to the ora serrata, a distance of about 7 mm.; the transverse diameter measured 16 mm. The edges of the patch were thickened, yellowish white in color, while the inner portion was

CASE II, FIGURE 2. SOLITARY TUBERCLE OF CHOROID.

deeply and unevenly pigmented. Over this area of destructive chorio-retinitis the sclera was thickened and bulged slightly. The lens was cataractous, and was partly adherent to the thickened iris. The upper half of the eyeball was again divided by a section through the center of the destroyed portion; one-half was mounted in glycerine jelly and the other half was cut in sections after celloidin imbedding.

Microscopical Examination. (Fig. 2.) The cornea is thickened and œdematous, the lamellæ being pushed apart, the corpuscle staining poorly and the lines between the basal cells of the anterior epithelium being especially distinct. At the periphery there is a moderate infiltration, with small round cells; these are grouped particularly around the superficial episcleral vessels, and along a few newly-formed vessels which penetrate for a short distance into the corneal tissue. The canal of Schlemm is similarly surrounded, and the angle of the anterior chamber contains a few mononuclear cells, which extend in an interrupted layer on the posterior surface of the cornea. The iris is greatly thickened by the presence of a round cell infiltrate. The cells are of two main varieties.

(1.) A small cell, of less calibre than a red blood corpuscle, which contains a single, deeply staining nucleus, around which is a very narrow ring of protoplasm.

(2.) Larger oval cells, with a single, less deeply staining nucleus, which is eccentrically situated and is surrounded by a much broader, pale ring of protoplasm. The cells of the second variety are scattered diffusely throughout the stroma of the iris, and on its anterior surface. The small cells are also present, being diffused through the stroma, though grouped particularly around the blood-vessels, and in notable masses in three positions: at the pupillary margin, at the ciliary border, and at a point midway between these two portions. In these places they form nodules from .2 to .5 mm. in diameter, occupying the entire breadth of the iris. The cells are closely packed and all stain well, showing no evidence of degeneration. The nodule at the ciliary border has increased the breadth of the membrane, so that

it presses against the posterior border of the cornea, and thus partly obliterates the angle of the anterior chamber. The nodules are exactly similar in structure to the miliary tubercle in the iris of the rabbit inoculated from Case I. In addition to the mononuclear cells, there are a few scattered polymorphonuclear leucocytes in the iris stroma and in the vessels. The latter are distended and filled with blood, but show absolutely no evidence of thickening or of endarteritis.

The lens shows well-advanced cataract formation, the fibres of the cortex being split up and converted into irregular droplets, numerous open spaces existing between the degenerated fibres. The anterior capsule is partly covered with clumps of pigment, the result of previous adhesion of the iris, but there is very little cellular exudate between the iris and the lens. The ciliary body is moderately infiltrated with mononuclear cells, chiefly along the vessels. A few cells are present around the ciliary processes, and extend in lines backward along the fibres of the zonule, and along the fine fibres representing the remains of the shrunken vitreous. Just posterior to the ora serrata, the retina and choroid show an increase in the number of infiltrative cells, and the retinal surface is covered by a thick layer, most of which are long, spindle-shaped forms, running parallel to its surface. At a position corresponding to the anterior border of the degenerated area mentioned in the microscopic description, the choroid is very much thickened by masses of small round mononuclear cells, similar to those forming the miliary nodule in the iris. The retina here is also much thickened, and its structure concealed by the cells infiltrating its substance and covering the surface. Further backward the round cells are replaced by oval or spindle-shaped cells, each with a single pale nucleus, typical epithelioid cells. There are also several typical giant cells, in which the nuclei are arranged about the periphery of the cell. At this point the layer on the surface of the retina reaches its maximum thickness and contains many of both forms of the mononuclear cells, and epitheloid cells, and a number of giant cells. This area of thickening is succeeded by an area in which all trace of the retina is lost, with the exception

of a few degenerated cells of the pigment epithelium, which remain attached to the still intact lamina vitrea of the choroid. Beneath the lamina vitrea, scattered, degenerated pigment cells and a few elastic fibres alone represent the choroidal stroma. The tissue is entirely necrotic, no cells staining, and the necrosis extends to the underlying sclera, which at this point is much thickened. Its fibres are swollen, the cells have lost their staining power, and the sclera bends outward, forming a shallow staphyloma. On either side of the central necrotic area the sclera shows a cellular infiltration, corresponding to that of the choroid — an outer layer of round cells and an inner layer of epithelioidal cells, with a few giant cells. The process, however, has not been severe enough to destroy the scleral structure, or cause perforation. The posterior margin of the destroyed area in the choroid is similar to the anterior, but the thickening is still more marked, and the number of giant cells is greater. The entire picture is one of a typical solitary tubercle of the choroid, with necrosis of the adjacent retina and sclera.

In the posterior half of the eye the choroid is hyperæmic, but shows very little cellular infiltration. The retina has been artificially detached, and shows diffuse infiltration with round cells, the number of which is greatly increased in the neighborhood of the vessels, about which they form thick mantles; at these points the cells have broken through the internal limiting membrane of the retina, and form heaps on its surface, in the vitreous. In addition to these masses above the vessels, the surface of the retina is covered elsewhere by a double layer of cells, many of which have assumed spindle forms. The vessels contain polymorphonuclear leucocytes. The retina is œdematous, thickened, the supporting fibres being especially prominent, and the large ganglion cells are degenerated; many of them have disappeared entirely. The optic nerve shows a moderate infiltration, especially around the central vessels, but is otherwise normal. Many sections were stained by the Ziehl-Neelsen method, and examined for tubercle bacilli, but none were found. As the condition was not suspected at the time of enucleation, no attempts at inoculation were

made. *However, the histological structure of the growth, the central area of necrosis, surrounded by epithelioidal cells, and beyond these a ring of mononuclear cells, the large number of giant cells, and the absence of changes in the vessel walls, point so decidedly toward tuberculosis, as against syphilis or other inflammatory condition, that the diagnosis may safely be assumed to be solitary tubercle of the choroid, situated in the median line above, just posterior to the ora serrata associated with miliary tubercles of the iris.*

Though tuberculosis of the eye is a rare affection, and the opportunity should not be lost of putting new cases of it on record, the writer would hesitate to consume the time of this Society with the reports of two additional cases, did he not consider that both demonstrated points in the history of the disease which are still mooted, and demand further consideration and study. Thus, the first case, while differing in its course in no wise from the usual clinical manifestation of conglomerate or solitary tubercle of the iris, is of interest as it serves to dispel the impression which seems to be growing, that tuberculosis of the iris is a secondary affection, and indicates that an inflammation of undoubted tuberculous nature, as established by both bacteriological and microscopic examination and by inoculation, may occur primarily in the eye; the primary nature of the ocular involvement being attested to by the absence of tuberculosis elsewhere in the system, as proven by the searching physical examination which was made when the case came under observation, and by the cessation of further tubercular development during a period of three years after the removal of the eye. Furthermore, the escape of the general system from participation in the tuberculous process illustrates the value of the complete and early removal of the primary source of infection, though it should be remarked that the favorable termination of a large number of cases of undoubted tubercular iritis without operation, by appropriate local and general treatment, demonstrates that such a radical procedure as the removal of the eye is not to be advised in all cases, even after the diagnosis of tuberculosis has been confirmed. It should be re-

membered, too, as has been shown in a recent paper by Rogman, that the operation of enucleation is not without danger in cases of intraocular tuberculosis, this author having reported nine instances where the tuberculous process, which had been without general manifestation prior to the removal of the eye, seemed to be stimulated by it and, assuming an active form, occasioned death from meningitis.

Tentative treatment should, however, be continued always with caution, for even in adults, where the growth of the tuberculous deposit is slow, the tendency of the disease to spread throughout the system is great, and in children its course is often so rapid that general infection may ensue very soon after the appearance of the primary nodule in the eye. It goes without saying that when there is marked evidence of tubercular involvement of other parts of the body, operative treatment upon the eye is of unavail, in so far as effecting any beneficial action upon the general system, the removal of the globe being only indicated under such conditions for the relief of pain or to prevent sympathetic trouble in the fellow eye. Regarding the comparative value of enucleation and iridectomy in this class of cases, the writer believes that despite the considerable number of cases which have progressed favorably after iridectomy without the development of tuberculosis elsewhere in the system, the statistics of Hill Griffith, which showed that of eight cases where attempts had been made to remove the growth by excision of a piece of the iris, enucleation had later on to be performed in every one, indicate that the removal of the entire globe is the better procedure.

The second case, in addition to illustrating the points which have just been discussed, demonstrates the difficulty in diagnosing tuberculosis of the choroid from other intraocular affections, but particularly from gumma of the choroid.

While the precaution was not taken in this case to render its tuberculous nature certain by inoculating the eyes of animals, its structure, as revealed by the microscope, is sufficient proof of its identity, while the absence of any tuberculous lesions elsewhere, both at the time of the ocular disease and during the four

years following the removal of the eye, are sufficient indications of the primary character of the tubercle.

Unlike tubercle of the iris, where the diagnosis is, as a rule, simple, the determination of the character of the ocular lesion in solitary tubercle of the choroid is almost always difficult, as the patients generally come under observation after the disease is well established and ophthalmological examination is impossible, on account of haze of the media. Usually the absence of increased intraocular tension, which is occasioned by the early breaking down of the tubercular deposit, serves to differentiate tubercle of the choroid from intraocular sarcoma, but this negative evidence cannot always be relied upon, for, as in the writer's case and in a series reported by Lubowski,* the tension may be distinctly elevated, the anterior chamber shallow, and other signs of intraocular tumor present. The chief difficulty in diagnosis lies, however, in excluding gumma of the choroid, as the clinical manifestations are the same, and, as is frequently the case, no information can be gathered from the history or the physical examination. Under such circumstances, a diagnosis is alone possible by the microscope, after the removal of the globe.

A CASE OF CONGLOMERATE TUBERCLE OF THE CHOROID.

By THOMAS R. POOLEY, M.D.,
New York City.

From a clinical standpoint the tumors of the choroid of most practical importance are sarcoma and tubercle. At the last meeting of this Society I reported one of non-pigmented sarcoma, by far the rarest form of sarcoma. I now beg to present one of conglomerate tubercle, which from several points of view is very interesting.

On July 6, 1903, I was consulted by a young man aged twenty-six. There was nothing in his general appearance to suggest

*Archiv. f. Ophthal., Vol. 29, p. 278.

a grave constitutional disorder, although he was somewhat emaciated and of a sallow complexion, and he declared that besides the eye disease, about which he came, he had not suffered, except from the usual infantile diseases, but had always been healthy. He denies syphilis and there were no physical signs of tuberculosis present. His mother died of diabetes in her fifty-third year. His father, æt. sixty-five, is still alive, and has never been sick a day in his life, but all of his brothers and sisters died of consumption. For the past year he had suffered from pain and redness of the right eye, which had been alternately better and worse. For a long time (several months) he was under the care of a member of this Society, who treated him with anti-syphilitic remedies, but at the end of six months advised enucleation. He then consulted Dr. Knapp, who also gave the same advice.

When I saw the patient, the eye presented the usual symptoms of absolute glaucoma: wide, immovable pupil, circumcorneal injection, anæsthesia of the cornea, slight opacity of lens, $+ T^2$, no pain on pressure over the ciliary region, $V = 0$, no ophthalmoscopic reflex. Left eye normal. The same day he was admitted to the hospital, and the eye enucleated under ether anæsthesia. The healing was without any incident, and he was discharged on the 13th, with a good conjunctival stump.

The globe was examined by the pathologist of the New Amsterdam Eye and Ear Hospital, Dr. Edward B. Coburn, whose report is as follows:

Macroscopical. — The globe is somewhat irregular in shape, appearing somewhat enlarged in a plane slightly oblique to the antero-posterior axis of the eye, being larger from above and to the temporal side, to the lower and nasal side. This axis measures 30 mm., the one at right angles to this measuring 22 mm. The antero-posterior diameter measures 26 mm. This enlargement is to the outer, upper, and temporal side, just behind the equator. Trans-illumination of the globe shows the pupillary area least illuminated when the light shines through this thick part, which appears more dense and more resistant to the touch. The lower

half of the cornea appears somewhat opaque. The pupil is dilated and irregular.

On section, the anterior chamber is shallow and is partly filled with an albuminous exudate. The iris is pressed forward by the lens, which is surrounded by what looks like condensed vitreous or exudate. The retina is almost entirely detached, only a small portion being adherent over the site of the above-mentioned thickening. Elsewhere it extends from the *ora serrata* to the head of the optic nerve. The enlargement of the eyeball sems to be due to thickened sclera, which measures about 4 mm. in thickness. Measurement of this thickened sclera shows that it extends from the equator about 15 mm. toward the optic nerve. The choroid under this enlargement is also thickened and solid and of a different color from that of the rest of the choroid. This thickened choroid is about 1 mm. thick at its densest part, is flat, and extends in every direction, covering an area about 12 mm. in extent, tapering off toward the ends.

Microscopical. — The circumcorneal vessels are dilated and filled with blood. These appear to merge with vessels from the scleral and episcleral tissue, and extend into the *substantia propria* of the cornea. This corneal infiltration and new vascular formation appears separable into two distinct regions, the anterior one having its origin in the conjunctival and episcleral vessels and extending to and beneath the anterior limiting membrane (Bowman's). From the scleral vessels are continuations extending into the middle and posterior lamellæ of the cornea. These extend so far into the *substantia propria* that only the central portion is free from them. One vessel appears to lie on Descemet's membrane.

The anterior chamber is shallow and contains some albuminous exudate. The angles are closed and the root of the iris is adherent to the cornea.

The iris is infiltrated and thickened. The anterior surface is covered with an exudate membrane, which extends to the pupillary margin and is continuous with an exudate in the pupillary area lying on the lens capsule, and extending backward to a mass

of exudate behind the lens and in the ciliary region. There are several aggregations of round cells in the iris, and the cells here and elsewhere in the eye show marked mitosis.

The lens is normal, except in one part just outside of the pupillary area and beneath the capsule, where the lens fibres are broken, and there is a small area of infiltration with round cells. At this place the intracapsular epithelium is absent, being replaced by round cells. Continuous with and from this infiltrated area is a layer of flat cells, three or four in thickness, but gradually diminishing to a layer of a single cell, extending for some distance to either side of the infiltrated part, between the capsular epithelium and the lens substance.

At either side of the lens, and continuous with the iris exudate and the condensed vitreous behind, is a mass of hyperplastic tissue. This appears to come largely from the proliferated retina at or behind the *ora serrata* and extending forward.

The ciliary body and processes are only moderately infiltrated and but slightly involved in the inflammatory action. The ciliary processes are somewhat entangled in the circumlenticular mass, but not apparently active in its production.

A satisfactory description of the sclera, choroid, and retina is difficult, as the changes are so numerous and the characteristic features of each are so altered in many places that it is quite impossible to distinguish one tissue from another. The thickened part of the eyeball consists of tissue eminently tubercular in character, and here the landmarks are in large measure destroyed.

The sclera is infiltrated in different parts, and many of the nerves and vessels are surrounded by areas of round cells. The linear infiltrations in the cornea extend into the sclera in a similar form (or, more properly speaking, from the sclera into the cornea). Many infiltrated parts consist chiefly of round cells, but numerous ones contain nests of epitheloid and giant cells. The thickened part of the sclera, which occupies about the position of exit of one of the perforating vorticose veins, is composed most of caseous material, surrounded by a zone infiltrated

with round, epitheloid, and giant cells. At one point the diseased tissue does not appear to have been entirely removed when the eyeball was enucleated.

The choroid is everywhere infiltrated, in many places is increased in thickness, especially where the sclera is thickened and near the entrance of the optic nerve. In some places it appears to merge into the retina and sclera in an indistinguishable union. Epitheloid cells are particularly numerous in this structure, and numerous giant cells are visible.

The retina is generally detached except for a limited extent over the thickened choroid and sclera. It is generally hyperplastic and, where not so changed, is infiltrated with round epitheloid and giant cells in a structureless mass. This hyperplasia of the detached retina seems to form the material surrounding the lens.

The optic nerve shows round cell infiltration, but the nerve was cut behind this affected portion.

The result of the staining for tubercle bacilli was positive.

Pathological Diagnosis. — Conglomerate tubercle of choroid, with extension into the sclera and retina, and secondary glaucoma."

The pathological examination of this conglomerate mass, therefore, gives positive evidence of the tuberculous nature of the growth, the result of the staining for tubercle bacilli being positive. In view of the statement made by the pathologist — "at one point the diseased tissue does not appear to have been entirely removed when the eyeball was enucleated" — I think it proper to say that the operation was done in the usual way, that no rupture of the globe occurred, the conjunctiva was circumcised to the corneal margin, and, as it is stated, the optic nerve was divided far back in the orbit behind the affected portion, and therefore it is difficult to see how the operation could have been more thorough without the removal of all the orbital contents, a procedure which did not seem to me to be warranted.

It is well established that tubercular growths in the choroid are met with in the subject of chronic tubercule whose general condition is not such as to be of greater importance than the local affection, and that although the choroidal disease is probably always secondary to tubercle elsewhere, the existence of the latter is often difficult to establish.

Such seems to be the fact in the case here reported. That the diagnosis, in some instances, too, may be made by ophthalmoscopic examination is well known, and cases have been reported by Brailey, Horner, Manz, Carpenter, Schöbl, Hirschberg, and others (*vide* Griffith's Chapter on Diseases of the Choroid Vitreous in Norris and Oliver's System of Diseases of the Eye).

These growths sometimes spring from the disc, as shown by Michel, Brailey, and others, and quite recently Dr. Arnold Knapp has reported one of localized tuberculosis of the head of the optic nerve (Archives of Ophth., Vol. xxxii, No. 1, 1903), in which the eye was removed on the probable diagnosis of glioma. It is obvious enough, however, that in my case no positive diagnosis other than the one of a probable tumor and the supervention of glaucoma could have been made. As would be expected from the fact that tubercle usually causes softening of the tissues in which it originates, the globe generally assumes the form of a general inflammation with rapid formation of a staphyloma, and then it has to be distinguished from panophthalmitis or specific disease, for which this was mistaken, or it may, as shown, occur as an ophthalmoscopic picture, or, as in my case, which is the rarest, under general glaucomatous symptom.

In regard to the prognosis of my case, I will state that I have seen the patient while writing this paper, one year after the operation. He has married since, looks perfectly well, has gained in flesh, and there is no evidence in the appearance of the stump of any return of the disease. In order, however, to be better advised as to his physical condition, I referred him for examination to Dr. G. R. Russell, whose long experience in the diagnosis, observation, and treatment of tuberculosis, makes his report of much value and importance.

His report is as follows:

POST. GRAD. HOSP. DISP.,
July 8, 1904.

My dear Doctor Pooley:

Thank you for the opportunity of examining Chas. Hedde. I find no physical signs of disease. Should he develop any symptoms later I shall be happy to examine him again any time.

Very truly yours,
JOHN F. RUSSELL.

In considering, in a general way, prognosis and treatment, I agree with Griffith (l. c.), that we are not justified in removing every eye affected by tuberculosis, in the hope of preventing general infection. This should only be done when the eye is either lost or the course of the disease is of a markedly rapid and progressive character. But the eye should be carefully observed, and the disease treated with the usual remedies. In the treatment of the general disease, the use of Russell's emulsion has been found of great value. Death may occur, — whether or not enucleation has been performed, — from tuberculosis of any organ, but not with the same frequency that it does in miliary tubercle of the choroid. Thus, as pointed out by Griffith, in the summing up of the whole matter, it is more than probable that the dissemination takes place, not from the affected eye, but from the lighting up of activity of some latent focus in the interior of the body.

DISCUSSION.

DR. GEO. E. DE SCHWEINITZ. — In connection with these two papers on tuberculosis I would like to exhibit and put on record briefly an analogous, or identical condition.

This eyeball was removed from a colored child three years old, who had tuberculosis of the lymph glands and symptoms of tubercular meningitis. The eye presented the appearance often seen in some forms of intraocular tumor. It was displaced to the right, and the pupillary space occupied by white exudate. The growth springing from the choroid is well shown in this

preparation made by my associate, Dr. Shumway. From this eye a small piece was placed, in the usual way, in the anterior chamber of a rabbit's eye, and at the end of the third week tuberculous iritis was evident, and this is the section of the rabbit's eye, in which you can see the tuberculous nodules. Sections of the growth, from the child's eye, represented in this slide, show the ordinary histological appearance of tuberculosis of the uveal tract and tubercle bacilli. The sections from the rabbit's eye show the same characteristics and a most unusual development of the tubercle bacilli.

I simply record the case in connection with the others, reserving the details for further publication.

DR. WALTER L. PYLE. — I would like to call attention to the relative infrequency of reports of tuberculosis of the choroid in America in comparison with those in Great Britain. I was struck with this fact at a meeting of the Ophthalmological Society of the United Kingdom in 1901. It was quite common at that meeting to hear of tuberculosis of the choroid. One prominent gentleman told me that tuberculosis of the choroid was of very common occurrence there, even in adults, and I made a mild protest against this statement. I said that certainly that was not the case in the United States, but notwithstanding considerable argument the greatest concession he would make was that "it was not infrequent." In the meetings of the British societies we frequently see reports of cases, and in the British literature there are numerous reports. A number of these are in children. It has been my experience that tubercle of the choroid, except in acute miliary tuberculosis, is a very rare disease. Tuberculosis of the choroid in children I have seen, as well as intraocular tubercle in cases of cerebral tuberculosis, but I was struck with the apparent frequency of these conditions in Europe.

DR. H. F. HANSELL. — As to the tests upon which we rely usually for diagnosis, the discovery of the bacilli and the inoculation tests, I would say a word. I had a case of tuberculosis of the choroid, sclera, and conjunctiva. The man had lost ninety pounds in six months, had large cavities and all the physical signs of tuberculosis, and in two or three months he died, when the diagnosis of tuberculosis was confirmed. At the first examination I diagnosed tuberculosis of the eyeball, but numerous bacteriological examinations made of the parts cut from the conjunctiva

failed to demonstrate tubercle bacilli. I had pieces taken from the swelling in the conjunctiva that was distinctly tubercular in appearance, and inserted into the anterior chamber of the guinea-pig, and though this was repeated several times no tuberculosis developed in the animals. I have noticed in published reports that others have had similar experiences. The diagnosis of tuberculosis is positive when the bacilli are found, but cannot be excluded when they are not found, or even when the inoculation experiments are not successful.

DR. B. F. FRYER. — I should like to ask the gentlemen who have reported these cases if at any time during the watching of the patients there was any elevation of body temperature observed? We generally find in tuberculosis a slight evening rise of temperature.

DR. W. F. MITTENDORF. — We all agree that the diagnosis in these cases is extremely difficult, and in many cases is only to be made by excluding other possibilities. I have therefore kept under observation three cases, two of which have been published: one a young man; twelve years old when I first saw him and now twenty-two; one case of miliary tuberculosis of the iris, which was seen by several gentlemen, and the man is now twenty-eight or twenty-nine years old; and the third, a lady that I have had under observation for a number of years, who has a single tubercle of the iris that reminds me very much of the picture that Dr. Posey has shown here, and this patient has been under observation at least ten years without any change taking place. In all these cases there have been, however, mild attacks of iritis now and then; attacks entirely different from those of specific iritis; very mild attacks, the inflammation subsiding rapidly upon treatment. I think, therefore, as Dr. Posey has said, that enucleation of such eyes should be deferred unless there are very alarming symptoms, because the patients will, under favorable circumstances, get along all right for many years.

It is undoubtedly a fact that tuberculosis of the eye, and especially of the choroid, is not so frequent here as in Europe, and the only explanation, I think, is that our lower classes are much better nourished, are in much better physical condition, and so not so liable to the affection.

DR. T. R. POOLEY. — In regard to the question raised as to the rise of temperature in these cases, it is a singular thing, and

perhaps important to notice, that there is really no record of that in our ophthalmological cases, as a rule. We are apt to observe things from a one-sided standpoint. We all preach the importance of examination of the fundus oculi in cases of otitis suppurativa, though few of us really do it. The same thing holds good in many other conditions.

Yesterday, before the Otological Society, I presented a case of fibroma of the external ear in which the clinical diagnosis was plainly that of a malignant growth, and I made the diagnosis sarcoma. Evidence of sarcoma was, however, wanting in the examinations, and yet the tumor recurred and was finally cured only by means of the X-ray.

In concluding, I would say that the macroscopical specimens I had intended to present had not sufficiently hardened. The slides are here under the microscope.

DR. W. C. POSEY. — As to the question raised concerning the rise of temperature I would state that it was not taken in the first case, the child being an out-patient and the opportunity of so doing being not afforded. In the second case it was taken during the intervals the patient was in the hospital, and my recollection is that there was a rise of temperature, which might be accounted for, however, by the local reaction in the eye.

I should like to refer to the point raised by Dr. Hansell as to the negative inoculation tests with animals' eyes. As stated, in my first case the inoculation of guinea-pigs' eyes was negative, except for the production of a traumatic cataract. The pigs died three weeks after inoculation, but the cause of death could not be ascertained. It would seem that the guinea-pig, for some reason, doesn't take the tubercular test, or that the tubercular material is so virulent in its action upon the animal that it produces death before the local ocular manifestations can occur.

A CONGENITAL INTRAOCULAR TUMOR CONTAINING EPITHELIUM AND CARTILAGE.

BY A. N. ALLING, M.D.,
NEW HAVEN, CONN.

George Wormcke, four years old, was brought to me April 13, 1903. No specific or tuberculous history was obtained from the parents. He was the only child and apparently healthy. Two

months before, the parents had noticed a white spot in the right eye, which would occasionally become red. There was no definite history of traumatism.

A reddish-gray, somewhat translucent, tumor was seen in the anterior chamber of the right eye. It was lying over the iris on the temporal side and was in contact with the posterior surface of the cornea at the periphery. It reached nearly to the pupillary edge. Pupil slightly irregular and immovable in the region of the tumor. A deeply pigmented mass, which filled about one-half of the pupillary area, could be seen back of the iris, in a position corresponding to that of the tumor in front. The lens, which was displaced inwards by the tumor, was clear. That part of the interior of the eye which could be examined through the unobstructed portion of the pupil was normal. There was a trace of ciliary congestion. Tension normal. Vision could not be exactly determined, but was at least 20/200.

Ten days later there seemed to be a slight increase in the size of the tumor. Under the impression that we had to deal with a malignant growth the eye was enucleated April 24, 1903. There was nothing abnormal in the orbital cavity. On June 1, 1904, there was no recurrence of the growth and the stump was healthy.

The eye was preserved in formalin and, after freezing, was divided by a section through the tumor. A mass about 8 x 10 mm. in size, apparently springing from the root of the iris and the ciliary body, occupies the vitreous chamber on the temporal side. A smaller part extends into the anterior chamber. The iris thus lies between the larger and smaller portions, while on the median aspect of the tumor in the vitreous there is a layer of pigment evidently split off from the iris and ciliary body. A few scattered areas of pigment are found in the tumor. The mass in general is creamy-white, except in the center, where there is a well-defined area of purer white.

Dr. Arnold Knapp prepared the specimen for microscopic examination, and his report is as follows:

Pathological Report. — Imbedded in celloidin. Hematoxylin-eosin stain. In the section showing the most extensive changes

Dr. Allings case Congenital Tumor of Eyeball.

we find the iris at its root and the adjoining base of the ciliary processes occupied by a tumor formation which has detached the ciliary processes and has completely interrupted the iris. In this part the tumor is composed of cells closely crowded together with large, deeply-stained nuclei, which resemble epithelium. The extension of the tumor into the anterior chamber presents large oval spaces, lined and partly filled with large, uniform epithelial cells (endothelium), with an amorphous network and globules in the center. The tumor as it extends backward has apparently distended and then perforated a ciliary process, as it is partly surrounded by a row of pigmented cells. Adjoining the ciliary processes the cells are often arranged in a circle about a lumen like the "rosettes" occurring in glioma and teratoma. The tumor, as it extends backwards into the vitreous, changes in character. The cells are smaller and branching, and the tissue becomes looser-meshed, resembling myxomatous tissue. The most interesting features in this part of the tumor are circumscribed areas of cartilage. These areas are surrounded by a well-marked fibrous capsule, although, in some places where the capsule is less dense, the transition to cartilage can be followed.

The eye presents no other microscopic changes beyond a cataractous formation of the lens in the part adjoining the tumor, and a very marked cystic (hydropic) degeneration of the basement layers of the corneal epithelium. There are no inflammatory changes.

The tumor, in brief, consists of an undifferentiated (embryonal) tissue which contains distinct epithelium and cartilage. Its origin is apparently in the stroma of the iris and of the ciliary processes. It appears to have no relation to the epithelium covering the ciliary processes, hence cannot be classed in that group of tumors of the ciliary body spoken of as glioma, adenoma, etc.

Concerning the presence of cartilage within this tumor, it may be said that chondromata are only occasionally seen in the body away from the localities where cartilage and bone are normally found, as, for example, in the parotid gland, testicle, and ovary. Although cartilage is normally present in the eyes of some birds,

in the human eye is is exceedingly rare. Knapp and Alt record cases in which islets of cartilage were found in sarcoma. Collins and Mitvalsky found plates of cartilage in microphthalmic eyes. Jackson, Pes, Sgrosso, Fantabella, Stoewer, and Moauro have reported cases where this tissue was formed in phthisical eyes or in connective tissue of inflammatory origin. Our case is unique in that the eye was normal, with no trace of inflammatory action. A reasonable explanation, therefore, for the presence of the cartilage is the supposition that it arose from misplaced chondroblasts, or a matrix composed of embryonic cartilage cells.

In regard to the tissue which constitutes the principal portion of the growth, it is certainly difficult to classify except as non-differentiated or embryonic. The cells near the iris and ciliary body, however, are epithelial or endothelial in character. Pergens, Alt, Badal, Lagrange, and others have described epithelial tumors arising from the epithelium of the ciliary body and pars ciliaris retinæ; nevertheless this tumor cannot be classified in the same category, as it does not arise from this source. It is possible that the cells are endothelial, and that we have to deal with an endothelioma. Such tumors of the ciliary body, as far as my knowledge goes, are not described.

The growth is probably congenital, and being composed of varieties of tissue not normally present in this locality would probably be called a teratoma.

DISCUSSION.

Dr. B. F. Fryer. — This is certainly a very interesting report of an almost unique condition, and is especially interesting to me as tending to confirm the still much disputed Cohnheim theory as to the origin of tumors.

Dr. B. A. Randall. — I have met a case with hyaline cartilage, less typical than that described by Dr. Alling, in which there was also ossification of the choroid.

Dr. F. H. Verhoeff. — Doctor Knapp kindly sent me some specimens of this case, stating that he regarded the tumor to be composed of cartilage and epithelium. I at first thought the cells

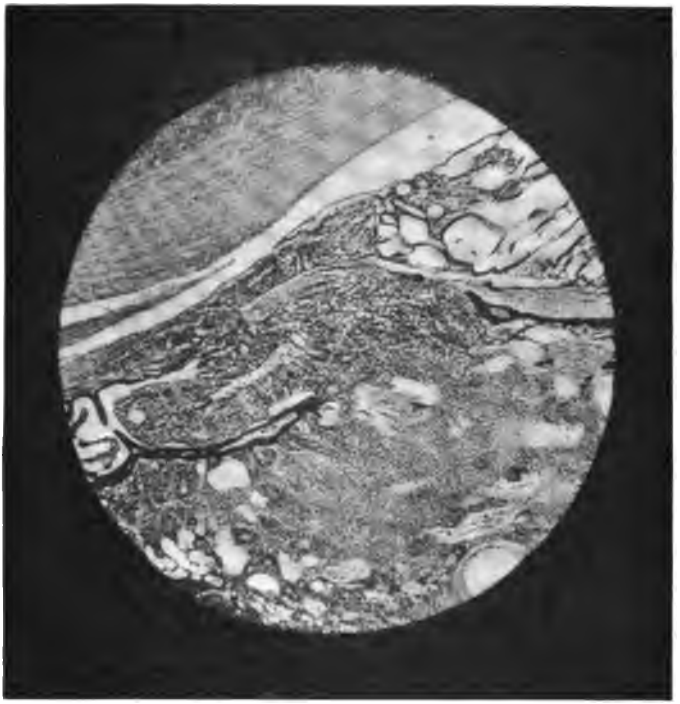

MICRO-PHOTOGRAPH.

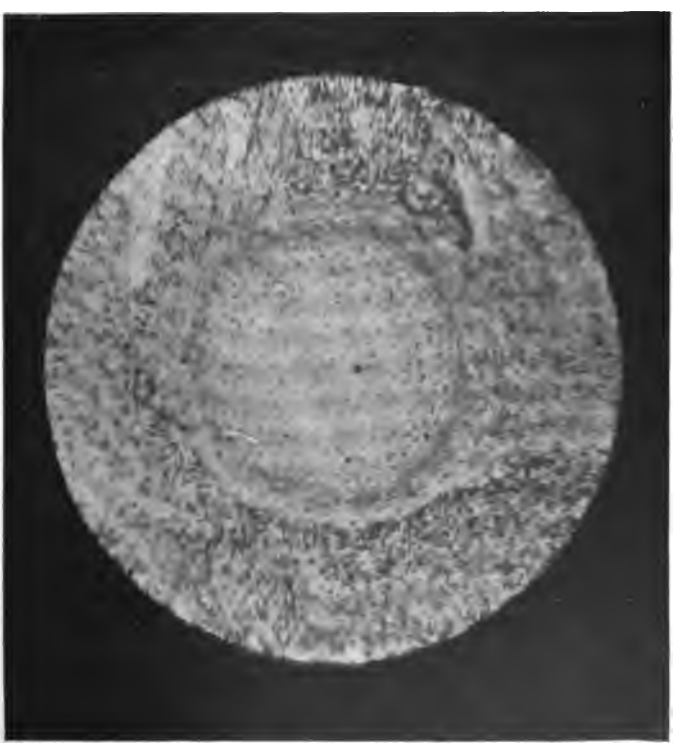

CONGENITAL TUMOR—ALLING.

resembled epithelium, but after further study I concluded that the tumor was really an endothelioma of a distinct type. I do not think a tumor of this kind has ever been reported as occurring in the eye before, but elsewhere in the body such a tumor is sometimes met with. The endotheliomata are not very well understood, but there are certain classes generally recognized as such, to one of which, I think, this tumor belongs. It seems to take its origin from near the root of the iris, and the most probable origin is in the spaces of Fontana, because there the endothelium has the most complicated arrangement. The cells in the anterior chamber are very small, and identical in appearance with the endothelial cells lining the posterior surface of the cornea and anterior surface of the iris. These gradually pass into connective tissue, and take on the character of connective tissue cells. That is one of the characteristics of certain endotheliomata, that they form connective tissue. The presence of cartilage is not unusual in endotheliomata; it has been described in endotheliomata elsewhere, though not, perhaps, in the eye. The tumor is evidently locally malignant, if not in a general sense so. Endotheliomata do sometimes produce metastases, but not usually. This tumor has infiltrated the ciliary body and iris, and has even invaded the corneo-scleral junction to a slight extent.

DR. A. N. ALLING. — This case seemed to justify enucleation because the parents, who were quite intelligent, insisted that the tumor was not present three months before. Further, I myself thought the tumor was increasing in size. Dr. Verhoeff also seems to think it was malignant in character.

A SEVERE CASE OF UVEITIS TREATED WITH RADIUM.

BY CHARLES H. WILLIAMS, M.D.,
BOSTON, MASS.

The report of a single case can be excused on account of the rarity of the case, or because it shows that some new form of treatment can be used without injury to the eye, and with such good results as to encourage its use in other cases, and it is on the latter ground that this case is reported.

Mrs. E., æt. forty, consulted me in April, 1903. Her right eye had been enucleated, and in the left there was considerable interstitial opacity of the lower third of the cornea, some posterior synechiæ, and deep circumcorneal injection of the blood-vessels, extending back over the whole ciliary region, and giving the sclera a purplish color. There are occasional pains in the eye, not severe; the vision has been failing for some years and is now a little better than 3/10; not improved by glasses. Her general health is good, although she has had a few slight attacks of rheumatism. She has no children, but the family history is good, except for one case of supposed scrofula.

She has been under the care of three other oculists of good standing, and I am indebted to Dr. Wadsworth for the following notes of her case for the three years before I saw her:

"Mrs. E., æt. thirty-seven, consulted me first October 8, 1900; many years before she had pains in hand and fingers, attributed to gout. Her general health has been good; she is much in the open air. In 1895 or 1896 she had an inflammation of the left eye, and in 1898 of the right. With the first attack KI gave apparent relief; with the second it disturbed her digestion. She says the present attack of inflammation in the right eye has continued for about four months. The right eye now shows general ciliary congestion, the upper ciliary region bulging, with two small, dark ectasiæ; cornea cloudy; iris turbid, pushed forward, at part of the periphery in contact with the cornea, its pupillary edge attached to the lens; no reflex; T normal, V perception of light. Left eye: ciliary region clear, but easily flushing, whitish, interstitial opacity of the lower half of cornea, pupil reacting moderately, but several posterior synechiæ, fundus apparently normal, V = 20/30.

"Under the use of atropine and general hygienic measures the right eye became less congested and somewhat more comfortable, but by November the ectasiæ were larger, and on November 9, 1900, the eye was enucleated. Macroscopically, the lens and vitreous were clear, and there were no changes behind the ciliary body.

"In October, 1902, there was a little ciliary congestion outward and downward in the left eye, vision with plus 0.5 and plus 0.5 cyl. ax. 90 was 20/25, fundus normal. In January, 1903, she reported that there had been some congestion for six weeks. There was general moderate ciliary congestion, increased and with some swelling over a rounded area downward and outward, corneal opacity much as before, but showing some deep vessels, pupil, etc., as before, vision = 20/30 plus; not much discomfort. General health very good; was taking lithia and much water. For the next six weeks there was no change, except that the congestion became somewhat less. She took KI and iron. Her physician could find nothing wrong on careful general examination, but a gynecologist whom she consulted found displacement of the uterus, which apparently caused no disturbance.

"March 5, 1903, she complained of blurring of vision for several days, vision with plus 0.75 cyl. ax. 90 = 20/56, the eye in other respects as it had been."

When I first saw her, April 2, 1903, the vision was 3/10, the fundus could be seen, and nothing abnormal was found there. The interstitial opacity of the cornea covered nearly the lower third. With atropine, cocaine, and adrenaline a moderate dilatation of the free parts of the pupil could be had. The circumcorneal congestion extended over the whole ciliary region. The tension was normal, but the eye was sensitive to the touch. Atropine and dionine were used in the eye, and full doses of salicyl soda internally.

During the latter part of May, although the circumcorneal injection was less, there was an increase in the corneal opacity; small round dots of opacity would develop in the clear cornea a little in advance of the rest of the opaque area; these points would soon become surrounded by a halo of interstitial opacity, which, coalescing with the neighboring spots, would steadily advance the area of the opaque part. There was at no time any ulceration or break in the epithelial layer. June 3d she was given pilocarpine sweats three times a week, and protiodid. of Hg., which was later changed to mercurial inunctions. There was at this time some

exudation into the field of the pupil, and the vision had fallen to 1/10. June 26th the pilocarpine was stopped, but the inunctions were continued, and on July 24th the vision had improved to 2/10, and the exudation in the pupil was disappearing. August 18th the inunctions were stopped, and she was again given KI. The vision was now 4/10, and by September 23d it had increased to 5/10, with a marked reduction in the amount of circumcorneal congestion. By the middle of October there was another increase in the inflammatory conditions of the uveal tract, but no fresh blocking up of the pupil. The vision was still 4/10. Pilocarpine and inunctions were renewed, with atropine for the eye.

By the end of November there was considerable increase in the opacity of the cornea, with the ciliary congestion about the same, and as the treatment by inunction and pilocarpine, which had worked well before, now seemed to be doing no good, they were stopped. She was given large doses of salicylate of soda, and for two weeks there was a marked improvement in the ocular conditions. This did not continue, and by the first of February the corneal opacity had extended so that vision was reduced to counting fingers at about ten feet. It was then decided to try the effect of radium, to see if it would have any effect in clearing the cornea and reducing the ciliary inflammation.

My brother, Dr. Francis H. Williams, while in Paris last summer, was able to get some pure bromide of radium, with which he has been having some very good results in the treatment of lupus and other diseases in which he had formerly used the X rays, and he was asked to try the effect of radium on this case. From the first of February, 1904, to the end of May about thirty applications were made, at first three times a week, for two weeks, then omitting the treatment for a week, and afterward either two or three times a week with occasional intermissions until May 21st, when the use of radium was discontinued. During this time there was no other treatment, internal or external, except a mild collyrium of borax and boric acid to the eye. The pure bromide of radium, of a strength equal to 1,500,000 times that of uranium, with which it is compared, was held just clear of

the eyelashes with the eyelids open for about one minute. At first there seemed to be, at times, an increase in the circumcorneal congestion after the applications, and at other times there was no change. There was never any complaint of pain, and during the last part of the treatment the patient said the eye felt more comfortable after the applications.

March 1st, about one month after the radium was first used, the cornea showed a decided clearing at the upper and inner part, and the vision had increased to 1/10. March 11th the applications were increased to two minutes, in periods of one minute each. March 22d there seemed to be a slight roughness of the corneal epithelium, and the vision had fallen off to fingers at fifteen feet. This was, however, a very temporary set-back, and three days later the corneal roughness had disappeared and the vision was up to 2/10. March 29th the applications were increased to three minutes, in periods of one minute each, but the distance of the radium was increased to about half an inch from the eye, the intensity of the action being inversely as the square of the distance. April 15th the vision had increased to 4/10. May 18th it was nearly 5/10, and the fundus could be seen with the ophthalmoscope for the first time since June, 1903. May 21st the vision was 5/10 except the letter B, which was called R, and with a plus 1 the reading power was 5/6, although the surface of the cornea was so irregular, as seen with the ophthalmometer, that the retinal images were quite blurred, and the eye soon tired when used for near work, and also glasses did not make any marked improvement in the vision.

The radium was now discontinued, as the cornea had become apparently as clear over the upper and inner portions as when first seen, and even at the lower part it seemed less dense than formerly; there was also very little circumcorneal congestion, but the eye still remained very sensitive to cold and damp weather, and feels distinctly worse if she gets wet or chilled.

It is impossible to say that the improvement in this case was due to the radium, although for the last four months no other treatment was used, but the case does show that a specimen of

pure radium bromide can be used about the eye without danger, provided it is used with care.

I have recently had two additional cases that have also been sent to Dr. Francis H. Williams for radium treatment. The first was a central ulcer of the cornea in a man of about forty, where, with a strong oblique illumination and a magnifying lens, an infiltration could be seen gradually extending from the seat of the ulcer into the corneal tissue until it had covered the whole pupillary area. Under five applications of radium this infiltration disappeared, leaving the cornea clear, and the ulcer healed rapidly.

In another case of acute iritis with several relapses and much turbidity of the aqueous, the application of radium seemed to hasten the clearing of the aqueous. My brother tells me that he has also used radium with apparently good results in some cases of trachoma. The cost of radium is the principal obstacle to a more extended trial of its usefulness, and little effect can be expected from the weaker preparations, which are the only ones to be had at present in our markets.

Day before yesterday, since this paper was written, Mrs. E. again came to my office. Her general health does not seem to be so good as when I last saw her, but the only thing she complains of is the diminished vision. There is a slight increase in the circumcorneal congestion, and the opacity of the cornea is slightly increased, but in the pupil there is a new deposit of inflammatory material, and the vision is now reduced to 1/10.

It remains to be seen whether radium and atropine will again bring the vision up to the former figure.

The other two cases are doing well.

DISCUSSION.

DR. SAMUEL THEOBALD. — I would like the doctor to tell us if in the case of central ulcer the treatment consisted wholly of the radium bromide, or whether any other treatment was used?

DR. WILLIAMS. — Atropine had been used, and it was continued right along. Atropine had been used for some weeks before the radium was tried, and with it there was extension of the ulcerative process.

DR. T. R. POOLEY. — Was it a septic ulcer?

DR. WILLIAMS. — I made no bacteriological examination of the discharge from the ulcer. There was no history of any septic exposure.

DR. H. W. RING. — I would like to ask Dr. Williams how he used the dionin: was it in powder?

DR. WILLIAMS. — In the form of a solution.

DR. RING. — Did you get a typical reaction?

DR. WILLIAMS. — There was some pain and some chemosis.

SOME OBSERVATIONS ON THE PROGNOSIS AND TREATMENT OF HYPOPION ULCER OF THE CORNEA.

BY CHARLES J. KIPP, M.D.,
NEWARK, N. J.

In a paper entitled "The Treatment of Serpiginous Ulcer of the Cornea," which I read at the meeting of the American Medical Association, Section of Ophthalmology, in 1902, and which is published in the *Journal of the American Medical Association,* August 2, 1902, I made the following statement:

"More than twenty years have now passed since I first observed that certain cases of serpiginous ulcer of the cornea, in which no further progress was noticed after they came into my hands, presented the features I am about to describe, and since then I have not seen a case in which they were present that did not heal under very simple treatment.

"From the margin of the ulcer straight or nearly straight lines, broadest at the ulcer and gradually tapering, diverge in all directions somewhat obliquely, through the parenchyma of the deepest layer. They never give off branches. The further end

of these diverging lines are connected by grayish intermediate striæ, of the same width throughout, and running at right angles to them. If present all around, these intermediate linear opacities form a complete ring of the same form as the margin of the ulcer, but situated more deeply, and 3 or 4 mm. distant from it. Sometimes a smaller ring is seen between the outer ring and the margin of the ulcer. The cornea between the opaque linear opacities here described is cloudy, but that outside of the outer ring is usually of normal transparency. An ulcer situated in the central part of the cornea, with these striæ well developed, may be compared in appearance with a spider's web. In all of the cases of this kind seen by me the ulcer was at least five days old. I have never seen the picture develop in cases under treatment. The opaque lines gradually disappeared as the ulcer filled up. A few years ago I made no microscopic examination of the exudation on the ulcer, but have done so recently, and while I have found the pneumococcus usually present in the progressive cases, I have been able to find but few in any one of the cases presenting the above-described features. I think I am justified in assuming that the ulcer in these cases has ceased to be progressive, and that any treatment which involves further destruction of tissue, or the danger of anterior synechiæ, is entirely unnecessary and should be dispensed with. I feel so sure of this that even in the cases in which blennorrhea of the sac was present I have done nothing more in the way of surgical procedures than to split the canaliculus. In these cases the symptoms of the irido-cyclitis are usually not very severe, and the hypopion rarely fills more than the lower third of the anterior chamber. As I have already said, such cases always got well, and the only treatment required was warm fomentation with boric acid solution and instillations of a mydriatic. In all cases I was able to break up the posterior synechiæ by a one or two per cent. solution of sulphate of atropine, repeated often during the first day and less frequently after that. In most cases I have tried to expedite the complete cicatrization of the ulcer by gentle massage with a salve containing a small quantity of the yellow oxide of mercury.

The opaque striæ here described and regarded by me as an evidence of the arrest of progress, were first described, as far as I know, by Saemisch in his famous chapter on the diseases of the cornea, and von Michel, in his description of the serpiginous ulcer of the cornea, corroborates what Saemisch has said about them. Both of these authors describe the linear opacities as of common occurrence in such ulcers, but neither of these writers looks upon them as a sign that the ulcer has entered into the retrogressive stage. I have seen these linear opacities so often that it seems exceedingly strange to me that men of such large experience as Fuchs, Schirmer, and Vossius have never seen the intermediary lines encircling the margin of the ulcer. I may mention here that I have been unable to find any reference to these linear opacities in the description of serpiginous ulcer in any American text-book. Whether or not the diverging opaque lines are due to folds in Descemet's membrane, as Schirmer seems to think, or are due to cell infiltration, as is held by Schmidt-Rimpler, I do not know; their similarity in appearance to the opaque lines diverging from the corneal wound sometimes seen after cataract extraction cannot be denied, but I have never seen in such cases the ends of the lines connected by the intermediary linear opacities. To me the diverging linear opacities have always seemed to extend obliquely to the inner layer of the cornea, although Schirmer says that they are all in the same plane and in the deepest layer. I may say here, in passing, that I have seen precisely the same picture in cases of so-called abscess of the cornea, and in these cases, also, no further progress was noticed after the development of the linear opacities."

Since then I have seen many other cases presenting the features above described, and all of these, too, have healed without other treatment than the one above mentioned.

My object in referring to this matter once more is to add to the above the result of a further study of the infected or hypopion ulcer of the cornea. During the last two years I have observed that in the cases in which the straight diverging greyish lines radiated from *all* parts of the margin of the ulcer, if this was situ-

ated in the central part of the cornea, or from the margin nearest the center of the cornea if the ulcer was situated near the periphery of the cornea, did as well under the simple treatment of warm fomentation of boric acid solution and instillations of a solution of atropin, as the ulcers in which the straight diverging linear opacities were connected by the greyish intermediate striæ, described in my first paper. In cases in which the greyish linear opacities were seen only on a part of the margin of the ulcer at the time the case came under observation, I have usually resorted to this same simple treatment for a day or two, and have often seen the striæ develop from the parts of the margin which was free from them when first seen, and further progress was arrested. In other cases of the same class, the ulcer continued to progress, and the margin of the ulcer from which no greyish striæ radiated became somewhat raised and of a yellowish color, and from here the ulceration advanced. The bacteriological examination in many of these cases failed to reveal the presence of pneumococci or other bacteria in the scrapings from the ulcer. With regard to the involvement of the iris and the ciliary body, these cases did not differ from those described in the first paper. As to the treatment of the cases in which the linear opacities above described were absent, my views may be found in the paper published in the *Journal of the American Medical Association* of August 2, 1902.

DISCUSSION.

DR. J. A. ANDREWS. — Has Dr. Kipp used argyrol?

DR. KIPP.— In these cases I use only atropin and sterile water. I use argyrol in other ulcers and have used it to mark out the outline of the ulcer, instead of using fluorescein.

DR. ANDREWS. — I think argyrol is one of the most valuable germicides we have at the present time. I have been interested in the silver combinations for many years. When the first preparation of organic silver compound was placed on the market it was a disappointment, but it was thought that a stronger percentage of silver might give better results, because I had learned

from Fraenkel of Vienna that it was the silver that was the germicide and nothing else. Up to the time that protargol was put upon the market, with its eight per cent. of silver, I felt that all the preparations were more or less disappointing, because they produced irritation. Then, when albargin came to us, with its fifteen per cent of silver, I felt that we had at last something that would meet the indications: a preparation non-irritating, penetrating, and germicidal; but it was the most disappointing of all, because the most irritating. A little over a year ago, when argyrol, with its thirty per cent. of silver, the preparation given us by Dr. Barnes, was placed on the market, I had grave doubts as to its value, and it was some time before I tried it. The first case in which I used it was one of infected ulcer, involving three-fourths of the periphery of the cornea, and its action was almost like magic. The nasal passage having received due attention, the eye was frequently irrigated with a hot (140 degrees F.) solution of boric acid, and the patient was given to instill into the eye at home a fifteen per cent. solution of argyrol, and at the office I applied a fifty per cent. solution of the same compound. The cornea cleared up completely without my being obliged to use the cautery. The case was one of ulcer of the cornea, complicating an acute conjunctival inflammation, due to infection from the nasal passages.

Another point in connection with argyrol that I think is of very great value is that it is, so far as I have been able to determine, free from irritation.

AN UNCOMMON CONGENITAL ANOMALY IN THE VITREOUS CHAMBER AND THE INNER MEMBRANES OF BOTH EYES.

By CHARLES J. KIPP, M.D.
Newark, N. J.

(With three colored drawings.)

The drawings shown here are taken from both eyes of a boy ten years of age. He was born in this country; both parents are natives of Italy. He has eight brothers and sisters, all of whom, as well as the parents, have normal eyes and are in good health.

The boy is well developed, and apparently without other defect. Intellectually he is decidedly deficient. The right eye is of normal form, and the eye socket seems to be of normal size. He can move the eye in all directions without difficulty, but forced abduction causes violent nystagmatic oscillations in the horizontal meridian. Horizontal nystagmus is also produced by attempts at examination of the eye, and by almost anything that excites him. His vision is greatly impaired. He counts figures at about ten feet with either eye. The visual field can not be made out on account of the boy's mental deficiency. His parents tell me that his vision has never been better than it is now, and that he has had at no time an inflammation of either eye, or that the eyes have ever been injured accidentally. He came to the hospital at the request of his teacher, who found out that he was partially blind.

The anterior part of the eye is normal in every respect. There is no injection of the conjunctiva; the cornea is perfectly clear and of normal form. The anterior chamber is of normal dimensions and the aqueous of normal clearness. The iris is normal, the pupil of medium size and reacts normally. It is dilated ad maximum by atropin. The lens is of normal form and clearness. The vitreous is perfectly clear except in the outer third of the chamber, where there is a bluish-white mass, somewhat conical in shape, with its apex near or at the retina. This mass appears to be composed of almost transparent membranes, in the nasal portion of which, anteriorly, there is seen a tubular formation, the outer extremity of which flares, seems to be turned up all around, and from which project numerous thin processes pointing in all directions. (See Fig. I.) This tubular formation is of a dark color, almost black, as seen with the ophthalmoscope. Its diameter is about that of the largest retinal vessel. Its inner termination is somewhat broadened, but its end gradually fades away in the bluish-white mass. The whole mass, including the tubular formation, is stationary and does not float. The anterior part is best seen with a +12D glass. It can also be seen with oblique illumination. It then appears very white and opaque,

and of the shape of a distaff. The optic disk is best seen with a —2D glass. The disk is very white, it seems small, somewhat irregular in shape, and on its nasal side it is bounded by a crescent of very dark pigment. (See Fig. II.) On its temporal side its boundary can not be made out. The central vessels emerge near its supposed temporal edge. Adjoining the outer part of the disk there is apparently a cleft in the choroid, which continues outward for a distance of about two diameters of the disk. From here on outward, almost to the limit of the ophthalmoscopic field, there is in the retina, or the same is covered by, an intensely white mass, at the temporal end of which are several bright red patches, in appearance not unlike fresh extravasations of blood. Beginning at the disk the cleft is about the width of two-thirds of the disk's diameter, and its middle is on a line with the center of the disk. It continues to be of this width for a distance of about two diameters of the disk. Up to this point its color has been whitish-blue. From here on it is somewhat narrower, and of a grayish-white color. Further out it becomes again much wider, and of a distinct white color. Near the disk the margin of the supposed cleft is lined by pigment, and further on, adjoining its lower margin, are several very white patches, bounded by and upon which are masses of pigment. Of the vessels emerging from the disk, the largest pass on to the coloboma, and continue on the same for a distance of two diameters of the disk. Here the main trunks pass off above and below on to retina, and turn backwards and upwards. Some small vessels are, however, continued on the whitish-gray band. I can distinctly make out both an artery and a vein, both in the upper and lower portions, and smaller retinal vessels in the middle of the supposed cleft. No choroidal vessels are visible. A little beyond the point where the large vessels leave the cleft, there seems to spring from the grayish band a whitish membranous mass, which seems to be connected with the bluish-white mass in the outer third of the vitreous chamber. Through this membranous mass it is seen that the white mass is on the retina, extends almost to the limit of the ophthalmoscopic field; it becomes broader beyond the place from

which the membrane springs into the vitreous chamber, and is bounded by a silvery, shining mass above. At several places above and below this band there are also small shining white dots in the retina. Beyond its outer end the normal choroid is visible for a short distance.

The left eye (see Fig. III) presents almost the same appearance, except that at the outer end of the whitish band, in or on the retina, there are vast disturbances in the arrangement of the pigment. Here are large plaques of choroidal atrophy, with patches of pigment on same, and all more or less fringed with pigment. The mass in the outer third of the vitreous chamber does not extend forward as far as in the right eye, but otherwise it is like it, and has the same tubular formation in it.

There can be no doubt, I think, that the anomaly above described is congenital. Its symmetrical presence in both eyes, as well as the coloboma in the choroid, and the arrangement of the retinal vessels, would seem to make this certain. I have been unable to find a description of a nearly similar condition in the literature at hand. As regards the tubular sheath and the membranous formation surrounding it, seen in the outer third of the vitreous chamber, I think that Hirschberg (Einführung in die Augenheilkunde, 2te Hälfte, I Abtheilung, p. 206) is right in his belief that it must be regarded as the persistence and condensation of the connective tissue surrounding the foetal artery of the vitreous body. In most of the cases in which this was seen it appeared as a bluish tube, extending from the region of the optic papilla, in which there was always an irregular distribution of pigment of the eye ground, through the vitreous chamber forward; it was fixed to the background by tent-shaped membranes composed of threads; from its body it sent out winged-shaped processes to the retina, and from its outer extremity radiated fine fibres and membranes diverging towards the posterior surface of the lens. Amblyopia, with central scotoma and convergent strabismus, was always present. In the case here reported it seems probable that the tubular body became detached from the posterior surface of the lens, and was pushed

into the outer third of the vitreous chamber, where it became fixed, at some time during the development of the vitreous body. Posteriorly it was fastened to the coloboma of the choroid, at some distance outward of the optic papilla. I have described a somewhat similar case under the title "A Case of Persistent Hyaloid Artery in Both Eyes," in the Archives of Ophthalmology and Otology, Vol. III, Part I.

THE BACTERIOLOGICAL DIAGNOSIS OF THE DIPHTHERIA BACILLUS, ESPECIALLY IN CONJUNCTIVITIS.

BY ARNOLD KNAPP, M.D.,

NEW YORK CITY.

There are two bacteria that resemble the diphtheria bacillus except in virulence: first, the pseudo-diphtheria, or Hoffman bacillus, which occurs in non-diphtheritic throats, and second, the xerosis bacillus, which is a constant inhabitant of the conjunctiva. These two organisms have in common with the diphtheria bacillus a tendency to club-shape, and show certain peculiarities in staining. Some points of dissimilarity have been found in the morphology, the reaction to certain stains, in acid-production and in growth on various media, not entirely without contradiction, so that it is today generally accepted that these bacilli cannot always be distinguished morphologically or culturally, and the pathogenicity for animals has been the final means of differentiation.

Especially in the conjunctiva is a differentiation between the virulent diphtheria bacillus and the saprophytic xerosis bacillus important, owing to the varying severity of the diphtheretic infection in that organ.

Dr. Hiss, of the Bacteriological Laboratory of Columbia University, has succeeded in differentiating the pneumococcus and streptococcus, and recently the various organisms in dysentery and typhoid fever, by fermentation tests. The method in brief is as follows: A one per cent. solution of each of the following

sugars — dextrose, mannite, maltose, lactose, saccharose, and dextrin, is made in a medium composed of beef serum one part, distilled water three parts. Finally some litmus is added. It was found that the growth of certain organisms in some of these media was associated with a production of acid and a coagulation of the medium. As different sugars were affected by the various organisms a means of differentiation was furnished.

We tried this same method with the three members of the diphtheria group, and found that the diphtheria bacillus causes the medium containing dextrin to become red and coagulate, while saccharose is unchanged; the xerosis produces fermentation with acid production in saccharose, while dextrin remains unaffected, and, finally, the pseudo-diphtheria bacillus affects none of the sugars. We have thus a method of differentiation which has given constant results in an examination of 28 diphtheria, 10 xerosis, and 4 pseudo-diphtheria series. The method is very much simpler than animal experimentation and shorter, as the media begin to show fermentation changes in twenty-four to forty-eight hours.

The utility of this method was clearly pointed out during the past winter in a practical manner.

A child two years of age was brought to the dispensary, with the statement that the right eye had been red for two weeks; the child had been in perfect health. The eye presented the changes of a moderately severe conjunctivitis: the lids were red, there was some muco-purulent discharge, pseudo-membranes were present but were easily detached. There was a small corneal infiltrate. A culture was made. Under cold applications, frequent instillation of sublamin solution 1 : 3000, later silver nitrate, the eye recovered completely in ten days.

The culture proved suspicious, and a series of sugar media were inoculated, with the result that dextrin turned red and coagulated, just as in the case of the diphtheria bacillus. From the mild course of the conjunctivitis it seemed probable that the fermentation test in this case was wrong. We therefore gave a guinea pig a subcutaneous injection of the culture. The ani-

mal promptly died in thirty hours, and showed at autopsy the typical lesions of a diphtheritic infection. The little patient was kept under observation, but did not subsequently show any other manifestation of diphtheria.

Clinically mild membranous conjunctivitis, the so-called croupous conjunctivitis, associated with the virulent Loeffler's diphtheria bacillus, has been repeatedly observed. On the other hand, this case shows the importance of a bacteriological examination, and the aid which we think this fermentation test offers.

DISCUSSION.

DR. VERHOEFF. — I think this will be a very valuable method if we can be sure of its constancy, but in my experience the pseudo-diphtheria bacilli vary a great deal. It requires a large series of experiments to be certain about them. Some time ago, in conducting some experiments, using ten or twelve cultures of the pseudo-bacilli, I thought several times that I had a certain method of differentiation from the true diphtheria bacillus, but found later that it would work in only about one-half of the cultures. I think further experiments will be required to determine whether or not it would be safe to rely upon Dr. Knapp's method.

DR. B. ALEX. RANDALL.— At the Children's Hospital, three or four years ago, a case of croup, in which all cultures were negative, was operated upon at night for extreme stenosis of the larynx, and shortly after the child died. I was making some studies at the time of the contents of the tympanic cavities, and the cultures from this case were not reported upon for nearly a week. During that interval examinations had been made of other tissues, and again, as I now recall, with negative results. The night nurse, however, developed a typical throat; the nurse who had held the child's head at the time of operation developed a nasty conjunctivitis, quickly healing under treatment and again recurring; the surgeon, a near-sighted man, whose face had been very close to the field of operation, developed in about five days a mild conjunctivitis, with much lachrymation, but no trace of pseudo-membrane could be discovered, yet it persisted for several weeks and finally yielded only to injections of anti-diphtheritic serum, which was called for by the fact that the delayed report upon the tympanic exudate showed a virulent diphtheritic culture.

I believe we have these cases, like Dr. Knapp's, that are true diphtheria cases and are capable of being transmitted to others, and yet lack all clinical evidence of diphtheritic conjunctivitis. I believe that nothing but the anti-diphtheritic serum could have cleared up this case, and yet during the three weeks that the case was observed there was no trace of membrane recognizable under the lens.

DR. HIRAM WOODS. — I want to report, in line with Dr. Randall's remarks, an observation I made two or three years ago in my clinic at the Presbyterian Eye and Ear Hospital. A little girl was brought in, presenting on the conjunctiva of the left lower lid a thin, easily detachable pseudo-membrane, the underlying conjunctiva being soft, entirely free from plastic infiltration, and bleeding when the false membrane was removed. There were present all the clinical characteristics of classical croupous, as distinguished from diphtheritic conjunctivitis. The case was so presented to the students there at the time. This false membrane was, however, sent to Dr. Flexner, now of New York, and then at the Johns Hopkins Hospital, for examination. He reported the presence of the diphtheritic bacillus in pure culture. The child recovered with antitoxine treatment. A small area of the cornea was ulcerated when the case was first seen, but the trouble did not advance. I think we shall have to reconstruct our ideas of diphtheritic conjunctivitis in the light of the teaching of bacteriology. We must get rid of the belief that plastic infiltration is its essential feature.

A CASE OF MIND BLINDNESS, UNIQUE IN THAT THE ENTIRE MESIAL SURFACE OF BOTH OCCIPITAL LOBES AND BOTH OPTIC RADIATIONS WERE PRESERVED.

BY WARD A. HOLDEN, M.D.,

NEW YORK CITY.

I desire to place on record, in the shape of a preliminary report, the history of an individual who suffered from mind blindness, and a description of the gross anatomy of his brain, which presented the unique feature that the entire mesial surface of

both occipital lobes and both optic radiations were preserved. The case eventually will be described in detail after the investigation of the brain, which is now being done in the Pathological Institute of the New York State Hospitals, is completed.

W. S., a man of 53, was seen by me at the Long Island State Hospital for the Insane at Kings Park, October 19, 1902. His pupils were of medium size, and responded promptly to light, and his fundi were normal. He was, however, apparently unable to count fingers, and his eyes did not follow a light. Nevertheless he seemed to me to be visually aware of the presence of persons in the room, and although at first glance he impressed one as being blind, the ward attendants were sure that at times he saw, and his behavior differed from that of patients in the same ward blind of optic-nerve atrophy.

My frequent examinations revealed no changes in the pupils or fundi up to the time of his death, August 26, 1903, ten months later.

At this point I may say that the retinas and optic nerves have been examined microscopically, and are normal.

When I first saw the patient he was demented, aphasic, and extremely obstinate, so that extended psychical examinations could not be carried out, and hence we were largely dependent upon the records of hospitals in which he had been previously and upon the anamnesis furnished by his wife, an intelligent woman.

The chief points in his history are as follows: Eight years before his death he staggered one day while in the street, and after reaching home was found to be numb on one side and unable to speak intelligibly. The following day he seemed quite well again, and returned to his work — that of roasting coffee.

In March, 1902, seventeen months before his death, he came home one night feeling ill. On arising the next day he bumped into objects, apparently being blind. His mind was confused, and he was unable to speak intelligibly. He went to bed and remained there a week, after which he was able to get up, but his left arm and leg were very weak. He had become emotional and

depressed. He refused to take objects handed to him, or to feed himself, or to help himself in any way. He accused his wife of infidelity, and was ugly, refusing to answer her questions.

In June, 1902, with his wife he visited his mother-in-law. At her house improvement was noticed, and at times he talked rationally with his mother-in-law, whom he liked. Speech was difficult, and memory for recent events was very poor. He seemed to see, but he never tried to read. When he walked his wife always led him, because of his muscular weakness, and therefore it was difficult for her to judge of his powers of orientation.

At this time he had frequent visual hallucinations, believing, for example, that he saw men in the street when no one was there.

In July, 1902, he failed both physically and mentally, and then ceased to answer questions. On some days he bumped into objects, on others he seemed to see. He talked thickly, and, besides this, failed to recall the words he wished to use. He was fond of smoking, but now when he took his pipe in his hand he was unable to fill it or even to hold it properly, not knowing whether he was grasping the bowl or the stem (apraxia), and he puffed away contentedly when an empty pipe was placed in his mouth, provided that a match had been struck and held near it.

In the Kings Park Hospital he slowly wasted away, and died finally of enteritis. His wife frequently visited him, and up to the last she thought that on some days he saw, since he would answer correctly when she asked him if she had on her hat or gloves, or some question of that sort. On other days he refused to answer such questions, and on these days she believed him to be blind.

To sum up, this was a case of dementia after hemiplegia, together with aphasia, apraxia, and an interference with vision which much of the time amounted apparently to total blindness.

There are doubtless several forms of mind blindness. This case was apparently not of the commonest form, which has been

much studied in recent years, particularly by Liepmann. In the common form of blindness the patient unquestionably sees, but does not recognize what he sees. That is, perception takes place probably in the lower cortical visual centers about the calcarine fissures, but there is destruction or cutting-off of the higher centers of visual apperception, which lie presumably in and about the angular gyri. With this form of mind blindness there are as a rule hemianopic defects in the visual field, and frequently aphasia, and also astereognosis — the inability to recognize objects by the touch, or apraxia — the inability to handle objects recognized. The patients have arteriosclerosis, and occlusion of cerebral arteries, leading to softening in the occipital lobes, is the anatomical cause of the mind blindness. In the cases reported, so far as I can learn, there has always been found, besides other lesions, either destruction of the cortex near the calcarine fissure on the mesial surface of the occipital lobe, or destruction of the optic radiation. Yet there are cases on record in which there was bilateral destruction of the calcarine cortex without true mind blindness; hence it has been supposed that the cortical centers, whose destruction or cutting-off causes mind blindness, lie outside of the cuneus.

In this case the vessels of the brain exhibited many patches of sclerosis, and the parieto-temporal branch of each middle cerebral artery, which runs in the fissure of Sylvius, was occluded from the point where it was given off. This occlusion had caused softening in an extensive area in each hemisphere, including the angular and supramarginal gyri, and reaching back on each side nearly to the tip of the occipital lobe.

There was, however, no softening on the mesial surface of the occipital lobes, and in a frontal section 4.5 cm. anterior to the tips of the occipital lobes the softening of the cortex on each side was found to extend only to the upper margin of the tract of white matter whose lower portion is supposed to contain the optic fibres.

Thus this case differs from the ordinary case in that here calcarine cortex and optic radiations were preserved. Here the

primary visual pathway from retinas to calcarine fissures was normal. But softening of the angular gyri, and the parts adjacent, in which it is believed the higher visual centers lie, produced such disturbance of vision that it was a question much of the time whether the patient had any power of visual perception.

This case, then, shows that extreme disturbance of vision may be brought about by lesions in the higher cortical visual centers alone. The study of a few cases of this sort might doubtless lead to the discovery of the more exact location of the higher cortical visual centers in man, to which we ophthalmologists have, as yet, given little attention.

THE CORTICAL FUSION OF SOME COLOR SENSATIONS.

By CHARLES H. WILLIAMS, M.D.,
Boston, Mass.

In testing patients with an apparatus for measuring the muscle balance of the eyes, in which one eye looks through a red glass and gets a retinal image of a red line, and the other eye looks through a green glass and gets a retinal image of some green figures, it was noticed that when these lines and figures were at right angles with each other, as in testing for deviations in the horizontal or vertical meridians, no trouble was found in recognizing the two colors, but when the red line and the green figures were both shown in the vertical meridian, so that the colors overlapped and were focused on corresponding parts of the two retinæ, the patients were often unable to see the red line in this last position, although they had had no difficulty in seeing it in the other positions. A small apparatus was then constructed, in which two small incandescent lights were placed behind two discs carrying a number of colored glasses. The lights were the same distance apart as the interpupillary distance, and from the discs to the eyes the light came through two tubes three feet long, with

five blackened diaphragms inside the tubes to cut off the light reflected from the sides of the tubes. As one looked through these tubes with both eyes open, the tube opposite the right eye showed a red light and the other tube showed a green light. The area of these colored surfaces could be changed at will by a diaphragm, the colors could be varied by revolving the discs, and the intensity of the lights could be varied, either both together being made more or less intense, or one light could be kept constant and the other varied, by means of a resistance rheostat. It was found when a red and green of about the same saturation were thus shown, as soon as the two colored areas entirely overlapped, the red disappeared and the disc appeared as green slightly modified in shade. If the retinal image of one eye was diverted by a prism of three or more degrees to a part of the retina which did not correspond to that receiving the image in the other eye, the two colors were at once seen in their true tints, as red and green, but on withdrawing the prism as soon as the images again fell on corresponding parts of the retinæ in each eye, the red again disappeared. This effect could also be produced by a voluntary deviation of the eyes without any prism. In other words, as soon as there was a fusion in the cortical visual centres of the red and green sensations received from corresponding parts of the retina in each eye, the green seemed to predominate and the red disappeared. This effect persisted with varying degrees of intensity of illumination, and also when one eye received a constant amount of light and the intensity of the light for the other eye was varied. The effect was most marked when the colored area in the two eyes was about the same in size.

If the red light was reduced to a circle of 3 mm. in diameter, and the green remained as a disc of 16 mm. in diameter, as seen with the largest diaphragm, the red sensation seemed to persist, and was not drowned out by the green until the area of the red light was nearly half that of the green. When two discs of red and green colored paper were looked at with the stereoscope, so that one eye saw the red disc and the other eye the green disc, the usual well-known retinal rivalry appeared, and instead of a

fusion of the colors the disc appeared at one time red, at another green, the alternations becoming slower the longer the discs were looked at, and the green seeming to predominate. This change from red to green, and vice versa, was not a sudden one, but generally began at one side of the disc and spread across its surface like a drifting bank of fog. If the card on which the discs of red and green were pasted was arranged so as to turn on its horizontal axis, and on the back of the card two other discs of the same red and green were pasted, so that when the card was turned quickly about its axis while still in the stereoscope, a red disc would appear in the same place where a green one had been, and vice versa. The eye which had become fatigued by the red would then look at a green disc, the eye which had been fatigued by the green would then look at a red disc, and the colors would appear much brighter than before the card was turned, and the retinal rivalry would be more intense, the alternations in the color of the disc changing from red to green and green to red every second or two, then, as the eyes become accustomed to the new colors, the alternations become less frequent, the green seeming to be more persistent than the red. With other shades of red and green it is possible to get a *fusion* of the red and green instead of a rivalry. A darker shade will give a fused color, like an olive green, and without any apparent rivalry or alternations in the colors.

Dr. E. P. Holt has shown that two Canadian postage stamps, one cent dark green and three cent red, when fused with the stereoscope look like a dark gray, or even black. When four of these stamps were tried with the reversing card in the stereoscope, there was no effect of fatigue, and when reversed the color appeared to be a gray from the moment of reversal. In order to be sure that the sensation from both eyes was being noted at the same time, I pasted the green postage stamp on the left hand side of the stereoscopic card with the head upright, and the red stamp on the right hand side of the card with the head inverted. When these stamps were looked at with the stereoscope with both eyes open, two profiles of the head could be seen, one looking to the

left, the other to the right and inverted, thus showing that the brain was recognizing the sensations received from each eye, but at the same time was fusing the red and green colors, making the stamp appear as a dark gray.

Another experiment was then tried by placing a square of paper above and below each of the postage stamps. The pieces below the stamps were ruled with fine lines 1/64 of an inch apart with a ruling machine; on one piece green Higgins' drawing ink was used, and on the other the same in red ink. The pieces of paper above the postage stamps were washed with the same inks, to get a more solid distribution of the color, which was of course in each case mixed with a large percentage of white reflected from the paper. In the stereoscope the right eye saw a red stamp, with a green square over it and a striped green square under it, and vice versa for the other eye. When these images were fused with the stereoscope the stamp appeared dark gray, the striped square was also gray, and in some lights the solid square above the stamp was a gray; but in brighter illumination there was sometimes a faint rivalry, and alternation of red and green on this square of brighter color. If the eye receiving the green image from the upper solid green square was closed this square was at once seen as red with the other eye, but on again opening both eyes this square at once changed to green. If the eye receiving the red image was closed, and then both eyes were again opened, the color of the square did not change but remained all the time a green. Again, two very small incandescent electric lights, such as are used in a telephone switchboard, were looked at across the room at a distance of five meters, one light being covered with a green glass and the other with a red glass; the observer used a pair of spectacles one side having a green and the other a red glass, so that when he looked with his right eye he saw the red light only, and with his left eye the green light only. When the image of these two lights was formed on different parts of the two retinæ the true color of the lights, red and green, was recognized, but when the images were brought on corresponding parts of the two retinæ, by a prism, or

voluntary deviation of the eyes, the red disappeared and the green remained.

W. McDougall, in the summer number of *Brain,* for 1903, page 178, says: "We may observe in those tracts (retino-cerebral) an instance of alternating activity and inhibition of two related tracts affected by constant stimulation, and that this instance constitutes an extremely close analogy to the cases of alternating inhibition and excitation in spinal arcs. I mean the physiological processes that underly the struggle of two different colors presented to corresponding parts of the two retinæ. In a former paper I have adduced experimental evidence to show that the alternate inhibition and excitation of the two tracts, which occurs under these circumstances, depends upon a fatigue of the tracts, presumably of their synapses, which is rapidly produced and as rapidly recovered from." This may explain the retinal rivalry, but it does not seem to explain the fusion of the colors, like that of the red and green postage stamp, or the red and green colors from the glasses where the green seems to drown the red.

The practical application of this matter, so far as it relates to green and red signal lights, is that such lights should not be placed too near together, for there is always a chance, if such lights are too near together and are seen at a considerable distance, that the green may drown the red, and thus obscure a danger signal.

A CASE OF OPHTHALMOPLEGIA EXTERNA BILATERAL.

By WALTER EYRE LAMBERT, M.D.,
New York City.

The following case of this unusual disease, occurring during an attack of la grippe and resulting in complete recovery, seems worthy of being briefly reported:

The patient, a widow, fifty-five years of age, two children between thirty and thirty-five, excellent family history, syphilis

and alcoholism absolutely excluded, health fairly good, except that her digestion had been bad for some time, suffered with constipation and general gastro-intestinal disturbance. Has had several attacks of grippe. Had been confined to her room, most of the time in bed, for about ten days with such an attack, and under the constant care of her family physician.

After a very restless night, January 23d, having had severe attacks of coughing, she found next morning that her vision was very poor, and complained of headache and dizziness. The following day, Monday, January 25th, she was seen by me in consultation.

The patient, with whom I was well acquainted, presented a very strange appearance, and seemed in a very unusual state of mind, very drowsy and heavy, but as I knew that she had been taking some sedatives for the cough I thought at the time that this was possibly due to the effect of the drugs.

The ocular conditions were as follows:

With the exception of a very slight power of abduction in both eyes, there was absolute loss of mobility of the eyeballs, in other words, almost a complete ophthalmoplegia externa. There was incomplete ptosis of both eyes, slight exophthalmus, pupils of both eyes slightly dilated but reacting to light. Ophthalmoscopic examination showed normal fundus. There were no means at hand for testing her vision accurately at the time, but in a general way it seemed perfectly good in each eye. The next morning a more careful and extensive examination showed that the vision, with the correction for a small amount of hypermetropic astigmatism, was 20/20 plus in each eye. Near vision was also good with glasses correcting presbyopia. The slight power which had been in the external recti muscles on the previous day had entirely disappeared, so that both eyes were absolutely fixed and immobile. There was diplopia in all parts of the field.

In view of the severe attack of coughing, and that there was some arterial tension, and a possibility of some slight kidney affection, I at once suspected that she had had a hemorrhage

affecting the nuclei of the nerves involved. A consultation with Dr. Starr was suggested, and held the next day. He also at first thought that a hemorrhage had taken place, the location probably being in the raphé of the upper pons, causing destruction of the post-longitudinal bundles.

In a letter written to me the next day he modified this opinion by saying that it is also possible that it may be a case of polio-encephalitis superior of Wernicke. An examination of the urine was made, and only a very slight trace of albumen was found, so that disease of the kidneys was eliminated. The patient was kept in bed, and put on moderate doses of iodide with peptonoids. No change took place in the ocular condition for about two weeks, except that the diplopia had disappeared after a very few days. The general condition of the patient, however, gradually improved: the cramps in her lower extremities had disappeared and her ability to walk was very soon restored, and at the end of three weeks some mobility in the eyes was observed, external recti muscles first showing signs of restoration of power. Improvement after that was steady and fairly rapid, so that in about eight weeks' time the functions of the eye had been entirely restored, and at present the patient is perfectly well, with not the slightest trace of any paralysis.

As some cases of this sort have been reported occurring in attacks of grippe, and as both syphilis and alcohol can be excluded in the case here reported, it would seem that this one might be considered as due to a sub-acute polio-encephalitis, superior of Wernicke, and classed with the grippe cases.

DISCUSSION.

Dr. Samuel Theobald. — It might be of interest to mention in this connection a case I reported several years ago, of spastic convergent squint, the only case I ever recognized as of that nature. It followed an attack of influenza, in a little girl of twelve. There was a marked convergent squint, with movement, however, in the various directions. The point of interest was that it disappeared so rapidly and completely. No insuffi-

ciency was left. Small doses of iodid of potassium were given. I mention the case in this connection because it followed an attack of influenza.

A CASE OF SIMPLE GLAUCOMA WITH SOME UNUSUAL FEATURES.

BY WALTER EYRE LAMBERT, M.D.,
NEW YORK CITY.

In September, 1903, a patient, female, married, thirty-eight years of age, presented herself at the clinic and gave the following history:

As far back as she could remember her left eye had been turned in. Ten years ago she was operated upon, apparently a tenotomy of the internal rectus having been made. Immediately after the operation the left eye turned slightly out and decidedly up. She consulted another physician about four years ago, but no operation was suggested, merely a change in her glasses being made.



When I saw her in September there was slight divergence of the left eye, which was turned up to such a degree that the cornea was almost hidden by the upper lid. The vision of her right eye at that time was 20/20, with plus 5.D; vision of the left eye was 10/200 unimproved by the correction, the correction being plus 3 = plus 3, axis 155°. The ophthalmoscopic examination revealed in each eye a very deep excavation of both discs. In view of the fact that the excavation did not extend to the periphery of the disc, the vision normal in

the right eye, and furthermore that there was no history of there having been at any time any pain or redness of the eyes, or any disturbance in the vision, and also that this condition had been noted by the last physician who examined her four years ago, it was considered as a physiological excavation. As she was very anxious to have her eye straightened, I consented to operate, and did so on October 16, 1903, making an advancement of the internal rectus of the left eye and a tenotomy of the superior rectus of the same eye. The result was most satisfactory, and the patient much pleased. The error of refraction in both eyes was accurately corrected, the patient told to wear her glasses constantly, to practice with a stereoscope, and to cover up her good eye for some time every day, hoping thereby to restore some vision in the amblyopic eye.

A few weeks ago she returned, complaining that her vision with the right eye was getting very poor. I referred her to one of my assistants, thinking possibly some change in her glasses might be indicated. He reported, however, that he could not improve her vision beyond 20/40. I examined the patient shortly after that, which was about ten days ago, and to my surprise found that the excavation had extended to the periphery of the disc, and that the field was very much contracted, as seen by the chart. Vision reduced to 20/50; tension slightly raised in both eyes. The patient had no pain whatever, and had remarked nothing in fact about the eyes except the gradual failing vision. Pilocarpine was ordered, and an operation advised. A few days afterwards the patient came to the New York Eye and Ear Infirmary, and a broad iridectomy was made on Thursday, June 30, 1904. The eye healed without any complications, and when I saw the patient, on Thursday last, one week later, the tension was reduced to minus, vision 20/50 with a correcting glass, but the field had not improved.

It is to be regretted, in the first place, that the field was not taken six months ago, when I first saw the patient, and also that the patient did not return earlier after noticing this decided failure of vision, as without these data it is difficult to say how long the glaucoma had been going on, but it would seem to me

that the process had commenced at a very recent date and to have progressed quite rapidly. I received a communication from Dr. Webster, who saw the patient in February, 1901, in which he states that he had observed the excavations of both optic discs, but had considered them physiological.

DISCUSSION.

DR. P. A. CALLAN. — I saw the patient, and was very much interested in the case and in Dr. Webster's note. The physiological excavations should always be watched. I have done that for years. Often we do not like to take the trouble to do this, and the patient suffers in consequence.

DR. C. S. BULL. — I had supposed that every oculist examined the field of vision in patients with physiological excavations. I was taught to do so in Vienna, and supposed it was always done.

DR. LAMBERT. — I regret that it was an oversight on my part, that the field of vision was not examined, but my excuse is that the condition existed for a very long time. I turned the patient over to my assistant to investigate, and failed to insist that he make an examination of the field. The contraction of the field commenced quite recently, of that there can be but little doubt, for the patient is intelligent, and gives an accurate account of this gradual, progressive narrowing of her field of vision, and not so much the loss of acuity of vision.

DR. S. D. RISLEY. — Did you use the term physiological cupping facetiously — did you mean physiological cupping?

DR. BULL. — Yes, I invariably examine the field of vision in these cases, not that I always, by any means, find narrowing of the field.

DR. RISLEY. — I have sketches in my case books of large physiological cups by the hundred, and I have yet to see in any single patient (and many of them have been under observation for years) a development of glaucoma — I have yet to find the first one with contracted fields of vision. I make this remark because I think it is important that we should draw the line, not that I want to say that it is not important that the field should be taken, but I think there is a difference between the so-called funnel shaped cup and the cupping of the entire optic nerve, which we see in glaucoma accompanied by increase of tension. So that I do not feel like accepting the idea that these large physiological cuppings are pathological.

DR. C. S. BULL. — What Dr. Risley has just said illustrates the old axiom, that language was given us for the purpose of concealing our ideas. He has drawn an unwarrantable inference. I said that where I saw a cupping of the disk, which we have put down in our minds as physiological and not pathological, experience plus my instruction has taught me to examine the field with the perimeter in every such case, and in a certain number, by no means small, I have seen not only a narrowing of the field, which previously was normal, but have seen glaucoma develop.

DR. KIPP. — If you find narrowing of the field, it is not a physiological excavation.

DR. BULL. — At the time it was.

DR. RISLEY. — I do not think I misunderstood Dr. Bull at all. It ceases to be a physiological cupping when there is narrowing of the field of vision. I have repeatedly seen glaucoma where there was also a physiological cupping, but it is a distinct process.

DR. LAMBERT. — The point of special interest to me was whether eyes with the so-called physiological excavation were more prone to the development of glaucoma than other eyes. The patient presented this condition, and with undoubted development of glaucoma. I wanted to hear the ideas of some of the members on the subject.

PRISM EXERCISES — THEIR INDICATIONS AND TECHNIQUE.

BY ALEXANDER DUANE, M.D.,
NEW YORK CITY.

In offering these remarks on prism exercises I intend simply to give a few conclusions that I have reached as a result of my own experience. These conclusions, it must be added, I regard as tentative only. Premising this, I will state first the methods that I have been led to adopt in making prism exercises, and second, the indications that, in my experience, such exercises may be expected to fulfill.

METHODS EMPLOYED.

I regularly employ four exercises:

Exercise A. Distance exercise with prisms, base out. — The patient looks at an object — either a small light or the bull's-eye

of a one-foot target — on the other side of the room, and holds a square prism of, say 10°, base out, before the left eye. The moment he unites the double images produced by the prism he drops the latter and puts up a stronger prism, say one of 15°, before the right eye. This in turn he drops as soon as the double images are united, and substitutes for it a prism of 20°, held base out before the left eye. When he can overcome the 20° readily, he tries in succession the following combination:

15° before one eye and 10° before the other, producing an absolute converging effect of 13.5° of arc.

20° before one eye and 10° before the other, producing an effect of 16.5°.

20° before one eye and 15° before the other, producing an effect of 19.5°.

20° before one eye and 15°+10° before the other, producing an effect of 25°.

20°+15°+10° before one eye, producing an effect of 29°.

A progressive increase in the effect may be produced not only in the way above indicated, *i. e.*, by using different combinations of two or three prisms, but also by using a single prism and *rotating* it on a vertical axis either forward or back. The deflecting power of a prism can be almost doubled in this way, and, moreover, can be increased gradually, so that with two or three prisms thus rotated all degrees of deflection may be produced from 5° to 50° of arc.

If with any given combination the diplopia cannot at once be overcome, resort may be had to Gould's expedient of approximating the test-object until seen single, and then gradually carrying it off to the proper distance, the patient all the time keeping his eyes on it and endeavoring to maintain fusion. Or, the same thing may be effected if, as suggested by Stevens, the patient looks through the prism at a finger held close to his nose, and keeps his eyes fixed sharply on the finger as it is slowly carried out toward the distant object.

Exercise B. Exercise with prisms, base out, at near points. — Exercise at near points with prisms, base out, is done in the same

way as for distance, except that the test-object is either a minute electric light or a fine dot[1] in the center of a circular card five inches in diameter. The card is held at the reading distance, and is shifted back and forth, special efforts being made to maintain fusion while the card is being carried *toward* the eyes.

Exercise C. Exercise at near points with prisms, base in. — As is well known, the ability to overcome prisms, base in, when the eyes are directed at a distant object, cannot usually be increased by practice. This does not hold, however, for such prisms when used at near points.

The test-object here is the same as that used in Exercise B, *i. e.,* is either a minute electric light or a dot on a card. The patient, holding a 12° or 15° prism before either eye, brings the object up toward him until it appears single, then carries it steadily off until he can no longer fuse the double images. This is done three or four times in succession, the attempt always being made to carry the object as far off as possible and still maintain fusion.

Exercise D. Exercise in converging on a pencil. — This consists simply in carrying a pencil (or in amblyopic patients a minute electric light) from arm's-length in toward the nose until the object appears double. This is repeated three or four times, the attempt always being to bring the object closer than before and still maintain fusion, — in other words, to approximate the convergence near-point.

PRECAUTIONS TO BE OBSERVED IN DOING THE EXERCISES.

1. The *test-object* should be well defined and not such as to be confused with its surroundings. It should be just large enough for the patient to see distinctly at the distance employed, and yet so small that he has to fix sharply in order thus to see it.

2. The patient should wear the *glass correcting his refractive error* when doing the exercises, and, if presbyopic, he ought to wear his reading-glasses when doing Exercises B, C, and D.

[1] If there is hyperphoria, the dot may conveniently be replaced by a short vertical line.

3. Attention should be paid to the *effect of the exercises on the accommodation.* The use of prisms, base out, tends to cause a spasm of accommodation, the amount of which can be inferred from the degree of blurring of sight produced when the patient looks through the prisms at a test-card, and from the strength of the concave glass that is required to clear his vision.

In some cases possibly this spasm of accommodation may keep up for a long time after each practice, and may even be permanent. In most cases it should be possible to obviate any such tendency to undue spasm by using diverging exercises (Exercise C) directly after Exercises A and B. If this does not suffice, or if for any reason it seems improper to use Exercise C, the desired relaxation of the accommodation can be effected by using the test-types as an object of fixation when doing Exercise A. The patient, looking at the letters through the prisms, gradually learns to relax his accommodation, so that his vision slowly clears from 20/200 to perhaps 20/40, or better, even while he is still maintaining the convergence that the prisms impose. With Exercise B (prism-convergence at near points) a similar relaxation of the accommodation can be effected by adding a +2 or +3 D to the patient's distance glass, and with Exercise D (convergence on a pencil) by adding a +10D. This seems to be rarely necessary.

USES OF PRISM EXERCISES.

The uses of prism exercises, I think, may be stated as follows:

I. *To rectify muscular anomalies.* — Prism exercises often relieve a muscular anomaly either because they actually reduce its amount or, perhaps more frequently, because they give the patient ability to overcome the anomaly with greater ease, so that he can readily maintain binocular fixation in spite of it.

1. *Exophoria.* — In this condition I use all four exercises, A, B, C, and D, combining and varying them according to the variety of exophoria present.

Thus in a pure *convergence-insufficiency,* marked by considerable exophoria for near, with recession of the convergence near-point, but with little or no exophoria for distance and a

prism-divergence of not over 8°, I restrict or altogether dispense with exercise with prisms at a distance (Exercise A), but push the convergence exercises at near-points (Exercises B and D). At the same time it is often necessary, particularly if the diverging power is low (less than 5°) to add diverging exercises (Exercise C) and even push them, in case observation shows that the convergence practice is causing an homonymous diplopia for distance or is producing a spasm of accommodation. In these cases we have to watch closely the results of the practice, and push sometimes one exercise, sometimes the other, as the occasion seems to demand.

On the other hand, in a *divergence-excess,* characterized by marked exophoria for distance with a prism-divergence of 10° or considerably more, we should push the distance practice with converging prisms (Exercise A). If, as is often the case in this variety of exophoria, there is little deviation for near, and the convergence near-point is about normal, we would restrict or even altogether dispense with convergence exercises at near (Exercises B and D). Exercise C (practice with prisms, base in) would here be obviously improper.

In cases of *combined divergence-excess and convergence insufficiency,* with marked exophoria for both distance and near, we would use all four exercises, varying them according as one or the other element (divergence-excess, convergence-insufficiency) predominates.

Each case has to be judged by itself, and the amount of exercise prescribed determined by the patient's ability and endurance. As a rule, I have the patient practice at home either three or four times a day, for three or four minutes at a time, each practice consisting of Exercises A, B, C, and D, done in succession, and in the order given, and very precise directions being laid down as to the amount of work to be done in each exercise. These directions have to be modified from time to time, as the muscular condition changes. Hence, I re-examine the patients once or twice a week, determining the amount of deviation for distance and near and the converging and diverging power, and from these

data judge how the case is progressing and how the exercise should be varied.

At no time should any exercise be pushed to the point where it produces more than slight or temporary fatigue.

As a general thing, I think convergence exercises do very little good, unless the patient works up to a prism-convergence of at least 50° for distance and near and reduces his convergence near-point to less than two inches. This he can usually do in two or three weeks.

2. *Esophoria.* — Here the use of diverging prisms at near points (Exercise C) is indicated. This is done some four times a day for a few minutes at a time. I have thought this exercise especially useful in cases of *convergence-excess,* and particularly in the temporary esophoria produced in myopes who for the first time are wearing concave glasses for near. Theoretically, it should also help in divergence-insufficiency, or the condition characterized by marked esophoria for distance, with low or negative diverging power and with little or no esophoria for near. I have not had enough experience with it in these cases to vouch for its efficacy.

II. *To modify the effect of operations.* — The effect of a tenotomy can be very considerably modified by prism-exercises, particularly if these are initiated during the first few days after the operation.

Here considerable care has to be observed, for it is quite possible to produce an unpleasant over-effect by excessive exercise. The exercise in this case, at least during the first week or two, ought to be conducted mainly by the surgeon himself, being altered from day to day, and one exercise being balanced against the other as the case demands.

I am sure that I have prevented the development of a divergence after tenotomy of the interni, by exercise with prisms, base out, and the development of an undue convergence after tenotomy of the externi, by exercise with prisms, base in, and in other cases still have secured closer approximation to an ideal result by means of prism-exercise.

III. *To modify accommodative states.* — Exercise with prisms, base out, may be used to stimulate a subnormal accomodation, and exercise with prisms, base in, to relieve a spasm of accommodation. These exercises, particularly the latter, constitute, I believe, a very useful application of prisms.

THE PATHOLOGIC RESULTS OF DEXTROCULARITY AND SINISTROCULARITY.

By GEORGE M. GOULD, M.D.,
PHILADELPHIA, PENN.

A little observation and a few tests will show with some exceptions, to be noted later, the right-handed or dextromanual person is also right-eyed, or dextrocular, and the left-handed is left-eyed. That is to say, there is, in the dextromanual, the same habitual and unconscious choice of the image of the right eye for the more expert and important tasks, just as the right hand is chosen for those functions in skilled work. A dextromanual hunter places his gun against the right shoulder because he can sight it with the right better than the left eye. The right-handed person, in playing the violin, violoncello, etc., is forced to use the left hand for the more expert task, because he thus sees the fingers and the neck of the instrument without foreshortening and better than he could if the fingering were done with the right hand. All actions, in fact, are determined by the fundamental necessity that accurate vision shall precede all action, and vision is more accurate with the habitually exercised eye just as manual function is more expert and reliable with the hand most exercised in a special kind of work.

A little closer observation soon demonstrates that not only is the dextromanual also dextrocular but that he is likewise right-footed, and usually right-eared; he is dextropedal, and dextro-aural. This is equivalent to saying that a person is either dextral, generally, as to ear, eye, hand, and foot, or else he is sinistral. There must manifestly be a unity in the coördinations of all acts,

and such coördinations would evidently be better if there was a habitual one-sided similarity of execution running through all kinds of action, so that there would be no indecision in rapid and dangerous acts. The unity and the resultant promptness and accuracy of all motions is thus enhanced by a synchronous dextrality or sinistrality. The mixed type, illustrated by the so-called ambidextrous, would place the organism at a wretched disadvantage in the struggle for existence, and in the social struggle of the highest types of human life.

The underlying and long forerunning cause, however, of the coördination of dextral acts, or of sinistral ones, lies in the necessity of the localization of the organ of speech in one or in the other side of the cerebrum. As it is a single and not a dual function its organ can be only in one place. Pathology has proved what physiology pointed out, that in the dextral the speech-center is in the left side of the brain, and in the sinistral it is on the right side. Moreover, the intellectual act of writing develops the speech center on the side opposite to the writing hand. The history of cases with tumors and paralyses has settled this question beyond controversy.

The speech center may be looked upon as the organ through which intellectual judgment and decision issues in determination and act. The spoken and written word is the most intimate act of the mind, its irrevocable and immediate exponent. Prior to all judgment and decision vision must give the data. Intellect is in fact the product of vision, and all mental symbols, the letters of the alphabet themselves, are but modified visual images. The thing seen is thus worked into judgment, and by the third component of human action, motion, is wrought into completed function. Vision, judgment, act, are thus the unexceptional conditions of human activity and validity. It is at once plain that if the centers which intermediate these three functions are upon one side of the brain, in contiguity, and closely united by many intercentral fibres, the resultant act will be more accurate and rapid than if one or two of the centers are in the opposite side of the brain. The commissural fibers between the two cerebral hemispheres would be

fewer and longer, and the coördination less clear, sharp, and certain. This is the neurologic basis for a common dextrality, or a common sinistrality, of function in one individual, and it completely demolishes the foolish contention of those who would vainly educate the two per cent. of left-handed children to be ambidextrous. There never was an ambidextrous person, but there has been produced much misery by the foolish attempt to create ambidexterity. A paper on the general subject of dextrality and sinistrality will soon appear in the *Popular Science Monthly.*

If by ocular disease, ametropia, accident, etc., the dextromanual are compelled to sinistrocular, the pathologic results which may flow from this interference, or reversal, of the natural order becomes of exceptional interest to the ophthalmologist. That these pathologic results exist I have no doubt, and have repeatedly demonstrated in the persons of actual patients. I suspect that they exist in at least ten per cent. of all patients, and no case whatever can be treated wholly irrespective of the fact of dextrocular, or sinistrocular, function.

For purposes of naming and clarifying the ideas to be presented, let us call the right eye of right-handed persons and the left eye of left-handed persons the dominant eye. The caution must be emphasized that the hand which does the writing unconsciously or preferentially dictates the location of the speech-center, and the true condition of dextromanuality or sinistromanuality.

It hardly needs the saying that the accidents of ocular diseases, keratitis, fundus lesions, cataract, high ametropia, heterophoria, amblyopia, etc., may put out of function, or threaten to do so, the primary, that is, the naturally, logically, and neurologically, dominant eye, and thus the eye of the other side must be used as a makeshift and educated to become the secondarily dominant one. The older the age at which this occurs the greater the difficulty, the more of a tragedy will it be to the patient. There arise a hundred problems. I shall here allude, and most briefly, to but a few of these:

1. In all operative procedures there should be an exceptional striving to save the dominant eye. I do not believe in operations for this purpose, but if only one eye can be straightened and made functional in strabismus, by all odds let it be the dominant one. The strabismus of a naturally dominant eye will be more easily cured than that of the non-dominant one. In double convergent squint the dominant eye should be the one first chosen to save.

2. In inflammatory diseases there should be the same solicitude, when choice, as frequently, is possible, to preserve the best function in the dominant eye.

3. The supreme value of the dominant eye makes it highly important that ametropia shall be corrected at the earliest day and year possible. Every month that amblyopia, heterophoria, or strabismus increases in that eye makes the life history and struggle of that child a different and a more difficult one. Dextromanuality, or its opposite, is pronounced in children of less than a year, and the location of the speech center is being fixed rapidly, and often unchangeably at two and three years of age.

4. If saving of the naturally dominant eye is impossible in the young child, and its fellow must be secondarily educated into dominancy, it becomes a question if the child should not also be taught to write, eat, etc., with the corresponding hand.

5. In the adult the dominant eye, I have found, will preserve its dominancy despite a considerably higher degree of amblyopia, ametropia, etc., than that of its fellow. But it is evident that there must be a limit. I doubt if the naturally dominant eye would retain its dominancy if it had, say, an acuteness of only 20/50, while the vision of the other was normal. This fact arouses a number of queries in the mind of the refractionist. One of these would refer to the inadvisability of giving the non-dominant eye a greatly superior acuteness of vision by means of glasses. In an adult such a sudden change, even reversal, in the habits of a lifetime might be brought about that the spectacles would not be tolerated, and failures of varied kinds ensue. The

patient would then have a life handicap that would greatly lessen his personal validity and happiness.

6. An axis of astigmatism in the dominant eye from 10° to 20° to either side of 90° or 180°, while the axis in the fellow eye remains normal or unsymmetric, produces head-tilting; symmetric axes produce no head-tilting. In the few months after I discovered this law I found in the ordinary run of office practice over thirty cases of head-tilting. The stupid error I had made all my life was to allow these patients to cant the head during the refraction testing. In this way I had failed to find how large is the number of right-handed patients who have the axis of astigmatism of the right eye from 10° to 20° to one side of 90° or 180°. And never before this had I thought of the necessity of inquiring as to dextromanuality in patients having these slightly unsymmetric axes of astigmatism. It is evident that an axis in the dominant eye only 5° to one side of 90° or 180° would hardly produce a noticeable tilt of the head, or might possibly be compensated for by the rotation of the eyeball itself. It is possible that some types of heterophoria, and especially cyclophoria, may be explained as arising from this compensation of the ocular structures instead of producing the tilt or cant of the head. It also seems to me possible that this compensatory twist of the eyeball in the orbit may possibly cause a compensatory twist of the optic nerve, and perhaps certain other diseases of the papilla and retina. After prescription of proper correcting glasses it would be natural to find before long a secondary change of axis resulting from the rectification of the abnormal head-tilt, or ocular twist. Such patients must be kept under continuous and repeated observation.

If the axis of astigmatism of the dominant eye is about 75° or 165°, it is evident that, if the non-dominant eye is unsymmetric, the head must be tilted to the right in order to bring the false axis into line with the vertical lines of print, trees, houses, wall paper, doors, etc.

If the axis of astigmatism of the dominant eye is about 105° or 15°, compensatory tilt of the head must be to the left. Greater

variations of the axis than 20° would hardly be compensated for by head-tilting, but would either produce amblyopia, a transfer of dominancy to the other eye, or else some other pathologic consequence equally harmful to action and life. The axis of the largest number of head-tilters is 75° in the right eye, and thus the majority tilt the head to the right.

7. Among the thirty or more head-tilters I have found, in the few months mentioned, about a dozen with resultant scoliosis. The fact was usually unsuspected by the patient, the parent, and the attending general physician. I sometimes had difficulty in getting consent that an expert orthopedic surgeon should verify the diagnosis. A report of these cases, the nature of the compensatory spinal curvature, and the cure by glasses alone, or by glasses and orthopedic help, will be published later. It is needless to add that the method of production of scoliosis resulting from an enforced and habitual abnormal position of the head is well understood by orthopedic surgeons. Habitual carrying forward, for instance, of the hearing ear in case of unilateral deafness will result in scoliosis. There are undoubtedly thousands of scoliotic children in the United States whose spinal malcurvation is due to a slightly aberrant axis of astigmatism.

8. An ametropia in the non-dominant eye which tends to throw it out of function is much more likely to result in malfunction, non-function, and disease of that eye, than would be the case in the dominant eye. Many practical suggestions and rules result from this fact, both in refraction work and in the management of inflammatory diseases. In amblyopiatrics, for instance, it is perhaps as well not to strive to give the non-dominant eye an exceptional or even an equal acuteness of vision. Nature will not respond to the attempt so willingly as in a similar attempt with the dominant eye.

9. The failure to diagnose the unsymmetric variation of axis of the dominant eye will of course result in the non-cure of the reflexes, which are caused by eye-strain. This is so well established that it may serve as a reason for re-examination of the cases in which in the past there has not been perfect relief of

patients with general ill-health, migraine, dyspepsia, headache, neurasthenia, insomnia, melancholy, etc., probably due to eye-strain. Not seldom the change of axis, found to exist when the refraction test is made with the head accurately erect, will at once bring astonishing and brilliant relief of many forms of inveterate systemic functional disease.*

POSTSCRIPT.

After the foregoing paper had been read at Atlantic City Dr. Peter N. Callan said to me that the suggestion of right-eyedness had also come to him, and he had asked the question in the *Medical Record* of April 2, 1881. Confirmation of the fact had been found in the examination of the records of more than 1,000 of the private patients of Dr. H. D. Noyes, in whom each eye had been carefully examined and the vision and refraction noted. The general results were that when myopia existed there was a higher degree in the right than in the left eye, and when hyperopia was present there was a less degree in the right than in the left. In the hyperopic cases the vision was more acute in the right than in the left, and in the myopic the vision was almost the same in each eye, taking all degrees into consideration. Dr. Callan drew the conclusion "that with binocular vision we use one eye more than its fellow — that one being generally the right eye." This quick confirmation of the theory of dextrocularity was unexpected, and suggests a number of valuable and practical rules in refraction-work, in the case of the eyes of school children, students, etc.

There are indirectly further proofs of the theory to be found in the ingenious and instructive paper of Dr. Wheelock Rider on

* A corollary of the discovery of the cause of so many cases of tilted heads is suggested. Besides the thousand vertical and horizontal objects that demand relief of astigmatism, or its placing at axes 90° or 180°, the predominant cause in civilization is the shape of the letters of the printed page. As a rule these are made up chiefly of lines at axis 90° supplemented by a few at 180°, and a less number of curves and of oblique axes, at about 60° or 70°, or, conversely, at 120° or 110°. It is these last which should be eliminated when it is possible, and in all but a few letters this is possible, the exceptions, (K, V, X, Z) being relatively unimportant. The lower case of small letters could be modified in shape to correspond to these. The lesson as to vertical and slanted handwriting at school is equally plain.

"Unilateral Winking," published in *Transactions of the American Ophthalmological Society,* 1898, to which my attention was kindly directed by the author in the discussion of my paper, and which had also escaped my notice.

DISCUSSION.

DR. WALTER L. PYLE. — I feel somewhat embarrassed to steal Dr. Gould's thunder, but I have been in conference on this subject with him many months, and think that many points should be brought out that he has omitted in his paper. It is marvelous the way these examples can be multiplied. Carrying the gun to the right shoulder and playing the violin are most striking, but there are many others; the engineer, who sits so that he can use his right eye for watching, with his weaker left hand on the throttle, for instance. In gross work the difficult part is done with the left hand; in chopping, for instance, the right hand simply guides the blow. As to the inconvenience of ambidexterity I know of a naturally left-handed man who was compelled to use his right hand by his early teachers and who complains of being unable to think when he writes, so that he has to do all his literary work by dictation.

As to head-tilting, Dr. Gould's first case was very striking. He spoke to me of a girl several months ago, who came into his office with wry-neck and evident spinal curvature, whom he refracted. She was sent to a physical culturist, and taught to stand erect. On her return, notwithstanding her improved health, she said, "when I stand straight, Doctor, I can not see through my glasses." Immediately after the proper oblique axis of the cylinder was prescribed vision with the head erect was perfect. We make a mistake if we allow patients to cant the head in testing the eyes. I recently sent for a half-dozen cases that in my earlier days I had failed to correct satisfactorily, and these I refracted again. In three the oblique axis was 75, where I had put it at 90 with the head tilted. The association of ocular deformity with spinal curvature is not new, but it has usually been attributed to muscular anomaly, no attention being paid to the axis of the astigmatism as a factor. The treatment advised was tenotomy, or prisms, and these nearly always failed to give relief.

In regard to the pernicious effect of small amounts of hypermetropia brought out today, it is my opinion they are not of such consequence in producing asthenopia as are similar amounts of astigmatism, particularly when at oblique axes.

DR. W. E. LAMBERT. — I wish to disagree decidedly with the illustrations brought out and applied by Dr. Gould: saying that because a man takes his gun up to the right shoulder he must be dextrocular. It is because he uses his right hand to pull the trigger. And, as to the violin playing, it is more important to have the right hand manipulate the bow than the strings of the instrument. As to passing to the right on the road, it is only in this country that it is done; in Europe they pass to the left. I do not think the illustrations are at all good.

DR. PERCY FRIDENBERG. — The idea of Dr. Gould's is interesting, if true. Some ethnologists tell us that the original favoring of the right side is due entirely to the position of the heart. The greatest vascular supply is to the left side, and there is early development of the brain on that side, while the development of the right side was due to the importance in early times of protecting the heart with the shield on the left arm and using the right arm for fighting. I think the objection Dr. Lambert has just stated may be applied to other examples. The violinist does not look with the right eye at the strings, good players look away from the instrument when they play. The 'cellist holds the instrument about an equal distance from both maculae. I think the idea of associating dominance of one eye in this manner is certainly open to objection. If the normal being has equal vision in both eyes I can hardly see how such dominance can be established. The fact of the case is that the majority are unable to distinguish which eye is concerned in vision, and many tests of simulation are based upon that fact. One eye is only dominant when the other is defective. To carry this theory further and say that we should avoid straightening a non-dominant eye it seems to me would be a mistake.

DR. P. A. CALLAN. — I am fully in accord with Dr. Gould as to the question of a dominant eye, but presume the doctor knows it is not original with him, but that the idea is a generation old. I think La Compte, in the International Scientific Series, thirty years ago, published a book on vision, giving a good many of these examples.

As to ambidexterity, I think every surgeon should educate his left hand to use the knife and scissors. It is a great handicap for a young man to be able to use only one hand in surgical work, and if he starts out early he can accomplish a great deal by using his left hand. In that respect I think the deductions of Dr. Gould are

wrong. I use my influence at every opportunity to persuade young men to develop the use of the left hand so that they can use the Graefe knife, or the scissors, in that hand if necessary.

DR. LUCIEN HOWE. — I think we would all be interested in this summary which Dr. Gould makes, to have at least a digest of the data from which the conclusions are drawn. The latter are very interesting, but are based upon observations which we must look for elsewhere. We would like to hear the data, and have the figures a little more exactly.

I wish to say that the subject is gone into thoroughly by Grant Allen, in a chapter on right and left handedness. It is in a little book entitled " Falling in Love, and Other Essays on the More Exact Sciences." The subject of ambidextrousness interests us, though we have all seen surgeons who were ambisinistrous.

DR. C. H. WILLIAMS. — I would like to mention one case in this connection: A friend of mine, a distinguished surgeon, is right-handed, and is also a very enthusiastic sportsman. For many years he could not understand why he missed so many of his birds when shooting. He finally found that he was putting his gun to his right shoulder and sighting with his left eye. He was right-handed, but left-eyed.

DR. WHEELOCK RIDER. — Dr. Gould's paper is along lines that have occupied my time and attention for many years. Some of the results of this study may be found in the transactions of this society for 1898, and I have since collected a much larger number of observations for further investigation.

An English ophthalmic surgeon, whose paper I have never seen, called attention, I believe, some years ago, to the subject of the " master " eye, and it is not only easily demonstrated but highly important to remember that in most individuals the right or left is the " dominant " or " fixing " eye, and that much that passes for binocular vision is in reality monocular vision.

The " winking-test " roughly determines, among other things, which is the better eye — the one probably dominating over its fellow in binocular vision, so called. The influence of dexterity in the selection of this eye, when even slight visual conditions alone have not already determined the matter, is, I believe, much less than the reader of the paper assumes. Right-handed persons are surely not, *ipse facto,* right-eyed. In many hundreds of

persons examined on this point not much more than 10 per cent. seem to be influenced by their right-handedness.

With regard to the violin, the manner of holding which the reader instanced as an example of the right-eyed tendency, I feel somewhat competent to speak from long personal experience with its use, my practice beginning in my seventh year. The violin, like all instruments of the viol class, is a right-handed instrument. In the early forms the fingering (executed with the left hand) was very simple, especially as the fingerboard was frequently fretted. The strings were struck with the fingers of the more skilled right hand, or with a plectrum held by them. The guitar of today well represents this archaic form. Today the training of the right fingers, right wrist, and right elbow — the bowing — makes the violinist. No violinist is better than his right wrist.

The gun is likewise a right-handed implement — the pistol surely, and just as surely the older forms of the musket, mechanically supported at the end of the barrel. The right index and middle finger are under better and quicker control, and the better trained right arm and shoulder bear the brunt of aiming and firing. Men very commonly shoot right-handed with a defective right eye, which would otherwise never be employed for sighting, but when the defect is marked they are forced to reverse the position.

Having determined that the unconsciously-acquired and very fixed habits of lid closure are chiefly due to differences of visual acuity (or effort) we are prepared to investigate other unconsciously-acquired muscular habits, such as clasping the hands, washing the hands, folding the hands and arms, chopping, spading, and shoveling, turning the head to look over the shoulder, kicking, jumping, sliding on ice, even smiling, and many others. Most of these habits are formed in early life, and are so fixed and numerous that they might serve as the foundation of a system of identification, just as do anatomical peculiarities. They are by no means the same in all right-handed persons, but are found in different individuals in all possible combinations and probably will be shown to be, while partly correlated, chiefly dependent upon general functional and anatomical peculiarities of the parts, as is lid closure, and not upon the particular functional peculiarity of right-handedness.

Carrying owls to Athens — suggesting terminology to a lexicographer — I would propose in place of the Latin terms "dextrocularity" and "sinistrocularity" that, for the sake of

obvious uniformity, the Greek equivalents be substituted: "dexiopia" and "aristeropia."

DR. MYLES STANDISH. — Some ten or twelve years ago two gentlemen, writing in collaboration, published a paper in the *Ophthalmic Review* or the *Royal Ophthalmological Hospital Reports* on this subject, right or left oculation. I found the subject interesting, and from that on to the present time all of my refraction cases have been tested as to whether they were right or left eyed. I am positive that the relation is real. I have tested people a number of times, and they have always selected the same eye. As to the theories of right and left handedness I will not speak. Every man regulates his following eye by the fixing one, if it is possible. If he has an error of refraction, which he can correct in the following eye, he corrects it through the standard of his fixing eye. If that fact is borne in mind many faults in glasses will be easily discovered; you must remember that the man is looking with one eye and trying to accommodate the other eye to it. Another thing: if any of you ever order prisms to correct a difficulty, in glasses that are habitually used, if you put the greater part of your correction before the following eye and the minor portion before the fixing eye you will find them much more readily used and longer worn with comfort than if you split it and put half before each eye; or in some cases if you put all your prism correction before the following eye you will do better still. I have not taken the matter up as a fad, but have followed it ten years habitually in every single case and have kept records of all my private cases. It is not a subject to be laughed out of court.

DR. ALLEMAN. — I have been in the habit of testing for the dominant eye for some time, and of being guided in operating by my findings in that respect. I have an example in a patient upon whom I operated some time ago for cataract. I operated on one eye, and he had normal vision with his correction, but when looking at anything quickly he looked with the bad eye, which had been the dominant one, and could not see. If he had time to select the corrected eye he could see all right, but was subject to all sorts of annoyance by using quickly the dominant eye.

DR. VERHOEFF. — I think the first one to bring out this conception of the dominant eye, or, as he called it, the directing eye, was Javal, who used it in his theory of stereoscopic vision. I think

it can be easily shown that in true bionocular vision, that is, in stereoscopic vision, where both eyes are being used, that one eye has not a predominance over the other. The question of a directing eye comes up only under certain conditions, where one eye is selected and the image in the other suppressed, that is, where we revert to monocular vision. Here, in my experience, where there is any great difference between the eyes, it has always been the poorer eye which gives way, as would be expected. Where the difference between the eyes is comparatively slight, the person is right-eyed or left-eyed accordingly as he is right-handed or left-handed, as would also be expected. I think the problem is a little different from what it is generally regarded. It is usually thought that the directing eye does about all the work, and that the other does almost nothing. It is easy to show that this is not the case, but that each eye does its full share. It is only when both eyes can not be used that one is selected, as in using the microscope.

DR. GOULD. — A word in reference to the thought that has been expressed as regards the first publication or notice of the idea of a dominant eye. I myself have never seen any, and I have looked through the literature pretty thoroughly. I shall be glad if any member will point out to me any reference to the matter. One gentleman has vaguely referred to such publication, but I wish he could give it more definitely, as I should have given credit to the proper authority had I been able to find it. It was certainly original with me, but I shall be glad to know if any one has preceded me.

In reference to the proof of which eye is the dominant one, there is a very simple test. I left out all the detail which has been discussed because it is to appear in the *Popular Science Monthly* for August. Ask a patient, touching anything, to go up and sight across a table or anything of that kind and see with which eye he sights. Or, ask a patient to take up a stick and sight with it: if he closes the left eye he is right-eyed, if he takes it up in this manner I know he is left-eyed.

As to violin-playing, I think the gentlemen are mistaken. They fail to recognize that the instrument could have been strung the other way had it not been for the fact that it was recognized that this would not allow the learner to watch the fingers manipulate the strings, because there would be poor vision because of foreshortening. The piano of course is a right-handed instrument,

because the right hand plays the more difficult part, while with the violin it is the left hand that does the more expert work.

I wish to enter a protest against the misreporting of what a man says. I never said, nor implied, that the non-dominant eye should be let alone, or not surgically treated. I never even implied it.

One of the most striking examples is a patient of mine in Camden, who is left-handed for everything, but who shoots the gun from his right shoulder, but he gets highly curved gun-stocks, and sights with the left eye, depressing the right below the level of the barrel. Another patient of mine in Philadelphia does the same thing. The instance Dr. Williams has given us is also a demonstration of this kind.

I did not know Le Conte had ever spoken of this theory, or of anything like it. You will find that there is a great deal of truth, most practical truth, in this idea. I beg you not to think that it is merely a theoretical fad.

THE MUSCLE OF HORNER AND ITS RELATION TO THE RETRACTION OF THE CARUNCLE AFTER TENOTOMY OF THE INTERNAL RECTUS.

By LUCIEN HOWE, M.D.,

BUFFALO, N. Y.

It is usually supposed that this muscle was described first by an eminent Swiss ophthalmologist of that name. But such is not the case. It was discovered by Prof. W. E. Horner, adjunct professor in the University of Pennsylvania, and described by him in a quaint chapter in the *Philadelphia Journal of the Medical and Physical Sciences,* 1824, page 70.

In order to demonstrate its position, he made an elliptical incision following the fibers of the orbicularis muscle around the upper and lower lids near the margin of the orbit except toward the inner canthus, and then deepening this incision until it passed entirely through lids, cartilage, and conjunctiva, he reflected the lid over the nose. In this way, when the dissection is completed, it is possible to see the faint outline of a muscle,which, commencing

just behind the lachrymal sac, passes outwards, toward the puncta above and below. With dissection of the conjunctiva the fibers can be seen even with the naked eye.

Horner considered that the principal function of the muscle was to keep the puncta in apposition with the globe, and in that way assist in the outflow of the tears. His description has been copied from time to time by most anatomists. A similar view of the muscle is given by Testut in his voluminous anatomy, and a copy of his figure is given herewith. In one of the most recent and best monographs on the capsule of Tenon, published two years ago by Hans Wirchow, an excellent view is given of the muscle of Horner, as it is seen in a horizontal section which passes apparently about on a level with the upper punctum.

To describe this muscle more exactly, we should say that it arises from the crista lachrymalis and from the posterior surface of the lachrymal sac, the fibers passing thence directly outward to be distributed to the puncta lachrymalia above and below. Also an important band passes to the subconjunctival tissue between the puncta, especially to the connective tissue forming the caruncle. No mention was made of these central fibers by Horner, perhaps because they are seen with such difficulty in the ordinary dissection, and we must remember that at his time compound microscopes were rarely if ever used. Now it is to these latter fibers that attention is particularly called in this paper. Those fibers are well marked, as can be seen in the horizontal section here shown. The direction of the fibers evidently indicate that they produce traction on the caruncle, and therefore would seem of sufficient importance clinically to be considered as a special muscle. Together they constitute what we might call the *attrahens caruncule.*

The physiological action of these fibers is not entirely clear, unless they be considered simply as the remains of the membrana nictitans, or that they have some function in connection with the exit of the tears from the conjunctival sac — a process which is not at all sufficiently explained by the theory of the capillary attraction.

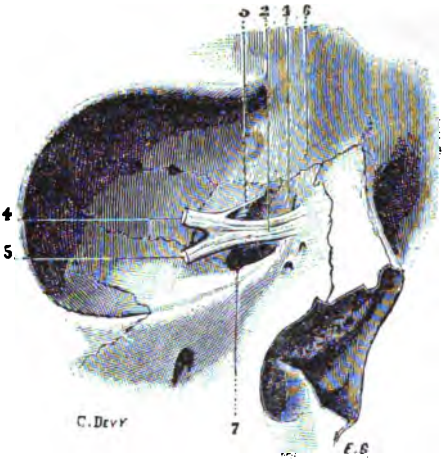

FIGURE 1.

Arrangement of the tendons of the fibrous tissue encircling the lachrymal sac (Testut). 1. Canalis lachrymalis. 2. Band of connective tissue passing from the anterior surface of the sac horizontally outward. From this tendon the fibers of the orbicularis arise. 3. Fibers from the posterior edge of the sac and from the crista lachrymalis which are directed also horizontally. The fibers which pass from this point, toward the globe, and which are removed in this dissection, constitute a part of the internal check ligament. 4 and 5. Portions of the tendons of the orbicularis muscle.

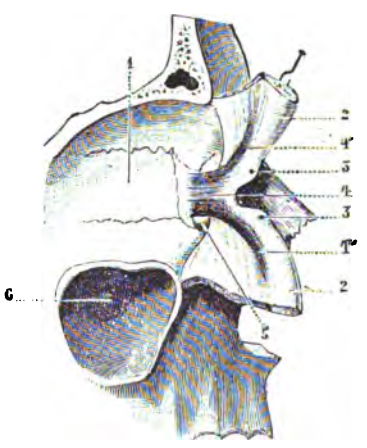

FIGURE 2.

Represents the lid bent forward, showing the ocular surface of the muscle of Horner. (Testut). 1. Plate of the ethmoid. 2. Palpebral edges of the cartilage. 3. Puncta lachrymalis. 4. Median portion of the muscle of Horner. The fibers which pass toward the caruncle can only be seen in a horizontal section.

Whatever may be the reason for the existence of these fibers, or their action in the normal condition, the one thing of which we are sure, and which is of special interest to the clinician, is the part which this portion of the muscle of Horner plays in the operation for tenotomy of the internal rectus. That the sinking of the caruncle after that operation is dependent in part at least upon these fibers there is apparently no question. That is indicated not only by the course of the fibers but by the retraction of the caruncle which we have all seen unfortunately after our operation, even when the wound was closed by a stitch.

It is not pretended that the traction made by these central fibers of the muscle of Horner is the only cause of the sinking of the caruncle. It is undoubtedly true that when we make what is generally termed a free division of the tendon, then as the internus retracts it takes with it the connective tissue of the fibers of tenon and indirectly makes some slight traction upon the caruncle. In other words, in the so-called free tenotomy, division has been made not only of the tendon itself at its insertion, but of those lateral connective tissue fibers, especially at the edges of the tendons, which were photographed, and described in a former paper on that subject before this society as the "secondary insertions." A more exact study of these, however, show that their connection with the fibers which pass outward towards the caruncle are not sufficient to account for the retraction which frequently occurs, and it is more rational to ascribe the sinking to the action of these muscle fibers distributed to the caruncle.

The efforts made to obviate the deformity caused by its subtraction are detailed in almost every text-book, and constitute one of the alleged reasons for subconjunctival operations. Perhaps the most efficient method of dealing with this difficulty is the plan proposed by Schwegger of advancing the caruncle. But that proves insufficient in such a considerable number of cases that very few operators resort to it, and even the more complete of the text-books sometimes omit all mention of it.

In order to avoid the sinking of the caruncle which thus follows free tenotomy of the internal rectus I have in several cases

performed a slight secondary operation, which perhaps may be called tenotomy of the attrahens with advancement of the caruncle. After making the tenotomy of the internal rectus according to whichever plan is indicated in that individual case, the caruncle is seized with a pair of stout forceps and drawn outwards. A cataract knife is then entered at the extremity of the internal canthus on the median side of the caruncle, the flat of the blade being parallel to the inner wall, and the axis of the handle directed toward the apex of the orbit. The point is entered far enough to pass just beyond the lachrymal sac, and a little deeper than the crista larchrymalis. By elevating and depressing the handle the fibers can be separated quite freely, though to make certain that the division is complete it is desirable to turn the edge in the opposite direction. This division of the muscle, however, is by no means sufficient in itself, and the fibers soon unite unless that is prevented by proper closure of the wound thus made. To do this to best advantage, it is desirable to attach the lower end of the vertical wound just described to its upper end. That wound, however, is so short in proportion to its depth that it is impossible to pass even the smallest curved needle in at one extremity and have its point emerge so that the needle can be withdrawn. In order to obviate that difficulty I have had some very small v-shaped needles made which seem to serve the purpose. Therefore, after the wound made by the tenotomy of the internal rectus has been closed, one of these v-shaped needles with the thread attached is passed through the lower angle of the wound made by the cataract knife and the thread is drawn through. Again it is caught in the needle-holder, the axis of the eye end of the needle being the same as the axis of the holder, and the angle of the v being pushed well down into the wound the point is brought out above the upper end: by turning the needle, the thread is easily brought through. When the speculum is in place it is not easy to tie the thread with the fingers, but if a double knot be made and each thread seized with a pair of cilia forceps the knot can be drawn tight. The effect of this is to convert the small vertical wound into one which is hori-

zontal or at most oval. That allows greater opportunity for the advancement of the caruncle, and, above all, lessens the sinking of the caruncle caused by the traction of the central fibers of the muscle of Horner.

DISCUSSION.

DR. SAMUEL THEOBALD. — There is a very much simpler way of presenting sinking of the caruncle as a result of tenotomy of this internal rectus than that which Dr. Howe suggests. I learned it so many years ago that I have forgotten from whom. After making the incision through the conjunctiva over the attachment of the tendon, and before dividing the tendon, carry the scissors well in towards the caruncle, undermining the conjuntiva freely in this direction, so as to separate the conjunctiva from tenoris capsule. The result of this is that the caruncle does not follow the recession of the divided muscle, and deformity is avoided.

CYSTADENOMA OF THE LACHRYMAL GLAND.

BY EDWARD STIEREN, M.D.,
PITTSBURG, PA.

Hugh C., age 42 years, a man of intemperate habits but denying lues, appeared in the eye clinic of the Western Pennsylvania Medical College, March 15, 1904, with a tumor in the outer upper portion of the right orbit. There was marked ptosis but no disturbance of motility of the eyeball.

The patient had first noticed a swelling in this region about six months before. It had never been painful nor inflamed, and, with the exception of the ptosis (noticeable only for the past six weeks) had never caused him any inconvenience. There was no family history of cancer, and the patient had never received an injury in this region.

On palpation a fluctuation was distinctly felt in the center of the mass. The tumor could be mapped out on all sides except above, where it disappeared under the rim of the orbit into the lachrymal fossa. The overlying skin was tensely drawn over the

rounded summit, and had inflammation been present a diagnosis of abscess would surely have been made, so closely did it resemble that condition.

Potassium iodid was exhibited for two weeks, but with no noticeable effect, and the tumor was enucleated March 29th.

An incision was made from a point opposite the external canthus on the rim of the orbit and carried in a curved line midway between the summit of the swelling and the eyebrow, *i. e.*, in a line corresponding to the sulcus of the upper lid, which in this patient was quite deep on the sound side, as the photograph illustrates.

The tumor was found to be encapsulated, and was enucleated with little difficulty.

Its separation from the bone in the lachrymal fossa was facilitated by the use of a Stacke gouge.

In size and shape the tumor resembled an almond shell, with a pedicle (corresponding to the original lachrymal gland) extending into the lachrymal fossa. It measured in the fresh state 32 mm. in length, 18 mm. in its greatest diameter and 12 mm. through its thickest portion. In the center, and extending into the pedicle, was a cavity lined with a gray, friable membrane, containing about 4 c. c. of a yellow gelatinous fluid. Throughout the entire mass were numerous small cysts, varying in size from a buckshot to microscopic spaces, all containing clear or yellow fluid. Microscopical examination showed the tumor to be a typical adenoma, with a general tendency towards cyst-formation. It was rich in blood vessels, and here and there in the sections examined were areas of newly-formed acini and tubules, with their walls thinned or broken down, coalescing, and forming cysts of various size.

The patient made a rapid and uneventful recovery, the incision healing by first intention, the scar attaching itself to the under margin of the rim of the orbit, giving an extremely satisfactory cosmetic result by forming a sulcus closely resembling the deep one of the left eye.

There has been no secondary growth, the complete removal

Cystadenoma Lachrymal Gland - - Stieren.

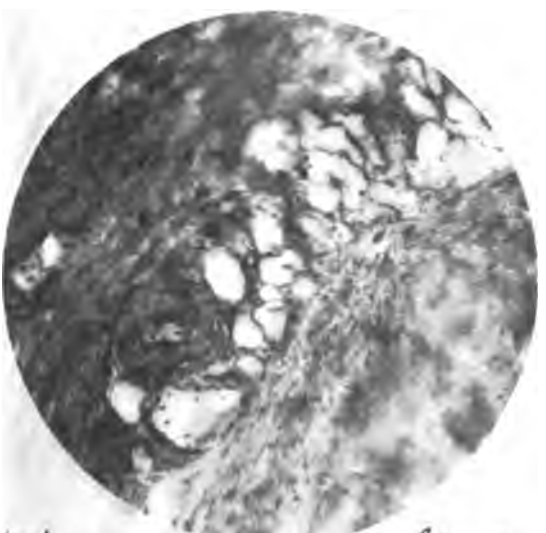

Cystadenoma of Lachrymal Gland showing the beginning of a cyst-formation X 340. Stieren.

of the tumor making recurrence rather improbable in a neoplasm of this nature.

All pathologists now agree I believe that benign tumors can and may degenerate into malignant growths. The very recent and excellent article by Keen on the danger of allowing warts and moles to remain lest they become malignant (*Journal American Medical Association,* Vol. XVIII, No. 2, 1904) advocates the early removal of these growths to obviate the danger of a general sarcomatosis.

According to Wagner (*Manual of General Pathology,* 1883, p. 473) and Schmaus (*Pathology and Pathological Anatomy,* Schmaus and Ewing, 1902, p. 154) adenomata and cystadenomata are benign new formations, which after complete removal do not return nor make metastases. But there are examples of adenoma as well as of cystadenoma, which not only in structure but also in method of growth approach very closely to the carcinomata. They are doubtless transition forms between adenomata or cystadenomata on the one hand and carcinomata on the other, consequently with these a sharp boundary line cannot be drawn between adenoma and carcinoma. Moreover, a cystadenoma, or its prototype, an adenoma, originally benign, may in its growth assume the characteristics of a carcinoma. The development of this character of malignancy announces itself chiefly by the fact that the tumor breaks into the surrounding tissues. At the same time there is often noticed a more active and likewise a more typical growth of epithelial cells (Ziegler, *General Pathology,* 1897, p. 352).

Hence the advisability of early and complete removal of all tumors originating in gland tissue.

TRAUMATIC EMPHYSEMA OF THE ORBIT AND LIDS.

BY HOWARD F. HANSELL, M.D.,

PHILADELPHIA, PA.

The three essentials for the entrance of air into the orbit are a break in the continuity of the mucous membrane lining the cavities accessory to the orbit, a fracture of the bony wall of the orbit, and a rupture of the periosteum. Air may permeate the subcutaneous tissue of the lids without fracture of the bones of the orbit or of the face or rupture of the periosteum. Usually, however, emphysema of the orbit and lids is associated and dependent upon a single cause. The air is, in the majority of cases, confined to those parts, and rarely extends to the adjacent parts of the face. This limitation is the result of the arrangement of the orbital fascia, and it is only exceptional that the character and violence of the traumatism are such that the strong anterior lamina of fascia that firmly connects the lids with the orbital margins is broken.

Emphysema of the orbits and lids may arise from (1) traumatism; (2) necrosis of the bones separating the orbit from neighboring cavities; (3) surgical operations on the lachrymal apparatus or in the cavities adjacent to the orbit; (4) spontaneous, from forcible expiration in the presence of erosion or ulceration of the buccal mucous membrane.

1. *Traumatic.* The only scientific investigation carried out with the object of learning the mechanism of emphysema and the site of the lesion that I have been able to discover in literature was conducted by Walser, at the suggestion of Fuchs (Graefe's Arch., 1897, Bd. 43). Fuchs did not credit the usual explanatory statement, to be found in most of the articles on the subject, that the fracture occurred at the point of contact, namely, the orbital margin. In the majority of the reports nothing was said of tender

or sensitive points, or of other evidence of fracture of that part of the orbit. Fuchs' theory was borne out by Walser's experiments on six dead bodies. These experiments demonstrated that the lamina papyracea of the ethmoid bone was fractured at the moment of impact, and that the periosteum covering this thin and extremely friable shell of bone was ruptured, thus opening up a communication between the nasal cavity and the orbit. The mechanism, as explained by Fuchs, is that the trauma forces the ball backward, causing elevation of pressure in the orbit and fracture of the lamina papyracea. In Walser's experiments colored fluids were made to act as substitutes for air. The fluid was found to have passed through the break in the ethmoid bone and to be distributed throughout the orbit as far forward as the tarso-orbitalis fascia. The fluid did not enter the lids or pass between the fibers of the orbicularis muscle in any instance.

Fuchs' theory explains the lesion in some of the cases in which the effect of the traumatism was borne by the ball and the anterior margins of the orbit, but cannot be applied to those in which the injury involved the back of the skull. Hilbert (Centralb. f. prakt. Augenh., 1884, VIII) describes such a case. A workman fell, striking the pavement with the back of his head. He arose at once, experiencing only a slight pain in the head and neck. Three hours later he had diplopia, a feeling of pressure in the left eye and swelling of the lids, — all increased by blowing the nose. There was proptosis, diplopia, limitation of movement outward, and emphysema of the lids on the left side. The author offers no explanation of the entrance of air. His diagnosis was hemorrhage into and emphysema of the cellular tissue of the orbit. A similar case has been reported by Baudry (Rec. d'Opthal., Aug., 1881).

Case I. Emphysema of the lids, secondary to emphysema of the orbit. A man was struck a sharp blow on the left eye and orbit by another's fist. On the day after the injury both lids were ecchymotic and emphysematous, the eye was dislocated forward, and the cornea turned down and out. Movements in all directions, particularly inward, were limited, and the patient com-

plained of a moderate amount of pain and diplopia. Under pressure bandage and by avoiding blowing the nose or straining the swelling receded, the ball returned to its proper place in the orbit and regained its movements, and the diplopia disappeared.

Proptosis and immobility of the ball, with diplopia suddenly appearing after violent expiratory efforts, are the characteristic symptoms of emphysema of the orbit, but they do not necessarily mean, as some writers imply, that the emphysema is complicated by hemorrhage. The pressure of the confined air alone is a sufficient cause for the symptoms. It is probable that a few drops of blood are exuded from the periosteum or other tissues that may be torn, but the amount of blood from this source is too insignificant to act as a factor. Extensive hemorrhage from the laceration of a large vessel is not likely to occur, because of the tortuous course of the vessels and their protection by the soft tissues. Moreover, we would expect loss of vision, serious and permanent changes in the ocular structures, and extensive conjunctival ecchymosis, conditions rarely associated with emphysema. As Hilbert has pointed out, the complete and speedy recovery also militates against the diagnosis of orbital hemorrhage. In Hirschberg's case (Centr. f. prakt. Augenh., 1884, VIII) the assumption that hemorrhage coexisted is probably correct. A man fell, striking the right orbit against an iron bar. Swelling of the lids and impairment of vision were at once manifest. On the next day he blew blood from his nose, and the lids and conjunctiva were suffused with both blood and air. Protrusion of the ball, emphysema of the orbits and lids, diplopia, and limited movement continued for three weeks. Fuchs (Wien. klin. Woch., Jan. 24, '01) says the exophthalmus is due to air when the ball can be pushed back into the orbit and again forced out by blowing the nose.

Emphysema limited to the lower lid has been reported by Malcolm (*Brit. Med. Jour.*, April 26, '02). A riveter received a light blow with a hammer on the outer angle of the orbit, causing apparently a mere excoriation of the skin. As he blew his nose on the same night the lower lid became suddenly swollen.

The emphysema was slight, and limited strictly to the lower lid. There was no pain or hemorrhage. Malcolm says: "The blow on the malar bone, I take it, caused a fracture indirectly of the orbital plate of the superior maxillary, so that when the air pressure in the maxillary sinus was increased some air found its way into the lid through the crack." Deprés (*Gaz. des Hospitaux*, June 6, 1889) also describes a case of emphysema of the lower lid. Each time the nose was blown the swelling began in the lower lid and spread to the upper lid. His explanation was identical with that of Malcolm.

2. Instances of emphysema of the orbits and lids, following necrosis of parts of the walls of the orbit, such as the ethmoid plate or the floor of the frontal sinus, are sufficiently familiar to justify the omission of case histories in this paper. The extent and the shape of the gaseous tumor depends upon the quantity of air and the location of the entrance point.

3. Surgical emphysema of the lids may be induced by division of the mucous membrane lining the nasal duct during the introduction of the Bowman knife, or rupture of the membrane by forcing a new passage in the attempt to probe the duct, and by operations on the cavity accessory to the orbit. C. L. Birmingham (*Lancet*, Nov. 10, 1900) describes under the title of "Surgical Emphysema of the Eyelids" a case in which the end of a rib of an umbrella was forcibly blown against the right eye close to the caruncle. Three hours later blowing the nose was immediately followed by a high grade of emphysema, closing the lids with a swelling so great that the eyelashes could not be seen. His explanation was "that the lachrymal apparatus was ruptured at the junction of the canaliculi and sac."

4. The appearance of spontaneous emphysema of the orbit without history of fracture presupposes the existence of a communication between the orbit and one of the accessory sinuses, yet in three cases reported no such communication could be found. Desmarres (Ann. d'Oculist, 1845, XIV) cites the case of a 58-year-old man, who subjected himself to heavy sneezing from his habit of taking snuff. Each time that he inhaled the snuff the

left eye protruded and the lids swelled. "So soon as he let go his nose the eye fell back and the lids resumed their shape." Schanz (Beit. z. Augenh., 1899, IV) observed the case of a glassblower, who forced one eye out while in the act of blowing through a tube of small caliber. The traumatism to the nerve finally induced a mild neuritis. T. R. Pooley (Sect. Oph. & Otol., N. Y. Acad., Med., Oct. 15, 1900) records a classical instance of emphysema of the orbit and lids that was not preceded by an injury or disease of the orbital walls. The patient had repeated attacks independently of blowing the nose or violent sneezing. Joncheray (Ann. d'Oculist., 1898, III) saw emphysema of the right orbit and lids repeatedly and suddenly occur after blowing the nose in an individual who had no signs of fracture or history of injury. He had slight nasal catarrh, with polypi.

To these few recorded cases of spontaneous emphysema I wish to add another, although the etiology is quite different. A boy of 16 was struck on the left cheek by the head of a companion. The buccal mucous membrane was forced against the teeth and lacerated. He felt no inconvenience, except from the sore mouth. On the day following the accident he attempted to measure his power of expiration by blowing into one of the recording machines often found in public places. Immediately the left side of the face became distended. A few hours later he applied at the Jefferson Medical College Hospital. The swelling extended from the lower margin of the inferior maxillary to the temporal region and laterally from the nose to the ear. By persistent massage the swelling was reduced until the two sides of the face were almost symmetrical. By repetition of massage and abstinence from forced expiration he recovered in a few days. Fontan (Rec. d'Opthal., 1884) is the only writer I have found in the literature who recognizes erosions of the buccal mucous membrane as a cause of emphysema of the lids.

The symptoms of emphysema of the orbit and lids — proptosis, limited movement of the ball, diplopia, swelling, gaseous crepitation or "crackling" supervening after blowing the nose,

violent sneezing or forced expiration with the outlets for the air closed, following injury or occurring in individuals who have a communication the result of operation or disease between the orbit and lids and the accessory cavities or erosion of the mucous membrane of the mouth — are so well known to you that bare mention is needed. The interest in these cases lies rather in the mechanism of their production than in their diagnosis or treatment. The diagnosis is sufficiently easy, and there is no diversity of opinion in the measures adapted for their cure, namely, massage and pressure. It is doubtful whether potassium iodid, recommended by some writers, is useful.

It is difficult to estimate the frequency of the occurrence of emphysema as compared with other ocular affections. No doubt many cases are met with that attract no particular attention. Certainly the published cases are few. In the Out-Patient service of the Jefferson Hospital of about 2,200 new cases yearly three or four cases are annually observed.

The interval between the time of the injury and the appearance of emphysema varies. Usually it is not longer than an hour or two before the patient feels the necessity for coughing, blowing the nose, or sneezing, but the interval may be much longer. Thus, Knapp (Monatsb. f. Augenh., 1863, I) mentions three days; Thompson (Trans. Oph. Soc. United Kingdom, 1891, XI) ten years, after an operation for exostosis of the orbit. Gosselin (Ann. d'Oculist., Bd. LIX) had a patient who had his lachrymal bone injured in his 24th year, and when 46 years old had sudden nose-bleeding and emphysema of orbits and lids. It is probable that in these long delayed cases the original injury can not be held responsible for the emphysema.

ON THE ACT OF WINKING AND ITS PHOTOGRAPHIC MEASUREMENTS.

BY LUCIEN HOWE, M.D.,

BUFFALO, N. Y.

The act of winking is apparently such a simple process as to have attracted but little attention. It is true we count it as an important factor, in the cleansing of the cornea and facilitating the outflow of the tears from the conjunctival sac. We know also that a person ordinarily winks easier with one eye where the vision of that is more imperfect than that of the other eye; and other points might be dwelt upon in regard to the physiological or pathological aspects of the act of winking.

The object of this paper however is to call attention to a method by which we are able to measure the length of time occupied in this act, and to consider the clinical value of this fact in the early diagnosis of certain forms of paralysis of the third nerve.

As a preliminary step, however, it is necessary to define the act of winking as a sudden and usually unconscious act of closing and opening the lids, that being quite distinct from the more or less deliberate closing and opening of them which is dependent on our volition.

With this limitation of our study, we may glance at the method of measuring the time required to wink. The plan is in general the same as that which I have adopted to measure by photography the time required for the eye to swing laterally through a given arc. It is as follows: The head of the subject is fixed firmly but securely in the head rest for ophthalmological examinations such as I have already described, then a ray of light or light from an arc lamp falling on the cornea is reflected thence into a camera. Instead of the usual sensitive glass plate, this camera is fitted with a film moving vertically on a roller, and the slide in

front of the film is perfected by a narrow horizontal slit. When the eye is opened, and the film is at rest, the reflection from the cornea is focused upon the film as a single point of light. When, however, the roller of the film is turned with a crank, and the film is moved vertically, then the reflection from the cornea describes a vertical line on the film. While this is being done, if the lids be closed, that vertical band is interrupted. Now, if we have a tuning fork near to the eye, so arranged that it throws a second beam through the same horizontal slit upon the same film, while the latter is moving vertically, evidently, as the tuning fork vibrates, it describes a series of toothed lines on the film.

If, therefore, the tuning fork be twanged and the film be moved vertically and while it is still moving, the eye be closed, then the length of time of the wink can be measured by counting the number of registered vibrations of the tuning fork between the point where the vertical line is interrupted and where it again commences. This is the plan of procedure adopted in the measurements referred to.

As for the result of these measurements, it may be stated in a word, that the normal act of winking requires from four-tenths to five-tenths of a second. This was found in eight normal eyes, and the photographs the toothed line represents, of course, the vibration of the tuning fork, and the bright line, the reflection from the cornea. It will be observed that the latter has usually a zigzag appearance, which was produced by the movement of the globe from side to side, but with that we have nothing to do at present. What interest us now are the points at which the bright line, produced by the reflection from the cornea, is interrupted. For, by counting the number of teeth between the point where this bright line is broken, and where it begins again, we have at once, as already stated, the time required for the wink. When this line of the reflection from the cornea is a clear and broad one, or when it is somewhat magnified, we find three parts of it can be distinguished, representing three stages in the act of winking.

First. The line is broken off quite abruptly. This shows

the closure of the lid. It is the most rapid of the three parts in the act of winking, and ordinarily does not occupy more than one-tenth or one-twentieth of a second.

Second. The time during which the lids remain closed. This varies somewhat, being from two to three tenths of a second.

Third. The time required to lift the lid. This is usually slower than the first act, occupying from one to even two tenths of a second. The question naturally arises of what possible value are such measurements. Apparently they are of some assistance in aiding us to recognize in an early stage certain cases of paralysis of branches of the third nerve.

When a ptosis is really developed we can all recognize by inspection a difference in the rapidity with which the lid of the eye is lifted, as compared with the rapidity of motion of the other. In certain cases this is evident. But in others, very close inspection for a considerable time is required in order to distinguish any such difference.

Now, photography thus employed gives us a method by which any such difference can be distinguished accurately and promptly. Moreover, measurements at different times show by comparison what the tendency is toward the increase or decrease of this imperfection.

When, therefore, the lifting of the lid is abnormally slow, it is safe to infer the existence of paresis of the levator.

But it may be asked: Suppose such a paresis of the third nerve does exist, of what great importance is it as long as it is in so slight a degree as to be noticeable only by minute measurements? In reply to this it may be said:

1st. The proposition will be generally admitted that the sooner any paralytic condition can be recognized, the more amenable it is to treatment. This is too apparent to require any discussion, and its importance also is evident.

2d. In any case in which some of the branches of the third nerve are affected while other branches remain in a normal condition, the distinct recognition of which muscles are or are not



FIGURE 1.

C C′ reflections from the cornea. The interruption of this line near its upper portion is caused by the closure of the lids (by a wink). T T′ Toothed line produced by vibrations of the tuning fork. Imperfectly shown in this photograph. E E′ An extraneous reflection. Of no importance in this connection.

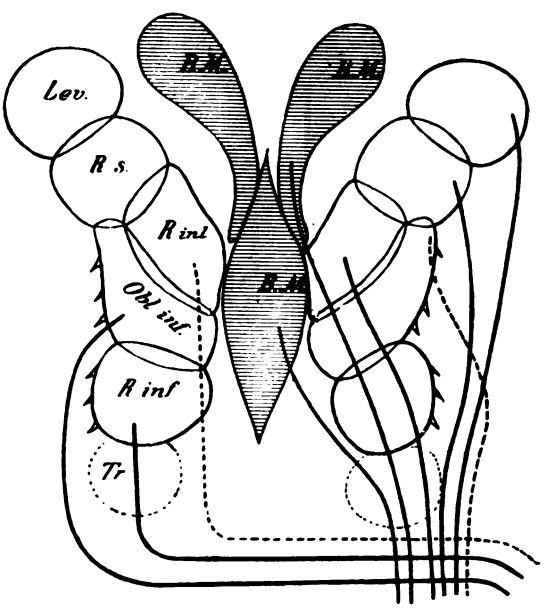

FIGURE 2.

A diagrammatic representation according to Bernheimer of the arrangement of the cells of the nucleus of the third nerve, anterior view. The shaded portions in the center and above are those which preside over accommodation and convergence

involved assists us in determining the function of the different groups of cells which constitute the nucleus of the third nerve.

In order to appreciate the meaning of this statement, it is necessary to recall for a moment the microscopical structure of the nucleus of the third. We know that it lies just beneath the fourth ventricle, and that serial sections show the nucleus can be resolved into various groups of cells, such as have been shown by Perlia, Archives of Ophthalmology, part 4, page 287, and more recently by Bernheimer. For example, a frontal section just anterior to the center of the nucleus presents an appearance such as is shown in figure. . . .

Unfortunately, there is still doubt as to which of these groups of cells preside over the separate muscles. Considerable light has been thrown on this subject, it is true, just of late, and the result of experiments in irritating certain groups of cells give fairly constant results. They show, for example, that the central group of cells preside over the act of accommodation, that those adjoining them on either side preside over convergence and that the lateral groups probably preside over the various extrinsic muscles. The study of this problem from that point of view must necessarily remain in the hands of those who are trained to laboratory work.

But there is another very interesting and important aspect of the subject which can be studied by any clinician. This depends upon the fact that when only two or more branches of the third nerve are affected, and the other branches remain intact, then it is probable that the lesion involves cells at the nucleus which are contiguous to each other. Thus, if we have difficulty only with accommodation and convergence, while the other branches of the nerve remain intact, we infer that the lesion is situated in the cells near the center and just on either side. A study of this subject from the clinical aspect was made by Starr of New York several years ago, and his article still remains a classic in the literature of that subject. As these cases in which only a portion of the branches of the third nerve are involved are comparatively common in the practice of every ophthalmologist, it is to our discredit that we

have not contributed more to the subject. In doing that, it is hoped that a study of the act of winking may assist in showing when the levator is affected, and in a degree which can be measured with the utmost exactness.

3d. These exact measurements furnish corroborative evidence to a very exact degree of a paresis, the existence of which we have reason to suspect, in some other branch of the third nerve, by which the muscle balance is affected. Especially is that important when those other branches have to do with either accommodation or convergence. For example, in a given case where an exophoria exists, it is desirable to determine whether that condition depends upon an abnormal action of the sixth nerve or a paresis of the third.

Now, if the time required in the act of winking and the limits of the field of fixation with other tests all indicate a paresis of the third nerve, then we are warranted in concluding that the exophoria is of what may be called the passive type. In other words, that condition in that individual is due rather to a relaxation of one or both interni than to any excessive action of the externi. That in turn means the direction in which prisms should be placed, either to give greater rest or to exercise the muscles which are at fault. The conclusions of the paper may be summarized as follows:

1st. It is possible to measure by means of photography the time required in the act of winking, according to the method detailed.

2d. Under normal conditions this occupies from four-tenths to five-tenths per second.

3. The recognition of a paresis of the levator palpebral muscle even in a slight degree is of advantage

(*a*) As affording in general better opportunity for early treatment.

(*b*) As indicating the function of certain groups of cells in the nucleus.

(*c*) The corroborative evidence gives some indication as to the real nature of any existing heterophoria.

SYMPATHETIC NEURO-RETINITIS AND SEROUS UVEITIS FOLLOWING ENUCLEATION WITH IMPLANTATION OF GLASS GLOBE — RESECTION OF OPTIC NERVE — RECOVERY.

By ROBERT SATTLER, M.D.,

CINCINNATI, O.

The extreme rarity of sympathetic lesions after timely enucleation is an admitted fact. The case, brief mention of which follows, belongs to this class. It assumed the clinical expression of neuro-retinitis and serous uveitis. It was favorably influenced by resection of the optic nerve.

Compared with the large group of hopeless sympathetic plastic lesions of the uveal tract, the ones comprising the more uncommon expressions — neuro or papillo-retinitis and serous uveitis, are small. The former or plastic lesions are almost uniformly uncertain and hopeless in their course, and their termination in total blindness almost a certainty. Once positively declared, enucleation cannot be counted upon. It may even influence it unfavorably. Common experience has established this. On the other hand, the other much less frequent expressions of so-called serous uveitis and papillo-retinitis are so far as their course and termination, a shade less hopeless. Experience has taught with this smaller group, that prompt enucleation may intercept a disastrous termination, even if started on its uncertain course. The present case belonged to this latter group. It had two points of difference. It developed after enucleation, and this was furthermore supplemented by a most successful implantation of a glass globe in Tenon's capsule.

My colleague, Dr. D. T. Vail, performed the operation. The tendons of the recti muscles were firmly sutured over the glass globe and the conjunctiva also. The reaction which followed was sharp but subsided promptly, and the patient was discharged from the Cincinnati Hospital forty days after admission, or

twenty-five days after enucleation of the injured eye, with a cavity most favorable for wearing an artificial eye, and free from all irritation. The artificial globe was securely held by the now firmly united muscles and conjunctival covering.

Shortly after his departure, he reported to Dr. Vail, who could find at such times no explanation for his repeated complaints that his vision was growing dim, and that at times he had difficulty in finding his way about. The eye was free from all objective disturbance and the left orbit showed nothing abnormal on inspection or palpation.

Sixty-three days after the accident, and forty-eight after enucleation of the left eye, he applied for relief at the Ophthalmic Hospital, and at that time it was discovered that he had pronounced neuro-retinitis associated with a low grade of serous uveitis.

He was at once readmitted to the Cincinnati Hospital under my service, and gave the following history:

On the preceding day his sight had so markedly diminished that he was rendered helpless, and the eye for the first time became irritable and inflamed. Rest in bed, with atropia instillations and warm fomentations, relieved promptly the irritable and inflamed condition of the eye, but vision remained reduced to light perception, and with difficulty to movements of the hand. There was neither redness nor tenderness, even with firm pressure over the glass globe.

Ophthalmoscopic examination disclosed a hazy aqueous and vitreous, with numerous precipitates on membrane of Descemet and posterior lens capsule. Typical papillo-retinitis with œdema and numerous delicate grayish-white exudates in and on the papilla and extending also into the adjacent retina were present.

Loth to disturb that which, at least for future cosmetic purposes, had been so successfully accomplished by Dr. Vail, I asked him to see the patient with me. Together we decided that radical interference was imperative, and on the same day I removed the glass globe and resected the trunk of the optic nerve, removing about two and one-half centimeters. The dissection was tedious

and difficult, and the cut nerve trunk was found firmly surrounded and imbedded by dense cicatricial tissue.

Less than forty-eight hours after the operation he was able to count fingers at six feet, and there had come about almost complete subsidence of irritability and injection of the globe.

In the course of the next five days vision steadily improved, and all local inflammatory symptoms had disappeared, when suddenly, without assignable cause, vision again dropped down to light perception. Ophthalmoscopic examination disclosed greater swelling of papilla, with blurring of its border and numerous thin, filmy, grayish-white exudates, but no hemorrhages. Dioptric media much clearer.

He was now placed on a vigorous course of inunction and vapor baths, followed by iodides, and from this time until his discharge, May 25th, or forty days after the resection, the papillo-retinitis had steadily receded and vision was restored to 0.6.

Summarizing the time limits: Feb. 8, 1904, injury of left eye with penetrating birdshot at close range (50 feet), followed by a low grade of painful irido-cyclitis with recurrent hemorrhage. Fifteen days after injury enucleation and glass globe implantation. Transitory dimness of vision, at first at long intervals, but, becoming more and more frequent, finally resulted in complete helplessness about three weeks after the operation. Unfortunately the patient withdrew from observation during part of the time, and, because certain evidences which ophthalmoscopic examination alone could have furnished are wanting, it must remain an open question whether the papillo-retinitis or the serous uveitis was the primary lesion.

Interesting queries are suggested by a study of this case:

Did the glass globe, so successfully implanted and so firmly secured in position, exert any deleterious pressure upon the cut end of the optic nerve, its lymph channels, or the adjacent sensory nerves? Toxines excited by micro-organisms could be excluded, for the injured eye showed no infection, and there was no evidence of any subsequent one. The surmise that shot had pene-

trated the trunk of the optic nerve could not be confirmed, as the resected end contained none, and subsequent disclosures did not uphold this.

The most careful search for evidences of syphilis, early or late, a central focal lesion or toxic causes, even as remote etiological factors, had to be excluded.

The case recites this new fact: that contrary to accepted opinions, sympathetic neuro-retinitis and certain expressions of serous uveitis may be excited even after enucleation of an eye destroyed by a *non-infectious lesion.*

It would also appear that resection of the optic nerve yields the same prompt results which follow enucleation, if practiced for the rare and typical ones of sympathetic neuro-retinitis and serous uveitis, in which the operation of an infected or degenerated eye has been deferred until one or the other positive expression of this more uncommon and much smaller group of sympathetic lesions is already well under way.

DISCUSSION.

DR. E. S. THOMSON. — I would like to report briefly a case I observed two years ago, which was operated on by Dr. Kinney. The Mules' operation was done, which was successful: the reaction subsided, but in about ten days the other eye began to get red and inflamed, and a low grade of iritis developed. The patient was treated energetically with antispecific treatment, but it was not until the globe was enucleated that he finally recovered. The type of uveitis was not so severe as Dr. Sattler describes in his case, and the boy made a complete recovery. This is the only case of the kind that we have had at the Manhattan Eye and Ear Hospital, where we have done about fifty Mules' operations. The glass ball was first removed, and then the optic nerve resected.

DR. T. Y. SUTPHEN. — It would seem that there must have been some irritation at the end of the nerve in the case of Dr. Sattler's. I reported a case a few years ago, where there were strong adhesions between the stump after enucleation and a cicatrix upon the inner side of the lid, producing traction on the nerve with each movement of the eye. Sympathetic neuro-retinitis de-

veloped three (3) weeks after enucleation, which quickly subsided following the cutting of the adhesive bands.

DR. W. E. LAMBERT. — I understand Dr. Sattler to say that the eye was enucleated and a glass ball inserted; it was not a Mules' operation then.

DR. SATTLER. — No, it was not a Mules' operation. The glass globe was implanted, after enucleation, in Tenon's capsule, and the muscles and conjunctiva securely sutured over it. The union was complete, and the artificial globe was firmly held.

DR. PERCY FRIDENBERG. — Dr. Sattler's case adds another contraindication to the implantation operations as substitutes for enucleation. The introduction of the Snellen "reform" artificial eye has already greatly reduced the necessity for any such alternative, as was pointed out by Dr. de Schweinitz in his report to the Paris Congress some years ago. In cases where the cosmetic result is not perfect, even with the Snellen eye, it can be improved by putting in a glass ball back of the shell, but not implanted at all. It is put in, and the thin shell placed over it. At Dr. Gruening's clinic we have done that with very good results. The ball is removed at night with the shell.

DR. G. E. DE SCHWEINITZ. — In 1900 I read before the Thirteenth International Congress of Medicine in Paris a paper entitled "The Comparative Value of Enucleation and the Operations which have been substituted for it," and, among other procedures, analyzed seventy-two operations done in America of implantation of an artificial globe in Tenon's capsule. Among these there was only one case, recorded by Dr. Suker, of sympathetic irritation, not inflammation, and this was cured by the removal of the implanted globe. The accident which Dr. Sattler describes is therefore an uncommon one. In my own practice such a condition has not occurred.

DR. SAMUEL THEOBALD. — I just want to mention a fact, with which probably some of the members are not familiar: that is, that the plan referred to by Dr. Fridenberg, of placing a glass ball under the artificial eye, originated with Dr. Russell Murdoch of Baltimore. However, I do not think he employs it now since the Snellen improved eye has come into use.

ANGELUCCI'S MODIFICATION OF THE TECHNIQUE OF THE CATARACT OPERATION — FIXATION OF SUPERIOR RECTUS AND COMPLETION OF ENTIRE OPERATION WITHOUT SPECULUM OR AID OF ASSISTANT.

BY ROBERT SATTLER, M.D.,
CINCINNATI, O.

In the discussion of Dr. Reik's paper on intracapsular irrigation in cataract operations Dr. Gruening referred to a recent improvement of the technique of the operation, proposed and practiced by Prof. Angelucci of Palermo. Dr. Gruening expressed his approval of this modification, and mentioned that he had practiced it in a series of ten cataract extractions with satisfactory results.

My associate, Dr. V. Ray, after reading this favorable notice in the published transactions of the society, was led to put it to the test, with equally gratifying results, in a small series of cataract extractions, during my absence. At the same time, last winter, an opportunity was afforded me to meet Prof. Angelucci, and to observe the practical application of his modification, — fixation of the globe by seizing the tendon of the superior rectus muscle and completing the entire operation without the speculum or aid from assistant, — as practiced by himself in the ophthalmic wards of the University Hospital of Palermo.

The main advantage of the Angelucci modification is that it simplifies the commonly practiced technique of extraction during the early and most important stage of the operation. It also eliminates throughout the use of the speculum, and renders unnecessary the holding of the lids by an assistant. It affords the surgeon, if not a better, certainly a less obstructed view of the field of operation. The section can, for this reason, be done with greater deliberation and precision. Furthermore it substitutes fixation of the globe, as the first step, and, owing to the selection

of a new locality, which secures a hold more safely to be depended on than the one ordinarily selected, serves at the same time the purpose of holding up the upper lid. This twofold purpose of fixation, with resulting retraction of the upper lid, is the principal practical feature of the modification. The subsequent steps of the operation are not modified.

Fixation by grasping the tendon of the superior rectus muscle controls more securely the movements of the globe. It suspends for the time being the action of the upper lid. It renders impossible muscular contraction of the orbicularis. The upper lid cannot descend. Owing to the firmness of its tarsus it is pushed up in toto, under the roof of the orbit, and is securely held up by the support which the closed limbs of the fixation forceps give it at one point only of its lid margin. It is this one point of contact or support which enables the surgeon to hold it up and increase or diminish the dimensions of the lid-opening as the needs of the case may require, by raising and pressing with gentle firmness the closed forceps against the cutaneous border of the orbit. The palpebral fissure can now be opened to its fullest dimensions, and a clear and unobstructed field of operation is brought into view. It may happen in large and shallow orbits of the brachycephalic type that the fixation of the globe and the attendant drawing up of the upper lid may produce traction upward of the lower lid; but this does not ordinarily interfere, and can be readily averted by relaxing the fixation and drawing the eye downwards, forwards, and a little outwards.

If fixation of the globe as described secures not only a firm hold which can with reasonable certainty be depended upon, and, at the same time, also immobility of the eye, together with suspension of muscular contraction of the upper lid and a reliable and wide opening of the palpebral fissure, it is certainly entitled to recognition and deserves to be put to a careful and painstaking test. Besides it simplifies the older and commonly adopted methods by substituting at the outset a different locality and firmer tissue for the fixation.

That the use of the speculum and fixation, practiced as part of

the technique of the commonly adopted method, may give rise to unlooked-for complications belongs to common experience. The former (except under complete general anæsthesia, which alone eliminates its greater risks), even with complete local anæsthesia, referring only to some of its objectionable features, may produce unequal pressure on the globe, contract or render unsatisfactory the field of operation, or its introduction may excite violent reflex contraction of the orbicularis, which may even lead to expulsion of the speculum at a critical moment during the operation. Fixation, as commonly done, does not always secure a firm hold, and tearing and excessive bleeding often add annoying delay.

We may recognize the importance and become convinced, after experience has demonstrated this, of the decided advantage of adopting Angelucci's suggestions for certain cases. We may also be forced to admit that the section of the cornea is made with greater precision; but whether we can complete the other steps of the operation after the manner done by him, that is another question, for that depends upon inherent and acquired aptitude of the surgeon, and not a little also upon the patient.

Briefly told, this is Angelucci's method of operating:

The patients are selected and prepared for operation by his assistants. In most instances he does not see them until the time of operation, after all preparations have been completed, as afterwards he does not see them again except when complications arise. Aseptic precautions, local and general, are rigidly enforced. Special attention is directed to the mouth, teeth and gums, nose, and tear sac. If glycosuria or albuminuria are discovered, the proper measures are at once adopted, and antistreptococcus serum is injected into the parietes of the abdomen as a preventive to possible unfavorable reaction at the moment of the operation. Accurately regulated cocaine instillations (four per cent.) are made by the aid of the sand-glass at intervals of two or three minutes. At the expiration of ten minutes the patient is placed before the surgeon, the face covered with cloths dipped in antiseptic solution. From this moment no one touches the patient or renders other aid than handing the instruments.

If the left eye is the one selected for the operation the surgeon with the index finger of the right hand raises the upper lid and directs the patient to look down, and seizes the conjunctiva and underlying tissues, and, with firmer pressure, grasps the tendon of the superior rectus muscle in the bite or hold of the forceps. He seizes the tendon and the tissues over it with an ordinary broad fixation forceps, sometimes parallel with its lateral border but generally parallel and near to the insertion. After the eye has been thoroughly immobilized by traction forwards, outwards, and upwards, the closed forceps now also supporting the upper lid is raised and gently pressed against the upper margins of the orbit. The section, following no rule, but adapted to the needs of the case, is now made, and the fixation forceps is removed at once after it has been accomplished. The next step, iridectomy, and all subsequent ones, are done without fixation. The little finger holds the upper lid, and the iris is drawn out and cut off with a single cut of a pair of De Wecker scissors. The coloboma is generally small. After reposition of the iris the capsule is freely opened with an ordinary cystotome, or it is removed with the capsule forceps if thickened. In the opening of the capsule no rule is followed, and vertical, horizontal, oblique, as well as peripheric incisions, are practiced, to effect the exit of the lens. Removal or expulsion of the lens is done with a narrow Daviels spoon, bent at right angles to the shank, and with this pressure is made in the usual manner against the lower margin of the cornea. Great care after the lens is extracted is taken to remove all cortical masses, and the spoon is repeatedly introduced and diligent search is made to bring out larger, less opaque, or less movable and adherent cortical masses. After this the eyes are securely bandaged, and the usual after-treatment adopted. Angelucci also performs the simple operation, but my observations during my stay were limited to those with iridectomy.

Let me briefly enumerate the practical advantages of Angelucci's method and determine so far as is possible whether, when once thoroughly appreciated and put to the test by others, it may revert to the common good of operators in general.

My observations and limited experiences of this method have forced upon me the conviction that an important improvement has been added to the technique of the cataract operation.

It is of unquestionable superiority, and will hold its place as a most valuable substitute for those cases of extraction in which a firm hold for fixation cannot be secured in the localities ordinarily selected, and in which, owing to senile fragility, arterio-sclerosis, or other causes, the bulbar conjunctiva and underlying tissues bleed excessively, tear, or give way, and for these reasons annoying delay and other complications may affect the making of a clean and clear section of the cornea.

It will also be found of great service in surgical measures requiring a longer and firmer hold of the globe and a wide lid opening, removal of superficial neoplasms of the bulbar conjunctiva, exploration of the eye with electro-magnet, etc. But not until individual and common experience prove it more conclusively will it receive larger recognition for cataract operations in general.

One of several reasons which may invite a test of its merits is that fixation and opening of the palpebral fissure are not, as in the old way, two distinct steps, but are reduced to one. The dangers of the speculum are entirely avoided, and fixation is more certain and can almost uniformly be counted upon. In other words, simplicity and greater safety have been added to the technique of the operation, justly regarded as the cardinal one of ophthalmic surgery.

My practical observations were not at once confined to cataract operations, but to insure proficiency in the manipulation of the fixation forceps, about to serve a double purpose, it was at first resorted to, — for inspection in obstinate phlyctenular keratitis with blepharospasm, for the removal of an extensive epithelioma of the bulbar conjunctiva, semilunar fold and caruncle, for iridectomy inwards for optical purposes, for cyst of the bulbar conjunctiva, for discission of secondary cataracts, even for the removal of foreign bodies from the cornea and other minor surgical measures. Here its facility and firmer hold was demonstrated. If it happened, as it did, that the lower lid was drawn up and

partly covered the lower border of the cornea, this could be easily averted by drawing it down with a small strabismus hook.

As already stated, Dr. Victor Ray, during the winter of 1903-04, at the Ophthalmic Hospital, had made eight extractions with gratifying results, but after the section was completed he did not follow Angelucci's method but relied more or less upon the aid of an assistant during the making of the iridectomy. The speculum was entirely avoided. Only in one, the last of the eight cases, was there any difficulty, namely, an unusually strong contraction of the orbicularis after the extraction had been made, resulting in a slight loss of vitreous. The final result, however, was excellent.

In my first extractions with fixation, by seizing the tendon of the superior rectus muscle, the hold of the globe was retained also for the iridectomy; this of course avoided the holding of the upper lid with the finger or the use of the speculum, but it necessitated the aid of an assistant. In the subsequent operations, whether simple extractions or with iridectomy, nine in number, this was abandoned, and the entire operations completed without aid from assistant. In two cases, one of hyper-mature cataract, in an unruly and half-witted person, general anæsthesia was resorted to. The simple operation was done with ease, dispatch, and excellent result. In a second case, also under general anæsthesia because the patient was demoralized by fright, the opaque lens had been dislocated into the anterior chamber; the result was also favorable.

It may be suggested that the speculum, with general anæsthesia, would have accomplished the desired purpose with the same ease. In both cases, and in others, its introduction was tried before resorting to the other fixation; but the lid-pressure was greater and the view of the field of operation was more contracted when compared with fixation, and the holding up the upper lid by its means, for the view of the upper margins of the cornea and regions adjacent, was less obstructed. The total number of extractions was fourteen, with eight by Dr. Ray, making twenty-two cases.

This limited trial of Angelucci's modification has demonstrated to me its practical advantages, and that it is deserving of a painstaking trial. Fixation is safer because the use of the speculum can be avoided. The operation is of shorter duration and less painful to the patient. Fixation is easier and firmer, and the mobility of the eye can be more effectually controlled.

DISCUSSION.

DR. T. R. POOLEY. — May I point out what seems to me to be one objection to the operation? That is the placing of a possible abrasion of the conjunctiva nearer the operative wound. Some of the gentlemen here have properly called attention to the advantage of, if possible, not wounding the conjunctiva at all with fixation forceps. It seems to me that placing a possible abrasion nearer the wound would add to the dangers of the operation.

DR. P. A. CALLAN. — Shortly after the publication recommending this method I tried it. Since then I have used it in about six cases, and I think a great deal may be said in its favor. In simple extraction it is probably an ideal method, but when you wish to perform an iridectomy your difficulties begin. It is a very difficult matter, as we all know, to do an iridectomy simply by cutting of the iris without any fixation, and with a patient that we can not rely upon. I have done it six times, but I do not think, however, that it is well to do it, except in selected cases perhaps. When you come to perform the iridectomy it is a very difficult matter. The speculum has its objections, but this method has more. The eye is unsteady, and you can not rely upon your patient.

DR. SAMUEL THEOBALD. — Dr. Callan has already mentioned one of the objections I had in mind; but another suggests itself, and that is that the point of fixation is in the direction that we are to cut with the knife. In the usual method of fixation we all, perhaps unconsciously, draw the eye against the movement of the knife, and it seems to me, without having had any experience with the operation, that the point of fixation suggested is objectionable because it renders this impracticable.

DR. PERCY FRIDENBERG. — In following a series of these cases it appeared to me that there were a number of objections. One

has already been mentioned, and was brought out yesterday by Dr. Pyle. The ordinary fixation forceps are apt to tear the conjunctiva, and with a small area of fixation rotation easily takes place. A better fixation is one that will take hold of the muscle. Another objection is that the lashes are apt to get in the way, especially with a deep-set eye. Although they may be supposed to be aseptic it is not desirable to have them come in contact with the knife. I have devised a small fixation forceps, intended to obviate that objection. They have also been used in removing foreign bodies, scraping corneal ulcers, etc. The forceps catch the entire muscle, and have a retractor for holding back the upper lid.

Dr. J. W. Ingalls. — When I heard Dr. Gruening's remarks at our last meeting I was much interested, and had a conversation with him as to the method. I thought at the first opportunity I would try it, but perhaps my ultra conservatism restrained me. A short time afterwards I read an article — I regret that I can not now recall the author's name — advocating the seizure of the eyeball by the Angelucci method, but using the speculum. I tried that, and was much pleased with it. It gives a more secure hold, and the knife is under better control than when we grasp the eyeball in the usual manner. I have done several cataract extractions in that way, and also several iridectomies. In cases of soft cataract in children and young adults I think the speculum is entirely unnecessary. Leaving out the speculum is certainly appreciated by the patients.

Dr. S. B. St. John. — I should like to say that since our last meeting, at which Dr. Gruening alluded to this method, I have been induced to try it in eight cases, and have been charmed with it. There is a class of cases, however, in which I would not try it: that is where the eye is very deep-set, because I am afraid of nicking the lid and making the patient start. In cases where the eye is not deep-set I have found it a very good method.

In regard to the objection of Dr. Callan, that you could not easily perform the subsequent steps of the operation, I would say that the subsequent steps are the same as I have been doing for many years. After making the incision I never use fixation forceps, I do not depend on an assistant, and have never had the patient disappoint me. The advantage given by deep fixation is a matter of a great deal of comfort when you are making the incision, in the solidity that it gives the eye. You feel that you

have something solid, and can direct the knife with greater accuracy. If you do not have it the eye will rotate, and you may need an assistant to use the forceps below; that happened in one case where I had not the fixation as deeply as I intended. Where you have this deep fixation the eye does not rotate, and it is also an advantage not to have the speculum in the eye in case anything should happen during the section.

DR. R. SATTLER.— Dr. Pyle asks whether the danger of wound infection may not be greater for the reason that the locality of fixation is nearer to it. So far as the distance between the new and old location for fixation is concerned, one cannot be much in excess of the other. If fixation is done in the locality suggested, tearing and hemorrhage are lessened. The point to be remembered is that the forceps must take only a small bite of the conjunctiva over the tendon. For this reason the forceps should, with gentle pressure, be applied closed against the bulbar conjunctiva, and then be cautiously opened with firmer pressure against the tendon, so as to seize it with a firm hold. The tendon is often lax, and one must give the forceps an additional twist to make it tense. But not until one has demonstrated to oneself by traction that the tendon has been seized by the forceps should this be done.

Dr. Callan has referred to the possibly greater difficulty in making the iridectomy if fixation of the tendon is retained for this step of the operation. In the cases in which it was resorted to for extraction or iridectomy for other purposes, it did not appear to me more difficult, but it required of course the aid of an assistant.

Dr. Theobald, in referring to fixation in this locality, mentioned the greater difficulty in making the incision, and that the knife might be hampered in its excursions.

The fixation must be properly done, and the tendon securely seized. If this is really accomplished, then the section, owing to the larger field of operation, can be made with greater ease. The eye can by traction upon the tendon of the superior rectus muscle be pulled downward and forward, which offers a counter force, and the incision can be made as readily with the high as with the old method of low fixation.

Another point to which I would call attention: and this is, that the Angelucci method of fixation may also be a forceful measure of suggestion, and that it can be used as such alone in some cases and with hypnosis in others. It is like putting the twist on a horse's lip to insure its keeping quiet.

As already stated, I have used the method as an accessory measure of suggestion without hypnosis in case of chalazion and other minor surgical operations, and it was attended by satisfactory results. It is not improbable that with a certain class of patients this method of fixation may for this reason do much to insure quiet submission for the short period necessary, if the mental attitude of the patient and operator and the surroundings will to make it so.

Dr. St. John's favorable report with this method of fixation confirms my own experience. In deep-set eyes with overhanging orbital margin it should not be practiced. Convinced by my own experience of the usefulness and advantage of this modification of fixation I have had but one desire, and this to bring it to a more general notice of the society and have it put to the test in suitable cases.

A RARE TUMOR ARISING FROM THE PARS CILIARIS RETINÆ (TERATO-NEUROMA), OF A NATURE HITHERTO UNRECOGNIZED, AND ITS RELATION TO THE SO-CALLED GLIOMA RETINÆ.*

BY F. H. VERHOEFF, A.M., M.D.

(From the Pathological Laboratory of the Massachusetts Charitable Eye and Ear Infirmary.)

Badal (1) and Lagrange, in 1892, gave a description of a tumor arising from the pars ciliaris retinæ, which they regarded as an adenocarcinoma. Four years ago Emanuel (2) reported from Leber's clinic a case similar in almost every respect, but he took the view that in both cases the growths were gliomata. The writer has recently met with a third case of the kind, which presents a number of important features that either did not occur in the other two, or, as seems more likely, were overlooked. The findings in this case seem to be absolutely unique, and not only to demonstrate beyond question the real character of these three tumors, but to indicate the nature of the whole class of tumors ordinarily referred to as gliomata retinæ. The case is as follows:

Annie C., white, aged 2½ years, admitted to the Carney Hospital March 14, 1904. Family history negative in regard to tumors. Mother noticed for the first time 3½ months ago that the child's right eye was more

*Read by invitation of the society.

prominent than the left, that the pupil was enlarged, and the eye inflamed. The child cried often at this time and frequently vomited. The inflammation soon disappeared, but the eye gradually became more and more prominent and the child "acted as if she did not see with it." About two months ago the child was seen at the Massachusetts Charitable Eye and Ear Infirmary, where the diagnosis of glioma retinæ was made and enucleation advised. It was noted there that the lens showed cataractous changes in the cortex.

On admission to the Carney Hospital, the right eye was much more prominent than the left and showed two bluish staphylomata in the ciliary region, each about the size of a bean; one situated on the nasal and the other on the temporal side above. There was no sign of inflammation and no pain. The cornea was perfectly clear, the pupil dilated, irregular, and unreacting. Tension +1. The lens was completely cataractous, brilliant white in color, and was dislocated downward and outward, the inner edge being tilted slightly backward. A red reflex could be obtained with the ophthalmoscope past the nasal side of the lens. No new growth could be made out in the ciliary region, but the child was so refractory that only a hasty examination was possible. The right eye appeared normal. The child was well nourished, and aside from the ocular condition, apparently healthy. On the day after admission the eye was enucleated. No signs of a new growth could be found in the orbit.

Pathological condition. Immediately after enucleation the globe was sectioned in a vertical plane passing just anterior to the ora serrata. Diameters of globe, ant. post. 27*mm.*, vertical 23.5*mm.*, horiz. 24*mm.* The cornea is 11.5*mm.* in diameter, and at the center is only .5*mm.* thick. The two staphylomata are seen to be of the intercalary type, due to a thinning of the sclera between the ciliary body and cornea. Each is about 4*mm.* in diameter and 2*mm.* high, the walls being .25*mm.* in thickness. The anterior chamber is 1.5*mm.* deep, and is free from coagulum after fixation. The pupil is 6*mm.* in average diameter. Hanging from the pupillary margin above there are five small white globular bodies attached by short delicate pedicles. The largest is .35*mm.* in diameter. On closer inspection a larger number of bodies apparently of the same kind, but much more minute, can be made out along the margin of the pupil. The iris is adherent to the cornea for a distance of 1*mm.* from the limbus all around. Beneath the staphlyomata it is not recognizable, probably having undergone atrophy. At one point there is a small anterior synechia.

Arising from the ciliary body in the upper inner quadrant, there is a white irregular growth showing numerous rounded excrescences of various sizes, which fills the space between the ciliary body and lens, pushing the latter aside. Many of the excrescences are similar to the globular bodies attached to the margin of the pupil. Posteriorly the growth nowhere extends as far backward as the ora serrata. Anteriorly the main body of the growth extends only a short distance beyond the anterior margin of the ciliary body, but as a thinner layer, showing, however, here and there globular bodies, it can be seen extending beneath

the staphyloma on the nasal side, and growing over the posterior surface of the iris (Fig. 1). On the temporal side the ciliary body appears to be unaffected and there is apparently no growth beneath the staphyloma on this side.

The lens, *9mm.* x *6.5mm.*, is completely opaque, swollen unequally, the nasal side being most enlarged, and is pushed over in contact with the ciliary body at the lower outer quadrant. The vitreous body, at first perfectly clear, is after fixation coagulated in the form of an opaque granular mass. The sclera is not appreciably thinned except at the sites of the staphylomata. The retina and choroid are in situ, the optic disc is not cupped, and the nerve is apparently normal.

Histological examination. Fixation in Zenker's fluid. Embedding in celloidin and paraffin. Sections were made at different levels throughout the growth so that nothing important could escape notice. Staining in hematoxylin and eosin, Van Giesen's stain, Weigert's elastic tissue stain, Haidenhain's iron hematoxylin, and Mallory's connective tissue stain[3]. In addition the following modifications of Mallory's method[3] for staining neuroglia were employed:

METHOD A.

(1) Mallory's phospho-molybdic acid hematoxylin. 15 *min.* — 2 hrs.
(2) Wash in water.
(3) Mallory's phosphotungstic acid hematoxylin (or hematein), 1 h. or longer.
(4) Wash in water.
(5) 10% aqueous sol. phosphotungstic acid, 1½ hrs. or longer.
(6) Wash in water; examine on slide under microscope, and, if desired, differentiate further according to (5) below.
(7) Acid fuchsin ½% solution, 5 min. or longer.
(8) Wash quickly in water.
(9) Alcohol 95%. Mount on slide.
(10) Blot, and apply xylol quickly.
(11) Blot, xylol, blot, xylol-balsam, cover glass.

METHOD B.

(1) Mallory's phospho-molybdic acid hematoxylin, 24-48 hrs.
(2) Wash in water.
(3) Mallory's phosphotungstic acid hematoxylin (or hematein), 1 hr.
(4) Wash in water.
(5) Differentiate by placing sections for 5 seconds in aqueous solution of potassium permanganate, 1:2000, then in oxalic acid solution, 1:1000, then in *distilled* water. Examine on slide under microscope and repeat process as often as necessary. The further steps are as in Method A, beginning with (7).

The advantage of Method A is that it not only gives a strong stain, but also sharp differentiation. It can be greatly shortened, and good

results still obtained, by omitting step (3). Method B is to be used chiefly for staining cell processes. Both methods are especially successful after fixation in Zenker's fluid.

On microscopic examination, the cornea shows nothing of importance. The iris is considerably atrophied and below shows marked ectropion uveæ. Near its root, where it is adherent to the cornea and sclera, it is reduced to scarcely more than a line of pigment, and beneath the staphylomata only a trace of it remains. At one point it is adherent to the cornea and in retracting has formed an anterior synechia. Descemet's membrane, however, is intact at this point. The ciliary body and ciliary processes elsewhere than in the region of the tumor show simple atrophic changes. At the sites of the staphylomata the ciliary processes are carried forward, pressed together, and incorporated in the walls of the staphylomata. The lens presents the appearance of a traumatic cataract. Its fibers are widely separated, especially in the cortex, and the spaces filled with hyaline balls and granular material. "Bladder cells" are also to be seen. There is no proliferation of the capsular epithelium, but the latter shows degenerative changes. The choroid, retina, and optic nerve are normal.

The main body of the new growth is attached to the surface of the ciliary body, being supported by the greatly elongated ciliary processes and by a certain amount of connective tissue arising from them. In the sections it appears in the form of intricate convolutions enclosing lumina of various shapes and sizes (Figs. 3 and 4). The structures forming the convolutions are chiefly of two types, one type being derived by more or less gradual transition from the other. That which is evidently the primitive form consists of a single layer of columnar epithelium with oval vesicular nuclei, and differs from the normal unpigmented epithelium of the ciliary body only in staining more deeply. The convolutions of this kind are perhaps most numerous over the posterior surface of the ciliary body, and both here and over the ciliary processes they can often be traced into direct continuity with the normal unpigmented epithelium. In some places the latter simply changes its character without altering its position, so that the pigment epithelium is lined directly by the epithelium of the tumor (Fig. 2). In other places the new epithelium grows over the normal unpigmented layer. The other type of convolution is several cells in thickness, but strictly speaking is not stratified epithelium, since the cells are not arranged in parallel rows. The cell outlines are generally seen with difficulty, the appearance presented being that of a band the central two-thirds or more of which is closely packed with elongated nuclei, having their axes all perpendicular to the surface. One border of the band is sharply defined and beneath it there is a clearer zone in which no nuclei occur unless they are undergoing karyokinesis. In this zone the outlines of the cells are easily recognizable, giving it a striated appearance. The other border of the band is not sharply outlined, and next to it there is an ill-defined zone having a reticulated structure, in which the nuclei are fewer in number, smaller and more rounded in shape. The picture pre-

1

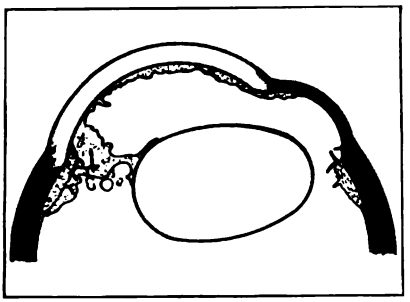

2

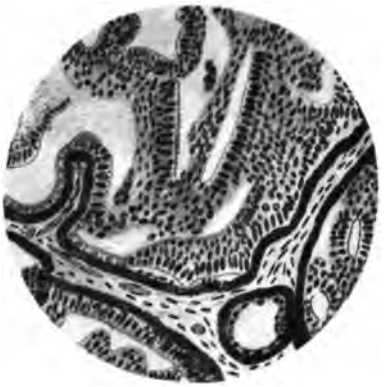

3

4

5

6

sented by this type of convolution, even in hematoxylin and eosin specimens, recalls at once that of an embryonic retina in an early stage of development. This type never arises directly from the normal epithelium, but always by transition from the simple columnar type.

That this band type of convolution really does represent different stages in the development of an embryonic retina is demonstrated beyond any manner of doubt by staining after Method B given above. After this method, if the differentiation is not carried too far, the individual cells are plainly brought out and are seen to correspond in every way to those of an embryonic retina. Fig. 5 shows the growth in this form over the posterior surface of the iris, where the bands attain their highest development, and Fig. 6 shows its detailed structure as brought out by special staining. The embryonic rods and cones, their nuclei and fibrils, are clearly shown. The cell processes which run toward the sharp margin of the band are always more deeply stained than those running in the opposite direction. The cells nearest the iris probably represent early forms of Müller's fibers.

As already noted, only one margin of the band type of convolution is sharply defined. This is true also of the simple columnar epithelium. In sections stained by Method A it is easily seen that the sharp margin is due to a definite fenestrated membrane (Fig. 7), similar to the membrana limitans externa and to the membrane in the pigment layer of the retina recently described by the writer.[4] When the membrane lies in the plane of the section, the openings in it are clearly made out. They are small, much smaller in the band convolutions than in the columnar epithelium, and hexagonal in shape. Into these openings the ends of the cells exactly fit without projecting through, in the case of the columnar epithelium, but in the case of the band convolutions, protruding beyond the membrane in the form of knob-like processes, the embryonic rods and cones. Besides these projections, the cells here and there end in large bulbous expansions, which are plainly granular, but which can be seen distinctly only when a small diaphragm is used in the microscope. These expansions evidently do not correspond to rods and cones. Similar appearances are to be seen in the ependyma of an embryo pig, and they are probably connected in some way with the process of cell division.

Near the center of each opening in the membrane and usually exactly on a level with it, there are always two dots, and occasionally four dots, to be seen (Fig. 7). The dots stain intensely in the neuroglia stain, and are extremely minute, so much so that it is impossible to make out their exact shape, but they do not appear to be quite round. They always occur close together in pairs, but occasionally one of the pair is not seen distinctly owing to its being obscured by the other. Sometimes the dots are so close together as to appear as short rods. Frequently the dots seem to be situated in an indistinct round body; possibly this is an optical effect. Very rarely, instead of the one or two pairs of dots there occur as many as fourteen pairs of very much larger dots. Sections stained in a simple aqueous solution (.5%) of acid fuchsin often show the dots and the membrane fairly well.

The margin of the epithelium which shows the membrane is never in contact with connective tissue, and in fact is usually perfectly free, lining a space or lumen. The lumina of this kind may contain apparently nothing, or they may be filled with coagulated serum, or more rarely, with tumor cells. It is only in those places where the epithelium of the pars ciliaris retinæ first becomes changed into tumor cells, or where the convolutions are massed together, that the membrane is in contact with other surfaces. On the other hand the opposite margin of the epithelium is almost always closely united with connective tissue, and it is this margin which faces the surface over which the tumor grows. It is, however, never in direct contact with the underlying surface, but is separated from the latter by a greater or less amount of loose connective tissue.

The lumina, too, formed when the diffuse margin is internal, are entirely different from those just described. In this case they are filled with fibrillated connective tissue not to be distinguished from vitreous humor. This has not simply been enclosed by the tumor, since the latter does not come in contact with the normal vitreous humor, but it is newly formed, and the stages in its formation can be easily traced. It is best brought out in sections stained by Mallory's connective tissue stain; Van Giesen's stain is far less satisfactory. In the small lumina, hyaline connective tissue can be seen entering their openings and filling the cavities. Soon after entering, the connective tissue changes its character, forming a loosely fibrillated tissue containing a few vacuolated connective tissue cells and leucocytes of different kinds. It is only occasionally that a blood vessel is met with in this tissue, and when one is found its walls are very thin, like those in the vitreous body of the embryo. In the larger lumina the tissue is still more fibrillated, and what is particularly striking, at the periphery it is condensed into a more homogenous layer, identical in appearance and staining reactions with the hyaloid membrane of the normal vitreous body. This hyaloid membrane is usually most fully developed in the larger globular bodies formed by a single layer of epithelium (Fig. 8). However, it is also present as a thinner layer in the lumina enclosed by the band-like convolutions.

As already noted, the lumina vary greatly in size and shape, but they always show a decided tendency to become round. The smallest ones, which are quite numerous, correspond in size to the rosettes of the so-called glioma retinæ, and are seldom formed by the simple columnar epithelium. The walls of the larger lumina, on the other hand, may consist of either type of convolution. Both the small and the large lumina are undoubtedly formed by a continuous growth of the convolutions, and there are probably no strictly isolated spherical bodies in the tumor like the rosettes of "glioma retinæ." The rosette-like pictures here in most cases represent small globular buds from the walls of the larger lumina, in which the fenestrated membrane is internal.

At some levels the growth is in contact with and has spread over the surface of the lens, eroding the capsule in places, but not infiltrating the lens substance. Near by and often upon the surface of the lens, the

growth undergoes a remarkable change in character, becoming converted into a meshwork of fibrils containing large cells. The cells are irregular in shape but have rounded outlines, present a homogeneous appearance, and often are continued into one or more long processes. Their nuclei are oval or round, and, as a rule, relatively small compared to the size of the cells. The fibrils are sometimes very fine, sometimes very thick, do not branch, and are free from nodosities. Even in hematoxylin and eosin specimens this tissue is easily recognized as neuroglia, but its nature is fully demonstrated by the neuroglia stain, Method A, which differentiates the fibrils in a most beautiful manner (Figs. 9, 10). In addition to this, they fail to stain by Weigert's elastic tissue stain, are colored red by Mallory's connective tissue stain, and yellow by Van Geisen's stain. It is noteworthy that the transition into neuroglia always takes place from the columnar or cuboidal epithelium, never directly from the thicker convolutions, and occurs where the growth extends far from its blood supply. In places, outgrowths of connective tissue are found coated with neuroglia in the same way as the lens capsule.

In addition to the form of neuroglia proliferation just described, there is another variety which consists simply of an aggregation of spindle and somewhat stellate cells among which there are few neuroglia fibrils. These cells are somewhat similar to the cells in the optic disc which were described, the writer believes incorrectly, by Nikolaï as muscle fibres. It is not possible to demonstrate by staining methods that these are glia cells, since the neuroglia stains are only differential for the fibrils, but they can scarcely be looked upon in any other light. In some situations their gradual transition into the cells of the distinct neuroglia formations is perfectly plain.

The epithelium forming the walls of some of the globular bodies, especially the larger ones in which the hyaloid membrane is well developed, differs somewhat from the columnar epithelium already described. The cells are lower, often somewhat globular, and stain more intensely in eosin. This change in character of the epithelium is no doubt the result of a lack of nourishment, since the walls of the globular bodies are entirely dependent for their blood supply upon the few vessels in the enclosed vitreous humor. A similar but more marked change is seen in other parts of the tumor, particularly near its surface where the columnar epithelium grows far from its base. Here the cells may even become elongated horizontally. Such an appearance is seen in places also beneath the staphylomata, and the epithelium usually takes on this character just before it passes into neuroglia tissue. Not infrequently this modified epithelium is found within a mass of connective tissue, or in the vitreous humor which fills some of the lumina, where the cells may take on the appearance of neuroglia cells.

Leaving the ciliary body, the growth anteriorly follows along the posterior surface of the iris, passing around the pupillary margin and growing for a short distance on the anterior surface. The whole upper half of the iris is lined in this way by the tumor, and on the temporal side the latter

extends for some distance beneath the staphyloma. Between the ciliary body and cornea, especially beneath the nasal staphyloma as already noted, the iris has almost disappeared and so that here the tumor is really growing upon the sclera. In places it grows as a uniform layer, sometimes in the simple columnar type, and sometimes in the band type. More often than not — in fact, always in the case of the band type — there is a certain amount of new-formed connective tissue between the growth and the underlying structures. In places the growth is heaped up in the form of nodules showing on a smaller scale the convoluted structure in the main body of the tumor. These nodules are particularly apt to contain the rosettes already described. In other places, after assuming the simple columnar type, the growth is transformed into comparatively large papillary projections composed almost entirely of neuroglia (Fig. 11). In one situation a very interesting formation is observed. This is a cyst-like structure formed by columnar epithelium and containing coagulated serum into the lumen of which a bud of neuroglia projects (Fig. 12). Another peculiar formation is produced by a layer of columnar epithelium growing over the layer of the band type and at intervals undergoing transformation into neuroglia. But perhaps the most interesting as well as the most instructive appearance of all is that illustrated in Fig. 5. Here the growth comes down in the band form over the posterior surface of the iris, passes around the pupillary margin and buds out as a perfectly globular body filled with vitreous humor. The hyaloid membrane is present in this structure but can be made out well only by an oil immersion lens. On the temporal side of the iris, where the growth is farthest from the parent tumor, it assumes the modified columnar type, but here, too, globular bodies are formed at the pupilary margin filled with vitreous humor showing a well-marked hyaloid membrane.

At certain places along the sclera the tumor shows a decided tendency to invade the underlying tissue. In no place, however, does the invasion extend very far, nor do the cells accumulate in such numbers as to form definite nodules. As a rule they are seen simply as lines, or double rows, of cells filling the tissue spaces. In every case the invasion is by direct continuity of growth, and there is no evidence of local metastasis by the lymphatics. In a number of sections the growth is seen in the iris stroma at the angle made by the junction of iris and cornea. Here it takes the columnar type and sometimes forms rosettes. Occasionally the growth is found growing not upon but within one of the ciliary processes, and in a few sections it is found invading the ciliary body itself.

The tumor is dependent for its blood supply upon the few vessels which accompany the connective tissue stroma. The latter, as already indicated, is derived chiefly from the ciliary processes and is not very abundant. The tumor cells in general grow upon the surface of this stroma, and not in it, just as they do upon the surfaces of the ciliary processes. It is from this stroma that the vitreous humor is derived which fills some of the globular bodies. No vessels are ever found in the convolutions themselves, as they are in the adult retina. Notwithstanding the

7

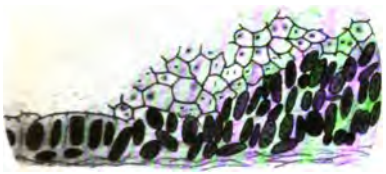

8

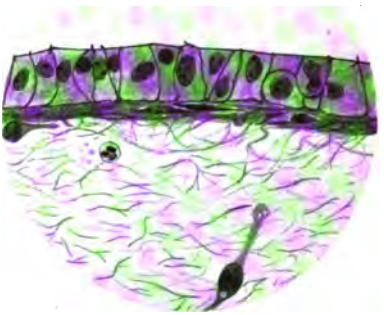

9

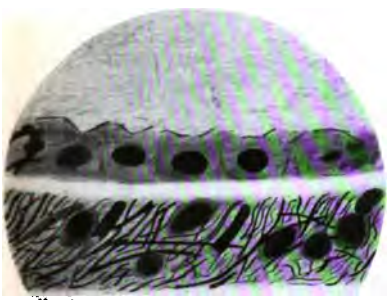

10



11

12

scanty blood supply there are no large areas of necrosis in the tumor, but along the periphery as well as between the convolutions there are many cells in various stages of necrosis. Only here and there are pus cells to be seen. Karyokinetic figures are everywhere abundant. They are apt to occur in the clear zone just beneath the fenestrated membrane, and in some instances it can be determined that one pole of the nuclear spindle occupies the position of the dots seen in the openings of the membrane.

The tumor cells in general are not pigmented, but now and then one of them is found packed with pigment. The pigment granules are always round, never rod-shaped, and are in all probability never formed by the tumor cells, but are simply taken up by them. They are evidently derived from the desquamated cells of the posterior surface of the iris and the pigment layer of the pars ciliaris retinæ. The pigment in every case is readily bleached by the method of Alfieri and does not give the iron reaction.

REMARKS.

That the tumor takes its origin from the unpigmented layer of the pars ciliaris retinæ is not to be doubted, since it can frequently be found in direct continuity with this layer and does not come in contact with the pars optica retinæ. It is a continuous growth of epithelium, sometimes taking the form of tubular or globular structures of various sizes, at other times lining a surface, notably the posterior surface of the iris, and is nowhere made up of a mass of cells without definite arrangement. In places the epithelium retains its primitive columnar or cuboidal character, while in others it undergoes more or less gradual transition into a thicker band-like layer identical with an embryonic retina (Fig. 6). Here an appearance is frequently presented similar to that seen in the embryo, where the change from the pars ciliaris retinæ to the pars optica retinæ occurs. In other places again, where the growth has extended far from its blood supply, it becomes converted into pure neuroglia (Figs. 9, 10, 11, 12). No matter how it varies in other respects, the epithelium always shows at or near one margin a definite fenestrated membrane corresponding to the membrana limitans externa of the normal retina (Fig. 7). The contents of the tubular or globular bodies differs in character according as the lumen is lined by this membrane or by the other margin of the epithelium. In the former case the contents consists chiefly of serum, and the resulting structure may be

regarded as corresponding to the primary optic vesicle of the embryo. In the other case, the contents invariably consists of vitreous humor, which presents a more or less highly developed hyaloid membrane. Thus here there is produced a structure analogous to the secondary optic vesicle of the embryo (Fig. 5).

The way in which these little optic vesicles come to be formed seems to be as follows: When, as for instance is shown in Figs. 3 and 5, the epithelium grows along a surface (the membrane then always being external), and at certain points takes on a more rapid growth, it must project out of line with the rest of the layer, and it can of course project in only one direction, namely, outwards. The tendency of the growth to do this is indicated by its undulatory form, as shown in the illustrations, and is clearly a manifestation of the law of unequal growth. Where the proliferation is especially active, a globular body or bud such as that seen at the pupillary margin would result. The formation of the vitreous humor in these bodies is due to the connective tissue which follows into their cavities, and its fibrillar character is probably dependent upon its deficient blood supply. On the other hand, when this budding process takes place in the more compact portions of the tumor, just as much external resistance would be met with in one direction as another, and the direction of the budding would be conditioned by the tension of the fenestrated membrane, so that the latter would be internal. A similar explanation was advanced by the writer to explain the form taken by the rosettes of glioma retinæ. The rosettes in this tumor, however, are more properly spoken of as pseudo-rosettes, since they are really small buds from the rest of the growth.

It will have been noticed that the description given of the formation of vitreous humor in this tumor is in accord with the classical ideas as to its formation in the embryo, and not with the recent views of Haemers (24) and others, who believe it to be derived from the neuroglia of the retina. By ordinary methods of staining it does seem in the embryo as if the delicate fibrils at the periphery of the vitreous body take their origin from the

retina; but Mallory's connective tissue stain shows definitely, both in the embryo (pig) and in the adult (human), that these fibrils are connected with the hyaloid membrane, and are sharply differentiated from the fibrils in the retina itself. Moreover, there are no fibrils in the vitreous body that stain by the neuroglia method.

The tumor is certainly malignant, though in how high a degree it is impossible to say. Its rapid growth, as indicated by the clinical history, the abundance of karyokinetic figures, and the invasion of the sclera, ciliary body, and ciliary processes, are sufficient proofs of this. No local, regional, or general metastases were found, however, so that the question as to whether or not the tumor is capable of forming metastases remains unanswered.

So far as the writer is aware, this is the first malignant tumor of the retina in which the presence of neuroglia has been positively demonstrated. However, neuroglia can hardly be regarded as an essential part of the tumor. It is always formed by a transformation of the simple columnar epithelium, and occurs where the blood supply is scanty. It is, therefore, probably in the nature of a degenerative change; but it is of interest in showing that the epithelium of the pars ciliaris retinæ can revert to the type of embryonic ependymal cells from which, in the brain, neuroglia is primarily derived.

In connection with the external limiting membrane of the normal retina, and the similar membrane displayed by the epithelium of this tumor, the writer has made a number of observations that will be published later. It will suffice to state here that such a membrane is not peculiar to nervous epithelium, but that it occurs in other forms of epithelium as well. In regard to the dots seen in the openings of the membrane, the writer has found that these, too, are to be found elsewhere than in the nervous system. Similar dots were first described by Weigert (5) in the normal ependyma of the brain, and were regarded by him as interruptions in a cuticular surface. Here they are always multiple, but have the same situation as in the tumor, occurring in the centers of the openings of a fenestrated membrane. Some observers have considered the presence of such dots in a

cell as an indication of its ependymal origin. Lewy (6) studied them in several gliomata of the brain, and concluded that they were centrosomes. Christian (7) found them in neuroglia cells of several teratomata removed from the ovaries. He also found somewhat similar dots in the sweat ducts and in the pancreas. These, however, may have been products of secretion. The writer has found that in the ependyma of an embryo pig 21 mm. in length, the dots everywhere consisted of single pairs in each cell except over the choroid plexus, where they were multiple. In the same embryo dots identical in appearance, having the same situation, and occurring in single pairs, were found also in the epithelium of the pharynx. In the adult they were found as single pairs in glands of the trachea. That they were not products of secretion is sufficiently clear from the fact that they were situated in the center of a fenestrated membrane, just as in the case of nervous epithelium. Careful observation seems to show that each pair or dots is situated in a small, round body; but this may be an optical effect. Similar dots in pairs were found by the writer in the smooth muscle cells of the ciliary body, situated just in front of the nucleus. In the case of the retina the writer has found multiple dots in the rods and cones, and also in the pigment epithelium. In the former structures the dots do not occur on a level with the membrane, but beyond it, being situated at each end of the ellipsoids of the cones and at corresponding levels in the rods. While the occurrence in a cell of a single pair of dots staining by the neuroglia method gives no clue to its origin, this can not be said of multiple dots, since the writer has been unable to find the latter elsewhere than in cells belonging to the nervous system. The occurrence of the double dots in cells of such different character would seem to accord with the view that they are centrosomes. However, the writer has been unable to determine that they play any part in cell division, although one pole of a nuclear spindle was frequently seen in the situation ordinarily occupied by the dots.

The clinical features of this case are not without some interest. The history of redness of the eye, which was noticed when the

eye began to enlarge, was no doubt the passive congestion of glaucoma, not an active inflammation. The short duration of the glaucoma was evidenced, not only by the clinical history, but by the absence of cupping in the optic disc. The blocking of the filtration angle by the iris and the formation of the intercalary staphylomata were, of course, secondary to the glaucoma. The cataract, as shown by the clinical history, was of recent formation, and no doubt due to the erosion of the capsule by the tumor, since it was typical of the traumatic type. It would seem that it ought to be possible to diagnosticate a case of this kind from its clinical aspect alone. The intercalary staphylomata, the brilliant white cataract of short duration, with dislocation of the lens, the clear cornea, and finally the small white globular bodies attached to the pupillary margin, seem to constitute a characteristic picture.

As to the nature of the tumor there can be no doubt. It is essentially that of an embryonic retina, in various stages of more or less orderly development. The little globular bodies, with their contents of vitreous humor, may even be regarded as abortive attempts to form eyes. While the occurrence of neuroglia is here, not in line with the regular sequence of retinal development, but, as just explained, is the result of pathological conditions, it at least serves to confirm the nervous origin of the growth. Since the tumor evidently does not belong to any class of tumors hitherto known a new name for it may be devised. To speak of it as a glioma would of course give no idea of its true nature. In its complexity of structure, its high differentiation, and the early period of life at which it occurs, it is more closely allied to the teratomata than to any other recognized class of tumors. However, it differs from them in its evident malignancy and in being of nervous origin, although the presence of mesoblastic tissue in the form of the specially differentiated vitreous humor is one of its striking features. The term terato-neuroma would seem to express very well the general character of the tumor, indicating a monster-like growth composed of nervous elements. This term, too, has the advantage of being applicable to tumors of similar nature which possibly may be met with elsewhere in the

nervous system. Exception may be taken to the term neuroma, on the ground that by the latter is usually meant a tumor composed of nerve fibres. The root "neur," however, is no longer restricted in meaning to nerves alone, but pertains to the nervous system in a more general way, as, for instance, is evidenced by the term neuro-pathology. Moreover, there is probably no true tumor made up of nerve fibers, unless the proliferation of nerves in a stump after amputation is to be regarded as such, so that strictly speaking this is perhaps the only tumor to which the term neuroma has ever been legitimately applied.* The term neuro-carcinoma was thought of; but, although the tumor is malignant, and of epithelial origin, it differs from the carcinomata in its high differentiation and in its evidently congenital nature.

Aside from the case of Badal (1) and Lagrange and that of Emanuel (2), both of which are given in detail below, the writer has been unable to find any cases which are unquestionably of the same nature as the one reported here. A case reported by Hirschberg and Happe (8), and another by Helfreich (9), were regarded by Emanuel as possibly similar to his own. The writer believes that Helfreich's case, at least, which was reported as a glioma, is almost without doubt a similar case; but neither of the two cases was adequately enough described to be of much value, so that it is necessary only to mention them. As Emanuel points out, the cases of Collins (10) and Robertson (11), reported as cases of carcinoma of the ciliary body, are plainly cases of sarcoma or endothelioma. In the writer's opinion the tumors were sarcomata, showing unusually well-marked alveolar structures. Schlipp (12) has described from Fuchs' clinic a remarkable tumor in a girl of 10 years of age, which completely filled the vitreous chamber, and which he regarded as an epithelial growth, arising from the pars ciliaris retinæ. It did not resemble either in the character of its cells or in its general structure the tumor described by the writer, and its nature is not clear. Possibly it was an endothelioma. Emanuel shows that the small tumors re-

*The term neuroma ganglio-cellulari verum, however, has been applied to a rare benign congenital growth which develops in the sympathic system and which contains both nerve fibres and ganglion cells.

ported as adenomata of the ciliary body by Pergens (13) and Alt (14), as well as the tumor described by Hanke (15), are to be regarded as senile excrescences, or as inflammatory growths. A case somewhat similar to that of Hanke has recently been reported by Parsons (16). In each of these two cases there was a small globular body attached to one of the ciliary processes. The description and illustration of the growth in Parsons' case almost exactly fit the small bud of neuroglia shown in Fig. 13, while the epithelium composing the growth described by Hanke was similar to that often found as a preliminary stage to the formation of neuroglia in the writer's case. Although, unfortunately enough, it was impossible to apply differential staining in these cases, it is not unlikely that they were really gliomata. They would thus correspond to the benign gliomata (or gliosis?) of the brain, and would form the only class of true gliomata retinæ ever described.

CASE OF BADAL AND LAGRANGE.*

Boy, aged 8 years. Family history unimportant. A short time after birth parents noticed that the child saw badly with the left eye, and that the pupil was dilated. The right eye had never shown anything abnormal. At five years of age, vision in left eye was entirely lost and eye began to enlarge. At time of operation, the eye appeared injected, prominent, and about one-fourth larger than the other. Cornea nearly normal, anterior chamber very deep, pupil widely dilated, media invisible with the ophthalmoscope. By oblique illumination pupillary area appears rose colored, but shows no vessels. Intercalary staphyloma size of bean above; below, a little larger one, with multiple embossment. Sclera very thin at level of staphylomata, which appear as vascularized masses probably formed by a neoplasm. Lymphatic glands show nothing. There is no great pain. The eye is red, watery, hard, very sensitive to light (?). Enucleation. No involvment of nerve or orbit.

Anatomical study. The eye appears as a thin empty shell. The lens and vitreous body spontaneously left the eye when the anatomical section was made, immediately after the operation. The lens showed a facet in the equatorial region large enough to lodge the tumor. Retina completely separated. Choroid in situ. Optic nerve normal.

The growth is situated exclusively in the ciliary region and consists of two little white nodules, unequal in size, placed one near the other. They reach from sclera to compressed lens. Largest nodule size of pea, other is one-third as large. The choroid stops at the base of the tumor

*The remarks in parentheses have been inserted by the writer.

and at its posterior limit. In front the iris is invaded; its large circumference and more than half of its tissue are involved in the new growth. Elsewhere, ciliary body is normal.

Microscopic examination. The tumor mass presents a highly irregular appearance: one sees numerous islets, unequal in size, and more deeply stained than the surrounding tissue. Even at this low magnification one distinguishes tubes with a central lumen. These tubes are especially abundant anteriorly; behind the tissue is more uniform. In this region posteriorly, one finds remains of the ciliary processes, and in front one likewise seen fragments of the iris. . . .

Fig. 3 is remarkable for the number of glandular canals it contains. It has without any doubt the character of an adenoma. A cylindrical epithelium lines the walls of the tubes, which are now rounded, now flattened by compression, or perhaps cut obliquely by the knife.

By the side of the tubes with large lumina, having but one layer of epithelium upon their walls, one finds a compact mass of elements, the form of which it is impossible with this magnification to distinguish, but which evidently have some relation to a segment of a tube of which one sees only the semicircumference. But — and this is a highly important point — the quantity of tubes which possess a large central lumen with a simple layer of cells is relatively limited; there are, on the contrary, a great number of others in which the epithelial cells have proliferated. (Evidently refers here to the thicker convolutions seen in the writer's case.) . . . As in the epithelioma intracanaliculares, the epithelial cells have lost their normal form; to employ the language of the pathological histologist, they have become metatypes. Finally, it is easy in many places to determine that under the stress of the internal cellular pressure the tube is broken, thus allowing its contents to invade the surrounding tissue. (Section of tube cut obliquely.) . . .

If now, with a magnification still greater, we seek to study the details of structure of the cells themselves, what do we find? They are irregular in their form, elongated, polyhedral, ovoid, with one extremity pointed; others, on the contrary, have several little mulitple nuclei. Many of them thus show the proof of their vitality and active proliferation.

By the side of these cells, which are derived without doubt from the cells contained in the tubes, there are others which are simple sarcoma cells; they are smaller, round, and are met with especially in the posterior part of the tumor.

CASE OF EMANUEL.

Boy aged 5½ years. Family history unimportant. From birth pupil of right eye had been elongated vertically. At age of 3 years was treated by an ophthalmic surgeon for pain and redness of eye, but it did not improve under treatment. Three months previous to time first seen at clinic, the eye began to enlarge. Examination shows cornea of right eye slightly turbid, and anterior chamber filled with blood. No fundus reflex. Pupil widely dilated. High grade ciliary staphyloma around the cornea except

inwards, most marked below. The eye is very tense. Moderate ciliary injection; no pain. Left eye normal. Enucleation. (Four years later the child was still alive and well).

Anatomical investigation. Large intercalary ectasia. Tumor 10*mm.* x 6*mm.* in size, growing beneath lower staphyloma and invading ciliary body and sclera. Lens cataractous and dislocated upwards. Retina completely separated, choroid also in great part separated. Tumor grows over iris as thinner and thinner layer but does not appear in anterior chamber except on nasal side, where it has grown between iris and cornea.

Histological examination. One sees band-like structures, arranged in multiple folds lying beside one another, now forming garland-like windings, now displaying complicated networks by manifold communications. From one band go out, arcade-like, other bands, with which it encloses a lumen. The bands consist of thickly set strongly staining long or round nuclei, which take up the greatest part of the middle of the band, leaving on each side a protoplasmic border of varying width, which in many places is not plain. By strong magnification one can see parallel lines running perpendicular to the margins, which probably are cell outlines. The margin of the cell bands is in places sharp through a refracting line, in many places, however, not sharp, and there go from the cell band little broad-based fine fibrils. This occurs where the protoplasmic border is reduced in width or has completely disappeared. (Fenestrated membrane cut obliquely.) Here one can also see pictures, where a cell nucleus projects half way out of the cell band. Other nuclei appear pushed against the margin. Here on the margin of the band appear also nuclei apparently attacked by regressive metamorphosis, whose contents and appearance are formed by strongly staining granules. (Karyokinetic figures.) Upon the surface of the cell bands lie cells which are more or less degenerated. Between the cell bands lie masses of little bright balls, among which there are degenerated cells, which are probably the forerunners of the homogeneous balls. Between the bands run very thin-walled simply-made vessels of various sizes. Upon one side, where the tumor is limited by a connective tissue mass, one sees fine vessels grow out which run into the cell bands. (Probably does not mean that the vessels actually penetrate into the epithelium.) The tumor thus constructed lies in an angle, one limb of which is formed by the pars ciliaris retinæ, and the other by the already-mentioned connective tissue mass.

At the foot of the ciliary processes the unchanged pars ciliaris retinæ goes over into a cell band consisting of many layers of strongly staining nuclei, which, on both sides, is accompanied by a bright border. This cell band is sharply defined on each side. At the point of transition the nuclei are more elongated, but soon give way to a more rounded shape. . . . The lumina differ in shape, being irregular, elongated, or round. They are distinguished from each other by their size — the larger are irregular, the smaller almost always round. In the case of the smaller lumina, the inner protoplasmic border is with greater regularity sharply limited than in the case of the larger. (This is one of the essential differences between the

primary and secondary optic vesicles described by the writer.) The protoplasmic border in the round structures is plainly radially striated. Within the lumina are cell nuclei in degeneration and hyaline masses. (Emanuel omits to mention the character of the contents of the other lumina, in which the writer found vitreous humor.) The thickness of the band surrounding the lumen varies to a certain degree with the size of the latter. In many places the lumina are so closely placed that the surrounding cell rows appear as a network; in others the intervening space is much greater, and is filled out with irregularly arranged less thickly lying nuclei, those of which lie immediately next the lumen being distinguished as cell circles by their thickset arrangement and their stronger staining. . . .

There occur here (lining the inner surface of the sclera) cell bands consisting of cylindrical cells lying beside one another, with broad protoplasmic border and sharper margins on both sides. These bands lose themselves in the uniformly distributed masses of round cells. We see here projecting from the sclera continuous masses of gland-like cell pouches which are formed of cylindrical cells. Where the tumor develops in the tissue of the ciliary body, or in the connective tissue, it is governed in its direction by the texture of the tissue. One sees between the separated tissue structure the tumor cells in long rows. However, there also occur the circularly arranged nuclei, which are smallest here and show a somewhat constant size. The thickness of the circle consists of only a few nuclear rows, lying one above the other. The circles occur seldom and do not form networks.

In places where single tumor cells are isolated, one sees that little protoplasm lies around the great nucleus, and that the cell runs out into a short pointed process towards one or both sides. . . .

At certain places where the cells enclose a lumen, one sees from the depth of the cell masses, the finest fibrils run toward the lumen and unite into a cluster. At such places the sharp margin fails. One has the impression as though these fibrils formed the limiting membrane of the cell bands. These fibrils are seen more plainly after Van Giesen and before all, after Mallory, in preparations stained with phosphomolybdic acid (hematoxylin). (It is possible that these were neuroglia fibrils, but it seems more probable that the appearance described was due to an oblique section of the fenestrated membrane.)

Lens, 6½*mm.* x 2½*mm.* Irregular in shape. . . . Capsule epithelium has proliferated. . . . Lens substance cataractous: bladder cells, albuminous balls, especially at cortex. The nasal border of lens is infiltrated with tumor cells, which push themselves in between the bladder cells. The capsule is here broken through. Slight calcification of central lens substance. Lens capsule is embedded in a connective tissue mass, whose meshes are filled with blood. . . .

The two cases just described are plainly identical in nature with the writer's case, and the tumors are hence properly to be

designated as terato-neuromata. In fact they correspond so closely to the latter case in all the details given that it seems altogether unlikely that they did not show the other features made out. It is probable that some of the features were overlooked, owing, partly, at least, to inadequate technique. Thus no mention is made of neuroglia, which was probably mistaken for connective tissue, nor of the presence of vitreous humor in some of the lumina. Although the limiting membrane was seen by Emanuel, its real structure was not made out, nor were the dots in its openings described. But most important of all, the character of the thicker convolutions, that of an embryonic retina, which is alone sufficient to determine the nature of the growths, was not recognized.

Badal and Lagrange* described their tumor as an adeno-carcinoma. Their conception, of course, was that the convoluted structure of the tumor was a manifestation of a normal tendency on the part of the pars ciliaris retinæ to become differentiated in certain places, and to grow downward in the form of glands, just, for instance, as in the case of the epithelium of the intestines. As a matter of fact, however, the unpigmented layer of the pars ciliaris retinæ, from which the tumor arises, shows no tendency to become differentiated in such a way, but simply undergoes gradual transition from the high columnar epithelium at the ora serrata to low cuboidal epithelium over the ciliary processes.

The so-called glands of Treacher Collins consist of down-growths from the pigment epithelium, and are of questionable significance. It is, of course, possible that the epithelium of the ciliary processes may have some influence on the formation of aqueous humor, but the evidence indicates that the latter is in the nature of a simple transudate. As already explained, the tubular structures in the tumors under consideration really correspond to primary and secondary optic vesicles of the embryo, and it is no more reasonable to consider them glandular formations than it is to look upon the latter as such.

* Lagrange (17) in the latest edition of his work on tumors of the eye still expresses the same views regarding the nature of this tumor, notwithstanding the objections raised by Emanuel.

Emanuel held the tumor in his case to be a glioma, because he regarded it as similar to the malignant tumors of the pars optica retinæ, which he accepted as true gliomata. The only points of similarity he mentions, however, are age of patient, structure of tumor — cells with large nuclei and little protoplasm, — and the occurrence of rosettes. The writer believes, on the contrary, that the features presented by any one of the three tumors are sufficiently outspoken as to show in themselves the true nature of the growths. On the other hand, the nature of the so-called gliomata of the retina is still in great dispute, so that any similarity to them the tumors of the pars ciliaris retinæ may show must be regarded as throwing light, not on the latter, but on the former. Moreover, as will be pointed out, the similarity is not so great as believed by Emanuel.

Ginsberg (18), after reviewing the two cases, accepts the diagnosis of adeno-carcinoma arrived at by Badal and Lagrange. In opposition to Emanuel's diagnosis of glioma, he points out that neuroglia was never produced in the tumors, and that the neurogliar nature of the pars ciliaris retinæ is not proven. The writer's case, however, shows that neuroglia can be produced in such tumors, and from epithelium corresponding to that of the pars ciliaris retinæ. Nevertheless, as already conclusively shown, these tumors are neither adeno-carcinomata nor gliomata.

THE RELATION OF THE TERATO-NEUROMA TO THE SO-CALLED GLIOMA RETINÆ.

It would naturally be expected that tumors of the pars ciliaris retinæ, arising as they do from cells which genetically are the same as those of the retina proper, would offer some clue to the nature of the tumors occurring in the latter. The writer believes this to be actually the case, though perhaps as much information is afforded by the dissimilarity of the tumors in the two situations as by their points of resemblance. Emanuel, as already mentioned, considered the tumor described by him and the so-called glioma retinæ so much alike that he classed his tumor as a glioma. In certain respects, however, the two tumors are

strikingly different. In glioma retinæ the growth is composed of masses of cells, sometimes containing here and there rosettes, but otherwise forming no definite structures such as the convolutions and globular bodies (optic vesicles) in the tumor of the pars ciliaris retinæ. Nor do they ever contain columnar epithelium, or show transformation into neuroglia. The character of the nuclei, too, differs: in glioma retinæ they are usually round or slightly oval, while in the other tumor they are almost always elongated. As already pointed out, the rosettes in the tumor of the pars ciliaris retinæ do not correspond to those in glioma retinæ, since they are produced by buddings from the convolutions, while those of the latter tumor are in a sense isolated structures. They also do not represent such an advanced stage in the embryological development of neuro-epithelium.

But notwithstanding these important differences, the writer believes the two tumors to be closely related. In the first place it can be regarded as certain that the malignant tumors of the retina are not gliomata. As stated in a previous paper (4), the writer has found it impossible to demonstrate glia fibers in tumors of this class by Mallory's neuroglia stain. It can not be urged that neuroglia under pathological conditions will not stain by this method, since the latter has been successfully applied to gliomata in other situations and also in the tumor just described. Moreover, neuroglia is not difficult to stain and to recognize by other methods not differential; but even these fail to show it in the tumors under discussion. Greeff (19) and Hertel (20), it is true, found spider cells by the Golgi method; but the latter is noted for giving misleading pictures. Finally, the tumor described by the writer indicates that neuroglia if present would be produced by transition from simple columnar epithelium, whereas the so-called glioma retinæ contains no such epithelium.

On the other hand, the view first advanced by Flexner (21), and later by Wintersteiner (22), that the tumors are neuro-epitheliomata, is also insufficiently grounded.* The rosettes, how-

* Wintersteiner (23) in his monograph gives altogether too little credit to Flexner whose views he adopted and who was the first to propose the term neuro-epithelioma. This is evidenced by the fact that in Europe Flexner's work on the subject is generally ignored.

ever, upon the occurrence of which their conception was based, often correspond more closely to the adult neuro-epithelium of the retina than was recognized by either of these observers. The writer has shown that the limiting membrane in the rosettes is identical in structure with the membrana limitans of the normal retina, and that the projections through it may take on the exact morphology of cones. More recently, the writer has found that these projections contain multiple dots situated beyond the limiting membrane, something which is met with in the normal retina only in an advanced stage of development. Nevertheless, from these facts alone it is obviously unjustifiable to consider the tumors neuro-epitheliomata, since rosettes occur in only about one-third of the cases and usually form only a small part of the tumor. Wintersteiner believed that the other cells which make up the bulk of the tumor represented a lower order of differentiation than those forming the rosettes; but embryology shows that the external layer is not differentiated from cells similar in appearance to the tumor cells in question. The cells from which the rods and cones develop show a limiting membrane from the very beginning. Thus, in the tumor described above, the primitive retinal epithelium is represented by a single layer of columnar cells bounded on one side by the limiting membrane.

It is evident, therefore, that the key to the nature of the so-called glioma retinæ is to be found in the character of the cells which do not take part in the rosette formations. They are usually described as round cells, with little protoplasm, and by ordinary methods of staining they do appear as small, round cells, resembling lymphocytes; but the writer is convinced that this is not their real form. In a tumor recently examined, even in hematoxylin and eosin specimens, the cells were plainly seen to be similar to the bipolar cells of the adult retina, having a delicate process at each end. The processes were often quite long, stained only faintly, and their endings could not be made out. Sometimes one process would appear to join another cell. The tumor contained rosettes in great numbers, and in other respects did not differ from the ordinary glioma retinæ. In at least three

other tumors the writer has been able to make out numbers of cells with such processes, but has been unable to find any stain which would show that the majority of the cells were of this character. Often one of the processes would be stained for a short distance, and then gradually or suddenly become invisible. Similar cells have also been noted in glioma retinæ by others. The writer is therefore convinced that the bipolar cells are the predominating and characteristic elements in these tumors, but that ordinarily it is impossible to stain the processes.

That these bipolar cells do not correspond to the cells of the external nuclear layer of the retina is almost certain, since they are not connected with a limiting membrane; and that they are well advanced in development is evidenced by the shape of the nuclei, which are round or at most only slightly oval. They probably correspond to the cells in the inner layers of the embryonic retina at a stage previous to the complete differentiation of the inner nuclear layer. It is noteworthy that in the embryo the processes of these cells are almost as difficult to stain as in the tumor. Including, then, the cells of the rosettes, all of the elements of an embryonic retina would be represented in the tumor. It is conceivable, of course, that adult multipolar ganglion cells and also glia cells might occur, but the writer has never been able to demonstrate their presence.

According to these observations, the tumor ordinarily known as glioma retinæ is really composed of nervous elements in an embryonic state, and is hence entitled to the designation "neuroma." The term neuroma retinæ malignum would seem to indicate the important features of the tumor that can be regarded as at present established. While the terato-neuroma of the pars ciliaris retinæ, and the neuroma malignum of the pars optica retinæ, are both of nervous origin, they show just such differences as might be expected between a tumor which springs from an undifferentiated portion of the retina and another which arises in a portion of the retina that has undergone differentiation in the highest degree. Thus the latter differs from the former in presenting higher though fewer stages in embryonic development,

and in not retaining so perfectly the normal relationship of the cells. These differences are fairly well brought out by omitting the prefix "terato" in the case of the tumor of the pars optica retinæ. However, it does not seem impossible that there might develop in the pars optica retinæ, from cells which perchance have remained undifferentiated, a tumor that would possess the distinctive features of a terato-neuroma.

CONCLUSIONS.

(1) From the unpigmented epithelium of the pars ciliaris retinæ there may rarely arise a tumor which exhibits the structure of an embryonic retina in various stages of development.

(2) This tumor is malignant, but in how high a degree is uncertain.

(3) It is the only retinal tumor in which neuroglia has been demonstrated to form an integral part, but nevertheless it is not a glioma.

(4) It is not to be confounded with the small benign epithelial growths that have sometimes been described as adenomata of the ciliary body.

(5) On account of its complexity of structure, its high differentiation, and its nervous origin, this tumor is properly designated as a terato-neuroma.

(6) The so-called glioma retinæ, while differing from this tumor in many important respects, is yet of the same nature, in so far as both tumors are composed of embryonic retinal elements. The chief difference between the terato-neuroma of the pars ciliaris retinæ and the neuroma malignum of the pars optica retinæ, lies in the fact that the latter represents throughout a less typical, though higher retinal development, than is anywhere reached by the former.

REFERENCES.

(1) Badal and Lagrange. Carcinome primitif des procès et du corps ciliare. Arch. d'opht., 1892, Vol. 12, p. 143.

(2) Emanuel. Ein Fall von Gliom der Pars ciliaris retinæ. Virchow's Archives, 1900, Vol. 161, p. 338.

(3) Mallory. A contribution to staining methods. Journal of Experimental Medicine, 1900, Vol. 5, p. 15.

(4) Verhoeff. A hitherto undescribed membrane of the eye, and its significance. Royal London Ophthalmic Hospital Reports, 1903, Vol. 15, p. 309.

(5) Weigert. Bemerkungen über das Neurogliagerüst des menschlichen Centralnervensystem. Anat. Anzeiger, 1890, Vol. 543.

(6) Lewy. Ueber Centralkörperchen in Gliomen. Virchow's Archives, 1903, Vol. 171, p. 236.

(7) Christian. Neuroglia tissue and ependymal epithelium in teratoid tumors. Jour. Amer. Med. Assoc., Sept. 5, 1903.

(8) Hirschberg and Happe. Ueber einige seltenere Augengeschwülste. V. Graefe's Archiv., 1870, Vol. 16, p. 297.

(9) Helfreich. Beitrag zur Lehre vom Glioma retinæ. V. Graefe's Archives, 1875, Vol. 21, p. 236.

(10) Collins. Researches into the anatomy and pathology of the eye. London, 1896, p. 68.

(11) Robertson. Carcinoma involving iris and ciliary body. Ophth. Review, 1895, Vol. 14, p. 374.

(12) Schlipp. Ueber einen epithelialen Tumor des Ciliarkörpers. V. Graefe's Archives, 1899, Vol. 48, p. 353.

(13) Pergens. Ueber Adenom des Ciliarkörpers als Ursache von Glaukom. Archiv. für Augenheilkunde, 1896, Vol. 32, p. 293.

(14) Alt. Adenoma of the ciliary body springing from the pars ciliaris retinæ. Four cases. Amer. Journal of Ophth., 1898, Vol. 15, p. 321, —— Another case of adenoma of a ciliary process. Ibid, p. 363. —— On intraocular epithelial new formations. Ibid, 1902, Vol. 19, p. 97.

(15) Hanke. Zur Kenntniss der intraocularen Tumoren, V. Graefe's Archives, 1899, Vol. 47, p. 474.

(16) Parsons. Epithelial hyperplasia of a ciliary process. Royal London Ophthalmic Hospital Reports, 1903, Vol. 15, p. 375.

(17) Lagrange. Traite des tumeurs de L'Oeil. Paris 1901, Vol. 1, p. 730.

(18) Ginsberg. Grundriss der pathologischen Histologie des Auges. Berlin, 1903, p. 186.

(19) Greeff. Der Bau und das Wesen des Glioma Retina, Deutsche med. Woch., 1896, Vol. 22, p. 327.

(20) Hertel. Ein Beitrag sur Kentniss des Netzhautglioms. Klin. Monatsbl. f. Augenheilk., 1897, Vol. 35, p. 323.

(21) Flexner. A peculiar glioma (neuro-epithelioma ?) of the retina. Johns Hopkins Hospital Bulletin, 1891, p. 115.

(22) Wintersteiner. Uber Bau, Wachstum und Genesis des Glioma Retinæ. Wiener klinische Wochenschrift, 1894, No. 27, p. 493.

(23) Wintersteiner. Das Neuroepithelioma Retinæ. Franz Deuticke, 1897.

(24) Haemers. Regeneration du corps vitre'. Archives D'Ophthalmologie, 1903, Vol. 23, p. 103.

DESCRIPTION OF PLATES.

1. Diagram showing tumor (dotted surface) in greatest cross section at a level considerably higher than the pupil.

2. Drawing showing the tumor in continuity with pars ciliaris retinæ. The epithelium is in many places cut obliquely. Zeiss, Obj. DD, Oc. 4.

3. Photo. X 38. Showing attachment of tumor to ciliary body and processes. The convolutions are so thickly set that the lumina are not readily seen.

4. Photo. X 70. Below there is a globular body (secondary optic vesicle) formed by the thicker epithelium and filled with vitreous humor. Above two similar bodies are being formed. The large space to the left is surrounded by modified cuboidal epithelium and is filled with vitreous humor. The large lumen on the right is lined by columnar epithelium and filled with serum. Numerous rosette-like formations are to be seen in the more solid portion of the growth.

5. Photo. X 44. Showing thicker epithelium coming down over posterior surface of iris and budding out near pupillary margin as a globular body filled with vitreous humor (secondary optic

vesicle). The hyaloid membrane is present, but cannot be made out in the illustration.

6. Showing detailed structure of thicker epithelium as made out by special staining. The membrana limitans externa and the embryonic rods and cones with their nuclei and fibrils are clearly seen. Zeiss, Obj. 1/12, Oc. 4.

7. Showing fenestrated membrane. On the right it is cut obliquely, the hexagonal openings thus being brought to view. In each opening are one or two pairs of dots. (A similar membrane with smaller openings is present also in the thicker epithelium.) Zeiss, Obj. 1/12, Oc. 4.

8. Wall of large globular body formed by modified columnar epithelium (atypical secondary optic vesicle). The hyaloid membrane beneath the epithelium sends fibrils into the vitreous humor. Zeiss, Obj. 1/12, Oc. 4.

9. Layer of neuroglia stained by differential method, growing over surface of lens capsule. Zeiss, Obj. 1/12, Oc. 4.

10. Photo. X 500. Neuroglia near lens, stained by differential method.

11. Photo. X 86. Papillary outgrowth from columnar epithelium, composed chiefly of neuroglia.

12. Photo. X 225. Small bud of neuroglia, projecting into a cyst-like structure formed by columnar epithelium.

THE IMPORTANCE OF TESTING THE OCULAR MUSCLE BALANCE FOR NEAR AS WELL AS FOR DISTANT VISION.

By SAMUEL THEOBALD, M.D.,

BALTIMORE, MD.

With increasing experience in dealing with asthenopic eyes, I am more and more impressed with the importance of making in every such case a careful test of the muscle balance for near, as well as for distant vision.

Although in recent years so much attention has been paid to anomalies of the ocular muscles, the significance of the muscle

balance in near vision does not seem to have received the recognition which its importance demands. The fact that there is often marked discordance between the behavior of the muscles in distant vision and in near vision appears not to have impressed itself upon systematic writers upon diseases of the eye; and, indeed, it is evident that not all of them are informed as to what is the normal behavior of the muscles when tested for the reading distance.

What constitutes orthophoria in distant vision everyone knows; but, in spite of the fact that it was long ago pointed out, everyone, it would seem, does not know that, as determined by the vertical diplopia test, the normal state at 12″ or 13″ is an exophoria of 2° or 3° or even of 4°, and that a muscle balance which in distant vision indicates orthophoria is indicative really of a heterophoric condition when found at the reading distance.

In my papers upon "Subnormal Accommodative Power,"* I have emphasized this point, and have also set forth what, as I view it, is the peculiar significance of esophoria which is present in near vision only, or which is more pronounced in near than in distant vision.

The results which I have obtained in this condition, to which I gave the name subnorfnal accommodative power, by following the rules laid down in my papers — prescribing at times for young asthenopic emmetropes convex glasses of considerable strength for near work, and for young hypermetropes stronger glasses for near than for distant vision or combining with their near lenses esophoric prisms — have been so eminently satisfactory that this practice is now as much a matter of course with me as the correction of astigmatism or of hypermetropia itself.

The opposite condition, in which there is present a considerable amount of actual exophoria at the reading distance, with normal muscle balance in far vision, a condition by no means rare, is of scarcely less importance, and calls as emphatically for glasses especially adapted for near work, that is to say, for lenses which, in addition to correcting such refractive error as may be present, take into account the muscular fault.

* Trans. Am. Ophthalmolog. Soc., 1891 and 1894.

Occasionally, in dealing with this condition of discordance between the far and near muscle balance, and having in mind the convenience of the patient, I prescribe bifocal lenses; and, when they see one of my, perhaps, fifteen or sixteen-year-old patients thus equipped, some of my brother oculists are doubtless not a little surprised.

It is not my present purpose, however, to dwell upon these differences of lateral muscle balance to which I have alluded. It was the observation recently of several cases of hyperphoria, which was present in near vision only, and which proved to be an important factor in the causation of the asthenopic symptoms, that prompted me to write this paper.

Thanks to Maddox, we are able now to detect the existence of hyperphoria, and to determine its degree, much more easily and exactly than was formerly possible. With the aid of his multiple rod, and with the further assistance of Dr. Schild's well-contrived little electric light,* which I have the pleasure of showing you, I now find it no hardship to test for this defect in near as well as in distant vision. And the outcome of this is that I have learned that differences exist between the vertical muscle balance in far and in near vision much oftener than I had supposed. Indeed, I have not only found cases such as I have mentioned, in which hyperphoria was present in near vision only, but I have met with a few instances, not, however, marked in degree, in which there was hyperphoria in one direction in distant vision and in the opposite direction in near vision — a right hyperphoria, for example, at 20′ and a left hyperphoria at the reading distance.

I am, therefore, as I said at the outset, more than ever convinced of the importance, in every case of asthenopia, of testing the muscle balance for near vision. Frequently this test shows nothing that is significant; but, on the other hand, it occasionally reveals a fault which must be taken into account if our patient is to obtain complete relief.

I may add, in conclusion, that in determining the balance of the muscles in near vision I use the simplest contrivances — for

* Described in the Ophthalmic Record, June, 1904.

the vertical diplopia test, a prism of 7° taken from my trial case, and upon a card attached to a rod 12″ in length a small object calculated to stimulate accommodation, such as an asterisk; and for discovering hyperphoric faults, a multiple Maddox rod with a Schild electric light. The Schild light, if one wishes, may be used instead of the asterisk in the vertical diplopia test; but I do not feel quite sure that it prompts the patient to accommodate as accurately as the asterisk does.

The employment of these tests, which usually give entirely trustworthy results, requires but a very few moments, and the information which they afford is, I am sure, much too valuable to be ignored.

DISCUSSION.

Dr. W. C. Posey, Philadelphia.— Some years ago in a study upon a large number of cases to detect hyperphoria, my findings in regard to the near muscle balance quite agreed with those found by Dr. Theobald. In addition, however, I found that the muscle balance at five meters was not the condition of so-called orthophoria, but one of esophoria ranging from about 2° to 3°; and at 35 centimeters an exophoria ranging from 4° to 5°. I have found the taking of the near muscle balance of particular value in anomalous cases where there is exophoria at the far point and esophoria at the near; in these cases I have been accustomed frequently to give the full correcting glass for near — sometimes with prisms base out, in addition to the ordinary lenses for distance. I believe that the muscle balance should be taken in every case at the reading distance, as it is of great value and advantage in prescribing the proper glasses.

Dr. C. H. Williams, Boston.— In regard to the use of the Maddox rod for this test, I think there is one practical difficulty for both distance and near, which I find in using it and in comparing it with other methods; it is this: if you have a point of light across the room and use the Maddox rod you get a very good test, but there is a tendency of the eyes to bring the point of light and the line of light together; in other words, you get a different amount of exophoria, or esophoria, or hyperphoria with this test from that given with a test where there is no tendency for the eyes to turn so as to bring the retinal impressions from each eye on corresponding parts of the two retinæ. The test

which I showed the society some years ago, in which one eye looks through a red glass and the other through a green one, one eye seeing only a series of red lines through the red glass and the other only a series of green figures through the green glass, avoids that difficulty. When the red lines and the green figures are seen crossing each other at right angles there is no tendency for the eyes to bring the red line over any particular green figure on the line of figures, and if the red line is seen between 1 and 2 we know that there is no appreciable amount of deviation of the axes of the eyes from normal, in the horizontal meridian. Again, if the illumination is changed to show the red line horizontal and the line of green figures vertical, we get a test for deviation in the vertical meridian. When the vertical red line and the vertical line of green figures are shown together (as in the test for torsion) we often find that less ex- or esophoria is shown than by the first test, for there is a tendency for the eyes to turn so as to bring these vertical lines together; as in the Maddox test, they bring the vertical line and the point of light toward each other. In a smaller apparatus which I have used for the reading distance, constructed on the above principle, better results seem to be obtained than with the ordinary tests.

DR. ALEXANDER RANDALL. — This subject is one of great practical value and I made a remark in relation to it in discussing Dr. Dixon's paper. But, it seems to me that we must never forget (and there is always a little danger that we may) the question of the total refraction of the eyes and how these lines are strongly influenced by it. We have to deal essentially with the question of the region of relative accommodation and convergence, and we must not forget the habitual hypermetropia of the average eye. The question Why doesn't every hypermetrope squint has this same answer — we have a region of accommodation and convergence, and overtaxing it, we acquire a slight divergence. .

DR. THEOBALD.— Just a word in closing in reply to Dr. Williams — I am strongly inclined to agree with him that the Maddox rod test gives us sometimes faulty results when we are testing the lateral muscles, but I do not think there is the same difficulty in testing the vertical muscles. There is not the same tendency there to blend the images. I am inclined to agree with him, however, as to testing the lateral muscles, and, for that reason I

use the vertical diplopia test in measuring faults of these muscles. Dr. Randall has kindly " let me out " in suggesting the importance of taking into account the refractive errors. I do not think I can be accused of neglecting them.

DR. HIRAM WOODS. — I should like to ask Dr. Theobald a question in line with his paper upon " Subnormal Accommodative Power in Young Persons," presented to this society several years ago. The diagnosis was made when the NEAR balance showed a greater amount of esophoria than existed at twenty feet. Of course, such balance tests are taken only after refraction correction and with correcting glasses on the patient. Does Dr. Theobald regard this condition, when found in young persons who have never worn correcting glasses, as indicating the immediate need of spherical lenses for near in addition to the glasses correcting their error for distance, or has he seen the muscular imbalance straighten itself out after glasses correcting distance error have been worn for some weeks? I think the clue to weakness of accommodation given by this comparative test of distance and near balance of great practical value; but, particularly in cases of hitherto uncorrected astigmatism, I am not disposed to give spherical correction for near until some time has past. I have seen the normal relation between distance and near balance established with no other treatment than correction of static refraction, though at first there was an excess of near esophoria.

DR. THEOBALD.— I think that what Dr. Woods suggests sometimes happens, undoubtedly, but if I have a marked case of subnormal accommodative power I do not trust to its straightening itself out. We all know, however, how muscular faults may change. I have been called upon to give prisms to correct exophoria, for instance, and twelve months later have found that there was no indication for them and have withdrawn them. But, as a rule, the subnormal accommodative cases do not behave in this way.

A striking example of subnormal accommodative power may be found in any patient who has not fully recovered the accommodative power after the use of a mydriatic. If you test the muscle balance for near, you will get what I have called subnormal accommodative power. The patient will show no exophoria or, perhaps, slight esophoria in the near, yet if you repeat the test ten days afterwards you will get the normal exophoria.

OBSERVATIONS OF A CASE OF BITEMPORAL HEMIANOPSIA WITH SOME UNUSUAL CHANGES IN THE VISUAL FIELDS.

BY CLARENCE A. VEASEY, M.D.,
PHILADELPHIA, PENN.

The following case of bitemporal hemianopsia has seemed to the writer to present some unusual features of sufficient interest to merit its isolated report.

G. P. S., a married traveling salesman, 34 years of age, consulted me first on May 27, 1903, and presented the following history: His general health had always been excellent and his appearance so indicated, as he was about six feet in height and weighed about 170 pounds. There was no history of any ocular trouble in his family, and though he began to wear glasses at 16 years of age, for a low compound hyperopic astigmatism, his eyes had given him no trouble except the headaches, which the glasses had corrected. Early in January, or six months before I first saw him, there had gradually appeared a "fogginess" of the temporal half of each field of vision, which, he thinks, was noticeable in the right eye before it was observed in the left. He placed himself under the care of a homeopathic oculist, who gave him as much as fifty grains of iodide of potassium three times a day, and this dose he had been taking for some months. Specific history was denied and there were no other symptoms to cause its presence to be suspected. The urinary and blood examinations were negative.

Ophthalmoscopically, all the fundus details were normal and have continued so to the present time. There is no blurring of the disc edges nor pallor of the nerve heads in any part. The fields of vision taken at the time of my first examination (May 27, 1903), showed bitemporal hemianopsia with the light sense still preserved in the hemianopic halves. (Fig. 1.) The divid-

ing line was almost vertical in the right eye and passed directly through the fixation point, the patient stating that the round ivory disc in the center of the perimetric arc appeared as a semicircle. In the left eye the dividing line was inclined slightly to the right in the upper portion, and the fixation point was included in the preserved half of the field. Vision equaled 6/30, eccentrically, in the right and 6/15 in the left eye, but with both eyes 6/7.5 could be read slowly.

The visual fields, taken at frequent intervals, continued in practically the same condition until June 19th, a period of a little more than three weeks. On this date there was absolute hemianopsia in the right eye, the dividing line passing slightly to the right of the fixation point, the light sense being still preserved in the left. On June 22d the light sense had returned in the former blind portion of the right eye, and the dividing line passed nearly 5° to the right of the fixation point, affording normal visual acuity. In the left eye the light sense was preserved only in the outer half of the temporal field. (Fig. 2.) During inhalation of amyl nitrate the fields cleared greatly, the patient being able to count fingers, distinguish objects (lead pencil, bottle, hand, etc.,) in the portion of the fields in which the light sense was preserved, though the "fogginess" remained. On July 11th the temporal field of the right eye was absolutely hemianopic, the fixation point now being in the blind field; and in the left the light field was still preserved.

On August 8th there was found a very great change. In the right eye only the upper inner quadrant of the field was preserved, the remainder having lost all visual sense; and the dividing line passed about 2° to the left of the median line and fixation point. In the left eye light perception was still preserved in the outer field; but the dividing line now passed about 10° to the left of the fixation point, and beyond this was an area 3° wide in which form and color could be distinguished, though hazy; in other words the area was relatively scotomatous. (Fig. 3.) Vision in the right eye now equaled 3/100 eccentrically; in the left 6/6.

No.____

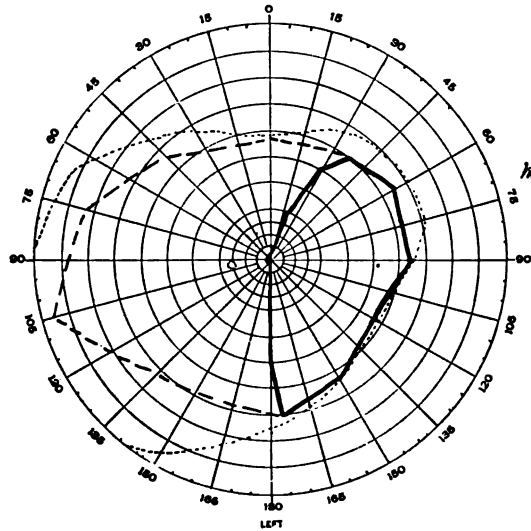

May 27. 1903.

Fig 1

No.____

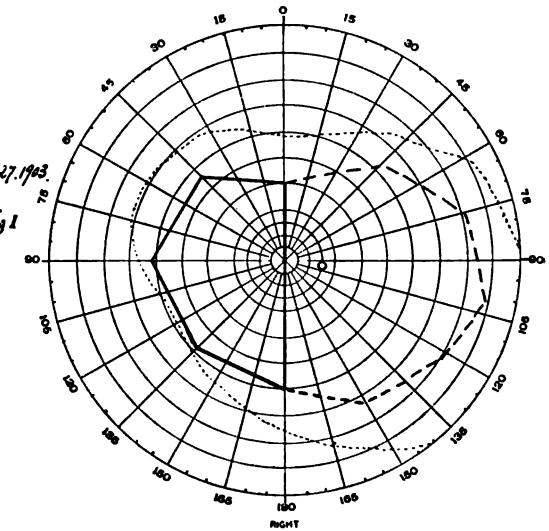

No._____

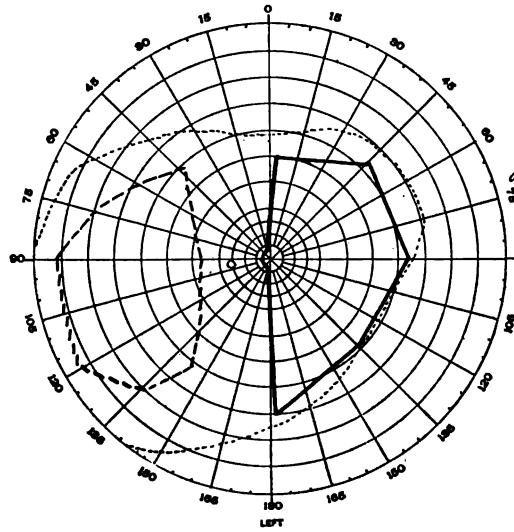

Jun. 22. 1903.

Fig 2.

No._____

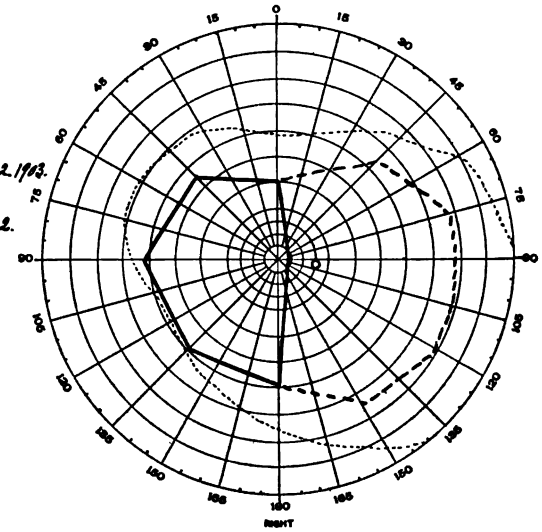

No. ____

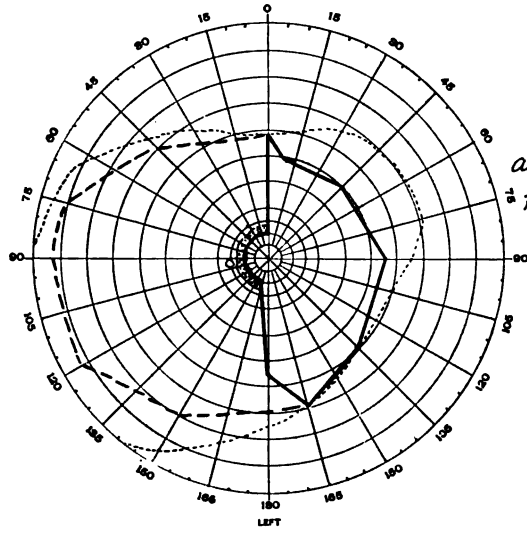

Aug 8. 1903
Fig 3

No. ____

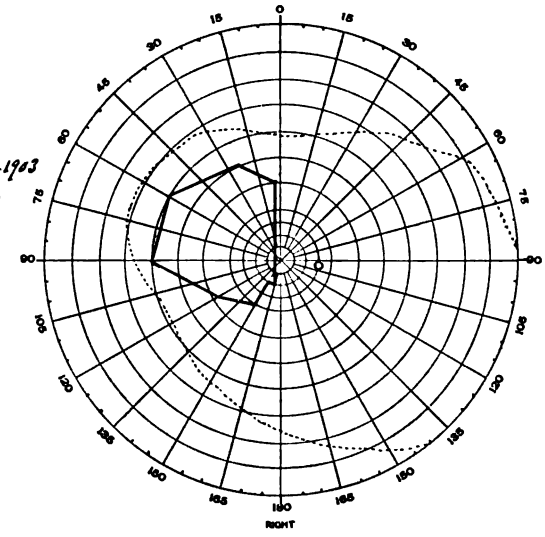

No.____

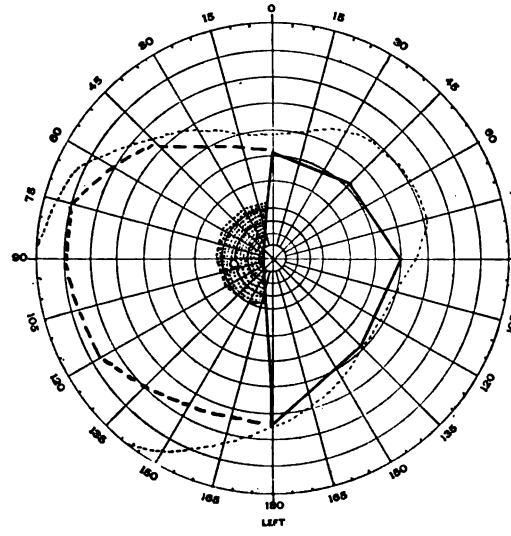

Oct-10 1903

Fig 4

No.____

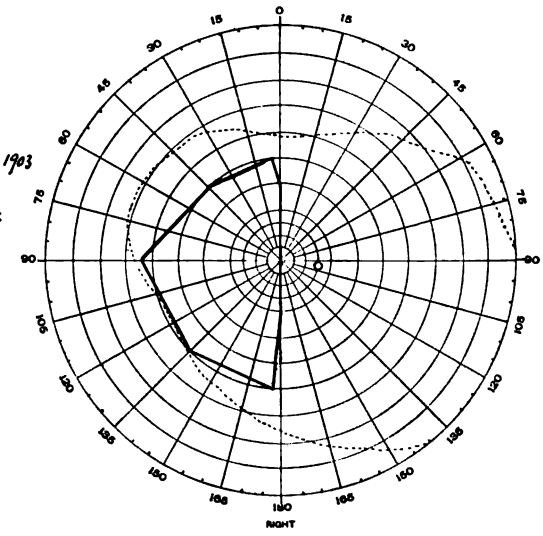

No. ___

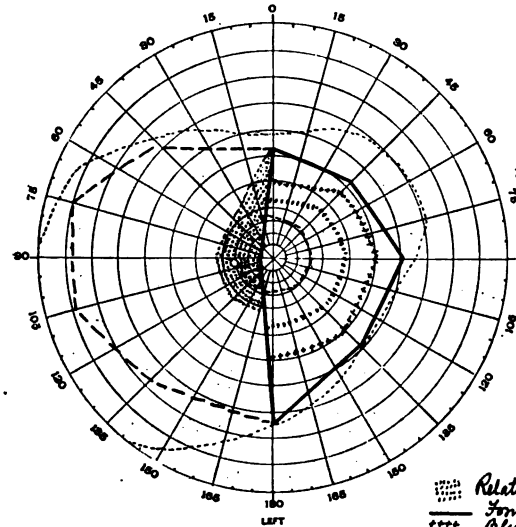

Feb. 22. 1904

Fig 5

No. ___

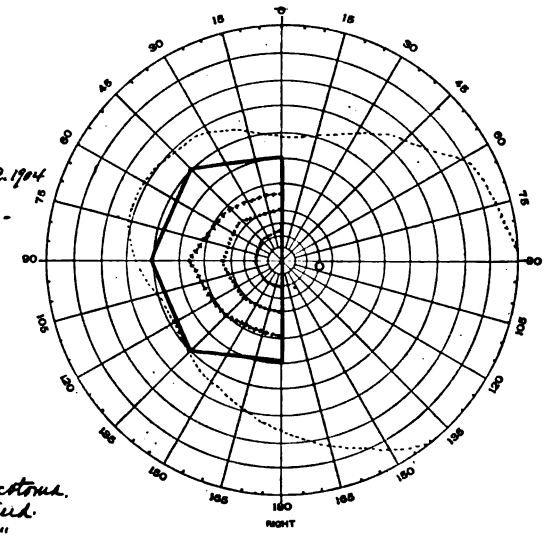

Relative scotoma.
Form field.
Blue "
Red "
Green "
Light "
Test object 1 cm. square.

On October 10th the lower quadrant of the right field, that had been lost at the time of the last examination, was entirely restored. The dividing line passed through the fixation point, and vision equaled 6/22.3, slightly eccentrically. Vision in the temporal half remained totally abolished. The field of the left eye showed form perception in a larger area than before, light perception being still preserved in the outer half. (Fig. 4.) Since this time, a period of nine months, there has been but little variation in the character of the fields at any examination. At the present time about the only change from the examination just described is that the relative scotoma in the left eye is slightly larger, meaning restored vision in a larger portion of the former blind field. The light sense is still present in the left, but lost in the right temporal field. (Fig. 5.) The vision in the right eye is 6/12, eccentrically, and in the left 6/6.

A skiagraphic examination of the brain of this patient shows a distinct shadow in the region of the chiasm. In presenting this skiagraph, I fully realize the skepticism regarding skiagraphy of cerebral lesions, even when of large size, and the method has certainly proved of very little value thus far except in furnishing corroborative evidence in those cases in which the diagnosis and the location had been previously determined by other means. In the skiagraph herewith presented, however, it is possible, if it be held about a meter distant from the eyes, and in such a position that the light will be reflected from its surface, to observe distinctly a shadow in the area indicated by the arrows, and concerning which the skiagrapher, Dr. G. E. Pfahler of Philadelphia, who has had a large experience in this line of work, writes as follows:

"The X-ray examination of the head of Mr. G. S., made January 23, 1904, shows a small and rather faint shadow, which is denser than the surrounding brain tissue, lying five-eighths of an inch above the floor of the Sella Turcica. This shadow is one-half inch in length and three-eighths of an inch in height. A tumor of this size lying at the middle of the brain could not be expected to cast a more dense shadow than that which is obtained

in this skiagraph. The detail is always a little more clearly shown in the negative than in the print.

"In addition to the above, the anterior clinoid processes are about twice the length of the shadows obtained in any other head that I have examined."

In the line of treatment the patient has received almost everything that suggests itself in this class of cases. Mercurial inunctions, large doses of potassium iodide, pilocarpin sweats, salicylate of sodium, and thyroid extract have all been tried, but without appreciable effect.

As to the etiology, there is probably a small tumor in front of the chiasm, of a more or less vascular nature, that changes its size, and thereby the amount of pressure, from time to time, thus producing the alterations of the visual fields as described, the pressure not being sufficient to produce atrophic changes in the nerve-heads. There is no history nor any indication of syphilis, and hysteria can be absolutely eliminated. Whether the lesion is an aneurism of an anomalous artery, as in the case of Weir Mitchell and Dercum, or a solid vascular tumor, it is impossible to say; but it has been observed frequently during the treatment of the case that the fields were always worse in damp, cloudy weather, though the patient is only vaguely rheumatic; and he himself has frequently remarked that the "fogginess" seemed to be less dense when he was under the influence of antirheumatic remedies.

DISCUSSION.

Dr. G. C. Harlan. — I believe such well-defined cases are rare. I can recall two in my experience. One is a case that some of the members may remember my reporting some years ago: a sailor from a South American port, with obscure cerebral symptoms, and finally this bitemporal hemianopsia appeared. The man described his condition as like that of a horse with a pair of large blinders. Microscopical examination of the blood showed Lavaran corpuscles and the cerebral symptoms disappeared, and with them the hemianopsia, under large doses of quinine.



VEASEY — Bitemporal Hemianopsia.

In a second case, which I have since had, a young married woman, entirely free from any neurotic condition, noticed a little confusion of vision, and on examination it was found that in the right eye the field was limited on the temporal side. This limitation extended until, at the end of seven months, it had reached the median line. The ophthalmoscopical examination was negative, and the patient was otherwise in a perfectly healthy condition. Not long afterwards the outer field of the other eye commenced to fail, and the limitation progressed until it also reached the vertical middle line. There was no further symptoms until some three years afterwards, when the patient was seized with cerebral symptoms, apparently meningeal, and died. There was no post mortem. The pathology, of course, is extremely obscure. We suspected a growth of the pituitary gland, or of the sella Turcica.

DR. POSEY. — I would like to refer briefly to a case of bitemporal hemianopsia which I saw a year ago, which exhibited the same curious diminution in the light sense as that noted by Dr. Veasey. I will refrain from giving the details of the case, as I understand that Dr. Cutler of New York will prepare the case later, but will merely mention that the restriction in the visual field was found to be due to an aneurism.

REPORT OF TWO CASES OF FAMILY MACULAR DEGENERATION OF THE CORNEA.

BY CLARENCE A. VEASEY, M.D.,
PHILADELPHIA, PENN.

In the January number of the *Centralblatt f. prakt. Augenheilk.*, 1904, Fehr reports from the eye clinic of Hirschberg three cases of a corneal affection, which he has termed Family Macular Degeneration. The disease is characterized by a progressive opacity of the cornea of both eyes, beginning about the tenth or twelfth year of age, and finally leading to disability for work after about thirty years. The opacity is diffuse, and intermingled with numerous whitish dots and maculæ; but upon close examination with a strong corneal loupe, the diffuse opacity is found to consist of numerous fine chagrin dots. In the central portion

of the cornea the opacity is densest, and the superficial layers are those principally involved; in the periphery, however, the deeper layers are most affected. There is no vascularization, nor tendency to involve the deeper structures of the eye, and indeed, beyond the progressive failure of vision and very slight irritability and photophobia, there are no subjective symptoms. The surface of the cornea is even and smooth, reflecting light normally, and sensation is unaffected. There seems to be a tendency to affect several members of the same family; but the etiology is undetermined, and treatment has proved ineffective.

Fehr has regarded the affection as an intermediate form of corneal disease between the nodular and lattice-like opacities described by Haab, Dimmer, Freund, Groenouw, and Fuchs. He has reported three cases (two sisters and a brother), and, in reviewing the literature, found only one case (Koerber's) probably identical with his. To these four cases I desire to add the two following, a brother and a sister, one of whom was exhibited before the section on ophthalmology of the College of Physicians of Philadelphia in 1899:

Case I. — W. R., a married male, aged 41 years, was first seen February 6, 1899, in the service of Dr. G. E. de Schweinitz at the Jefferson Medical College Hospital. The patient recalls nothing concerning the ocular conditions of his grandparents; but his father's eyes were good, though he died from supposed cancer in his sixty-third year. Personal examination of the eyes of the mother, her age now being 71, shows them to be normal, excepting the usual refractive condition.

The patient's general health is excellent. During childhood he had measles and scarlet fever, but no abnormal conditions followed the attacks. Somewhere about the tenth year of age he began to have some trouble in seeing the blackboard in school, and thought he was nearsighted. The condition continued to grow gradually worse until an oculist was finally consulted, but no glass could be found that would materially improve the vision. The same result obtained with several other oculists, who examined his eyes upon different occasions; and at the time of our

first examination he could read nothing but very large print (J 12), and vision equaled in each eye 15/200. Examination of each cornea showed it to be diffusely hazy, with numerous grayish-white spots and maculæ here and there, the opacity being more marked near the center. With a corneal loupe and indirect illumination the diffuse haze resolved itself into hundreds of minute dots, almost like fine stippling, in the midst of which were found maculæ of varying shapes and sizes; and though the diffuse haziness was observed over the whole cornea, it was most marked near the center. The maculæ were also more marked near the center; and, indeed, there was a ring about 4 mm. in width just within the corneal limbus, in which but few maculæ were found. In the periphery of the cornea the opacity was not only less dense but occupied the deeper layers, whereas in the center the superficial layers were those most involved. The surface of the cornea was perfectly smooth, and sensation was normal. There was a moderate regular corneal astigmatism in each eye. The pupil reactions and the lenses were also normal. Vision had progressively failed, and at the time of the examination the patient could do no fine work. Excepting the progressive failure of vision, slight irritability, producing more or less lachrymation, and some photophobia in very bright light, there were no subjective symptoms.

The patient has been seen occasionally, and was last examined a few days ago. The condition is becoming more marked, and vision at the present time equals 3½/100 in the right eye and 3/100 in the left eye. No treatment has checked the progress of the affection and no lens has improved the vision since the patient has been under our observation, a period of more than five years. The patient is the father of two healthy children, a boy aged 11 years and a girl aged 9 years, both of whom have normal eyes at the present time,

Case II. — B. R., an unmarried female, aged 43 years, is a sister of the patient just described. She has always been healthy, excepting an attack of erysipelas in early childhood and some catarrhal deafness. About the twelfth year of age she first ob-

served that she could not see so well, and also thought she was myopic. At the time of the first examination, in February, 1899, the vision of each eye equaled 1/40; at the present time it is 1/50 of normal. She can only see very large type (J 14), no glass improves, and she is incapacitated for all but the coarsest kind of work. The corneal conditions are exactly similar to the brother's, except that they are somewhat more advanced, so that it would be superfluous to describe them in detail. There are also four other brothers and sisters, the eyes of whom are perfectly normal.

In a thorough investigation of the cases no cause could be found to which to attribute the condition, and all treatment has been powerless to check its progress.

SYMMETRICAL ENLARGEMENT OF PAROTID AND LACHRYMAL GLANDS — NODULAR IRITIS.

By COLMAN W. CUTLER, M.D.,
NEW YORK CITY.

This case is offered as an example of a very rare condition, and, in conjunction with the deposits in the iris, it is believed to be unique.

October 11, 1903, Sophie Ferguson, colored, age 20, cook and laundress. Her home is near Norfolk, Virginia, but she has lived for more than a year near New York. General health has always been good: no severe illness, no history of malaria or of pulmonary disease, nor of syphilis. The family history is negative.

For about one year she has noticed a swelling in front of both ears, which for six months or more has seemed to her to be unchanged in size. It has always been painless. The swelling of the lachrymal glands has attracted her attention recently. About four months ago she noticed that the right eye was irritable; it was not painful or bloodshot, but there has been occasional neuralgic pain in the temples, especially of the right side. Vision in the right eye has failed.

Examination: Both parotid glands are enlarged, with even,

smooth surface, and firm consistency. Not tender on pressure, and the skin is freely movable over them. Their dimensions are: Right parotid — greatest anterior posterior, 9 cm.; greatest vertical, 7 cm.. Left parotid — greatest anterior posterior, 5 cm.; greatest vertical, 7 cm.

The protrusion of the glands is very noticeable. Both lachrymal glands are palpable below the orbital margin, filling upper and outer thirds of lids nearly to outer canthus. They are firm, lobulated, rather uneven masses. The submaxillary glands are somewhat enlarged. Cervical, epitrochlear, preauricular, and inguinal glands are just palpable. Mouth is normal, mucous membranes pale. Liver and spleen not enlarged, ovaries apparently normal. Mammary glands normal. Examination of lungs is negative.

Examination of eyes: Conjunctivæ normal. O. D. slight ciliary injection; cornea rather dull with surface slightly roughened, with a very fine granular appearance of the stroma. Numerous small precipitates on Descemet's membrane. At the angle of anterior chamber are six or seven nodules smaller than the head of a pin, of yellowish or pale pink color. Some of these nodules have a fine vessel winding around or over them. They are arranged close together, and to some extent are confluent. Several very small white points protrude from the surface of iris; but otherwise its stroma appears normal, brown, with markings possibly a little blurred. Several fine posterior synechiæ. Tn. Lens clear, Vitreous hazy. Fundus not seen.

O. S. Cornea — few precipitates, no synechiæ. Iris, vitreous, and fundus normal.

Vision: O. D. 20/200. O. S. 20/30. Urine normal.

Blood examination, October 29, 1903, by Dr. J. T. Gorton:

Haemoglobin, 90 per cent. Red cells, 4352000. White cells, 5200.

Differential count:

Polynuclear neutrophiles, 59 per cent. Large lymphocytes, 15 per cent. Small lymphocytes, 22 per cent. Eosinophiles, 0. Basophiles (mast cells), 2.7 per cent. Transitional forms, 1 per cent.

November 23d, examination by Dr. F. C. Wood:

Haemoglobin, 70 per cent. Red cells, 4,730,000. White cells, 5,900.

Differential count:

Polynuclear neutrophiles, 65 per cent. Large lymphocytes, 18.5 per cent. Small lymphocytes, 7.5 per cent. Eosinophilis, 3 per cent. Basophiles (mast cells), 1.5 per cent. Transitional neutrophiles, 4 per cent.

Dr. Wood writes: "The result of the blood examination is entirely negative, except for a slight anæmia. The proportions between the leucocytes are quite within normal limits."

The patient remained under observation for two months; during this time the parotid tumors became a little smaller, the lachrymal remained the same.

The iris in the right eye showed slight changes from time to time, the tumors in the angle becoming larger and the protrusions from the surface more numerous; the white dots on the dark iris presented a very striking appearance.

In the left eye several small nodules appeared in the angle of the anterior chamber, and, although no white points were visible in the surface of the iris, there were several places where the tissue protruded as if nodules might appear.

The treatment was at first iodide and mercury in increasing doses, then arsenic, increased to fifteen drops of Pearsons' solution, and maintained at that until the limit of tolerance was reached, and finally pilocarpin given in full doses. The parotids, and the eyes for briefer periods, were exposed to the X-rays, but without noticeable improvement. During the administration of iodide and mercury the condition of the iris grew steadily worse, the exudates on D's membrane more numerous, and also the protrusions from surface of iris. Under large doses of arsenic the condition appeared to improve somewhat, and she was advised to continue that treatment after her return to her home. Dr. B. R. Kennon, of Norfolk, very kindly examined the patient July 13, 1904, and writes as follows:

"The small projections on the iris are very few in number,

but both irides are bound to the lens by many points of adhesion. The cloudiness in the cornea I cannot make out to be confined to Descemet's membrane, but seems to be in the stroma as well. She states that the parotid glandular enlargement has markedly decreased, and now there is but slight enlargement there. I cannot make out any lachrymal glandular enlargement."

It will be well to consider first the symmetrical enlargement of the parotids and lachrymal glands. This condition was first recognized as a disease by Mikulicz in 1888, in the *Berliner Klin. Wochenschrift,* and more fully described in *Billroth's Festschrift* in 1892. In this case, also, the blood was normal, the spleen and lymph glands not enlarged. The disease made itself manifest by symmetrical swelling of parotids, submaxillary and lachrymal glands. There was, in addition, glandular swelling in the roof of the mouth. About two-thirds of the tissue of the swollen lachrymal glands was removed, as they were the cause of the greatest annoyance to the patient; but the tumors returned in a short time. A second time a more radical removal was made, and until death, from appendicitis three months later, there had apparently been no return. The microscopic examination showed that the tumors were composed almost entirely of small round cells, among which the acini of the glands were intact. Histologically, they might be lymphoma or lymphosarcoma. If the former, one would expect enlargement of the other glands or of the spleen, and the latter would certainly show a more malignant character.

In 1889 Haltenhoff, and in 1891 Fuchs, each reported a similar case. In that of Fuchs the portion removed was composed of lymphoid tissue. It remained practically unchanged in spite of arsenic, which was not well borne, during a period of fourteen months.

In Haltenhoff's case the tumors disappeared spontaneously, or with syrup of the iodide of iron, in less than a year.

Fuchs saw two other cases in all respects like the first of Mikulicz, which were less pronounced. The tumors diminished after the continued use of arsenic for months. These are men-

tioned by Mikulicz, but so far as I know have not been reported in detail.

In a paper by Kummel (Mitteilungen aus den Grenzgebiete der Medicin und Chirurgie 2, 1897), twenty-one cases are listed which correspond in some respects to these. If we exclude those with leukaemia, and those in which the lymphatic glands are generally enlarged, there remain fourteen cases in which parotids or lachrymal glands were swollen, and in seven cases both parotid and lachrymal glands were involved. The prognosis has been favorable. The tumors disappear, as a rule, in from a few months to two years under treatment with iodide or arsenic. After complete extirpation they have not tended to return. With regard to this fact, Kummel and Axenfeld made the following observation:

"The absence of relapses after complete removal of the glands is important in separating this disease from lymphosarcoma and from pseudoleukaemia, in both of which diseases relapses are to be expected."

Since in our case there has been no examination possible of the tumors, it is not easy to classify it; but clinically it corresponds to the cases of Mikulicz and Kummel rather than to that of Axenfeld (v. Graefe's Arch. Bd. 37) and others where there have been lymphomata in the orbit, and in the most varied localities. The assumption is that in such cases the exciting agent has been brought by the blood or lymph channels, while in the cases in which the growths have been limited to the parotids and lachrymal glands, the access to the glands has been through the ducts, from the mouth and conjunctiva: this is probable in a recent case reported by Baas (Zeitschrift f. Augenheilkunde, Sept., 1903).

In our case, however, there is the limitation of the new tissue to the parotid, submaxillary, and lachrymal glands, but, in addition, a uveitis of so unusual a form that the diagnosis cannot be made with confidence.

Such a uveitis, however, is of endogenous origin, syphilitic, tubercular, lymphoid, or from some infection not at present to be classified.

Millée and Vidaur (Le Progrès Médical, Tome 16, Oct. 25, 1902) report a case of double dacryoadenitis, with double iritis: Male, aged 42, woodcutter. The patient complained of a firm, movable, painless swelling in the upper, outer part of both orbits, noticed ten days before he was first seen by the authors. Eight days later an acute attack of iritis occurred, with numerous synechiæ and two little "papules, reddish-yellow in color, size the head of a pin, in the lesser circle of the iris." There was also a papular eruption of the skin. These symptoms responded promptly to vigorous anti-syphilitic treatment. This case is interesting only because it combines the lesion of the lachrymal glands with iritis; but the etiology puts it in a different category, as our case was of a chronic, indolent nature, and, moreover, it grew worse under anti-syphilitic treatment.

The literature of tubercular iritis is very extensive. Leber has described cases under the title of Attenuated Tuberculosis of the Eye (Bericht der Ophthal. Gesellschaft, Heidelberg, 1891) which are striking in their fluctuations and tendency to spontaneous disappearance, and which, clinically, must have resembled the present case in many respects. Also, the appearance of the iris is not unlike some cases of inoculation tuberculosis.

Stieren (Johns Hopkins Hos. Bul., Nov., 1901) reports a case of dacryoadenitis and conjunctivitis, with general tuberculosis, and gives a review of the contributions to that phase of the subject.

Gallasch (Jahrbuch für Kinderheilkunde, Neue Folge VII Band 1874, p. 87) reports a case of a leukæmic child with, among many other symptoms of leukæmia, extreme enlargement of tear glands and parotids. It is interesting to note that the microscopical appearance of the glands was strikingly similar to that of the case described by Mikulicz and others, in which there was no suspicion of leukæmia.

Shoemaker (Annals of Ophthal., July, 1904) reports a case of bilateral enlargement of the lachrymal glands, with a discussion of the nature of that and related conditions.

Michel, in 1881 (v. Graefe's Archiv., Bd. 27, 11, p. 256), de-

scribed and depicted most clearly a case of pseudo-leukæmia, which seems to have a striking similarity, as regards the appearance of the iris, to that under discussion. Michel considered the tumors in the iris to be lymphomata, in a late stage of the disease, because of the fibrous character of the cells, combined with the new lymphoid tissue.

If the symmetrical enlargement of the glands and the uveitis are to be brought into the same category, we are justified, in view of Michel's case, in considering them both as a manifestation of lymphoid activity, due to some unknown agent circulating in the blood.

Haeckel (Archiv. für Klin. Chirurgie, Band 69, p. 191) describes an interesting case, in which the patient, who had suffered a severe injury to the kidney, to which, however, no etiological significance is given, developed a severe enteritis, associated with symmetrical enlargement of the parotids and lachrymal glands. Haeckel classes these latter conditions together.

It is obvious that the symmetrical swelling of the tear glands and parotids occurs in a group of cases by itself, as an idiopathic condition, and it is believed by Mikulicz and Haeckel that this group is an infectious disease in the broadest sense of the term, although no organisms have been found by the most careful search in the glands or blood.

In another group the same symmetrical enlargement occurs, in conjunction with leukæmia and pseudo-leukæmia, and the modern tendency is to attribute these diseases also to a bacterial origin.

In our case the iritis is an additional, and, it would seem, a conclusive argument in favor of the bacterial origin of the disease, whether we classify the condition as pseudo-leukæmia or not, which is, after all, a mere clinical way of begging the question.

The tendency of our case seems to be toward recovery, as is shown by Dr. Kennon's recent report, already quoted. The limitation of the lymyphoid tissue to parotids and lachrymals, with a relatively good prognosis, points to an essential disease in whicl

the growths are influenced by the functional activity of these organs, as in mumps, or else the result of infection, as is suggested by Mikulicz and Haeckel; and to this view the iritis, which with its sluggish course and fluctuations coincides with those of the glands, lends the strongest evidence.

EXCISION OF THE SUPERIOR CERVICAL GANGLION OF THE SYMPATHETIC FOR SIMPLE GLAUCOMA, WITH A REPORT OF CASES.

By COLMAN W. CUTLER, M.D.,

NEW YORK.

Two questions must be answered before excision of the superior cervical ganglion of the sympathetic can be given a definite place among other measures, likewise more or less empirical, for the relief of chronic simple glaucoma. These questions are:

1. Is the eye ever injured or the glaucoma aggravated by the operation?

2. Does sympathectomy offer a prospect of sufficiently prolonged relief to justify us in urging it in these desperate cases, either before or in place of iridectomy?

It is assumed that no question will be raised regarding the justification of any measures not threatening to life after iridectomy has failed to give relief. One case to be mentioned answers the second question, and the answer to the first question is negative, but more evidence is needed before conclusions can be reached; in fact, sympathectomy must be judged clinically, on its merits, as iridectomy has been judged.

In considering the danger of the operation, the risk to life may be eliminated; the disordered sensation, paræsthesia, pain in neck and face, paralysis of the trapezius, and interference with phonation, may also be avoided in great part by a skillful surgeon. These accidents should not weigh against the operation if a durable result is to be expected in a certain proportion of cases, or if the inevitable alternative is blindness.

Cases of chronic glaucoma which have progressed in spite of sympathectomy are numerous. The same is true of iridectomy; but it is especially important to recognize the possibility of danger to the eye attributable directly to the operation, if such a possibility exists, for one of the chief claims made for it is that although it may do no good, it will probably do no harm.

In the following cases after sympathectomy the outcome has been deplorable, but whether as a result of the operation or simply as a contingency of the protean disease it is not easy to say.

Case 32, in Axenfeld's list, reported by Mohr and Grunert: Simple glaucoma; vision, field and tension improved after sympathectomy; two and one-half months later an acute attack of glaucoma with iridectomy was followed by retrochoroidal hemorrhage and loss of the eye.

Case 35 (Axenfeld), Grunert: Chronic, inflammatory, absolute glaucoma. Duration of the disease four weeks. The tension and pain continued after sympathectomy. Enucleation ten days later.

Wilder, Case 7: Sympathectomy produced improvement in vision for one month; tension remained high. Sclerotomy, with brief reduction of tension; then iridectomy, followed by expulsive hemorrhage.

These are the only cases, so far as the writer is aware, in which there is reason to suspect a harmful influence on the eye. The two cases of Mohr and Wilder are sufficiently disquieting; but the six cases in Wilder's list, in which iridectomy was performed without accident after sympathectomy, are reassuring, and it is obvious that the danger of hemorrhage following sympathectomy is not great; nor can it predispose to an evil result of a later iridectomy, for in all the cases of hemorrhagic glaucoma collected by Rohmer and by Wilder, seven in number, no harm has been done, for all are reported as in some respects improved.

The case of hemorrhagic glaucoma reported by Dr. Price (No. 33 in Wilder's list) died of uræmia nine months after the operation. His daughter states that there seemed to be no return

of the glaucoma, that he used his eyes with comfort to the day of his death, and often remarked the improved condition.

The doubts as to the safety of the operation raised by De Obarrio and by Angelucci may be dismissed. Wilder, in his fifth case, mentions mental confusion and mild hallucination occurring in the first week. Bichat (La Sympathectomie dans le traitement du Glaucome, p. 146, Nancy, 1901) mentions mental disorder occurring a year after the operation, and states that Brown Sequard considered this to be a result of resection of the sympathetic.

So far as I am aware, this includes all that has been offered in opposition to the operation. The chief objection is that it is ineffectual, or that its influence on the disease is too brief.

In a paper published in the *Annals of Surgery,* in Sept., 1902, by Dr. C. L. Gibson and myself, the case of A. J. Rogers was described at some length. Permit me to give a brief résumé of the history brought down to a recent date. It has seemed best to postpone the report of the case before this society until a period had elapsed long enough to permit it to be classed as a permanent result.*

In 1893 glaucoma began, with severe pain in both eyes, impaired vision, and erythropsia. For a year and a half before the patient was first seen by the writer, in 1897, there had been frequent attacks of cloudy vision, with rings and more or less pain. Chromatopsia was frequent and distressing, red being the predominating color. These phenomena were lessened by myotics, and after anterior sclerotomy and iridectomy they disappeared for a time. Since sympathectomy the subjective sensations have remained absent.

The operation was performed June 10, 1901, vision at that time being O. D. 20/100 T + 1/2 to + 1. O. S. V: O T + 2. The retained vision in the right eye may be attributed to the iridectomy

* Oct. 25, 1904. O. D. (Eye with iridectomy and sympathectomy) Vision 20/70—Field, upwards reduced to fixation point. Tn. eye not injected, fundus as before. There has been no pain in this eye, but considerable photophobia and day-blindness.

O. S. (Absolute glaucoma of long standing, no operation) Ciliary injections, eye painful, pupil small, anterior chamber normal, cornea hazy, tension + 1.

These changes have occurred within the last two weeks. Since that date the patient, who lives at some distance, has not been seen.

in that eye three years previously. After sympathectomy vision improved, and in two days it was 20/30. The field was enlarged laterally, not upwards, where it still seems dangerously near the fixation point. In August, 1902, fourteen months later, it had approached still nearer; but in July, 1903, the field was larger than at any time, and on April 26, 1904, vision was still 20/30, the field larger in some directions, but upward it was narrower than the year before. Rogers reads with much ease for half an hour or more quite small print. Vision, as I have stated, is 20/30, that is, he picks out most of the letters of 20/30, and at times some of 20/20, but in a hesitating way, and if the light is changed he is easily disconcerted. In a brightly lighted place he is dazzled, and in the dusk he finds his way with difficulty.

These limitations are but natural when one considers the probable damage to the ganglion cells, and the partial atrophy of the nerve, which is pale and excavated about 3 D.; but the fact remains that he has had useful vision, has worked and enjoyed life without any symptoms of glaucoma in that eye for more than three years. Tension in the left eye, which is blind, has been raised at times, with some dull pain, and with the appearance of a symptom to which I would like to call attention. I refer to the retraction of the upper lids. Von Graefe's sign was present in both eyes at first; but since the sympathectomy it has appeared only in the left eye, which has absolute glaucoma, and it has only been observed when the tension is raised. In the paper before mentioned I called attention to the occurrence of this symptom in certain cases of chronic glaucoma then under observation, especially to one case of unilateral glaucoma, in which the retraction of the lid was present only on the side with increased tension.

Recently a case has presented itself, in which, with glaucoma secondary to a dislocated lens, this sign was very noticeable. So it is best explained as a reflex spasm, a result of the glaucoma.

A second case which Dr. Dennett very kindly permits me to report is that of Mr. M., age 54, May, 1902. — Chronic irritative glaucoma of the left eye; incipient glaucoma of the right eye.

The left eye had been failing for ten years, and iridectomy was advised tentatively, so that it might be tried on the right eye in case that developed glaucoma. The operation was performed without mishap, but vision in this eye was not improved. During the past year, in spite of the operation, there has been a severe attack of acute glaucoma, which produced a staphylomatous protrusion of the cicatrix of the iridectomy, done with admirable technique and without complications several years ago. In the right eye there have been subtle indications of the beginnings of glaucoma for several years. Central vision has been normal; but the field has suffered, and there has been frequent chromatopsia, with pale green and lavender mottling. There is occasional hemeralopia, and a large inconstant, diffuse, relative scotoma upward, of variable limits. This has made the adding of columns of figures difficult.

June 16, 1902, removal of right superior cervical ganglion by Dr. Haywood.

August 23, 1904, V: O. D. 20/20. Very slight excavation, color of disc rather pale. O. S. Fingers counted. Nerve excavated and pale. Slight protrusion of scar above coloboma, which is of good size with free pillars.

The field of vision of the right eye, taken in 1902, after the operation, was larger both for form and color, and less variable, and the faint relative defects were less apparent than before the operation; and in August, 1904, the same limits were retained. The eye has been more useful than formerly; but there is still complaint of lavender and green suffusion of the field, and of inability to see well in dim light.

In a third case of simple glaucoma the ganglion was removed by Dr. John Rogers, March, 1904. In April Dr. Alling found vision 20/20, from 20/30 before the operation, and the field 20° to 30° larger downward; and in August, four months after the operation, the improvement was retained. The patient was using pilocarpin from time to time. This improvement enables the patient to go about with much independence and to read freely, whereas before the operation the field had been reduced to a horizontal slit up 3°, in 5°, down 10°, out 60°.

In this case the time that has elapsed since the operation is brief; but as the disease had progressed steadily, though very slowly, during a period of eighteen months' observation, it is fair to claim the cessation of progress and the slight improvement as a favorable result.

That simple glaucoma may remain nearly stationary during prolonged periods is well known. The following case illustrates the error that might arise in claiming results for any method of treatment in this most uncertain disease:

J. F.; colored; male; age 55; May 25, 1902. V. 20/40 T, at times slightly raised. Field normal, except for nearly complete loss of inferior nasal quadrant, where green and red are within 5° of fixation point, blue 10°, and white 15°. Nerve white, not excavated. Operation refused. No treatment.

June 27, 1904, V: 20/50 T. + ½. Nerve as before. Field about 20° narrower than at previous examination. In inferior nasal quadrant, colors close to the point of fixation, white 5°.

In two recent cases of simple glaucoma the results of the operation have not been positive, that is, vision has not been improved; but the disease has not progressed, and the eye has not suffered.

It is to be hoped that this operation will not be allowed to fall into disuse because of any fancied difficulties it presents to patient or surgeon. The risk and discomfort is trifling in skillful hands, and the danger to the eye itself is entirely negligible. Whether this can be said of iridectomy, especially in chronic simple glaucoma, with the field near the fixation point, is open to discussion.

REPORT OF THE COMMITTEE ON STANDARDS.

READING TEST TYPES.

A set of test types for the reading distance has been carefully prepared, in accordance with the report of your committee adopted at the meeting of the society in 1903, as follows: "4. That for reading tests (following Jaeger) ordinary print of uniform character and gradation in size, as far as practicable, should be used. 5. That the standard, in reading, should be the ability to read print in which the height of the short 'lower case' letters subtends a visual angle of five minutes (5′). To record the observed reading power, it is recommended that Snellen's notation be employed in the slightly altered form, $L = \frac{d}{D}$, in which L (lectio) represents the reading power, d the greatest distance (in decimeters) at which the print is read, and D the distance (also in decimeters) at which it subtends the standard angle of five minutes."

In the principal set of the test types now presented, numbered from 4 to 70, on pages one, two, and three, and duplicate page 1, a, the fonts have been chosen so as to give a well-rounded letter, with good width in proportion to the height and with ample spacing between the letters. The general character of the letters is practically uniform throughout the series.

The subject-matter has been taken mostly from Dana's "Two Years Before the Mast," as, after much searching, this seemed to give the best combination of good English and short words; some selections have also been made from Addison and Emerson.

The numbers between the paragraphs indicate the distance, in decimeters, at which the short lower case letters, a, c, n, o, etc., subtend a visual angle of five minutes. It will be seen that from 4 to 13, inclusive, there is a uniform gradation of one minute increase in the visual angle for each paragraph; beyond 13 the increase is greater. This arrangement gives a very serviceable series, with ample provision for the smaller visual angles, where it is most needed.

These test types may be held at five decimeters, or at any other convenient distance from the eye, and the fraction for noting the

reading power will be made by taking the distance at which the type is read (in decimeters) for the numerator, and the number between the smallest paragraphs read (the distance at which the short lower case letters subtend a visual angle of five minutes) for the denominator. If a person can read the paragraph numbered 5 at a distance of five decimeters, his reading power will be noted as 5/5. If No. 10 is the smallest he can read at this distance, his reading power will be noted as 5/10. In the reading of printed matter most words are read as a whole rather than by picking out their individual letters, and this will often make the record of reading power seem too large as compared with the record for distant vision; for instance, most normal eyes will see the smallest print, No. 4, at a distance of five decimeters, and will be noted as having a reading power of 5/4, or, they may even read it at six decimeters, and have L = 6/4, although for the distance they may have only V = 5/5; on the other hand, printed words are the things with which we are mostly concerned, and such a test is, in general, the most satisfactory for a reading test.

A second set of letters has been printed, with a series of fractions between each paragraph, 5/4 to 5/12; in this series the print should be held at a distance of five decimeters from the eye, and the fraction between the smallest paragraphs read will give at once the reading power, on the same basis as the first series. This series, from 5/6 to 5/12, is printed with type of the "Riverside series," in which the letters are higher in proportion to their width than in the "Franklin series"; the vertical lines of the letters are also heavier in proportion to the horizontal lines, and there is less spacing between the letters. When the two series are compared side by side, especially in the larger sizes, the "Franklin" and "Old Style" type of the first series seems rather easier to read, and would be better for text-books, especially the No. 11, than much of the type now used.

In the page of numerals, arranged in the form of fractions, the numbers over each line show the average visual angles subtended by the individual numerals of that line at a distance of five decimeters. A page of playing card characters in graded sizes,

and a page of music printed in the four sizes of music type in most common use, have been added for use in special cases. A page of paragraphs printed in broad face type is also intended for special cases, and, as a comparison between this type and smaller faced type of the previous series cannot well be made on the basis of the visual angle, these paragraphs are lettered instead of being numbered.

In working over the height of letters required to subtend the desired visual angles, at the reading distance of five decimeters, and at the far distance of five meters, the following rule was evolved: Take the number representing the natural tangent of the visual angle subtended at the eye by any letter; move the decimal point three places to the right and divide by two, and the result will be the required height of the letter, in millimeters for the reading distance of five decimeters, or in centimeters for the far distance of five meters.

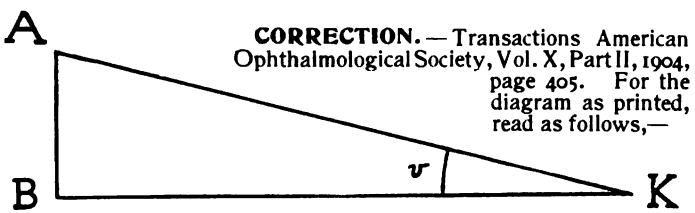

CORRECTION. — Transactions American Ophthalmological Society, Vol. X, Part II, 1904, page 405. For the diagram as printed, read as follows,—

In the right triangle KBA

test letter for the reading distance. Let BK equal the reading distance, 5 decimeters, or 1000 half millimeters. Let v equal the visual angle of five minutes under which the letter is seen:

tan. v $= \frac{AB}{BK}$.

AB $=$ tan. v $\times$ BK.

AB $=$ 0.001454 $\times$ 1000 (half millimeters).

AB $=$ 1.454 (half millimeters).

AB $=$ 0.727 (millimeters).

In the same way for the distance, BK equal 5 meters, the result will be: AB $=$ 0.727 c. m.

If we wish to find the angle subtended, when knowing the height of any letter in millimeters, we divide the height of the letter by the distance of the letter from the eye, 500 mm., and the result will be the tangent of the required angle, which can be then found in a table of natural tangents.

The following table was constructed to show the differences between the actual measured sizes of the short lower case letters and the theoretical heights, according to the above formula, in the series of test letters 4 to 70, inclusive. The measurements of the letters in paragraphs 4 to 17, inclusive, were made with a No. 0 objective and a No. 2 micrometer eyepiece, with the draw tube placed so that 40 divisions on the micrometer scale were equal to 1 mm. on a fine steel scale placed in the plane in which the letters were measured. Beyond No. 17 the letters were measured direct by a fine scale and magnifying glass. The average measurement of ten letters was taken for each size of type:

1	2	3	4	5	6	7	8	9	10
Kind of type.	Printers' name for size of type.	Measured height of the short lower case letters in millimeters.	Calculated height of such letters in mm. needed to subtend a visual angle of 5 minutes at each of the required distances.	Natural tangents of the different visual angles.	Visual angles in minutes under which each size of letters should be seen at a distance of 5 decimeters.	Distance in decimeters at which the letters should be seen to subtend a visual angle of five minutes.	Numbers over or between the printed paragraphs of test letters.	Visual angles in minutes actually subtended at a distance of 5 decimeters by the printed letters as measured.	Distance in decimeters at which the printed letters as measured subtended a visual angle of five minutes.
Old style type. / Franklin series type.	3½ point	0.58	0.58	.001164	4 minutes	4 decim'rs	4	4+ minutes	4.01 decim'rs
	Diamond	0.72	0.73	.001454	5 "	5 "	5	5 1 "	4.94 "
	5 point	0.86	0.87	.001745	6 "	6 "	6	6 1 "	5.93 "
6	"	1.00	1.02	.002036	7 "	7 "	7	7 1 "	6.86 "
7	"	1.12	1.16	.002327	8 "	8 "	8	8 1 "	7.68 "
8	"	1.23	1.31	.002618	9 "	9 "	9	8+ "	8.43 "
9	"	1.36	1.45	.002909	10 "	10 "	10	9+ "	9.29 "
10	"	1.49	1.60	.003200	11 "	11 "	11	10+ "	10.22 "
11	"	1.62	1.74	.003491	12 "	12 "	12	11+ "	11.16 "
12	"	1.85	1.89	.003782	13 "	13 "	13	13 − "	12.74 "
14	"	2.10	2.18	.004363	15 "	15 "	15	14+ "	14.47 "
18	"	2.48	2.47	.004945	17 "	17 "	17	17+ "	17.04 "
24	"	3.56	3.64	.007272	25 "	25 "	25	24+ "	24.48 "
36	"	4.84	4.04	.009891	34 "	34 "	34	33+ "	33.28 "
48	"	7.34	7.27	.014545	50 "	50 "	50	51 − "	50.51 "
60	"	10.16	10.18	.020365	70 "	70 "	70	70 − "	69.87 "

A careful study of this table will show how near the measured heights of these letters as printed come to the theoretical heights,

and our thanks are due to the American Type Founders Co. for the care they have taken to make these test types as perfect as possible. The first edition of the test types has been printed direct from the type, to get the clearest impression possible, and if any other sets are needed they will be printed from the electrotype plates, which have been very carefully prepared.

The same careful measurements as above were made of the letters on the other pages of the test types, and the figures printed between the paragraphs, or above the lines, except on the music page, are the result of these measurements.

For the sake of comparison, the same measurements were made of the letters printed in the following European series of test letters, the average measurements of ten letters being taken for each size of type. Schrift-Scalen. Ed. v. Jaeger. Wien. 1874. Fünfte Auflage.

No. over test letters.	Actual size as measured.	Calculated size for angle of	No. over test letters.	Actual size as measured.	Calculated size for angle of
No. 1.....	.57mm.	4′= .58mm.	No. 13.....	2.82mm.	19′= 2.76mm.
No. 2.....	.71mm.	5′= .73mm.	No. 14.....	3.58mm.	24′= 3.49mm.
No. 3.....	.87mm.	6′= .87mm.	No. 15.....	4.71mm.	32′= 4.65mm.
No. 4.....	.97mm.	7′= 1.02mm.	No. 16.....	5.46mm.	38′= 5.53mm.
No. 5.....	1.18mm.	8′= 1.16mm.	No. 17.....	7.34mm.	50′= 7.27mm.
No. 6.....	1.36mm.	9′= 1.31mm.	No. 18.....	8.91mm.	1°.1′= 8.87mm.
No. 7.....	1.48mm.	10′= 1.45mm.	No. 19.....	13.58mm.	1°.33′=13.52mm.
No. 8.....	1.63mm.	11′= 1.60mm.	No. 20.....	18.39mm.	2°. 6′=18.33mm.
No. 9.....	1.77mm.	12′= 1.74mm.	No. 21.....	22.14mm.	2°.32′=22.12mm.
No. 10.....	1.96mm.	14′= 2.04mm.	No. 22.....	27.49mm.	3°. 9′=27.50mm.
No. 11.....	2.23mm.	15′= 2.18mm.	No. 23.....	33.74mm.	3°.52′=33.79mm.
No. 12.....	2.46mm.	17′= 2.47mm.	No. 24.....	43 23mm.	4°.57′=43.30mm.

It is very interesting to see how accurate this early series of Jaeger's is as to the gradation in size and the general character of the letters. From 4′ to 12′, inclusive, there is a paragraph for each increase of one minute in the visual angle. The series is longer than needed for ordinary use, especially in the larger sizes of type.

In Snellen's Optotypi, edition of 1875, the same average measurements of ten different letters, as made for the previous series, gave the following results:

No. over test letters.	Actual size as measured.	Calculated size for angle of	No. over test letters.	Actual size as measured.	Calculated size for angle of
D=0.5.....	.78mm.	5′= .73mm.	D=1.5.....	2.11mm.	15′=2.18mm.
D=0.6.....	1. mm.	7′=1.02mm.	D=1.75.....	2.52mm.	18′=2.62mm.
D=0.8.....	1.16mm.	8′=1.16mm.	D=2.25.....	2.96mm.	20′=2.91mm.
D=1.....	1.34mm.	9′=1.31mm.	D=3.....	4.38mm.	30′=4.36mm.
D=1.25.....	1.64mm.	11′=1.60mm.	D=4.....	6.11mm.	42′=6.11mm.

In this series the rate of increase in the size of the visual angles is quite irregular, and as the type increase in size they also increase, out of proportion, in the breadth and blackness of the face of the type, so that they do not preserve the uniformity of the character of the type throughout the series.

In Schweigger's Seh-Proben, Berlin, 1876, the same measurements give:

No. over test letters.	Actual size as measured.	Calculated size for angle of	No. over test letters.	Actual size as measured.	Calculated size for angle of
0.4.....	.76mm.	5′= .73mm.	1.75.....	3.04mm.	21′= 3.05mm.
0.5.....	.86mm.	6= .87mm.	2.25.....	3.61mm.	25′= 3.63mm.
0.6.....	1.10mm.	8′=1.16mm.	3.5.....	5.46mm.	38′= 5.52mm.
0.75.....	1.25mm.	9′=1.31mm.	4.....	7.47mm.	51′= 7.41mm.
0.9.....	1.62mm.	11′=1.60mm.	6.....	10.16mm.	1°.10′=10.18mm.
1.....	1.87mm.	13′=1.89mm.	8.....	14.61mm.	1°.40′=14.54mm.
1.1.....	2.37mm.	16′=2.33mm.	12.....	20.73mm.	2°.22′=20.66mm.
1.25.....	2.51mm.	17′=2.47mm.			

In this series the letters are rounder and better shaped than in some of the others, but in the small sizes they have a relatively very wide spacing; and the series is not a regular one, in fact, Schweigger says, in his description of the test types, that the distance at which they can be easily read is determined empirically rather than by the calculation of the visual angle.

In Galezowski's Echelles Optométriques, Paris, 1883, the same measurements give:

No. over test letters.	Actual size as measured.	Calculated size for angle of	No. over test letters.	Actual size as measured.	Calculated size for angle of
0.5 — 0.5 mm.	.75mm.	5′= .73mm.	2.— 2.mm.....	2.34mm.	16′=2.33mm.
1. — 1. mm..	1.24mm.	8′=1.16mm.	3.— 3.mm.....	2.81mm.	19′=2.76mm.
1.25— 1.25mm..	1.33mm.	9′=1.31mm.	4.— 4.mm.....	4.16mm.	29′=4.21mm.
1.5 — 1.50mm..	1.71mm.	12′=1.74mm.	5.— .5mm.....	5.97mm.	41′=5.96mm.

In this series the gradation in size is quite irregular, and the character of the type varies too much in the different paragraphs.

In the series of deWecker and Masselon, Echelle Métrique, Paris, 1899, the same measurements give:

No. over test letters.	Actual size as measured.	Calculated size for angle of	No. over test letters.	Actual size as measured.	Calculated size for angle of
D=0.25.....	.60mm.	4′= .58mm.	D=1.50.....	2.03mm.	14′=2.04mm.
D=0.50.....	.89mm.	6′= .87mm.	D=2.....	3.14mm.	22′=3.20mm.
D=0.75.....	1.14mm.	8′=1.16mm.	D=3.....	4.59mm.	31′=4.51mm.
D=1.....	1.34mm.	9′=1.31mm.	D=4.....	6.77mm.	46′=6.69mm.
D=1.25.....	1.73mm.	12′=1.74mm.	D=5.....	7.78mm.	53′=7.71mm.

In this series the letters have the same general character, but the gradations are not regular, and, especially in the larger sizes, the height of the letters is too great in proportion to their width, and the vertical lines are too heavy in proportion to the horizontal lines.

CHARLES H. WILLIAMS,
WILLIAM THOMSON,
W. S. DENNETT,
JOHN GREEN,
Committee.

IMPROVEMENTS IN THE REFRACTOMETER FOR THE CORRECTION OF AMETROPIA DESCRIBED IN THE TRANSACTIONS OF 1902.

BY DR. WILLIAM AND DR. ARCHIBALD G. THOMSON.

The crude instrument described two years ago for the detection of ametropia and its correction by a study of the image of diffusion is now offered to you in its improved form as a rapid, easy, and accurate method for determining the refraction without a mydriatic as a substitute for the tedious and tiresome methods now in use.

It consists of a telescope mounted on a stand worked by a milled head, which brings its lenses near or further apart, mounted in tubes carefully graduated in diopters, which enables us to bring before the eye conditions equal to spherical plus and minus lenses from plus 7 to minus 6 diopters. Thirty sphere lenses

plus and the same number minus glasses are required for this purpose in our test boxes, making sixty in all. A rapid movement of the milled head enables us to use this limit in the time that would be required to take from and return to their places a very few of the glasses. On the tube is a finder, and the eyepieces have a spring in which a glass from the test case can be placed if necessary.

To attain this range it becomes requisite to use a sufficient magnifying power to permit the markings on the tube to be visible. This was found to be about three diameters, and, with a view to simplifying the construction of a proper test card, we concluded to take that magnifying power which would convert feet into diopters, and decided upon 3.3 powers. This range answers for most of the cases, but for defects higher than minus 6 or plus 7 a glass from the trial set can be placed in the eyepiece. In one tube there is a plus sphere; in the other a minus sphere, to be moved by a rackwork supported upon a tripod. To this is added an eyepiece, attached to which is a spring, as is seen in the ordinary test frame, large enough to hold any glass from the test set, so that glasses from the case may be used if degrees of hyperopia or myopia higher than the instrument may record, or cylinder glasses when the astigmatism is determined. One test glass, half of which is composed of a hemicircular piece of ruby glass and the other half white, is required. In another in an opaque disc the size of a test glass is mounted, a hemicircle of ruby glass 1/2 centimeter in diameter, and the other half containing a series of Maddox's rods, the bases of the rods coinciding with the edge of the piece of ruby glass. These are placed in the spring of the first eyepiece so as to coincide with a protractor engraved on the end of the tube. These two colored glasses may also be used in the trial frame with the larger lights without the instrument.

The test object is a point of light gained by using an asbestos chimney with a disc having openings of 10, 5, 2½, 1 and ½ mm. The light may be electricity or gas; or a spring candlestick, with a tin shade blackened to prevent any reflected light, properly perforated, may be used.

The second eyepiece contains a circular opening, half of which contains a hemicircular piece of ruby glass and the other half a high cylinder of white glass so mounted that the side of the red glass is in close apposition in the center of the opening with the exposed end of the cylinder. This enables the light passing through it to be divided into a red spot, bisected by a white line in emmetropia. In myopia the spot is seen to the same side of the line as the red glass is to the cylinder when placed before the eye, while in hyperopia the red spot is seen to the other side of the line, when the image of diffusion is properly examined with the rackwork of the instrument.

The most valuable result of this method is that when the light is emitted from a hole in a blackened surface and passed through the instrument it is placed on the retina one-half reduced in brightness by the red glass, the other changed into a long fine white line. In this condition it stimulates the eye so little that the accommodation is, if not entirely, mostly suppressed. The light for this fine test should be at six meters away, and should come from an opening of but one-half millimeter in diameter. Should these views be found to be correct, after a more extended use of the instrument by other observers, it will mark an epoch in the correction of optical defects, and eliminate the use of mydriatics so much dreaded by the patients and the public. In practice almost a moment only is needed with the large light point to determine if poor vision is caused by ametropia, or lesions of transparency, or ill-fitting glasses.

For astigmatism we have a rapid test in the use of the first described half-red, half-white trial glass, for with the instrument the red and white spots as they are reduced from a condition of high ametropia by the use of the rackwork, these two images approach each other, but do not cover each other, as in myopia or hypermetropia, but arrange themselves side by side. The degree with the axis of ametropia is quickly found by the second eyepiece with the cylinder and red glass, and the proper rotation of the eyepiece, to accord with the protractor, will give the two meridians of greatest and least ametropia promptly.

Emmetropia is found by the rackwork when a fine white line of light passes through a small red point, in form like a Graefe's dot and line; turning the rackwork then puts the red on one side of the line in myopia or on the other in hypermetropia. The scale on the tube should then indicate the degree of defect in diopters.

The necessity of a test card, suited to the instrument and constructed with perfect accuracy, led to the one here described where facsimilies of letters from Snellen's Optotypi are used, from 1 diopter to 12, reproduced by careful drawing and photography and etching. No. 6 D., which should be 8.75 mm. in size, will be found to be 9 mm. This gives 1.5 mm. for No. 1, and the same scale exists throughout. The half of the well-known clock face has been adopted for astigmatism, with a short line added between each hour.

The power of enlargement by 3.3 enables the conversion to be made from diopters into English feet for those who use that measurement, and on the card this has been done, and No. 1 Snellen = 10 feet, or 3 diopters, No. 2 = 6 diopters, or x x feet, etc., with the use of the instrument.

The card is very useful when used alone or with the test glasses, as it conveniently enables the V. to be ascertained by merely approaching it from 6 to 1 meter, or less. In feet the range is from 3.3 to 40 feet, but with the instrument added is from 10 to 120 feet. All other cards may be disused. The size of the card is one foot square. It should be mounted or hung on a blackened board or backed by a black curtain.

When there is low acuity of vision found after a short trial some lesion of transparency may be suspected and looked for by an entoptic test, using the light and the plus 7 of the scale, aided, if required, by a higher plus from the trial box. The circle of light may then present evidences of opacity in the media, especially of the cornea or lens. This can be studied promptly also by the cylinder eyepiece, as the white line of light may appear rough, partly broken, or with a spindle-shaped portion between clearly defined ends. A shield cover to exclude one eye when the other is examined is found requisite.

Cases quickly diagnosticated are those of conical cornea, mixed and irregular astigmatism, opacities of the cornea or lens, or other forms of ametropia.

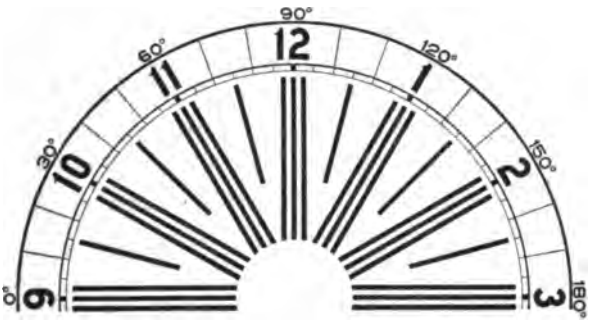

SUMMARY.

The test glass, half white and half red, may be held in the hand or placed in a test frame before the patient, with or without his glasses, and the manifest refraction tested by using any small light. Its usefulness is proved by the following case: Mr. B., over 80 years, feeble in health, lives in the country two hours away by rail and carriage. He had been operated for cataract by extraction with good result, and could not leave his house to be examined for his aphakia. With a few high + glasses, some astigmatic lines and test letters, and a small pocket electric torch, a correction was commenced. At four meters, the length of his room, he described his diffusion image as an oval with long axis, about 30°, but failed to split the image with the red and white glass, describing it as half yellow and very dark yellow. Being pressed for a reply to the question Do you see the light half white and half red? he reminded me that he had long known that he was color blind for red and green. At the next visit a trial glass of white and cobalt blue gave perfect reaction, and soon gave as best result + $13^s \supset - 4^c$ ax. 105° for V. of 4/6; and by adding + 4^s more for near he read D = 33 at 25 centimeters. His color defect was proved by his calling a pink colored handkerchief blue. When corrected his distant point of light could no longer be split by the white and blue glass: V. for far = 4/6, and for near 25/33. These glasses gave entire satisfaction.

The second trial glass, multiple rods, and red glass can be used with more rapidity, with any small light, held in the hand or in trial flame, and with the usual trial set.

Both these trial glasses can also be used with the Refractometer.

When greater accuracy is required the light should come through openings of 1 or ½ mm., using the cylinder and red glass eyepiece, and the rack and pinion for finding the ametropia and correcting it. Emmetropia is shown when the long white streak of light has upon it a small red spot. With care the accommodation seems reduced to a minimum, a change of from .25 to .50 diop. being enough to throw the red spot to one or the

other side of the line. All lights should be excluded if possible except that from the test opening.

To find the acuity of vision you remove the cylinder eyepiece, and use only the simple one. Place the test card in full illumination, and record the smallest letters than can be read, keeping in mind that No. 2 Snellen with the tube is now equal to the No. 6 of the usual test card, and will equal V. 1/1 at 6 meters, or 20/xx. When the V. is less, direct the attention to the radiating lines, and correct any remaining astigmatism by the motion of the rackwork. Finding the probable cylinder required, place it from the trial set in the spring of the eyepiece, and with the rackwork in use obtain the + or — spherical needed for high acuity. Using again the cylinder eyepiece, see if the same result is found with streak and spot of light. The absence of disturbing astigmatism is found when the streak and spot separate as the rackwork produces minus spherical conditions.

That the accommodation is suppressed by the device of the eyepiece, and the exclusion of all but the light from a minute point may be accepted. That accommodation is possible with the refractometer used with open eyepiece, full illumination, and test card is found by moving the tubes so as to place — condition before the eye, when young persons can see the small letters with — 4 or 5^s. With a short trial the patient may be trusted with the milled head, and place it where the best result is obtained.

The small card, used as an illustration, provides us with a valuable test for near vision, being reduced by photography to one-quarter the size of the Snellen letters used. No. 1 can therefore be seen at 25 centimeters. The card gives an excellent test for acuity at the near point, and is useful to make sure of the astigmatic correction, when + 4 or 3^s are placed in front of the correcting glasses.

The Refractometer complete, and the Test Card, are made by Queen & Co., and can be obtained from them.

TRANSACTIONS

OF THE

AMERICAN

OPHTHALMOLOGICAL SOCIETY.

Forty-first Annual Meeting.

BOSTON, MASS., 1905.

Vol. X, Part III.

HARTFORD:
PUBLISHED BY THE SOCIETY.
1905.

5261

PRESS OF THE CASE, LOCKWOOD & BRAINARD COMPANY.

TABLE OF CONTENTS

	Page
Members of the society,	421
Minutes of the forty-first annual meeting,	425
Melano-sarcoma of the choroid; Dr. C. J. Kipp,	432
Concerning melanoma of the choroid with report of one case of this character and of another exhibiting a pigmented sarcoma of the choroid early in its development; Drs. G. E. de Schweinitz and E. A. Shumway,	439
Metastic carcinoma of ciliary body; Dr. C. W. Cutler,	451
The Sachs lamp for transillumination of the eye; Dr. E. S. Thomson,	457
Improved surgical methods for the successful use of the electro-magnet; Dr. R. Sattler,	460
Magnetic properties of steel alloyed with other metals; Dr. W. M. Sweet,	470
On the various methods employed for localizing foreign bodies in the eye by means of the Roentgen rays; Dr. J. E. Weeks,	476
What are the so-called reflexes which can properly be referred to eye-strain? Dr. L. Howe,	491
Recurrent iritis, a study of nine cases; Dr. H. Woods,	501
Juvenile glaucoma; Dr. R. Sattler,	519
Case of acquired cyst of conjunctiva containing an embryonic tooth-like structure; Dr. Edw. Stieren,	521
Case of cystic sarcoma of the orbit — extirpation — death; Dr. H. F. Hansell,	525
Certain congenital affections of the eye following strong ante-natal impressions made on the mother; Dr. H. Derby,	530
Lesion of the choroid due to intestinal inflammation from ptomaine poisoning; Dr. C. S. Bull,	535
The treatment of inoperable cases of malignant disease of the orbit by the X-ray,	540
Vernal conjunctivitis in the negro; Dr. Dunbar Roy,	556
Value of the so-called high frequency currents in certain ocular conditions with illustrative cases; Dr. J. C. Lester,	566
Tumors of the conjunctiva and cornea — two cases; Dr. J. M. Ray,	571
A case of homonymous, left-sided inferior tetartanopsia following toxic dose of salicylate of soda; Dr. J. H. Claiborne,	581

PAGE

Epithelial corneal cyst; Dr. J. H. Claiborne, ... 588
Case of persistent pupillary membrane of rather considerable size; Dr. W. B. Marple, ... 593
Case of discoloration of the cornea by blood pigment and one of hemorrhage into the cornea; Dr. O. F. Wadsworth, . . 594
A series of reversible test-types arranged according to the geometrical progression of Drs. Jno. Green and C. H. Williams, . 602
Symptoms presented by the different bacteriological types of acute conjunctivitis; Dr. A. Duane, ... 608
Cyanosis retinæ; Dr. W. C. Posey, ... 632
Notes on the clinical determination of the acuteness of vision, including the construction and gradation of optotypes, and on systems of notation; Dr. Jno. Green, ... 642

MEMBERS

OF THE

American Ophthalmological Society.

1905-1906.

ACTIVE MEMBERS.

The (*) indicates *Associates.*

NAME.	RESIDENCE.	PLACE.
Dr. A. E. ADAMS,	44 Grand Street,	Newburg, N. Y.
Dr. J. L. ADAMS,	38 East 51st Street,	New York, N. Y.
Dr. L. A. W. ALLEMAN,	64 Montague Street,	Brooklyn, N. Y.
Dr. A. N. ALLING,	199 York Street,	New Haven, Conn.
Dr. G. W. ALLYN,	515 Penn Avenue,	Pittsburg, Pa.
Dr. A. ALT,	3036 Locust Street,	St. Louis, Mo.
†Dr. J. A. ANDREWS,	107 Madison Avenue,	New York, N. Y.
Dr. S. C. AYRES,	4 West 7th Street,	Cincinnati, Ohio.
Dr. WM. T. BACON,	75 Pratt Street,	Hartford, Conn.
*Dr. JAS. H. BELL,	Moore Building,	San Antonio, Texas.
Dr. H. W. BRADFORD,		Wolfboro, N. H.
*Dr. GUSTAVE E. BRUÈRE,	413 Oregonian Building,	Portland, Oregon.
*Dr. H. D. BRUNS,	830 Canal Street,	New Orleans, La.
Dr. CHARLES S. BULL,	47 West 36th Street,	New York, N. Y.
Dr. SWAN M. BURNETT,	916 Farragut Sq. (17th St.),	Washington, D. C.
Dr. PETER A. CALLAN,	35 West 38th Street,	New York, N. Y.
Dr. F. P. CAPRON,	118 Angell Street,	Providence, R. I.
*Dr. W. M. CARHART,	252 Madison Avenue,	New York, N. Y.
Dr. W. H. CARMALT,	87 Elm Street,	New Haven, Conn.
*Dr. JOHN T. CARPENTER, JR.,	1624 Walnut Street,	Philadelphia, Pa.
*Dr. BURTON K. CHANCE,	235 So. 13th Street,	Philadelphia, Pa.
Dr. H. B. CHANDLER,	34½ Beacon Street,	Boston, Mass.
*Dr. J. W. CHARLES,	509 Humboldt Building,	St. Louis, Mo.
Dr. WM. CHEATHAM,	303 West Chestnut Street,	Louisville, Ky.
Dr. F. E. CHENEY,	126 Commonwealth Avenue,	Boston, Mass.
Dr. J. H. CLAIBORNE,	34 West 36th Street,	New York City.
Dr. C. F. CLARK,	188 East State Street,	Columbus, Ohio.
Dr. DAVID COGGIN,	7 Chestnut Street,	Salem, Mass.
*Dr. WM. G. CRAIG,	15 Fuller Building,	Springfield, Mass.
Dr. C. M. CULVER,	36 Eagle Street,	Albany, N. Y.
*Dr. C. W. CUTLER,	52 West 53d Street,	New York, N. Y.

† Temporarily residing at Santa Barbara, Cal.

NAME.	RESIDENCE.	PLACE.
Dr. W. S. DENNETT,	8 East 49th Street,	New York, N. Y.
Dr. HASKET DERBY,	182 Marlboro Street,	Boston, Mass.
Dr. RICHARD H. DERBY,	9 West 35th Street,	New York, N. Y.
Dr. LEWIS S. DIXON,	232 Clarendon Street,	Boston, Mass.
Dr. ALEXANDER DUANE,	49 East 30th Street,	New York, N. Y.
Dr. J. B. EMERSON,	20 East 30th Street,	New York, N. Y.
Dr. ARTHUR E. EWING,	2670 Washington Avenue,	St. Louis, Mo.
Dr. T. H. FENTON,	1319 Spruce Street,	Philadelphia, Pa.
Dr. GEORGE F. FISKE,	100 State Street,	Chicago, Ill.
*Dr. W. H. FOX,	1826 Jefferson Place,	Washington, D. C.
Dr. PERCY FRIDENBERG,	114 West 126th Street,	New York, N. Y.
Dr. H. FRIEDENWALD,	1029 Madison Ave.,	Baltimore, Md.
Dr. B. F. FRYER,	Cor. 9th and Cherry Streets,	Kansas City, Mo.
Dr. G. M. GOULD,	1722 Walnut Street,	Philadelphia, Pa.
Dr. H. Y. GRANT,	414 Delaware Avenue,	Buffalo, N. Y.
Dr. JOHN GREEN,	2670 Washington Avenue,	St. Louis, Mo.
*Dr. ALLEN GREENWOOD,	101 Newbury Street,	Boston, Mass.
Dr. EMIL GRUENING,	36 East 57th Street,	New York, N. Y.
*Dr. C. W. HADDOCK,		Beverly, Mass.
Dr. G. W. HALE,	Wilcox Building,	Nashville, Tenn.
Dr. WM. D. HALL,	4 Arlington Street,	Boston, Mass.
Dr. H. F. HANSELL,	1528 Walnut Street,	Philadelphia, Pa.
Dr. GEORGE C. HARLAN,	1515 Walnut Street,	Philadelphia, Pa.
Dr. HERBERT HARLAN,	516 Cathedral Street,	Baltimore, Md.
Dr. DAVID HARROWER,	9 Elm Street,	Worcester, Mass.
Dr. N. D. HARVEY,	262 Benefit Street,	Providence, R. I.
*Dr. H. H. HASKELL,	34 Commonwealth Avenue,	Boston, Mass.
Dr. GUSTAVUS HAY,	1 Hathaway Street,	Jamaica Plain, Mass.
Dr. NEIL J. HEPBURN,	317 West 23d Street,	New York, N. Y.
Dr. WARD HOLDEN,	43 West 48th Street,	New York, N. Y.
Dr. E. E. HOLT,	723 Congress Street,	Portland, Me.
Dr. LUCIEN HOWE,	87 West Huron Street,	Buffalo, N. Y.
Dr. A. A. HUBBELL,	212 Franklin Street,	Buffalo, N. Y.
Dr. D. W. HUNTER,	80 West 40th Street,	New York, N. Y.
Dr. J. W. INGALLS,	874 Lafayette Avenue,	Brooklyn, N. Y.
Dr. E. E. JACK,	215 Beacon Street,	Boston, Mass.
Dr. EDWARD JACKSON,	1434 Glenarm Street,	Denver, Col.
Dr. B. JOY JEFFRIES,	15 Chestnut St., Beacon Hill,	Boston, Mass.
Dr. W. B. JOHNSON,	170 Broadway,	Paterson, N. J.
*Dr. H. W. KILBURN,	192 Marlborough Street,	Boston, Mass.
Dr. CHARLES J. KIPP,	560 Broad Street,	Newark, N. J.
*Dr. ARNOLD KNAPP,	26 West 40th Street,	New York. N. Y.
Dr. H. KNAPP,	26 West 40th Street,	New York, N. Y.
Dr. CARL KOLLER,	681 Madison Avenue,	New York, N. Y.
Dr. CHAS. W. KOLLOCK,	Cor. Wentworth & Com'g Sts.,	Charleston, S. C.
Dr. W. E. LAMBERT,	8 West 35th Street,	New York, N. Y.
*Dr. W. B. LANCASTER,	101 Newbury Street,	Boston, Mass.

NAME.	RESIDENCE.	PLACE.
*Dr. J. C. LESTER,	179 Schermerhorn Street,	Brooklyn, N. Y.
Dr. F. N. LEWIS,	35 W. 36th Street,	New York City.
Dr. J. A. LIPPINCOTT,	Arrott Bdg., Wood St. & 4th Av.,	Pittsburg, Pa.
Dr. F. B. LORING,	1420 K Street,	Washington, D. C.
Dr. D. B. LOVELL,	32 Pearl Street,	Worcester, Mass.
Dr. F. W. MARLOW,	731 University Block,	Syracuse, N. Y.
Dr. W. V. MARMION,	1110 8th Street, N. W.,	Washington, D. C.
Dr. W. B. MARPLE,	46 W. 53d Street,	New York, N. Y.
Dr. ARTHUR MATHEWSON,	408 5th Street,	Washington, D. C.
Dr. CHAS. H. McILWAINE,	264 Willis Avenue,	New York, N. Y.
Dr. R. J. McKAY,	Cor. 9th and Market Streets,	Wilmington, Del.
*Dr. S. C. MAXSON,	225 Genesee Street,	Utica, N. Y.
Dr. C. S. MERRILL,	23 Washington Avenue,	Albany, N. Y.
Dr. B. L. MILLIKIN,	200 Euclid Avenue,	Cleveland, Ohio.
Dr. HORACE GEO. MILLER,	262 Benefit Street,	Providence, R. I.
Dr. J. LANCELOT MINOR,	14 Randolph Building,	Memphis, Tenn.
Dr. W. F. MITTENDORF,	140 Madison Avenue,	New York, N. Y.
Dr. CHARLES A. OLIVER,	1507 Locust Street,	Philadelphia, Pa.
Dr. H. S. OPPENHEIMER,	741 Madison Avenue,	New York, N. Y.
Dr. R. J. PHILLIPS,	123 So. 39th Street,	Philadelphia, Pa.
Dr. THOMAS R. POOLEY,	107 Madison Avenue,	New York, N. Y.
Dr. WILLIAM C. POSEY,	1831 Chestnut Street,	Philadelphia, Pa.
Dr. M. H. POST,	Beaum't St., cor. Wash. Av.,	St. Louis, Mo.
Dr. H. R. PRICE,	1290 Pacific Street,	Brooklyn, N. Y.
Dr. J. S. PROUT,	26 Schermerhorn Street,	Brooklyn, N. Y.
Dr. WALTER L. PYLE,	1806 Chestnut Street,	Philadelphia, Pa.
Dr. ALEX. QUACKENBOSS,	71 Newbury Street,	Boston, Mass.
Dr. ALEX'R RANDALL,	1717 Locust Street,	Philadelphia, Pa.
Dr. R. L. RANDOLPH,	816 Park Avenue,	Baltimore, Md.
Dr. J. M. RAY,	423 West Chestnut Street,	Louisville, Ky.
*Dr. R. G. REESE,	58 East 25th Street,	New York, N. Y.
Dr. R. A. REEVE,	48 Bloor Street East,	Toronto, Canada.
Dr. H. O. REIK,	412 Cathedral Street,	Baltimore, Md.
Dr. STEPHEN O. RICHEY,	732 17th Street,	Washington, D. C
Dr. CHARLES E. RIDER,	53 South Fitzhugh Street,	Rochester, N. Y.
Dr. WHEELOCK RIDER,	53 South Fitzhugh Street,	Rochester, N. Y.
*Dr. G. O. RING,	1900 Chestnut Street,	Philadelphia, Pa.
Dr. H. W. RING,	187 Church Street,	New Haven, Conn
Dr. SAMUEL D. RISLEY,	1728 Chestnut Street,	Philadelphia, Pa.
Dr. EDMUND C. RIVERS,	1632 Welton Street,	Denver City, Col.
Dr. WM. K. ROGERS,	188 East State Street,	Columbus Ohio.
Dr. D. B. ST. JOHN ROOSA,	20 East 30th Street,	New York, N. Y.
Dr. DUNBAR ROY,	Grand Opera House Block,	Atlanta, Ga.
Dr. JOHN D. RUSHMORE,	129 Montague Street,	Brooklyn, N. Y.
Dr. ROBERT SATTLER,	7th and Race Streets,	Cincinnati, Ohio.
Dr. T. B. SCHNEIDEMAN,	1831 Chestnut Street,	Philadelphia, Pa.
Dr. G. E. DE SCHWEINITZ,	1705 Walnut Street,	Philadelphia, Pa.

NAME.	RESIDENCE.	PLACE.
Dr. P. N. K. SCHWENK,	810 North 7th Street,	Philadelphia, Pa.
*Dr. JOHN R. SHANNON,	25 W. 36th Street,	New York, N. Y.
Dr. HENRY L. SHAW,	19 Commonwealth Avenue,	Boston, Mass.
Dr. WM. T. SHOEMAKER,	2031 Chestnut Street,	Philadelphia, Pa.
*Dr. WM. A. SHOEMAKER,	1006 Carlton Building,	St. Louis, Mo.
*Dr. E. A. SHUMWAY,	2007 Chestnut Street,	Philadelphia, Pa.
Dr. F. D. SKEEL,	58 E. 25th Street,	New York N. Y.
Dr. J. A. SPALDING,	627 Congress Street,	Portland, Me.
Dr. MYLES STANDISH,	6 St. James Avenue,	Boston, Mass.
*Dr. E. W. STEVENS,	421 McPhee Building,	Denver, Col.
Dr. GEORGE T. STEVENS,	22 East 46th Street,	New York, N. Y.
*Dr. EDW. STIEREN,	Westinghouse Building,	Pittsburg, Pa.
Dr. SAMUEL B. ST. JOHN,	68 Pratt Street,	Hartford, Conn.
Dr. GEO. STRAWBRIDGE,	202 So. 15th Street,	Philadelphia, Pa.
Dr. T. Y. SUTPHEN,	999 Broad Street,	Newark, N. J.
Dr. WM. M. SWEET,	1205 Spruce Street,	Philadelphia, Pa.
Dr. LEWIS H. TAYLOR,	83 South Franklin Street,	Wilkes-Barre, Pa.
Dr. SAMUEL THEOBALD,	304 West Monument Street,	Baltimore, Md.
Dr. CH. HERMON THOMAS,	3634 Chestnut Street,	Philadelphia, Pa.
Dr. A. G. THOMSON,	1426 Walnut Street,	Philadelphia, Pa.
*Dr. EDGAR S. THOMSON,	19 E. 44th Street,	New York, N. Y.
Dr. WILLIAM THOMSON,	1426 Walnut Street,	Philadelphia, Pa.
Dr. JAS. THORINGTON,	120 South 18th Street,	Philadelphia, Pa.
Dr. JOHN VAN DUYN,	318 James Street,	Syracuse, N. Y.
Dr. C. A. VEASEY,	1833 Chestnut Street,	Philadelphia, Pa.
*Dr. F. H. VERHOEFF,	665 Boylston Street,	Boston, Mass.
Dr. O. F. WADSWORTH,	526 Beacon Street,	Boston, Mass.
*Dr. F. L. WAITE,	68 Pratt Street,	Hartford, Conn.
Dr. DAVID WEBSTER,	327 Madison Avenue,	New York, N. Y.
Dr. J. E. WEEKS,	46 East 57th Street,	New York, N. Y.
*Dr. CASSIUS D. WESTCOTT,	31 Washington Street,	Chicago, Ill.
Dr. J. A. WHITE,	200 E. Franklin Street,	Richmond, Va.
Dr. W. H. WILDER,	103 State Street,	Chicago, Ill.
Dr. CHAS. H. WILLIAMS,	1069 Boylston Street,	Boston, Mass.
Dr. WM. H. WILMER,	1610 I Street N. W.,	Washington, D. C.
Dr. F. M. WILSON,	834 Myrtle Avenue,	Bridgeport, Conn.
*Dr. WILLIAM L. WOOD,	412 Oregonian Building,	Portland, Oregon.
Dr. HIRAM WOODS,	842 Park Ave.,	Baltimore, Md.
Dr. J. P. WORRELL,	20 South 7th Street,	Terre Haute, Ind.
*Dr. S. LEWIS ZEIGLER,	1700 Walnut Street,	Philadelphia, Pa.
*Dr. WM. ZENTMAYER,	1819 Spruce Street,	Philadelphia, Pa.
Total, ...		168

HONORARY MEMBERS.

Dr. C. SCHWEIGGER, ...		Berlin, Prussia.
Dr. F. P. SPRAGUE, .	229 Commonwealth Avenue,	Boston, Mass.
Whole number, ...		170

MINUTES OF THE PROCEEDINGS.

FORTY-FIRST ANNUAL MEETING.

MEDICAL LIBRARY,
BOSTON, MASS., May 11, 1905.

The Forty-first Annual Meeting of the Society was called to order by the President, Dr. C. S. BULL, at 10 A. M. The President announced the following committees:

Committee on Bulletin — Drs. H. B. CHANDLER and E. E. JACK.

Committee on Membership — Drs. JOHN GREEN, S. THEOBALD, W. H. CARMALT, G. C. HARLAN, and MYLES STANDISH.

Auditing Committee — Dr. W. S. DENNETT.

The Committee on Bulletin reported and the following papers were read:

1. "A case of flat melano-sarcoma of the choroid with unusual clinical features," Dr. C. J. Kipp.

The following gentlemen were invited to attend the sessions as guests of the Society and take part in the discussions: Drs. G. S. Derby, C. W. Clap, F. M. Spalding, A. G. Morse, L. W. Mauser, E. T. Easton, and F. H. Verhoeff.

2. "Concerning melanoma of the choroid," with report of two cases. Drs. G. E. de Schweinitz and E. A. Shumway.

3. "Metastatic carcinoma of the ciliary body," Dr. C. W. Cutler.

Papers 1, 2, and 3 discussed by Drs. Taylor, Sutphen, Buller, Jack, Cutler, Weeks, Kipp, and de Schweinitz.

4. "The Sachs' lamp for transillumination of the eye," Dr. E. S. Thomson.

Discussed by Drs. Pyle, H. W. Ring, and Thomson.

5. "Improved surgical methods for the successful use of the electro-magnet," Dr. R. Sattler.

Discussed by Drs. Holt, Lambert, Marple, Hansel, Schwenk, Sweet, Risley, Fridenberg, Wadsworth, Ziegler, E. S. Thomson, Fiske, de Schweinitz, Callan, Weeks, and Howe.

6. "The attractive power of the magnet upon steel alloyed with other metals," Dr. W. M. Sweet.

Discussed by Dr. Hansell.

7. "Remarks on the use of the Roentgen rays in localizing foreign bodies in the eyeball and orbit," Dr. J. E. Weeks.

Discussed by Drs. Sweet and Weeks.

8. "What are the so-called reflexes which can be properly referred to eye-strain," Dr. L. Howe.

Discussed by Drs. Randall, Pyle, and Howe.

Adjourned to meet at 3 P. M. at Eye and Ear Infirmary.

Afternoon session called to order at 3 P. M. by President Bull.

9. "Symptoms presented by the different bacteriological types of acute conjunctivitis," Dr. A. Duane.

Discussed by Dr. Weeks.

10. "Relapsing iritis," Dr. H. Woods.

Discussed by Drs. Hansell, Kipp, Risley, Ziegler, and Woods.

11. "Juvenile glaucoma," Dr. R. Sattler.

Discussed by Drs. Posey, H. Harlan, H. W. Ring, and Sattler.

12. "Cyanosis retinæ," Dr. W. C. Posey.

13. "Acquired cyst of conjunctiva containing an embryonic tooth-like structure," Dr. E. L. Stieren.

14. "A case of cystic sarcoma of the orbit — extirpation — recovery," Dr. H. F. Hansell.

Discussed by Drs. Sattler and Hansell.

15. "Certain congenital affections of the eye coinciding with strong ante-natal impressions made on the mother," Dr. H. Derby.

Discussed by Drs. H. Knapp, Holt, Pyle, and Howe.

16. "Lesions of the fundus of the eye due to ptomaine poisoning," Dr. C. S. Bull.

[Society went into Executive Session at 5 P. M.]

On recommendation of the Committee on Membership, the following named gentlemen were elected associates of the Society: Drs. Edward Shumway of Philadelphia, Jno. R. Shannon of New York, F. H. Verhoeff of Boston, Allen Greenwood of Boston, Jas. H. Bell of San Antonio, Texas, William Zentmayer of Philadelphia, S. C. Maxson of Utica, N. Y.

The committee reported the following list of officers for the ensuing year, and they were all duly elected:

President — Dr. A. MATHEWSON.

Vice-President — Dr. C. J. KIPP.

Recording Secretary and Treasurer — Dr. S. B. ST. JOHN.

Corresponding Secretary — Dr. J. S. PROUT.

Publication Committee — Drs. W. S. DENNETT, D. W. HUNTER, and the Secretary (*ex officio*).

Treasurer's report was read and accepted. The annual assessment of $5.00 on each member was voted.

Voted to change the Standing Rule regarding the length of papers read before the Society from 20 minutes to 15 minutes.

The names of several applicants for membership were read by the Secretary and referred to the Committee on Membership for the next year.

Adjourned to 10 A. M. on 12th inst.

Thursday, May 12. Called to order by the President at 10 and reading of papers resumed.

Vice-President Mathewson called to the chair.

17. "Treatment of inoperable cases of malignant diseases of the orbit by the X-ray method," Dr. C. S. Bull.

Discussed by Drs. Theobald, Marple, Claiborne, Jack, Wadsworth, Roy, H. Woods, Duane, and Bull.

18. "Vernal conjunctivitis in the negro," Dr. Dunbar Roy.

Discussed by Drs. Pyle, H. Harlan, Gruening, Posey, Theobald, and Kipp.

19. "Value of so-called high-frequency current in certain ocular conditions (with illustrative cases)," Dr. J. C. Lester.

Discussed by Dr. Gruening.

20. " Tumors of conjunctiva and cornea," Dr. J. M. Ray.

21. "A case of discoloration of the cornea by blood-pigment and one of hemorrhage into the cornea," Dr. O. F. Wadsworth.

22. "A case of homonymous left-sided inferior tetartanopsia following toxic dose of salicylate of soda," Dr. J. H. Claiborne.

23. "A case of epithelial corneal cyst with microscopic and macroscopic specimens," Dr. J. H. Claiborne.

24. " Photophobia," Dr. Percy Fridenberg.

25. " Test type in geometrical progression," Dr. Jno. Green.

26. " A new test-type case," Dr. C. H. Williams.

Discussed by Drs. Green, Theobald, Jeffries, Wadsworth, and Standish.

27. " Some changes in the construction of eye instruments which have not been in the direction of improvement," Dr. S. Theobald.

Discussed by Drs. Standish, Wadsworth, and Theobald.

28. " The pupils in dementia paralytica," Dr. Holden (by title).

29. "A case of persistent pupillary membrane," Dr. Marple (by title).

Dr. H. Friedenwald was requested to prepare a memorial notice of the late Dr. R. Murdoch, one of our oldest members, who died in March last.

The Committee on Membership for the ensuing year was appointed by the President as follows: Drs. Carmalt (*chairman*), Theobald, George Harlan, Standish, and Harrower.

Drs. Callan, Risley, and Ewing were appointed as the members of the Ophthalmological Society to serve as part of the Joint Committee to decide the time and place of the next meeting.

Adjourned.

S. B. ST. JOHN,
Recording Secretary.

Present at the Forty-first Annual Meeting:

Dr. L. A. Prefontaine,
Dr. C. S. Bull,
Dr. S. B. St. John,
Dr. C. M. Culver,
Dr. H. B. Chandler,
Dr. W. T. Shoemaker,
Dr. Edw. Stieren,
Dr. H. H. Haskell,
Dr. Myles Standish,
Dr. Harry Friedenwald,
Dr. Hasket Derby,
Dr. B. Jay Jeffries,
Dr. C. W. Cutler,
Dr. W. L. Pyle,
Dr. L. H. Taylor,
Dr. F. W. Marlow,
Dr. F. M. Wilson,
Dr. J. D. Rushmore,
Dr. A. N. Alling,
Dr. G. Hay,
Dr. E. E. Jack,
Dr. G. E. de Schweinitz,
Dr. C. J. Kipp,
Dr. R. A. Reeve,
Dr. P. A. Callan,
Dr. W. B. Marple,
Dr. H. W. Ring,
Dr. H. Woods,
Dr. Dunbar Roy,
Dr. F. P. Capron,
Dr. J. A. Andrews,
Dr. F. E. Cheney,
Dr. O. F. Wadsworth,
Dr. C. H. Williams,
Dr. A. Quackenboss,
Dr. T. R. Pooley,
Dr. G. F. Fiske,
Dr. W. T. Bacon,
Dr. F. L. Waite,
Dr. J. W. Charles,
Dr. N. J. Hepburn,
Dr. E. Gruening,
Dr. D. B. Lovell,
Dr. W. E. Lambert,
Dr. S. D. Risley,
Dr. J. H. Claiborne,
Dr. J. C. Lester,
Dr. T. Y. Sutphen,
Dr. A. Mathewson,
Dr. H. L. Shaw,
Dr. D. Harrower,
Dr. E. E. Holt,
Dr. H. O. Reik,
Dr. P. Fridenberg,
Dr. P. N. K. Schwenk,
Dr. R. Sattler,
Dr. L. S. Dixon,
Dr. E. S. Thomson,
Dr. H. R. Price,
Dr. H. W. Kilburn,
Dr. A. Duane,
Dr. B. A. Randall,
Dr. C. W. Haddock,
Dr. A. A. Hubbell,
Dr. J. M. Ray,
Dr. H. Harlan,
Dr. H. F. Hansell,
Dr. Wm. S. Dennett,
Dr. W. M. Sweet,
Dr. L. Howe,
Dr. J. E. Weeks,
Dr. H. Knapp,
Dr. D. Coggin,
Dr. W. C. Posey,
Dr. F. H. Verhoeff,
Dr. W. T. Craig,
Dr. H. S. Oppenheimer,
Dr. W. N. Holden,
Dr. H. G. Miller.
Dr. John Green,

In Memoriam

DR. RUSSELL MURDOCH.

By Dr. H. FRIEDENWALD.

Dr. Russell Murdoch, one of the oldest members of this Society, died March 19, 1905.

Dr. Murdoch was born in Baltimore, February 12, 1839. Much of his early life was spent in Scotland and his collegiate education was received at the University of Edinburgh (1856-59). He returned to this country to study medicine at the University of Virginia, where he was graduated in 1861. Soon after, he became the resident physician of the Baltimore Almshouse and later, (1862,) attending physician to the Baltimore General Dispensary. In 1862 he was appointed surgeon in the Confederate Army and served in the engineer corps until the close of the war. He was with General Lee at the surrender at Appomatox.

After the war he took up the study of ophthalmology here and abroad and, again returning to Baltimore, became the "Lecturer on Diseases of the Eye and Ear" at the University of Maryland (1868-69). About this time Dr. Agnew invited him to come to New York as his associate, but he declined.

He was one of the founders of the Baltimore Eye, Ear, and Throat Charity Hospital in 1882 and an attending surgeon until his death.

For several years he filled the Chair of Ophthalmology and Otology at the Woman's Medical College of Baltimore (1884-87).

Dr. Murdoch was elected a member of this Society July 21, 1868.

He was married in 1873, and his wife died about eight years ago, leaving him four daughters, of whom two have devoted themselves to medicine.

For several months previous to his death he had been failing in health, but he was able during almost the entire period to attend to his numerous duties. On March 18th he performed a cataract operation. After its completion, while speaking to a colleague, he suffered an attack of apoplexy; at first very slight, it slowly increased in severity. He remained conscious for five hours during which he was cheerful and concerned only because of the



Sam sincerely yours,
Russell Murdoch.

discomfort of his friends. After losing consciousness he lived but a few hours, dying at 12.30 A. M., March 19, 1905.

This is a meagre outline of the life of a man who in many ways was remarkable. He was many-sided. Well trained in the natural sciences, especially in zoölogy and botany, he took an active and continued interest in the Maryland Academy of Sciences until his death. His special studies were in the comparative anatomy of the eye, a subject upon which he was an authority and about which he addressed several scientific assemblies.

He had great artistic talents to which his works in sculpture testify. Several reliefs which he executed are well known in his community and highly prized. His inventive skill produced a number of very useful instruments, the best known of which is his eye speculum; an enlarged form of this he devised as a mouth-gag.

As a physician he was ever anxious to keep in touch with all advances in medicine, and he was not only an extensive reader in Ophthalmology, but of the entire range of medicine. It is but a few years ago that the writer remembers his reading Osler's Practice, works on Clinical Examination, Chemistry, Anatomy, etc., and his reviewing the subject of Pathological Histology.

He was an able and successful operator, and was one of the few men of his years who was ready and eager to apply rigidly the rules of asepsis. In his relation to patients, public as well as private, his gentleness and kindness and patience were extreme.

He was a spiritual man and a member of the Presbyterian Church, to which he devoted much time. But though intensely religious he was very tolerant of the views of others. His great familiarity with the Bible was a constant source of wonder to his friends.

Few knew Doctor Murdoch well. He was a modest man and his disposition was to retire from the public gaze into the privacy of his home, his office, his clinic. But those who knew him well admired him not only for his great skill and learning, his broad interests, and wide scope of information, but especially for his gentleness, his kindly nature, his high sense of right and justice, his leniency in judging the frailties of others, his nobility of character.

TWO CASES OF MELANO SARCOMA OF THE CHOROID.

BY CHAS. J. KIPP, M.D.,
NEWARK, N. J.

With Four Figures on Text Plates Nos. 1-4.

CASE I. *A diffuse Melano Sarcoma of Choroid with Unusual Clinical Features.*

F. W. W., aged 40, of spare build, but in good health. He was seen on June 4, 1901. He was seeking relief for pain and inflammation of his right eye. The left eye was normal. In the right eye the ocular conjunctiva adjoining the lower outer margin of the cornea was raised in the form of a bleb, by a light yellowish fluid, and the superficial vessels were somewhat injected. The swelling extended about 1 mm. outwards, and was most prominent at the corneal margin. There was no deep-seated injection. Elsewhere the ocular conjunctiva was normal in appearance. The cornea was perfectly normal, the anterior chamber was of normal dimensions, the iris was normal; the pupil of the same size as that of the other eye and active. The lens and vitreous body were perfectly clear. The optic disc was normal in appearance, and so was the retina, except at the outer periphery, where it was somewhat milky and apparently detached. The milkiness did not extend to the region of the macula.

The eye was emmetropic and S 6/5. The V. F. was defective in nasal periphery. Tn.

He stated that his eyes had never given him any trouble up to three months ago. At that time while splitting wood, a fragment of the same struck him on the right temple and brow. This was followed by a black eye. This passed away and left his vision unimpaired. Since then he has had three attacks of pain and swelling just like the one from which he is suffering now. Between the attacks the eye had given him no trouble whatever.

He was again seen a few days later, when the bleb had en-

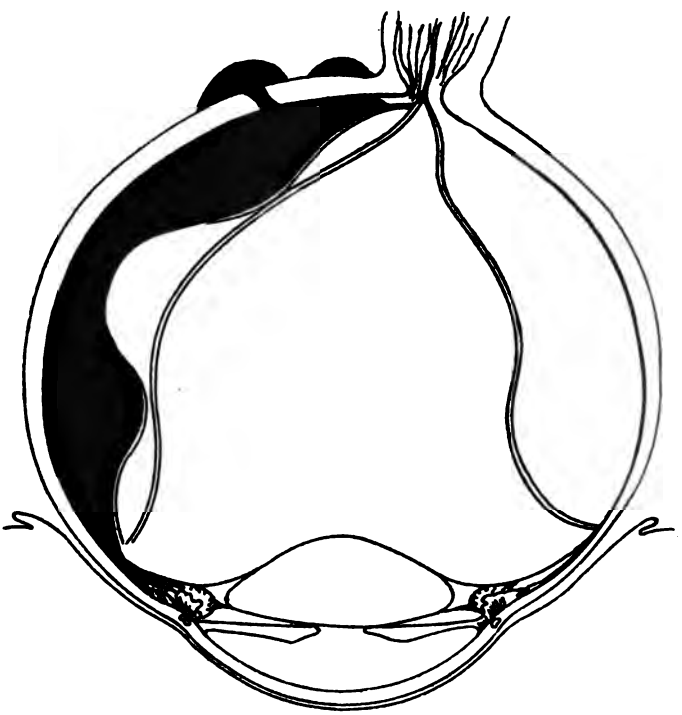

F.G. I.
LOWER HALF OF RIGHT EYE—KIPP.

tirely disappeared and the anterior part of the globe was apparently normal. On December 21st he came again. He had now another attack of pain and chemosis just as before. He stated that he had had several similar attacks since his last visit. On this date it was found that vision was reduced to less than 5/60. The ophthalmoscope showed that the opacity of the retina now involved the region of the macula. The temporal periphery of the retina seemed more transparent, and the detachment had apparently disappeared. Beneath the hazy retina, especially at the periphery of the opacity, shoals of dark pigment were visible; some of the pigment was apparently also in the retina itself. The opaque area extended to the disc, and two or three disc's diameters outward, and about one disc's diameter above and below the yellow spot. The opaque area was crossed by a large vessel of very bright red color, running from the disc toward the temporal periphery; it was best seen with a convex glass 2 D, while the disc was best seen without a plus glass behind the ophthalmoscope. No choroidal vessels were visible anywhere. The V. F. was contracted above and below, and there was an absolute scotoma extending from the point of fixation 50° inwards, and on an average about 15° above and below. He could count fingers at five feet. Tension was still normal.

A few days after this visit he was seen again. The chemosis and the injection had disappeared. At this visit the patient informed me that he had seen Dr. Knapp, and had been told by him that he had a tumor in his eye.

On October 12, 1902, he had another attack of pain, injection and oedema of the ocular conjunctiva. The fluid under the conjunctiva was of a yellowish color. The ophthalmoscopic appearance was about as before, there was no decided Increase in the dimensions of the opaque area of the retina, and it was no more prominent than before. This attack passed away in a few days under instillations of cocaine and boric acid solutions.

On February 19, 1903, he came again with an attack like those previously described. He had much pain, and the chemosis was more extensive, involving the whole lower half. The pupil was

somewhat dilated at this visit, and, on closing the good eye, it expanded very widely. At this time I found detachment of the retina below. The disc is seen without difficulty, and is apparently normal. The opaque area of the retina is unchanged, except that more dark pigment is visible under its peripheral portion. There are now also seen masses of dark pigment under this transparent retina on nasal side of disc. Tn.

The attack passed away like the others, in a few days.

On May 8th he had an attack of catarrhal conjunctivitis in left eye. The ophthalmoscopic examination of this was negative. S 6/5, V. F. intact.

On May 21st he had another attack of pain, injection, and chemosis. The eye was totally blind. I advised enucleation of the eye. On May 23d I removed the eye. The wound healed in a few days.

May 18, 1904. Has been in good health since last report. Ten days ago had pain in forehead, both sides, followed by vomiting next day. Skin of forehead and both sides of nose so sore that he could not touch it. Eye was not affected. Pain over left brow has continued off and on since. Yesterday afternoon noticed for the first time that left eye was red. Now injection of outer half of sclera, oedema of conjunctiva same side only. Only conj. vessels are injected. O. negative. S. 6/5. V. F. intact for white; blue, and red only 15° from fixation, green 10°. Vessels contracted promptly after adrenalin. A large wart has developed on the outer side of right nostril a short distance from orifice.

April 2, 1905. Is in good health, has been at work ever since last report. No signs of local relapse. Left eye normal. Has not had another attack of conjunctivitis since last report. The papilloma at orifice of nose has not grown.

The anatomical examination of the eye showed it to be of normal form; the exterior of the globe was normal, except at posterior pole, where about a mm. to the temporal side, in about the horizontal meridian there was found a hard nodule, in appearance like cartilage about the size of a lentil, and a dark colored nodule somewhat larger about 5 mm. Further outwards and be-

FIG. II.
SHOWING ALVEOLAR ARRANGEMENT OF CELLS NEAR BRUCH'S MEMBRANE DEGENERATED RETINA.



tween these two elevations was seen a large distended vein. The globe was divided in horizontal meridian. The retina was found detached, except over portion of tumor where it seemed to be fastened. The subretinal exudation was coagulated. The optic papilla was flat, not excavated. In the temporal half the choroid was of very dark color, was very much thickened throughout; in most places it was about 3 mm. thick, but in three places in different parts of the temporal half it was from 6 to 7 mm. thick, thus giving it a nodular appearance. These elevations arose gradually out of the flatter parts with sloping sides and rounded crests. The thickened part of the choroid extended antero-posteriorly from the ciliary body to the optic disc, above it reached the median line, below it extended somewhat beyond the median line. The nasal half of the choroid did not seem much altered. The ciliary body was apparently normal, the lens was in its place and transparent. The iris was not thickened. The anterior chamber was of normal dimensions, and the cornea was perfectly normal in appearance. (See Fig. 1.)

The microscopic examination showed this growth to consist of pigmented polygonal cells. In most parts of the tumor the pigment present was so abundant that the form of the cells could be made out only with difficulty. Areas of non-pigmented cells, mostly spindle-shaped, were in some places found surrounded on all sides for some distance by densely pigmented cells. In other parts groups of non-pigmented cells, distinctly spindle-shaped, were seen in contact with the sclera and in other portions under the vitreous lamina. In other parts islands of non-pigmented cells were seen within large areas of pigmented cells. The cells were everywhere densely crowded together. Scrapings from the surface of the sections of the tumor, made before the eye was put in the formalin solution, showed that both spindle-shaped and polygonal cells were present. A very distinct shining nucleolus could be seen in the oval or round nucleus of the non-pigmented cells. Pigment was present also in the form of very minute particles in large clumps and in shoals. In some parts nothing but clumps of pigment imbedded in a glossy structureless mass could

be seen. The growth had destroyed the suprachoroidea in many places. In other parts sarcoma cells filled the separated laminae of this layer, thus presenting an alveolar or pluxiform arrangement. (See Fig. 2.) The growth had invaded the sclera in several places, and had almost destroyed it in some parts. Several large vessels perforating the sclera were lined in their interior by fine dust-like particles of pigment. The epibulbar growths previously noticed, consisting almost entirely of non-pigmented round cells, between which there was scarcely any intercellular substance. A few pigment cells were scattered among the non-pigmented cells. In the center of one of the epibulbar nodules a large collection of red blood cells was found. The growth had only in a few places, corresponding to the highest elevation, broken the vitreous lamina. A layer of fibrous tissue was found between the vitreous lamina and the retina. At the summit of the growth the retina was adherent to this layer of fibrous tissue and had undergone fibrous degeneration. The growth was but poorly supplied with vessels. Most of those in the thicker parts of the growth were without distinct walls, they seemed to be merely vascular channels in the growth. In some parts the walls of the vessels had undergone hyaline degeneration. The choroid adjoining the thickened part was densely infiltrated with round cells for some distance from the edges of the tumor, but whether they were white blood corpuscles or young sarcoma cells I could not make out. The growth had not invaded the optic nerve or the retina.

The anatomical diagnosis is therefore diffuse melano sarcoma of choroid, consisting chiefly of pigmented polygonal cells and unpigmented spindle cells, which have invaded all layers of this membrane, perforated the sclera, and has extended outside of the globe.

I regret that I have been unable to formulate for myself a satisfactory explanation of the peculiar clinical features of this case. That the localized oedema of the eyeball was due to a lymph stasis goes without saying, but why this occurred only at intervals of weeks and lasted only for a few days I do not understand. When I first saw the case I considered the oedema due

FIG. III.
SHOWING POSITION OF TUMOR, HORIZONTAL SECTION OF GLOBE.

to filtration. I thought that a small wound in sclero-corneal margin now covered by conjunctiva, the result of the traumatism, might permit the fluid to escape from the anterior chamber, but this had to be given up, as no opening could be found. The pain with which the oedema was ushered in made me think of increased tension, but careful and repeated examination of the eye soon after the beginning of an attack failed to reveal either an increase in tension or indeed any symptoms of glaucoma besides the pain. The anterior chamber was always found of normal dimensions. There was, moreover, no deepseated injection during the attacks, only a few of the superficial conjunctival vessels being injected.

The fact that this patient had a somewhat similar attack of localized chemosis in the other eye, some time after the enucleation of the eye which contained the sarcoma, and that this also was attended by intense pain over the left eye, and indeed the whole forehead, and that it was followed by vomiting, would seem to point to a neuralgic character of the attack, though he never had similar attacks before he sustained the injury to his right eye, nor has he had any for the past year.

A point of interest in this case is also the fact that a blow on the eye preceded the development of the sarcoma by about three months. There is no evidence that the globe was perforated, but the marked changes in the temporal periphery of the retina, found at the first examination, make it highly probable that the traumatism had a share in their causation.

So far as my reading goes, there is no case on record of a sarcoma of the choroid in which there were symptoms similar to those present in this case, and this must be my excuse for bringing the case to your notice.

CASE II. *A Small Circumscribed Melano Sarcoma of Choroid with Early Invasion of the Sclera.*

Mrs. H. F., 50 years of age, in good general health. Neither parents or sisters or brothers have eye disease, or have had malignant disease of any part of body. The right eye is normal. Mas.

1, 5 D. 180° S. 6/5. A few weeks ago noticed blur before left eye, which has gradually increased till now, February 28, 1904. Has now absolute central scotoma. Periphery of V. F. not contracted. Externally eye is normal. Media clear, disc normal, retina normal except just below macula, where it is opaque and somewhat prominent. This opaque area is somewhat larger than the disc, and at its margin the choroidal pigment is irregularly distributed. The surface of opaque portion is best seen with a +2 D. glass, while the rest of the fundus is slightly myopic, about 1.05 D. The tension of the eye is normal. She complains of occasional pain in eye.

Two months later the opaque region was somewhat larger and more prominent, otherwise there was no change. No increased tension. I enucleated the eye in April, 1904.

The wound healed in a few days. No relapse in orbit, patient's general health is still good, April 30, 1905.

I opened the globe immediately after its removal, and found the retina in its place. (Fig. 3.) The tumor at the macula measured about 6 mm. in diameter, and was not over 2 mm. in height. It was disc-shaped and bi-convex, and tapering off at its edges. Its posterior edge lies 3 mm. from optic nerve entrance. The growth is covered by the pigment layer of the retina, and its central part is in contact with the sclera, which it has invaded in several places. (Fig. 4.) The growth is made up of small non-pigmented spindle cells mixed with a few pigmented ones. The adjacent blood vessels of the choroid are congested. The new growth is sharply outlined, though not encapsulated. The retina was in its place. The other structures of the eye were entirely normal.

The point of interest in this case seems to me to be the early invasion of the sclera. The growth was probably only four months old; was only 6 mm. in diameter, and not more than 2 mm. in height when the eye was enucleated. While the tumor was distinctly circumscribed and the lamina vitria was intact, it had destroyed the supra choroidea under its central portion, and had invaded the sclera to a considerable extent.

FIG. IV.

SHOWING INVASION OF SCLEROTIC BY TUMOR CELLS.



CONCERNING MELANOMA OF THE CHOROID, WITH REPORT OF ONE CASE OF THIS CHARACTER AND OF ANOTHER EXHIBITING A PIGMENTED SARCOMA OF THE CHOROID EARLY IN ITS DEVELOPMENT.

BY G. E. DE SCHWEINITZ, A.M., M.D.,
AND
E. A. SHUMWAY, M.D.,
PHILADELPHIA, PA.

That sarcomas may develop from pigmented nevi in various parts of the body is well known, and is a subject which has attracted considerable attention and created much discussion. The origin of malignant tumor-formations in the skin from points where nevi had previously existed was first pointed out by Virchow.[1] Unna, Kromayer, and others believe that these growths arise from cells which are derivatives of the surface epithelium, but other pathologists regard them as connective tissue growths, Ziegler believing that they are the result of proliferation of the endothelial cells of the lymph vessels, which have the property of producing pigment.

In the conjunctiva the same conditions are found and many cases are now on record in which sarcomas have developed from pigment spots, usually on the eyeball, and more rarely on the eyelids. These growths are usually alveolar in type, and have been considered by Panas, Leber, and others to be carcinomatous rather than sarcomatous. Wintersteiner, on the other hand, in a paper before the Heidelberg Society[2], showed that most of the cases arose as the result of frequent slight traumatisms, from previously existing melanomas, and with Greeff, Ginsberg, and others, considers them sarcomatous.

1 Onkologie, Vol. II, pp. 122, 234, 272.
2 Bericht der Ophth. Gesellschaft, Heidelberg, 1898.

Furthermore, it has long been well known that sarcomas of the iris likewise arise from melanotic spots in the iris stroma. Hirschberg[3] in a paper on this subject reported three cases out of sixteen in which pigment spots had existed before the growths developed, and more recently Wood and Pusey,[4] in their exhaustive article on primary sarcoma of the iris, record ten cases out of eighty-six in which a conjunctival pigment spot had been present, and seventeen others in which a dark spot had existed for varying periods of time before the sarcoma appeared. A similar origin of sarcomas of the ciliary body is recognized.

Several cases have been described in which sarcoma of the choroid has been found in association with congenital pigment spots elsewhere. Hulke[5] was the first to report a case of this character in a woman sixty-two years old, who had congenital pigment spots in the eyebrow, lids, and sclera. Hirschberg[6] records two cases. One of his patients was a woman, 34 years old, who had pigment spots in the sclera and one dark-colored iris, the iris at the opposite side being greenish brown. In another patient, a woman, 56 years old, the iris was dark brown (on the other side greenish-gray,) and there were pigmented spots in the sclera. In this case an anatomical examination of the eyeball was made, and revealed a partly pigmented growth in the choroid. Martens[7] records the following case: In a girl of 13 years there were several small nevi in the face, large grayish-black pigment spots in the sclera, reaching back of the equator, and dark brown pigmentation of the lower part of the iris. All of these conditions had been present since birth. On examination of the enucleated eyeball, a marked proliferation of the pigment cells was found at the position of the dark spots in the iris, and there was a large pigmented tumor in the choroid near the nerve entrance.

Pigmented nevi have also been found in the choroid in a few

3 Archiv. f. Ophth., XXIX, 2, p. 1.

4 Archives of Ophthalmology, XXXI, 1902, p. 323, and Archiv. f. Augenheilk, XLVII, 1903, p. 97.

5 Ophthalmic Hospital Reports, III, 1860.

6 Archiv. f. Ophthalmologie, XXIX.

7 Virchow's Archiv., Vol. 138, p. 111.

instances. Purtscher[8] found a marked thickening of the choroid, constituting a tumor, composed purely of chromatophores, in connection with other areas which represented nevi.

Fuchs[9] exhibited sections of an eye before the Heidelberg Congress in 1900 which showed collections of closely massed pigmented spindle cells in the macular region, which were grouped around the bloodvessels, chiefly in the layer of larger vessels. The chorio-capillaris and retinal pigment cells were undisturbed, and Fuchs said of the condition: "Whether a sarcoma would have developed upon the site of these pigmented areas had the patient lived longer, we cannot know positively. We can only say that their appearance is exactly similar to that of a spindle-celled sarcoma." In the discussion of Fuchs' paper, Wintersteiner remarked that he had found similar growths in two eyes during pathological examination. In one case there was a melano-sarcoma, and in the other a leuco-sarcoma, both arising in the layer of larger vessels, and invading the chorio-capillaris very slightly. Their greatest diameter was 4 to 5 mm. and their thickness hardly 0.5 mm. Further details were not given, but in a private communication to Derby, who has recently[10] reported a case of sarcoma of the ciliary body at a very early stage, Wintersteiner says that he expects to report them in full.

In considering the rarity of these findings it has seemed worth while to report the following cases, one of which represents a pigmented nevus or melanoma of the choroid, and the other a commencing pigmented sarcoma at a very early period in its development.

CASE I. *Fibro-sarcoma of the inferior and superior parietal convolutions; optic neuritis; melanoma (pigmented nevus) of the left choroid.*

History.[11] The patient, a colored woman, aged 32, a laundress by occupation, was admitted to the Philadelphia Hospi-

8 Archiv. f. Ophth., L, 1900.

9 Bericht der Ophth. Gesellschaft, Heidelberg, 1900.

10 Klinische Monatsblattēr f. Augenheilk., Beilageheft, 1903, 123.

11 This history is quoted from Dr. C. K. Mills's report of these cases, Philadelphia Medical Journal, February 8, 1902.

tal, October 11, 1901. Her family history was good, and no certain history of syphilis was obtained, although the infection seemed probable from some of the patient's statements.

Some months previous to her admission to the hospital, but just when she could not accurately fix, she began to lose power in her right leg. About the same time, or just previous to the impairment in her right leg, she began to suffer with headache, which gradually became more frequent and persistent. She stated that she became temporarily blind during the paroxysms of severe headache. The headaches at first would sometimes last half a day, at others for several days. The loss of power in the right leg increased, and during the month previous to her admission the right arm also became paretic.

She was first examined by one of the internes a day or two after admission. She was at that time well nourished. She complained bitterly of headache and evidently suffered greatly. Her tongue was slightly coated and moist; her pulse was full, strong, and regular. Examination of the chest and abdomen resulted negatively.

The right side of the face was paretic. Speech seemed a little slow at times, but all forms of aphasia were absent. Loss of power was marked both in the right leg and right arm, but more complete in the leg than in the arm. Knee-jerk was exaggerated on the right and about normal on the left. Patellar clonus was present on the right and absent on the left. Ankle clonus was absent, as was also the Babinski reflex, on both sides. No impairment of sensation was noted at the time of the first examination, but a careful examination for sensation was not then made. The right leg showed spasticity and tremor, and the right arm was spastic at the elbow.

The conditions at the time of the first examination of the patient by Dr. Mills (about October 18, 1901) were as follows: The right side of the face was paretic; paralysis was marked in both leg and arm, but was more complete in the leg. The only movement retained in the lower extremity was partial flexion of the thigh on the pelvis. Sensation to touch and pain was nearly

lost in the right upper extremity; it was but slightly impaired in the right lower extremity. Impairment of muscular sense was also a marked feature. Astereognosis was present and became more and more positive as the case progressed to its termination. All forms of cutaneous sensibility and muscular sensibility were tested by the usual methods, with the result of showing impairment which as time passed became more and more complete in the upper extremity. The so-called senses of locality, position, pressure, and spacing were found wanting. In the right lower extremity the quadriceps jerk and knee jerk were exaggerated, and patellar clonus was marked. The front tap phenomenon was present. Ankle clonus, however, was absent, this absence being unusual in cases in which patellar clonus and front tap are present. The muscle and tendon jerks in the upper extremity of the right side were increased; on the left side, both in the lower and upper extremities, they were about normal.

On October 23, 1901, the patient's eyes were examined by Dr. de Schweinitz, who made the following report: The external aspect of the eyes is normal; the visual acuity of each eye, without correction, equals 5/25. The pupils are round, equal in size, and their reactions are normal in all respects. There is no difference in the width of the palpebral fissures, the levators have full power, and the rotation of the eyeballs is unimpaired in all directions. Although there is a history of diplopia, it is not possible to demonstrate double vision by the usual methods, nor does any examination reveal paresis of any external ocular muscle. With the ophthalmoscope the following conditions are evident: Marked bilateral optic neuritis (choked disc), the swelling of the nerve-heads approximating 3 mm., their apices being reddish-white in color and gradually passing into a grayish tint. Upon the swollen papillæ and in their immediate neighborhood are numerous flame-shaped, fresh hemorrhages. The arteries are about normal in size; the veins are very dark in color and exceedingly tortuous. In the macular region are areas of yellowish-white infiltration somewhat similar to lesions found in renal retinitis. Examination of the visual field reveals typical right homony-

mous hemianopsia, the dividing line passing around the fixing point and leaving it within the region of preserved vision. The preserved half fields are of normal size. It was not possible to obtain a satisfactory color field.

A tumor was diagnosticated from the general symptoms, and owing to the combination of motor paralysis with impairment of cutaneous sensation, astereognosis and hemianopsia, the diagnosis was made of a dense tumor of large size, probably in the main subcortical, situated chiefly in the parietal region, possibly invading the motor region, and extending to or compressing the posterior limb of the internal capsule and the optic radiations where they approach one another in the region of the basal ganglia.

An operation designed to expose the growth was performed by Dr. W. J. Hearn and Dr. J. Chalmers Da Costa, and the larger part of the tumor was removed. The patient died, and at the autopsy the following conditions were found: Calcareous endocarditis; chronic interstitial nephritis; and congestion and emphysema of the lungs. This tumor chiefly involved the white matter of the superior and inferior parietal convolutions and the middle portion of the post-central convolution. It proved to be a fibrosarcoma.

The posterior half of each eyeball was removed, and after hardening in formalin submitted to examination.

Microscopical Examination. Case I. The posterior half of the left eye was imbedded in celloidin and cut in serial sections, parallel to the long axis of the nerve. There is a high-grade swelling of the nerve-head, the top of the elevation reaching a height of 1.25 mm. above the level of the scleral ring. There is a slight round-cell infiltration about the central vessels and a decided proliferation of the connective tissue cells along the pial septa. The fibers of the nerve are widely spaced one from the other, but the intervaginal space is not widened. The retina is detached (probably as the result of manipulations in removing the posterior half of the eye); it is edematous and exhibits moderate postmortem changes.

The choroid is very densely pigmented throughout, the cells

Fig. 1. Melanoma of Choroid.

Fig. 3. Case II. Choroidal sarcoma in very early stage. Low power.

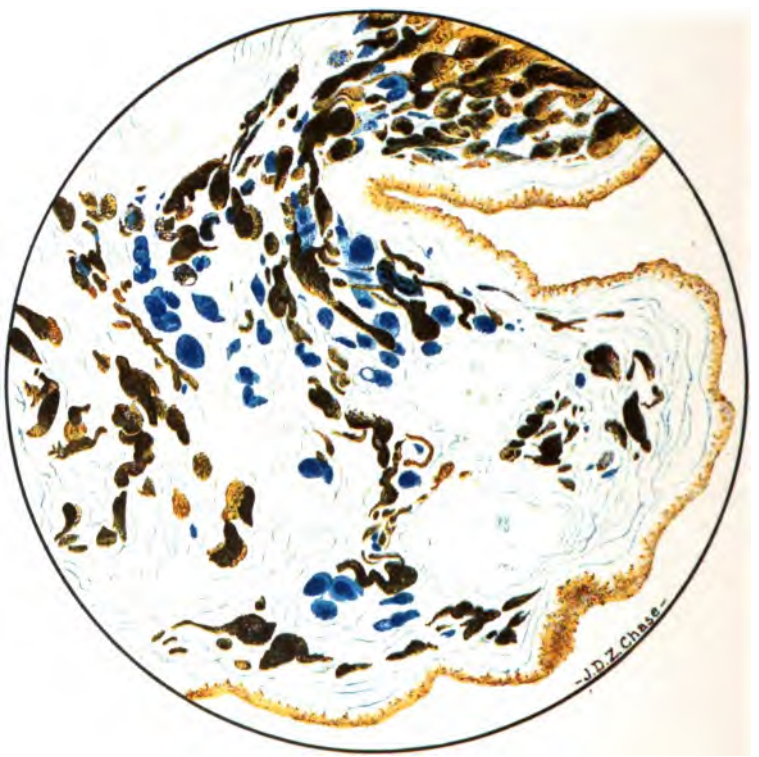

Fig. 2. Melanoma of choroid showing iron reaction in some of the cells.

being almost solid with very black pigment, which conceals absolutely their nuclei. This pigmentation spreads into the sclera in the inner layers, and particularly along the bloodvessels and the sheaths of the perforating nerve trunks. At one point, 3 mm. from the nerve entrance, there is a special thickening of the choroid, which is plainly visible to the naked eye. Measured carefully with a micrometer eye-piece, its long diameter is 1.2 mm. and its greatest width 0.5 mm. (Fig. 1). There is no evidence of any inflammatory reaction at this point. The retina is not attached, there are only a few leucocytes in the vessels of the area and in its vicinity, and the retinal pigment layer, which has remained adherent over it, shows no decided changes, although there is a slight increase in the pigment. The thickening in the choroid is made up of closely massed pigment cells, of the usual type of the choroidal stroma cells. Some of them are slender spindle cells with long processes; others are round and oval forms with short processes, and there are a number of very large round bodies, likewise densely pigmented, which show no processes. In addition to these cell forms pigment is scattered in irregular clumps in the tissue between the unpigmented cells which make up the rest of the mass. The blood vessels are distended, contain a moderate number of leucocytes, and exhibit a decided swelling of their endothelium, but there is no evidence of perivascular new formation.

The use of the ferrocyanid-hydrochloric acid test for iron revealed an interesting condition. The majority of the cells did not stain, but at each end of the growth in exactly the same position in several sections thus treated, a group of the pigmented cells stained a deep blue color where they tapered off into the normal choroid. At one point there were two large blood vessels in their vicinity, as will be noted in the colored sketch by Mrs. Chase (Fig. 2). The bluing can also be seen between the cells, as though there was iron in solution in the tissue, which was being absorbed by the cells.

In the absence of evidences of inflammation past or present, it seems proper to consider this choroidal thickening as a *melanoma*

of the choroid, in an eye with great increase of the pigment throughout the uveal tract as far as the sections reach.

CASE II. *Endothelioma of the dura mater; optic neuritis; melanosarcoma of the choroid at a very early stage of its development.*

History. J. T., white, aged 47, was admitted to the Polyclinic Hospital in Philadelphia, on April 12, 1899, in the service of Drs. William G. Spiller and Max J. Stern, at which time the following history was elicited:

Sixteen years before admission he struck his head against a joist, producing an injury of the left fronto-parietal region. This was followed by occasional attacks of dizziness, but no headache or other sequelæ. In 1891, enlargement of the affected area in the head was noticed, which gradually increased. Three years before he came to the hospital he began to have weakness in the right leg, which gradually became more pronounced but was not accompanied with sensory disturbances. He stopped work in February, 1898, at which time he noticed commencing aphasia, trouble in starting urination, and failure of vision. Seven weeks before examination there was a general epileptiform convulsion, which lasted fifteen to twenty minutes, and three weeks later severe occipital headaches made their appearance, which became progressively more severe and were occasionally associated with nausea. With these symptoms there was also marked loss of memory.

At the time of admission the records state that ophthalmoscopic examination showed bilateral optic neuritis, with secondary atrophy; the fields of vision were contracted, both for form and color. No mention is made of any growth within the eyeball.

On April 15, 1899, a craniotomy was performed by Dr. Stern, a large flap of thickened bone being elevated. A large inoperable tumor was found, and no attempt was made to remove it. Death occurred three hours after the operation.

At the autopsy permission was obtained to examine only the head. A large depressed area was found in the skull, with exos-

toses on the inner surface of the bone, and a large tumor of the dura mater, which measured 4 by 5 cm. antero-posteriorly, and dipped downward a distance of 2 cm. into the left hemisphere, situated just in front of the Rolandic fissure. The growth proved to be an endothelioma of the dura mater.[12]

Microscopic Examination. Case II. At the time of autopsy the posterior half of the left eye was removed and given to Dr. Shumway for investigation. It was placed in Müller-formol, imbedded in celloidin and cut in serial sections. Microscopic examination of these sections shows an elevation of the optic nerve-head to a level of 1 mm. above the choroid, swelling of its fibers, and separation of the individual fibers as the result of a preëxisting edema. There is also a moderate cellular infiltration along the lines of the pial septa. The retina shows swelling and edema of the nerve-fiber layer, with hypertrophy of Müller's fibers, and irregular elevations on the posterior surface.

The choroid is quite deeply pigmented throughout, this pigmentation extending also to the inner layers of the sclera. At a point 5 mm. from the center of the optic nerve, there is a pigmented thickening of the choroid which is visible to the naked eye, and was noted while the sections were being cut. This area measures 4.4 mm. in its antero-posterior diameter, and 0.9 mm. in thickness (Fig. 3).

Microscopically, thin sections show that this growth or thickening may be divided into two portions, a more densely pigmented part on the inner surface toward the retina, and a lighter part toward the sclera. It is situated in the layer of large vessels, the chorio-capillaris being practically uninvaded. The pigmented portion is composed of closely packed pigmented cells, some of which are of the type of the ordinary stellate stroma cells of the choroid, with long pigmented processes, while others are large round cells without processes, which are so densely pigmented that the nuclei are rarely visible. The outer portion is made up chiefly of spindle cells, without processes, which contain no pig-

12 The case was reported in detail with the pathological findings by Drs. Spiller, Stern, and Kirkbride in 1899 at a meeting of the Pathological Society of Philadelphia. From their account the history just recorded has been obtained.

ment. These are proliferating between the vessels, and displacing the stroma of the choroid. Between them there is a considrable amount of pigment, in the form of light yellow clumps, free in the tissue. These spindle cells, compared with the cells of the growth from the dura, are seen to be very similar in size and form, but they do not group themselves together in whorls, and do not show any definite relations with the blood vessels, as do those in the brain tumor. There is a moderate leucocytosis in the vessels of the chorio-capillaris, and at the margin of the growth. In the center of one of the sections is a large open space, filled with round and oval cells that vary in diameter from that of a white blood corpuscle to four or five times this size, which are densely crowded with pigment. With them there are a few leucocytes. Whether they represent wandering cells which have taken up pigment, or are degenerated chromatophores, has never been settled. In this growth they appear to be in a large lymph space, they are not associated with red corpuscles, and do not give an iron reaction.

The retina is detached, but this probably occurred in removing the half of the eye, as there is no evidence of the existence of a sub-retinal exudate. The pigment cells of the retina remain attached to the choroid. They show degenerative changes, and are interrupted in several places by homogeneous hyaline excrescences, which stain bright pink with eosin.

At the periphery of the growth, at each end, there are a few pigmented cells which give a decided iron reaction (Fig. 4), but nowhere else in the growth do any of the cells take the characteristic blue stain.

This growth, therefore, should be classified as melanotic sarcoma of the choroid in the very earliest stage of its development.

Remarks. With the exception of the cases of Purtscher, Fuchs, and Wintersteiner, all the choroidal sarcomas which have been described in literature have been much larger.

The possible connection of this growth with the brain tumor represents an interesting question. If one is to be considered a metastasis from the other, the dural tumor must have been the

Fig. 4. Case II. Periphery of choroidal growth, showing iron reaction in some of the cells.

original growth, on account of its size and long duration and the fact that it is non-pigmented. It is conceivable that a metastasis from this neoplasm might have settled in the choroid only if it is assumed that the cells first entered the general circulation, passed through the pulmonary vessels back to the heart, and then upward through the arterial channels to the eye. It is well known that such emboli are most apt to lodge in the lung. A general autopsy, which would have determined the existence of such metastatic growths unfortunately was not obtained. However, the necessarily roundabout route of such a metastasis to the eye, the absence in the choroid of the typical cell-whorls found in the dural tumor, and the marked participation of the choroidal chromatophores in the growth, strongly indicate that the choroidal tumor should be regarded as an independent one.

The two cases have in common the marked pigmentation of the choroid and of the inner layers of the sclera. The first case was a negro, hence this pigmentation of the uveal tract need not be considered to have been excessive, inasmuch as in the eyes of colored persons pigment spots in the conjunctiva and sclera are often observed, and sections usually reveal a large amount of pigment between the muscle bundles of the ciliary body and in the choroid, although no reference to such a condition is found in the ordinary text-books of opthalmology. The second case, however, was a white man, and the pigmentation is therefore much more noticable.

In the first case there was a typical melanoma, in the second a beginning melano-sarcoma of the choroid. Ginsberg[13] has pointed out the connection between sarcoma of the choroid and melanoma, and refers to the cases of Purtscher, Fuchs, and Wintersteiner. Our cases constitute a confirmation of their observations. Martens, partly quoting Hirschberg, also maintains that marked diffuse pigmentation of the uveal tract represents a fetal malformation, like nevus pigmentosus of the skin, which predisposes the eye to the development of a malignant growth. That in these persons the more pigmented eye is always the seat of the

13 Grundriss der pathologischen Histologie des Auges, 1903, p. 281.

growth was very evident in his cases in which an alveolar sarcoma developed in a child of 13 years, whereas sarcomas appear on an average at the age of 43 years. Naturally, this cause cannot be assumed for all cases, but must be considered as a factor in some of them, just as sarcoma develops from the pigmented nevi of the skin.

Another interesting point in connection with the growths is the fact that in each case the chorio-capillaris is not invaded and takes no part in the formation of the thickening. The starting point of choroidal sarcomas has long been a mooted point. Briere thought that leucosarcomas arose from the chorio-capillaris, while melanosarcomas arose from the deeper layers. Fuchs,[14] on the other hand, thought that both pigmented and unpigmented sarcomas arose from the deeper layers, and this theory was held until Schieck's[15] papers proved that they may arise both from the chorio-capillaris and the layers of larger vessels. In the first instance the tumors are usually unpigmented, and in the parts at least arising from the chorio-capillaris, they assume an angio-sarcomatous type. Our cases, therefore, conform to the rule that the starting point of the melanotic growths is in the layer of large vessels.

A further suggestive point in the anatomical investigation is the *positive iron reaction,* shown by the cells of the growths. As already described, this reaction is present in exactly the same position in the sections in both cases, in the extreme periphery, at points where the cells are developing most rapidly, and, at least in the second case, where they are invading the normal choroid. The question of the origin of the pigment in the melanotic growths of the choroid is one which has been discussed on many occasions, and it is not our purpose at this time to make an exhaustive study of the various theories which have been propounded. But it would seem that in early cases the conditions found must bear considerable weight, especially as to the formation of the pigment

14 Das Sarkom des Uvealtractus, Vienna, 1882.

15 Ueber die Ursprungstäte und Pigmentierung der Choroidealsarcome. v. Graefe's Archiv. f. Ophth., Vol. 45, p. 433, and Ein Weiterer Beitragoz u. den Leucosarcomen den Chorio-capillaris, v. Graefe's Archiv. f. Ophth., Vol. 48, p. 320.

from the blood. This staining of some of the cells of choroidal sarcomas has been thought by some investigators to indicate that their pigment was formed from the hemaglobin of the blood, which at certain stages of the pigment formation gives the iron reaction; Ribbert, Schieck, and others believe, however, that these cells have fully formed pigment and that they absorb the iron when away from their mother-soil (Mutterboden), and especially in the neighborhood of blood vessels or hemorrhages, and that they are really degenerated cells. That this is true in the case of the large densely pigmented cells in or near blood vessels, which often give the iron reaction, may be admitted, just as the pigment cells of the retinal pigment layer absorb iron in the presence of hemorrhages or of foreign bodies in the eye. In our cases, however, the cells which stain correspond morphologically with the ordinary choroidal stroma cells. They have well marked processes and are not swollen; there is, however, no trace of hemorrhage in the tissue, nor do the retinal pigment cells show any staining to indicate the existence of a hemorrhage in the past. On the other hand, the slight staining of the tissue between the cells would seem to indicate the presence of iron in solution at this position, and corroborate the suggestion made by Leber[16] that in these tumors of the choroid a fluid exudate may surround the growths, which contains the iron, and is the source from which the cells obtain their pigment. Leber's position that the retinal pigment cells have a prominent part in the formation of choroidal sarcomas, however, is not confirmed by our cases, as they show no evidence of proliferation or tendency to invade the growth.

METASTATIC CARCINOMA OF CILIARY BODY.

BY C. W. CUTLER, M.D.,
NEW YORK, N. Y.

This case is that of a nurse, Miss A. T., aged 33, seen first in Sept., 1901. The history of that time has to do chiefly with re-

16 Ueber die Aderhaulsarkome und die Herkunft ihres Pigmentes, Graefe's Arch f. Ophth., Vol. 44, p. 692.

fraction and with very curious attacks of migraine or sensory epilepsy, with some indications of a focal disturbance in the right hemisphere. There had been pain in and back of the right eye for several years. The refraction did not vary materially in the two eyes, and the discomfort was not relieved by glasses. These symptoms were not explained by the autopsy, and certainly have nothing to do with the question of the ocular metastasis. At my last examination, previous to the operation, April 12, 1904, the functions of the eyes were normal, and there was no abnormal appearance externally or internally.

The mother and a sister are said to have died of cancer. The patient had a cancer of the breast removed in 1903 by Dr. Runyon of So. Orange. I am indebted to Dr. Ransom of Maplewood, N. J., for the following notes. In a letter dated Sept. 5, 1904, he says:

"Three weeks ago she began to suffer with pain in her left eye, top of head, and side of face. The fundus and media were then absolutely clear. The pain increased, failed to yield to local measures and opiates. She had nausea and vomiting, complained of dizziness and some numbness of right arm and leg, with no loss of reflexes. On Tuesday last a spot appeared on the iris, the conjunctival injection increased, pain became localized in the eyes, and vision was markedly impaired. The spot has increased steadily in size, and pain has increased in spite of all efforts to alleviate it."

I saw the patient the following day, one week after the growth had been discovered. Cornea was clear, pupil half dilated under atropin, with no synechiae.

Occupying about 1/2 the width of the visible iris was a dull grayish mass slightly elevated, not vascular, and not sharply defined. Media clear, fundus normal. The patient was cachectic with a pretty general dissemination of the cancer, which, after remaining a year latent, had spread with terrible malignancy.

The lymph glands over the parotid and back of the ear were involved, and there was a large hard mass adherent to bone or periosteum at the vertex of the skull.



FIG. 1.—Metastatic Carcinoma. Ciliary Body and Iris. × 30.



FIG. 2.—Metastatic Carcinoma. Ciliary Body and Iris showing columnar form assumed by the cells on anterior surface of Iris.

The eye was removed to relieve the atrocious pain, which was due to the tumor, as tension was normal, and there was no iritis; and the result justified the operation. The patient was much more comfortable, but in a week a large mass was felt in the liver, and within a month she died of general carcinomatosis.

The report of the pathologist, Dr. Dixon, is as follows:

"When the globe was divided a tumor was found which macroscopically appeared as a white elevation occupying the ciliary body on the temporal side, and extending into the iris an apparent distance of 3 mm. The base of the tumor in the horizontal plane of the globe measured 9 mm., — extreme elevation 3 mm.

"Microscopically, sections showed a growth composed of epitheloid cells, beginning as a very thin layer just at the end of the choriod and origin of the ciliary body, the outer pigment layer intervening between the growth and the sclera. Passing forward it invested the ciliary body and processes, the root of the iris, and Fontana's spaces, reaching its greatest elevation 2.25 mm. behind the root of the iris. The stroma of the iris in the vicinity of the tumor was thickened considerably in horizontal, or transverse section, by the tumor cells which broke through its uveal layer into the posterior chamber near the root. The cells were more or less numerous in all parts of the iris in sections examined, but they became less in number as the pupil was approached. A peculiar feature in connection with this portion of the growth was that the cells were continued as a thin layer over the anterior surface of the iris, and where thinnest had almost a columnar appearance. They also lined Descemet's membrance for a short distance.

"The sclera was not involved nor much irritated except in the vicinity of some of the vessels, about which were a few round cells.

"The lens showed evidence of beginning cataract. The balance of the eye was normal.

"I regard your case as metastatic carcinoma of the ciliary body and iris."

Dr. F. C. Wood writes from Dr. Prudden's laboratory:

"I return the slides of the metastatic tumor of the ciliary body, and also a slide from the brain of the same case. It seems likely that the tumor is a carcinoma, though the morphology of the brain metastases and those in the eye are not wholly characteristic. Of course, the fact that the patient had a malignant tumor of the breast is the most important evidence which can be brought forward in this regard.

"Dr. Hodenpyl thinks that it is undoubtedly carcinoma, though he says he would not make such a diagnosis unless he knew of the primary growth in the breast. A number of other men here in the laboratory have looked at the specimens, and agree on the diagnosis of carcinoma."

The clinical features which seem to characterize this tumor are its dull gray color and flatness or extension laterally without sharp limitation, in which respects it differs from sarcoma. In appearance it resembled a solitary tubercle or a gumma. There was, however, no iritis and no vascularity. Pain was intense, tension normal.

The literature of metastatic carcinoma of the choroid is extensive. Between thirty and forty cases have been collected by Uhthoff, Oatman, and others. Two cases have been reported before this society by Drs. Noyes and Wadsworth. In two cases of La Grange and Ewing the area of the long ciliary vessels were involved as well as the short or post ciliary, which in the thirty-one or thirty-two cases reported by Oatman and La Grange were the avenue by which the metastasis reached the post. pole of the eye. The extension of the tumor forward in the present instance around the iris, and even on Descemet's membrane, is very characteristic of the flat shell-like growths seen in the post. part of the eye.

Only two other cases of metastatic carcinoma involving the ciliary body and iris alone have been reported, by Uhthoff (*Deutsch. Med. Wochenschrift.*, Sept., 1904) and by Von Briehn (*Inaug. Diss. Königsberg,* 1903).

DISCUSSION OF THE PRECEDING PAPERS.

DR. L. H. TAYLOR, Wilkes-Barre, Pa. — I should like to mention briefly a similar case, which I first saw in December, 1900.

I was called in consultation with the family physician, and found a lady of about sixty-five, with an eye intensely swollen, tension very high, and, I thought at once it was hemorrhagic glaucoma. I knew that there was nothing to be done but enucleation, under the circumstances; but I was going away on the following day, and on my return, December 28th, the eye was very much worse. I knew nothing of the previous history then, but subsequently learned that the patient had called to see me in September, during my absence, and subsequently went to Philadelphia and was seen by Dr. Carpenter, who found at that time a detachment of the retina over three-fourths of the field. On learning this I advised a consultation with Dr. Carpenter, who came from Philadelphia to see the patient, and we immediately proceded to enucleate the eye. It was examined by Dr. Shumway, who found the condition to be one of pigmented sarcoma of the choroid. The case is interesting because of the subsequent history. After ascertaining the true nature of the trouble we naturally feared a return, and Dr. Carpenter suggested that there would probably be such a return within a year. The patient did very well, the wound healed nicely, and there was no further trouble at all in that eye. I fitted the patient with glasses for the right eye, and she spent a comfortable summer at one of the resorts. On her return, however, she began having trouble with the liver. This trouble progressed rapidly, and she died in August, 1901, of sarcoma of the liver.

Dr. T. Y. Sutphen, Newark. — A woman, aged forty years, came to me with partial detachment of the retina of the right eye. The presence of a tumor could not be determined, but was suspected, as I learned that she had had a tumor of the breast on the right side removed about a year previously. Gradually the detachment increased, iritis developed, and the tension became higher. Upon removal of the eye a large tumor was found, which under the microscope proved to be a carcinoma. The disease involved all the tissues of the globe from near the ciliary region back to the optic nerve. A month later there developed a mild exophthalmos, with severe pain, in the other eye, which subsided quickly. The patient died a month later.

Dr. F. Buller, Montreal. — About twelve years ago I presented a specimen of sarcoma of the choroid, originating in the macula lutea, about one-half the size of that reported by Dr. Kipp today. I thought then that I had the smallest sarcoma on record,

but the following day I went to New York and spent the morning with the late Dr. Noyes, and upon showing him my specimen he said, "I am sorry, but you have made a mistake about its being the smallest," whereupon he showed me one about half the size of mine, obtained from Dr. Becker in Heidelberg.

This brings me to the consideration of why it is that our own work here in the society is so often overlooked by members of the society in making their reports. I have noticed it often, and would suggest that the secretary prepare a general index of all the work that has been done by the society, and that it be revised at least once every ten years.

Dr. J. E. Weeks, New York. — Sometimes it happens that we meet with metastatic carcinoma of the choroid before the primary growth is recognized. One case of this kind came to my notice a short time ago: a woman had a tumor of the eye involving the choroid. I removed the eye expecting to find sarcoma, and found that the tumor resembled closely an adenoma; but as true adenoma of the choroid has never been reported I termed it carcinoma. The patient made a good recovery, but about three months later an enlarged gland appeared in the axilla. A little later the patient began to have trouble in the lung, and a carcinoma, primary in the lung, was found. Metastatic carcinoma of the choroid had developed before the general symptoms were sufficiently plain to call attention to the lung.

Dr. C. J. Kipp, Newark (closing). — I did not report the second tumor on account of its small size, as Dr. Buller seems to think, but for other reasons to which I called attention in the paper. The tumor was only 6 mm. in diameter and 2 mm. in height, and yet had invaded the sclera.

Dr. G. E. de Schweinitz, Philadelphia (closing). — I beg to call Dr. Buller's attention to the fact that the paper presented by myself and Dr. Shumway was not intended to discuss sarcomas from the standpoint of smallness of size, but to show how these growths may originate from pigment spots in the choroid, just as they do from similar melanomas in the iris and ciliary body. The reference to the literature of small sarcomas was only incidental, and placed there as a matter of interest. I am sorry that we did not include Dr. Buller's case in the list.

THE SACHS LAMP FOR TRANSILLUMINATION OF THE EYE.

BY EDGAR S. THOMSON, M.D.,
NEW YORK, N. Y.

Transillumination of the eye has been practiced recently by Sachs of Vienna, Rochon-Duvigneaud of Paris, and Pooley of New York. Without knowing anything of the work of these gentlemen, I had been observing the possibilities of the method with a convex lens when, a few months ago, I found that Mr. E. B. Meyrowitz of New York was manufacturing a lamp after a model devised by Sachs. It consists of a twenty-five candle-power electric light, which is covered and bears a cone-shaped projector extending from the side of the light. This projector is of solid glass, silvered around the circumference of the cone, and carried in a rubber shell which does not get hot as the lamp is used.

In using the lamp absolute darkness is necessary if the best results are to be obtained. The point of the cone may be placed against the sclera, previously cocainized, or against the upper or lower lid. Some little manipulation is necessary to get the proper illumination, and the light must enter the eye at the proper angle. The nasal side of the globe is more easily illuminated than the temporal, as the bridge of the nose interferes with the cone of the lamp. If the lids are held back the superior and inferior parts of the globe may be illuminated, though with about the same amount of difficulty as the temporal side. Prominent eyes are much more easily illuminated than receding ones, and lightly pigmented show better than heavily pigmented ones. Myopic eyes, as would be expected, illuminate well. Important details in the ciliary region and anterior part of the choroid, that would otherwise be inaccessible, may be studied, and certain conditions that show poorly with the ophthalmoscope show clearly under transillumination on account of the greater intensity of the light.

The details shown by transillumination may be briefly summarized as follows:

Cornea. — Very little additional information is to be gained here further than can be obtained by focal illumination, except that in some instances where the media are hazy localization of opacities is easier.

Filtration Angle. — Here we have a region of the utmost importance, about which we may obtain much useful information. Transillumination shows distinctly the width of the scleral projection at the limbus and the anterior limit of the ciliary body. In cases of wound extending into the sclera we may thus observe the exact relation of the wound to the ciliary body, — information which is often of vital importance. The scleral projection varies considerably in different individuals, being much deeper in some than in others. Adhesions of the iris to the filtration angle, small amounts of hypopyon or hyphaema, inclusion of the iris in wounds, and of course any neoplasm at the filtration angle, show clearly and may be located much more definitely than by any other method.

Iris. — Atrophic or thin spots in the iris show very well. Very frequently in cases of old iritis the pupillary margin looks like a piece of lacework. In one case observed, in which an atrophic iris was bound up in a membrane after cataract extraction, the iris could only be differentiated from the membrane by transillumination. By oblique light it was impossible to tell where the iris stopped and the membrane began.

Lens. — Details in the lens and anterior part of the vitreous show plainly, and it is easier to localize an opacity in a very hazy eye than by any other method of illumination.

Ciliary Body and Choroid. — The anterior and posterior limits of the ciliary muscle show distinctly as well as the ora serrata. Exudates or tumors, either of the ciliary body or anterior part of the choroid, may be plainly seen. Atrophy of the ciliary body and any beginning ectasia in the ciliary region show well. Foreign particles of metal show very distinctly, and may be seen even when the lens is opaque, under which circumstances they could not be localized in any other way, unless by the X-rays. They must, however, be near the sclera to cast a shadow, and the

vitreous must not be too densely infiltrated. It is by no means necessary that the vitreous be entirely clear. I have no doubt that it would be possible by transillumination to determine the exact position of a lens luxated into the anterior part of the vitreous, though I have had no opportunity to try it in such a case.

Retinal detachments are difficult to observe through the sclera on account of the faint intensity of the shadow cast, but if the lens is clear they may be seen through the dilated pupil in cases where the media are too hazy to allow of a satisfactory ophthalmoscopic examination.

Finally, on account of the variations in pigmentation of the uvea and the anatomical configuration of the orbit, there is a wide difference in the ease with which different cases may be transilluminated. Many can not be transilluminated at all, and others only fairly well; but in a large number, perhaps the majority, it can be satisfactorily done, and it undoubtedly furnishes us with much valuable information which is often unattainable in any other way.

DISCUSSION.

Dr. Walter L. Pyle, Philadelphia. — Professor Leber has devised an instrument similar to this, which has been highly recommended for the diagnosis of intraocular tumors. Mr. Swanzy has recently reported the successful diagnosis of a number of such growths by a modification of the Leber instrument. I believe that an attachment has been constructed to keep the instrument cool by running water.

Dr. H. W. Ring, New Haven.— Theoretically the lamp is a valuable aid, but practically it heats so quickly that you can not use it a minute continuously on the eye or near it. It is a valuable light for transillumination if it could only be used long enough.

Dr. Walter L. Pyle, Philadelphia. — In Loeber's clinic they have an attachment by which cold water is used for obviating this objection of the heat.

DR. THOMSON.—I have used the lamp for twenty minutes at a time, and though the bulb gets hot the rubber cone, which is applied to the eye, does not.

IMPROVED SURGICAL METHODS FOR THE SUCCESSFUL USE OF THE ELECTRO-MAGNET.

BY ROBERT SATTLER, M.D.,
CINCINNATI, O.

The practical application of the Roentgen rays, for the purpose of more accurate or convincing diagnosis, to determine the presence, size, and location of a chip of iron or steel within the eye, the discovery of which by the methods of examination commonly employed is impossible, marks, together with the perfection of more powerful electro-magnets which preceded it, one of the signal advances of ophthalmic surgery.

It has long been recognized that the more powerful the attractive force of the magnet, the greater the chance of successful extraction of a hidden and impacted piece of metal. This has led to the construction of many useful instruments for this purpose, among which the giant stationary magnet of Haab and the larger portable magnet of Hirschberg deserve foremost mention. The prompt employment of a powerful stationary or portable magnet is indicated in every case of this class, for it serves the two-fold purpose of diagnosis and extraction. For diagnostic importance, however, greater distinction must be assigned to the recent achievements of X-ray examinations, for they supplement and reinforce all other methods, the sideroscope and giant magnets included. We have, however, only recently come into the possession of new and reliable facts as the result of carefully conducted X-ray examinations. This conversion of the Roentgen rays for the much desired and useful purpose of a more certain

diagnosis belongs to the credit of Dr. W. M. Sweet, who invented an apparatus and demonstrated a practical method by which this may be accomplished.

It recommends itself for simplicity and dispatch to those skilled and trained in X-ray work and also affords those who must assume the surgical management of these cases trustworthy evidence on an important point which all other methods of examination, the sideroscope and giant magnet included, leave in doubt, *i. e.*, the more or less exact localization of the foreign body within the eye or tissues adjacent to it. Sweet's apparatus furnishes in every case of this class reliable information and it also directs a more conservative and rational surgery. In every case the important question that a foreign body has actually penetrated and lodged within the eye or that it cleared the eye and lodged elsewhere in the orbit, must be determined with precision before the employment of the magnet is resorted to. Formerly, or before we had the new X-ray method of examination, the magnet being the most reliable agent to determine this, was used first to establish a certain diagnosis. In other words it had first to discover the foreign body and bring it from its concealed hiding place to a region forwards where it could be seen and from which locality again, accompanied by new and similar difficulties its final removal had to be accomplished. This was done by successive applications of the magnet to different points of the eye most favorable, in the judgment of the surgeon, to so influence its progress forwards around the lens, through the zonula into the anterior chamber. From this locality there was a better chance that it could be more safely removed either by the aid of the giant or a powerful portable magnet, or other surgical interference. We are governed in attempts of this kind by the valuable suggestions which have been formulated by Haab into a distinct method for the employment of the giant magnet, subject of course to such modification as the special needs in a particular case may call for. These suggestions are of the greatest practical importance to all concerned with the management of these cases, for they are supported by an exceptionally large and varied experience with cases belonging

to this category. Haab also emphasizes a fact which others also surmised and more limited experience upheld, that a chip of iron or steel could be influenced by the giant or other powerful magnet from any point for the reason that its attractive force was uniformly exerted in all directions. For this reason it is not necessary, as was formerly supposed, to apply the tip of the magnet so that its attractive force is spent in the direction of the original wound or along its track, but at any point or points at which by patient successive attempts it may be forced to advance with the least damage to the tissues along a different path to a locality from which it can be successfully removed with less difficulty and danger. It is supported by a mass of evidence that this plan and the surgical method which it suggests is successful in a large number of cases, but for a smaller number it is not, for the undeniable reason that we have no positive data for accurate diagnosis of the localization of the foreign body, even though its presence may be certain. We have, for the same reason, no reliable guide for the employment of the magnet. Only through carefully prepared radiograms after Sweet's method and even more careful interpretation of these by one who has acquired special aptitude for this difficult and responsible task, can a more successful management for this smaller contingent be secured. In these cases the discovery of the foreign body may be possible, but its localization is not. The injury is recent, the sclera is pierced at one point and the foreign body is driven to the opposite side where it becomes impacted or transfixed in the sclerotic or clears the eye and lodges just external to it in the orbit. Again it happens, while conclusive evidence that the foreign body is present may be at hand, its localization is uncertain and impossible, the injury not recent, the foreign body small. It penetrated the sclera at some point between the margin of the cornea and the equator and lodged close to the posterior wall or in the vitreous, retina, or choroid. The lens and anterior structures escape unhurt, but the vitreous chamber is packed with blood and exudates.

Both groups of this smaller division would justify the prompt employment of the most powerful magnet and the sur-

geon must decide upon the method of its most successful application. Shall the attempt be made after the method of Haab, Hirschberg, or others? The one now commonly adopted and successful in a large number of cases, or fortified by the findings of Roentgen rays now made practical and possible with Sweet's apparatus, shall the regions of the sclera nearest or directly over the site of the foreign body at or near which accurately taken radiograms and their interpretation based upon careful measurements and calculations point to the location of the metal, be exposed.

For those belonging to the former group, and if the radiograms furnish, as they do, reliable information, less haste and greater caution of magnet employment would be a necessary inference.

For the second group a more conservative course would also appear expedient in order not to jeopardize the integrity of the structures which have escaped injury or add unnecessary traumatism. In a recent case, an injury of forty-eight hours duration with the point of entrance in the ciliary region of the sclera, near the cornea, but without injury to the lens, the vitreous was packed with blood coagula and exudates. Discovery of the foreign body with ordinary methods of examination impossible. Radiograms taken by Dr. Wm. Jordan Taylor disclosed the certain presence of a medium-sized foreign body in the lower and inner quadrant of the posterior half of the globe. The inference, supported by several radiograms, was that it was in close contact with its tunics and beyond the equator. The question had to be decided promptly whether to proceed with the magnet application in the customary way and make the attempt to bring it forward and remove it as expediency directed. Relying exclusively upon the radiographic findings furnished me and with further knowledge that the metal was not small, the region indicated was exposed for direct examination and exploration. Through a large incision parallel to the depth of the lower fornix, the tendon of the inferior rectus was divided and the orbital end secured by catgut ligatures. The equatorial region of the sclerotic was now fully exposed to view by seizing the tendon of the inferior rectus

and rotating of the eye upwards and outwards. An ample incision, parallel to but behind the equator was then made and the magnet applied close but not into the incision. The foreign body was at once extracted. The tendon was then reunited and the conjunctiva carefully sutured. No violent reaction followed and ten months afterward the vision was 0.4.

In another case injury was of sixty hours standing. Discovery of the foreign body was impossible. Point of entrance of foreign body was near lower and inner ciliary region. Lens clear but there was dense hemorrhagic effusion into vitreous humor. Radiograms taken with great care forced the conclusion upon us that the foreign body was small and was impacted in the upper and outer posterior quadrant, but either in immediate contact with one or all the tunics at this point or had cleared the eye and was in close contact with the outer wall. After careful study of the radiograms was thoroughly exposed for inspection and exploration by dividing the superior rectus, the eye rotated downwards and inwards. We could not discover the wound of exit or other evidence of penetration. An ample incision of the sclera was made, parallel with the equator. Application of the magnet at once confirmed the disclosures of the X-ray examination by indicating its presence. Repeated attempts failed, however, to secure the foreign body, which was very small. Fearing violent reaction the globe was enucleated. Subsequent dissection revealed that the metal was enveloped in a large fold of choroid which was extensively detached by hemorrhagic extravasation beyond the scleral incision and this was encased in a dense mass of exudate and hemorrhage.

My own inference from personal observation with this class of concealed or undiscoverable foreign bodies leads me to suggest the expediency of resorting to X-ray examination with Sweet's apparatus in every case before magnet operations are practiced for it is of invaluable importance as it directs a safer and more rational surgery.

DISCUSSION.

DR. E. E. HOLT, Portland, Me. — I think I was one of the first if not the first to report a series of cases of steel removed from the vitreous to this Society. When I decide I must make an opening into the eye I always enter it in the inferior temporal quadrant and rotate the eye upward. I have almost invariably succeeded in getting the foreign body out. In the first series of twelve cases I reported to this Society I was unable to locate the foreign body before the operation in nine. In the three where I could locate the foreign body I had more difficulty in getting it than in those where I could not locate it. I remember one case where I failed to get the foreign body out, and that was a case in which it had gone through the eyeball and on removal of the eye was found in the internal rectus muscle.

I agree with the writer of the paper that it is safer to open the eye in the inferior temporal quadrant and introduce a small magnet than to undertake to pull the object out by the use of the large magnet with considerable tearing of the tissues.

DR. W. B. MARPLE, New York. — This question of whether the foreign body should be removed through an incision nearest where it seems to lie, or be drawn through the anterior chamber with the large magnet was discussed several years ago at Saratoga, and ever since the presentation by Dr. Risley of his opinion that where the foreign body was localized it should be removed by incision nearest the location of the body I have personally been in favor of that method. It seems to me very desirable that all the cases in which the foreign body has been removed through an opening in the sclera should be reported. Haab, who is more favorable to removing them through the anterior chamber by the large magnet, claims that the scleral opening tends to produce detachment of the retina; Hirschberg claims that that is not true. If detachment is not more frequent where the sclera is opened and the foreign body taken out nearest the point where it is lying, certainly that would seem to be the most desirable method.

I also want to say that we had Dr. Sweet over in New York in February and he stirred us up on the subject of localization. Since then Dr. Dixon has been working upon the problem, and up to the time when he began his investigations, no work worthy of the name of "accurate localization" in eye cases had been done at the Infirmary. Dr. Dixon has devised a modification of Dr. Sweet's method of centering the cornea, published in Knapp's

Archives, May, '05, and for several months past he has localized the foreign body with the greatest accuracy in all cases of this nature admitted to the New York Eye and Ear Infirmary, now some thirty or more cases. On Tuesday afternoon of this week I removed a foreign body that Dr. Dixon had localized. The skiagraph was taken and the foreign body removed in one hour and a half. Dr. Sweet tells me, however, he has done it in one hour. It was in this case a large body and Dr. Dixon localized it as directly back in contact with the retina. The scleral wound was slightly enlarged with the scissors and the small magnet used. It does not seem to me right to put a patient down before the Haab magnet without an idea of the location of the foreign body.

Dr. H. F. Hansell, Philadelphia. — Several months ago I had under observation a case in which I had Dr. Sweet localize the foreign body. There was an opening at the sclero-corneal margin. Dr. Sweet not only localized one, but two foreign bodies, which must have passed in through the same point. One was in the ball and the other had passed out at the inner equator. The eye became infected and after enucleation I found the bodies as located. The picture of the two foreign bodies is that the one outside the ball was a piece from the hammer, and the other a piece of the steel that was struck.

Dr. William M. Sweet, of Philadelphia. — I have employed the method of localization in over 300 cases of ocular injury, many of the patients coming to me from Wills Hospital for diagnosis as to the position of the metal in the eyeball. With few exceptions extraction of the metal was made through an incision in the sclera, using the large hand magnet operated on the 110-volt circuit. In a recent case in which the steel passed through the cornea and lens and fell to the bottom of the vitreous, I drew the metal without difficulty into the anterior chamber with the large hand magnet. I believe, however, that extraction through a scleral incision is the safer procedure in all cases, but especially if the lens is clear and the body is likely to be imbedded or covered with exudate, so that under the strongest magnetic pull it comes forward with great rapidity and force. I have not seen detachment of the retina that could be traced to incision of the sclera. In two cases that I have had under observation for over a year, in both of which extraction was through an opening in the sclera, there has been no evidence of detachment, and vision in both cases is normal.

DR. S. D. RISLEY, Philadelphia. — I feel, after Dr. Marple's remarks in reference to the relative probability of detachment of the retina in the different procedures described, that I should say that in the cases reported by me to the Society and a large number since there has in no single instance been a detachment of the retina and that I still hold, as in the paper to which he has alluded, that if the foreign body has been present long enough to have attached itself to the membranes of the eye, the retina or choroid, and to have become encysted by the products of inflammation, that the probabilities of detachment of the retina with the use of the powerful magnet are greater than if the foreign body is localized, section made through the sclera and the body withdrawn through the scleral incision. In two cases at least which I have been able to follow, where the body was so located that I could see the scar at the site of my wound, the choroid and retina seem to have been attached to the sclera so that there was a little white, atrophic linear wound at that point.

DR. PERCY FRIDENBERG, New York. — The magnet is also open to objection as a means of diagnosis because the findings are not absolute. In cases like that reported by Dr. Hansell of double perforation you may not be able to locate the foreign body with the magnet. We are pretty well agreed now, I think, that instead of putting the patient down before the giant magnet we should first localize the foreign body with the X-ray. In a case of suspected foreign body, a negative finding with the X-ray is definite and reliable, whereas a similar result of the magnet examination leaves us in doubt. The possibility of further injury to an eye containing a foreign body when exposed to the traction force of a large magnet should certainly be borne in mind.

DR. O. F. WADSWORTH, Boston. — In regard to the question of detachment of the retina, I reported two or three cases to this Society some years ago. One was a case in which the small bit of steel had entered the vitreous. It was easily located and removed through the sclera with the small magnet. The patient had 20/20 vision for as long as two months. The only thing that was to be seen out of the way were a few small pigment dots on and in the neighborhood of the disk, and these were first seen after about two weeks, I think, and they moved from time to time. There were a few fine threads in the vitreous. The posterior end of the wound in the sclera could be seen. A detachment of the retina developed at the end of about two months at a point dia-

metrically opposite the wound in the sclera. The foreign body had entered through the cornea.

DR. S. L. ZEIGLER, Philadelphia. — I think this question is determined by two factors. If the foreign body is large there is less danger to the eye; that should determine to some extent our procedure. The drawing forward of the body into the anterior portion of the eye means just that much more danger to the eye. As to detachment of the retina, we do the same operation for detachment, posterior sclerotomy. Of course, if the magnet should draw the body away and cause a detachment, that would not be the fault of the incision, but the fault of the magnet. That might happen just the same with the other method. I have never seen detachment follow scleral incision, and I have never done but one operation in the other way. That was a wound partially in the ciliary body and partially in the sclera and had not been X-rayed. The giant magnet was used. The foreign body was a thin, sharp piece with irregular edges and entangled the iris so that I had to do an iridectomy. In one case where the foreign body had been in the eye for a year and a half, Dr. Sweet X-rayed it, I made an incision over the body, the magnet took hold and drew the sac out with it, and there was no reaction.

DR. E. S. THOMSON, New York. — I usually practice the "limbus" incision for the removal of foreign bodies, but in one case in which I localized the foreign body and removed it through the sclera I was able to follow it for eighteen months and there had been no detachment up to that time. The lens remained clear so that I could observe the fundus distinctly.

DR. GEO. F. FISKE, Chicago. — I had one case in which there was very little hemorrhage and the foreign body could be located with the ophthalmoscope. Incision was made at the posterior pole and the piece of steel easily removed. For four or five months the patient had almost perfect vision and then detachment occurred and became complete.

DR. G. E. DE SCHWEINITZ, Philadelphia. — Recently I reviewed my cases of metallic foreign body in the eye, and compared the results of those in which the Haab method of extraction was employed, that is, in which the foreign body was drawn into the anterior chamber by means of a large magnet and extracted from this position, with those in which the extraction was made

through a small scleral incision placed according to the position of the foreign body as localized by Sweet's method. The results in so far as the saving of eyes is concerned were exactly the same with each method, if two cases of eyes hopelessly infected before the operation are excluded. I am convinced, however, that under most circumstances the best results are obtained in the long run by making an incision over the approximate position of the body after localization by means of the X-rays, and removing it through this scleral incision with a magnet. The magnet point, however, must not be introduced into the vitreous. I have never seen a detachment of the retina after such a scleral incision, provided the extension point of the magnet was not introduced within the vitreous body. Necessarily each case must be studied by itself, and I am convinced under any circumstances of the value of accurate localization, whether the giant magnet be used according to the Haab method, or whether an incision be made over the approximate position of the piece of metal, and such accurate localization certainly adds to the facility of the technique.

Dr. P. A. Callan, New York. — I have had considerable experience with these cases and am sorry to say that my results with the scleral incision have not been satisfactory. They have been much more satisfactory with the use of Haab's method and I am therefore a strong advocate of that method. One thing that we should not forget is that it is a much more serious affair to get a foreign body in the vitreous than in the anterior chamber. With a foreign body weighing more than a half grain penetrating the vitreous, whether we remove it or not, the chances are against saving the eye as a useful organ. Of course before the days of localization, when we used to penetrate an opening in the sclera and churn up the vitreous, the rule was to get detachment of the retina. Sometimes as many as a dozen insertions would be made at haphazard before we would get the foreign body. I think the diameters of a foreign body does not give us so much information as its weight. I should always advocate bringing it into the anterior chamber if possible to avoid infection of the vitreous.

Dr. J. E. Weeks, New York. — In regard to the removal of the foreign body after it is brought into the anterior or posterior chamber, I have just had a case in which the foreign body was located in the vitreous. I succeeded in drawing it into the posterior chamber, where it impinged upon the iris and I could not draw it into the anterior chamber. I made an incision through

the cornea and as soon as that was done the edge of the foreign body presented. I then took the patient to the Haab magnet, but the foreign body did not come away readily. However, in about five seconds or more, to my great astonishment, the foreign body came away with almost the entire iris. I shall always hereafter make an iridectomy if the foreign body is in the posterior chamber, or if I have reason to believe that it is entangled in the iris.

DR. LUCIEN HOWE, Buffalo. — Little has been said in regard to the time which has elapsed after the accident, but I have had that consideration impressed upon me. On one occasion where the foreign body had been lodged for some length of time I found it utterly impossible to remove it. When the eye had been enucleated I took the trouble to open the globe to apply the magnet to the section and the choroid and iron came away together. Another point is the advantage of getting near to the foreign body. Before we had the large magnet and used a small one the point of that was often introduced into the eye. When we remember what a difference it makes as to just how far the magnet is from the foreign body, we appreciate that a weak magnet introduced in that way into the globe exerts as great force as a larger one employed at a considerable distance from it.

MAGNETIC PROPERTIES OF STEEL ALLOYED WITH OTHER METALS.

BY WILLIAM M. SWEET, M.D.

PHILADELPHIA, PA.

Considerable attention has been given in recent years to the changes in the physical properties of steel which follow the addition of other metals, and the results of investigations conclusively prove the value of these metals in increasing the tensile strength, wearing qualities, and ductility of the alloyed steel. These so-called steel-hardening metals include nickel, chromium, manganese, and the rarer metals, tungsten, molybdenum, and others of the same group.

Apart from the commercial value of a determination of the

physical properties which these metals impart to steel, the subject of the magnetic properties of alloyed steels is of considerable importance to the ophthalmic surgeon in view of the possibility of ocular injury from splinters as these newer steels become more extensively used in the construction of tools and machinery and compose the raw material which must be manipulated into finished products by the workmen. It is possible that, since these steels possess tensile strength and ductility greater than is found in the ordinary grades of steel, the liability of these metals to break and chip will be less, and there will consequently be fewer instances of injury to the eyes from flying particles.

My attention was first directed to the importance of a knowledge of the magnetic properties of the different steel alloys by the following case referred to me for radiographic examination by Dr. W. W. McClure.

J. B., a machinist, came to the Wills Hospital on September 16, 1904, with injury of the right eye caused by a splinter of steel from a casting which he was chipping. There was a wound of the cornea near the lower inner corneo-scleral junction, but the lens was uninjured. The X-rays showed a foreign body, 2.5 mm. by 1 mm., situated close to the ciliary body in the lower nasal portion of the globe. Attempts by Dr. McClure to extract the metal by the magnet failed, but he subsequently secured the body with forceps. Vision equaled 5/22. The piece of steel after removal was tested by the magnet, and found to adhere so faintly that it could readily be brushed off with cotton. Inquiry of the man elicited that the metal was manganese steel.

For the purpose of determining to what extent the addition of the steel-hardening metals affect the magnetic properties of the alloyed steels, as shown by tests with the medium-sized magnet operated with the street lighting circuit, I secured samples of the various steels from a number of the leading steel manufacturers. These samples were found to vary within wide limits in the percentage of the alloy contained in each, in the carbon and other constituents, and in the treatment the metal received in the process of manufacture, whether forged, cast, annealed, or hardened,

while several of the samples contained more than one of the steel hardening metals. Although these are factors of importance in an accurate measurement of the magnetic properties of the several samples, they only indirectly bear upon the general question of the possibility of removal from the eyeball of steel alloyed with a given metal irrespective of its exact chemical constituents. The measurement of the magnetic permeability, residual magnetism, and coercive force of the different grades of iron and steel have been accurately determined by investigators of known experience after years of labor, and as the tests I have made of the induction of the samples examined give results that are approximately the same, I have compiled the following table from the investigations of Hopkinson.[1] These figures give the principal constituents of each piece of metal tested, and the extent each is attracted by the magnet (magnetic induction), and exhibit with greater accuracy the effect of the magnet than if expressed in pounds, since the pull as measured by a balance would vary with the shape of the particle, whereas the magnetic induction as shown in the table is based upon the lines of magnetic force per square centimetre of the material.

Specimen.	Total Carbon.	Manganese.	Other Ingredients.	Maximum Induction Lines of Force.
Cast Iron (gray),	3.45	0.17	.....	9,148
Cast Iron (mottled),	2.58	0.61	.....	10,546
Cast Iron (white),	2.03	0.38	.....	9,342
Cast Iron (malleable),	....	....	.....	12,408
Wrought Iron,	....	....	.....	18,251
Bessemer Steel,	0.04	0.20	.....	18,196
Open-hearth Steel,	0.32	0.43	.....	18,736
Hadfield Manganese Steel,	1.00	12.36	.....	310
Manganese Steel (forged),	1.29	8.74	.....	747
Manganese Steel (annealed),	1.29	8.74	.....	1,985
Chrome Steel (forged),	0.68	0.02	1.19 Chr.	14,680
Chrome Steel (annealed),	0.68	0.02	1.19 Chr.	13,233
Tungsten Steel (forged),	1.35	0.03	4.64 Tun.	15,718
Tungsten Steel (annealed),	1.35	0.03	4.64 Tun.	16 498

The relatively high magnetic induction of chrome and tung-

1 Phila. Trans. Roy. Soc., Vol. XXXV.

sten steel, and the almost total absence of magnetic properties of manganese steel is well shown by the above figures. Nickel steel is not included in the table, but is considered separately.

Nickel Steel. — Nickel is more extensively used than any of the other steel-hardening metals, owing to its greater cheapness and to the properties which it imparts to the finished steel product. Both nickel and iron are metals of strong magnetic properties, and the samples of low nickel steel which I have tested show characteristics not unlike ordinary forms of steel. In the higher percentages of nickel, however, there was found a decided decrease in the induction in the pieces examined. Thus, in three pieces of nickel steel and one of ordinary steel, each of 4 mm. cross section, tested on the end of the magnet with the tip removed, the following power measured by spring balance was found necessary to overcome the magnetic pull and detach the pieces from the magnet: Bessemer steel, 8 pounds; nickel steel, 3.5 per cent., 7¾ pounds; nickel steel, 11.5 per cent., 6 pounds; nickel steel, 32 per cent., 2 pounds.

Authorities differ as to the behavior of nickel steel in its magnetic properties under influence of temperature. Hopkinson[2] found that a specimen of nickel steel containing 25 per cent. of nickel to be non-magnetic at the ordinary atmospheric temperature, but on being brought slightly below the freezing point it became magnetic, and retained this property until it is brought up to 580 C., when it again becomes non-magnetic, remaining so after cooling to the ordinary temperature of the air.[3] Hadfield,[4] however, believes that in the absence of carbon and other elements such as manganese, alloys of iron and nickel will remain constantly magnetic whatever may be the treatment within the ordinary ranges of temperature. He experimented with three specimens of nickel steel containing approximately 15, 24, and 29 per cent. of nickel and 0.17 of carbon, respectively, and although the samples were heated and then quenched in a freezing mixture to 11 degrees F., no change could be detected in the magnetic sus-

2 Proc. Royal Society, 1889.
3 Ewing, Magnetic Induction in Iron and other Metals.
4 Proc. British Inst. Civil Eng., March, 1899.

ceptibility. I experimented by heating and cooling two samples of nickel steel, one with 11 and the other 30 per cent. of nickel, and found no change in the magnetic induction of the pieces as compared with the same metal untreated.

Nickel steel is extensively used in the metal industries. Practically all the armor plate and exposed parts of modern war vessels are now made of nickel steel, the metal possessing hardness to resist perforation but also having ductility and elasticity to resist cracking of the plate should perforation occur. The toughness and resistance to wear of nickel steel had led to its employment for axles, railroad forgings, and for railroad rails, the alloyed rail having a life equal to about four of the ordinary steel rails.[5] The percentage of nickel in the steel used for these purposes is approximately 3.5. A small percentage of chromium is often incorporated with the nickel steel. In the manufacture of tubes for marine and locomotive boilers and for other purposes requiring a metal of great strength with high elasticity, a nickel steel containing from 25 to 32 per cent. of nickel is now employed to some extent.

Manganese Steel. — Manganese is added to steel to produce a metal of great hardness and ductility, the percentage of manganese being approximately 12, with carbon about 1 per cent. This grade of metal is known as Hadfield manganese steel, and is used in rock crushers, mine car wheels, and in the frogs and crossings of street railways. Practically all the manganese steel of commerce contains over 10 per cent. of manganese, as steel with from 2 to 7 per cent. is brittle, and can be pulverized under a hammer like glass. Even the 12 per cent. steel requires special treatment to give it toughness and elasticity.

Manganese deprives the steel into which it is introduced in any considerable extent of its magnetic properties almost completely, and this non-magnetic condition is the same whether the metal is cast or forged. Even with the strongest magnet the particles of maganese steel hardly more than adhere to the tip of the magnet. Considering that the strongly magnetic metal, iron, is

5 Production of Steel Hardening Metals, J. H. Pratt, U. S. Geol. Survey, 1903.

present in quantity over 8 times the amount of the manganese, it is curious that the metal should show almost complete absence of magnetic properties. In ocular injuries from this metal, the magnet is therefore useless, and treatment must be the same as for the other non-magnetic metals. In a large plant in this city which works up manganese steel into finished forms, it is found that particles of the metal entering the flesh are always followed by severe inflammatory reaction unless promptly removed. With the exception of the case reported in this paper, where the piece of manganese steel remained in the eyeball for a period of two weeks without causing any excessive inflammation, no opportunity has arisen to test the action of manganese steel on the ocular structures.

Chromium Steel. — Chromium is used as an alloy of steel either alone or in combination with nickel or tungsten. Chromium steel is employed in the manufacture of burglar proof safes and to some extent in the manufacture of tools. The metal is extremely hard, and has therefore proven of value in the manufacture of armor-piercing projectiles. Like nickel, chromium is magnetic, and the magnetic properties of the alloyed steel is not markedly changed in induction by the addition of the chromium, which is used in the proportion of 3 to 5 per cent. in the commercial chromium steel. In ferro-chromium, which is the form in which the metal is supplied to the steel manufacturers for the making of chrome steel, the chromium is present in from 65 to 70 per cent., this metal still showing strong magnetic properties.

Tungsten Steel. — Tungsten is used in the proportion of from 3 to 10 per cent. in the manufacture of tungsten steel, the resultant steel being especially valuable for the manufacture of high-speed tools and in the making of magnets. The supply of tungsten is not equal to the demand, and the metal is therefore employed as yet only to moderate extent. Tools made of tungsten steel hold their edge even at red heat, a factor of considerable importance in some industrial operations. Tungsten is a metal of strong magnetic properties, its residual magnetism exceeding that of any of the other metals. The magnetic movement of

both iron and nickel is increased by the addition of tungsten, and there is made both a tungsten-nickel and tungsten-chromium alloy of steel. The ferro-tungsten, the form of metal used by the steel makers in the production of tungsten steel, contains from 30 to 80 per cent. of tungsten, the magnetic induction of the metal remaining high.

Conclusions. — It is therefore seen that, with the exception of manganese steel, the magnetic induction of steel is only slightly affected by the addition of the steel hardening metals. In the higher percentages of nickel steel some difficulty would be experienced in the removal of a splinter of this metal from the eye, particularly if the body were covered with exudation. The consumption of the alloyed steels is certain to increase as new uses are found for the metals in the mechanical industries.

ON THE VARIOUS METHODS EMPLOYED FOR LOCALIZING FOREIGN BODIES IN THE EYE BY MEANS OF THE ROENTGEN RAYS.

BY JOHN E. WEEKS, M.D.,

NEW YORK, N. Y.

The great value of the X-rays as a means of localizing foreign bodies in the eye is now, I think, conceded by all ophthalmologists.

We have in the ophthalmoscope, the sideroscope, and in the magnet means which, under certain conditions, enable the operator to locate foreign bodies in the eye and orbit, but their uses are limited.

The ophthalmoscope may be employed to determine the presence of foreign bodies in the interior of the eye that are visible. These do not comprise more than 10 per cent. of the cases. The ophthalmoscope is the most valuable means when the foreign body can be seen, as the location is accurate and positive and applies to foreign bodies of whatever character.

The sideroscope, if properly constructed and properly mounted, is of value in indicating the presence of a magnetic body in the eye or its vicinity. However, when it is used care must be taken to exclude any other magnetic body from the "field" of the needle of the sideroscope, otherwise the results are unreliable. The impossibility of determining the location of the magnetic body within one to three centimeters and the fact that the method is applicable to magnetic bodies only, detract greatly from the value of the sideroscope as a means of locating foreign bodies in the eye.

The only magnets that are of much diagnostic importance are the powerful magnets — those that are usually termed "giant magnets." The diagnosis of a magnetic body in the eyeball or in the tissues in the anterior portion of the orbit or in the lids can be made with the giant magnet ordinarily, provided the magnetic body is of suitable size, but if the magnetic body is very minute or is lodged in the posterior segment of the globe, or if it is bound down by adhesions or is deeply situated in the tissues of the orbit, the magnet often fails as a means of diagnosis. It is, of course, of no value in determining the presence of non-magnetic foreign bodies.

In addition to the limited application of the giant magnet, there is more or less danger attending the diagnosis of magnetic foreign bodies in the eye by the use of this instrument because of injury that may be inflicted by the application of too much force in a direction not the most favorable for the removal of the foreign body. Traumatism to retina, ciliary body, lens, and iris may result which might be avoided if the operator was aware of the exact location of the foreign body.

The X-rays are harmless as at present used for locating foreign bodies in the eye and orbit, so far as the patient is concerned, and they are applicable to all foreign bodies that are opaque to the rays. The principal substances (see table) are all the metals (with one exception), the degree of opacity varying with the density of the metal and glass. The X-rays are of no value in locating splinters of wood.

TRANSPARENCY OF VARIOUS SUBSTANCES FOR ROENTGEN RAYS.

Material.	Sp. Gr.	Transparency.	Material.	Sp. Gr.	Transparency.
Pinewood,	0.56	2.21	Tin,	7.28	0.118
Walnut,	0.66	1.50	Zinc,	7.20	0.116
Paraffin,	0.874	1.12	Iron,	7.87	0.101
Rubber,	0.93	1.10	Nickel,	8.67	0.095
Wax,	0.97	1.10	Brass,	8.70	0.093
Stearine,	0.97	0.94	Cadmium,	8.69	0.90
Cardboard,	....	0.80	Copper,	8.96	0.084
Ebonite,	1.14	0.80	Bismuth,	9.82	0.075
Woolcloth,	....	0.76	Silver,	10.5	0.070
Celluloid,	....	0.76	Lead,	11.38	0.055
Whalebone,	....	0.74	Palladium,	11.3	0.053
Silk,	....	0.74	Mercury,	13.56	0.044
Cotton,	....	0.70	Gold,	19.36	0.030
Charcoal,	....	0.63	Platinum,	22.07	0.020
Starch,	....	0.60	Ether,	0.713	1.37
Sugar,	1.61	0.60	Petroleum,	0.836	1.28
Bones,	1.9	0.56	Alcohol,	0.793	1.22
Magnesium,	1.74	0.50	Amylalcohol,	.....	1.20
Coke,	....	0.48	Olive Oil,	0.915	1.12
Glue,	....	0.48	Benzol,	0.868	1.00
Sulphur,	1.98	0.47	Water,	1.00	1.00
Lead Ointment,	....	0.40	Hydrochloric Acid,	1.260	0.86
Aluminum,	2.67	0.38	Glycerine,	1.240	0.76
Talcum,	2.6	0.35	Bisulphide of Carbon,	1.293	0.74
Glass,	2.6	0.34	Nitric Acid,	1.420	0.70
Chalk,	2.7	0.34	Chloroform,	1.525	0.60
Antimony,	6.7	0.126	Sulphuric Acid,	1.841	0.50

The above table for the relative transparency of equal thickness of various substances (water = 1) is due to Batelli and Garbasso.

Skiagraphy. — In the procedure for the localizing of foreign bodies in the eye, we must first have a good skiagram. The requirements for this are as follows:

1. The means for developing a suitable supply of X-rays. This implies the possession of either a static electrical machine of sufficient power, or a properly installed induction coil.

2. A suitable source of the X-rays. This is obtained by the use of a suitable Crookes tube, of which one of the best is a heavy anode Gundelach tube.

Roentgen rays pass from the anode of the tube in straight lines and cannot be deflected or refracted. Other rays, known as dispersion rays, are developed which have a tangential direction.

Fig. 1

Head rest of Mackenzie Davidson

Fig. 2

Head rest of Dr Geo. S. Dixon.
N.Y. Eye and Ear Infirmary.

They are relatively few in number and may be disregarded. Suitable screens have been devised for the purpose of intercepting these rays and preventing them from interfering with skiagraphy and with fluoroscopy, but ordinarily these screens are not necessary. The line perpendicular to the photographic plate that cuts the center of the anticathode is known as the *anodal axis.*

3. A head-rest that will ensure immobility of the head as far as possible during the period from the beginning of the first to the end of the second exposure. Of the head-rests employed those which are used with the patient in the recumbent position are probably the best. The head-rests of Mackenzie Davidson (Fig. 1) and of Hulen, with the patient in the sitting position, permit of greater possibilities of error in adjustment and of subsequent movement than do those of Mackenzie Davidson, of Sweet, and of Dixon (Fig. 2), which require the recumbent position. The head-rest of Dixon, which is simple and efficient, is certainly one of the best.

4. A plate-holder which will permit the plate to be inserted and removed readily, will hold it firmly in proper relation to the head, and possess the proper registration device, is necessary. The apparatus should include the plate-holder in the head-rest. The crossed wires introduced by Mackenzie Davidson supply an excellent registration device.

5. A suitable tube-holder. This condition will be met by a tube-holder that is sufficiently firm, will permit of a satisfactory adjustment of the distance of the tube from the photographic plate and of movements in all directions, particularly vertically and horizontally, with mathematical precision. (Two exposures at equal distances from the primary anodal axis are required, either in a vertical or horizontal direction.)

6. The proper relation of the patient's head and eyeball to the plate.

It is desirable that the part to be skiagraphed should be in the anodal axis as nearly as possible, as the clearness of the shadow is much greater and the time required for the exposure is less.

Head. — The sagittal plane of the head should be exactly

parallel to the plane of the photographic plate, and the horizontal plane of the head, when the head is in the primary position, should coincide with the horizontal cross wire in the plate-holder; (if the patient is in the recumbent position, with the vertical cross wire in the plate-holder). The desirable position can be most readily obtained by means of a straight edge or plumb line held parallel to the surface of the plate over the sagittal and horizontal planes of the head, and moving the head to conform to the desired position. When the head is in position, it should be suitably clamped.

The planes of the eye must correspond with the planes of the head. This may be obtained by requiring the patient to "fix" with the sound eye a small object placed at a distance of about one metre from the eye at a point where the vertical plane of the eye containing the foreign body would cut the horizontal plane of the same eye if both planes were extended. No movement of eye or head can be permitted during the time of making the exposures. Unless the relations of plate, head, and eye are exactly as described, error must result.

Localization. — Having obtained the skiagrams from the two exposures, whether on one or on two plates, the problem of determining the location of the foreign body in the tissues must be solved. "All proper methods of localization," as was recognized and employed by Mackenzie Davidson, "depend upon the determination of the three coördinates x, y, and z (Fig. 3), which fix the position of a given point in space." This is done by triangulation.

The location of the foreign body may be compared with the known location of a small object which has been termed a "marker." A "marker" is not necessary in determining the location of a foreign body in tissue, provided the relation of the plate to the tissues at the time of the exposure is known. This may be established by inking the cross wires and leaving their impression on the skin. While this method is sufficiently accurate for tissues of other parts of the body, it is not sufficiently so for the eye and surrounding parts.

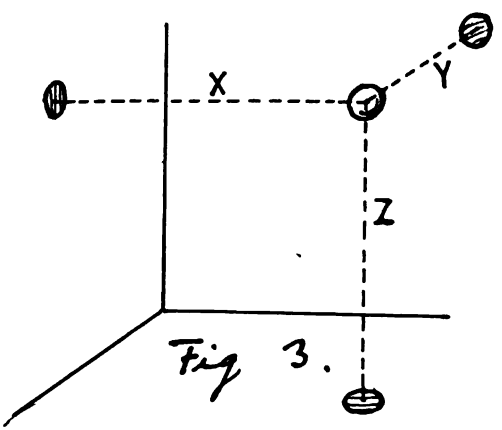

Fig 3.

Fig. 4.

Skiagraph showing foreign body
Dixon's "marker" in position.

Sweet employs two "markers" in the shape of small metal balls, one of which is placed immediately in front of the center of the cornea. The second is placed 15 millimetres from the first and on the same horizontal plane. The distance of the first ball from the center of the cornea is measured and recorded. Mackenzie Davidson employs one "marker" in the shape of a piece of fuse wire fixed to the lower lid by means of adhesive plaster. The distance of the upper end of this piece of wire below the center of the cornea, anterior to the center of the outer surface of the cornea, and to the nasal or temporal side of the vertical plane of the eye, is measured and all measurements are recorded. Hulen uses the same kind of a "marker." Dixon uses a small metal ball (Fig. 4), so fixed to a headband that the ball can be adjusted before the center of the cornea. The distance of the ball from the center of the cornea in the axis of the globe is recorded. All measurements are taken when the eye is in the proper position, as previously described. In order to give satisfactory results, the "marker" should not change its position during the time of making the exposures. The "marker" of Mackenzie Davidson is not so good as the others, as movements of the lower lid may cause it to move and produce considerable error.

Other measurements that should be known are the distance of the source of the X-rays, the target of the tube, from the plate, and the distance through which the tube is moved in changing from the first to the second position. These measurements have not been employed by Sweet until recently, as they are not actually necessary when two "markers" are used. In order to obtain the coördinates which serve to localize the foreign body, triangulation based on the measurements obtained and on those recorded on the photographic plate is resorted to. Sweet constructs his figure from the known position of the two metal balls in relation to each other, the plate, and the eyeball, and the measurements secured from the shadows of balls and foreign body found on the plates. Since the construction of the figure necessitates the joining of points that are very close to each other (distance between centers of balls, 15 mm.), the lines must be drawn with

great accuracy to avoid error. Sweet's use of the distance from anode to plate, which he now employs, serves to lessen the possibility of error in his method. If the distance between the position of the tube when the first exposure is made and when the second exposure is made is known, the necessity of the second (temporal) "marker" is obviated. Sweet's method of triangulation arrives at the same results as those obtained by other methods. It is not so simple, nor are the results more accurate.

Mackenzie Davidson seeks to obtain by means of an apparatus with cross threads the same conditions that were present when the skiagrams were taken, the cross threads representing the course of the Roentgen rays that impinged on "markers" and foreign body. This apparatus is known as the Mackenzie Davidson cross-thread localizer. It permits of arriving at results that are approximately accurate, but the apparatus is unnecessarily cumbersome, complicated, and expensive.

Dr. Vard B. Hulen of San Francisco has simplified the headrest and has done away with the triangulation apparatus entirely, employing the same principle exactly, but determining the location of the foreign body from the skiagrams by portraying the intersection of the rays at the sites of "marker" and foreign body graphically. The expense of the apparatus is greatly reduced and the accuracy of the method perhaps slightly improved upon.

The figure as constructed by Hulen is easy to understand and is accurate. I quote from his article: "On a piece of drawing paper make two vertical lines (Fig. 5), the distance between them being that recorded for the distance between the anode and cross wires. Cross each of these lines near the bottom by a horizontal line, and mark the point of crossing of left line '1.' Then mark a point '2' on this left vertical line, the same distance above as the tube was displaced vertically when taking the second picture. Then in photograph 1 measure the vertical distance from the shadow of the *horizontal* wire to the upper extremity of the shadow of the 'marker,' and on the right vertical line in the diagram, beginning at the point crossed by the hori-

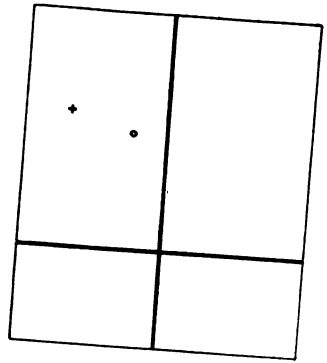

PIATE 1

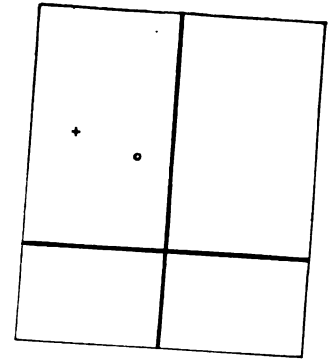

PIATE 2

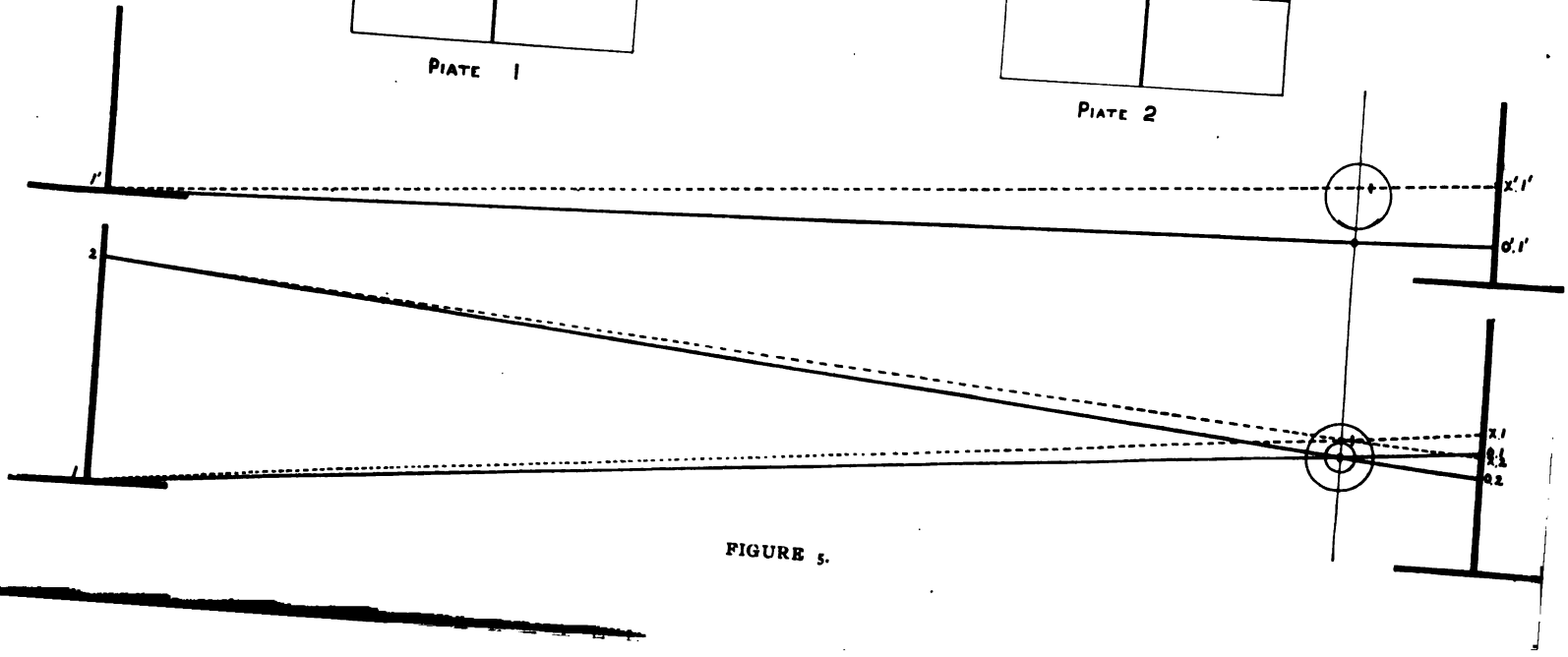

FIGURE 5.

zontal line, measure vertically this distance, designating that point '0.1.' In the same way measure and mark the vertical distance from shadow of horizontal wire to shadow of foreign body 'x,1.' Now take photograph 2, measure and mark shadows of the foreign body and 'marker' on same vertical line as with photograph 1, designating the point of the foreign body 'x,2' and that of the 'marker' '0,2.' Then connect by a continuous straight line point '1' on left vertical line with point 'x,1' on right vertical line, also by a broken line with point '0,1'; connect point '2' in a similar way to 'x,2' and '0,2.'

"It is evident that the point where the *continuous* lines cross represents the location of the 'marker,' and that the point where the *broken* lines cross is the exact location of the foreign body in the vertical plane. As the relation between the eye and the 'marker' is known, draw schematically an eye according to its anatomical measurements in its correct position, using the vertical measurement previously made from the center of the cornea to the upper extremity of the 'marker.' The location of the foreign body to the eye in the vertical and lateral meridians is thus made plain.

"Now for the upper part of the figure. Mark a point on the left vertical line '1' and also a short line at the corresponding horizontal point on the right vertical line. Then in photograph 1 measure the distance from the shadow of the *vertical* wire to the shadow of the 'marker,' and mark the point of that measurement above the crossing of the short line '0',1''; also measure the distance from the shadow of the foreign body, and, as above described, mark it 'x',1'. Connect point '1'' by a continuous line to '0',1'' and by a broken line 'x',1'.' Then erect across the paper a perpendicular continuous line through the point corresponding to the 'marker' and a broken perpendicular line* through the point corresponding to the foreign body in the lower part of the diagram. Again it is evident that the points where these lines cross the above lines will mark the exact location of the

* Note. The broken perpendicular line was by mistake omitted from the drawing and does not appear on the plate. Its proper location is indicated by a mark covering the dotted lines in upper and lower globe.

'marker' and the foreign body in the horizontal plane. Again draw the eye in its correct relationship to the 'marker,' using the other measurements from the 'marker' to the apex of the cornea. Thus the location of the foreign body in relation to the eye in its horizontal meridian is revealed and the localization is complete."

Sweet of Philadelphia (*Trans. Amer. Ophth. Soc.*, 1897, p. 88) was probably the first to seriously take up the work of localizing foreign bodies in the eye by means of the X-rays.

Mackenzie Davidson published the first description of his method in the *British Medical Journal*, January 1, 1898. The methods developed by both of these gentlemen are excellent. Both deserve much credit. The plan of producing stereoscopic pictures was first introduced by Mackenzie Davidson who effected it by making two exposures on separate plates, as follows: Before the first exposure is made the tube is shifted 3 centimetres to one side of the anodal axis exactly in the horizontal or vertical plane, and the second exposure is taken with the tube 3 centimetres to the opposite side. The patient must not move his head from the beginning of the first to the conclusion of the second exposure. The distance from the perpendicular on either side, which should be equal, may be varied at the will of the operator. The distances mentioned give good stereoscopic views.

At the present time, Mackenzie Davidson employs a couch, placing the patient in the recumbent position. The Crookes tube is placed in a box lined with lead oxide which is impervious to the X-rays and serves to protect the operator from their effects, and the box is placed on "ways" arranged under the couch so that the tube may be readily adjusted to any desired position.

The modification of Mackenzie Davidson's apparatus as devised by B. Schumayer (*Fort. a.d. Gebiete d. Röntgenstrahlen*, IV., p. 81) made for the purpose of simplifying the process and of making it more accurate, does not simplify, nor does it add to the accuracy of the determination.

A. Kohler (*Fort. a. d. Gebiete d. Röntgenstrahlen*, 1902 and 1903, p. 160) employs a method based on the motility of the eye to determine the presence of the foreign body *in the eyeball.*

Three negatives may be necessary; first, a lateral or a sagittal skiagram with the eyes quiet (patient looks in one direction, may or may not fix an object). A relatively sharp shadow of the foreign body is obtained on this plate. A lateral or a sagittal skiagram is now taken. If lateral, the patient is directed to move the eyes slowly upward or downward during the exposure. The shadow of the foreign body obtained will be blurred if the foreign body is situated in the eyeball, except it be small and in the axis of rotation. If a sagittal exposure is made, the movement of the eye is from side to side. A blurred shadow of the foreign body is obtained. While this method is sufficient under favorable conditions to show that the foreign body is situated in the eye, it may fail if the foreign body is small and located at the center of rotation of the globe. It is of no value if the globe is fixed. Again, the method gives results that are too crude, as the exact part of the eye in which the foreign body is lodged cannot be determined.

The methods of Levy-Dorn (*Deutsch. med. Woch.*, 1897, p. 13), of Burka (*Deutsch. med. Woch.*, 1896), of Rémy and Contremoulin (*Bull. de l'acad. de médecine*, XXXVII, May 30, p. 354) are not applicable to the eye. Professor Barrell's method (*Arch. of the Roentgen Rays*, 5, p. 29) could be employed, but is not so free from possible error as are the methods of Sweet and Mackenzie Davidson.

Dr. Fox of Philadelphia employs a device for locating foreign bodies in the eye by means of the X-rays which differs materially from the methods that have been described. (For an illustrated description of Dr. Fox's method see *Diseases of the Eye*, Fox, p. 374.)

Dr. Fox's method is attended by more difficulty than some of the others and is not more accurate.

Dr. Cowl of Berlin has recently published a new method of localizing foreign bodies in the eye, which consists in making one lateral view through the side of the head and another with the plate placed in the mouth, and the tube placed directly over the head so that the shadow is cast downward upon the plate and therefore shows the antero-posterior distance. In using this

method, it is of course necessary to place on the orbit or in some position near it wires or pieces of metal ("markers") which may be used as guides in making measurements. The shadow will then show the position of the foreign body with reference to these metallic "markers."

Fluoroscopy, which has been elaborated by P. Bernbach of Cologne (*Fort. a. d. Gebiete d. Röntgenstrahlen,* VII, p. 33), is not of value in locating foreign bodies in the eye and orbit for a number of reasons. One is that it often happens that the foreign body is so small that it cannot be recognized with the fluoroscope; another, that if it is seen, its exact location in eyeball or orbit cannot be satisfactorily determined. In some cases in which the foreign body is large and the question to be settled is its approximate location, the fluoroscope may suffice. Movement of the shadow of the foreign body on movement of the eyeball would suffice to show that the foreign body was in the eyeball, but, if it did not move, the fluoroscope would not suffice to determine whether the foreign body was in the eyeball or outside of it.

Charts for plotting the position of the foreign body in the tissues of the eye and orbit are convenient, as an illustration of the location gives one a much better idea than is given by a record of measurements only. Sweet's chart is a very excellent one, so far as the eyeball itself is concerned. In the writer's opinion other details should be added. The chart which is here presented (Fig. 6) is a modification of Dr. Sweet's chart. It combines the outlines of eyeballs, nerves, and orbits in three planes on a field traced in millimetres. By means of this chart the location of the foreign body when plotted can be seen at a glance. Its size and its distance in relation to parts of the eye and orbit can be readily determined in millimetres by the area that it covers and by the place that it occupies on the chart.

DISCUSSION.

Dr. William M. Sweet, Philadelphia. — It is eight years, as Dr. Weeks has said, since I first presented before this Society the method and apparatus I employ in the localization of foreign

MODIFICATION OF DR. SWEETS CHART

FOR

PLOTTING LOCATION OF FOREIGN BODIES IN THE EYE AND ORBIT

BY JOHN E. WEEKS M.D. AND GEO. S. DIXON M.D.

Scale Full Size

Name_____

Surgeon_____

Date_____

No._____

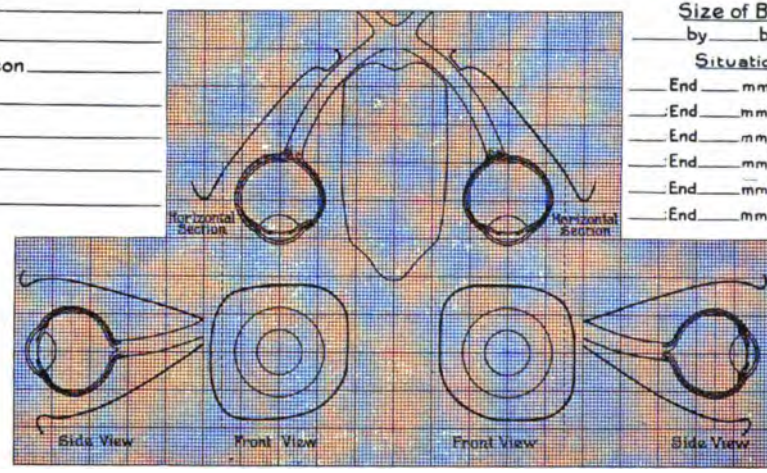

Size of Body

____ by ____ by ____ mm

Situation

____ End ____ mm { Back of Centre of Cornea

____ End ____ mm { Back of Centre of Cornea

____ End ____ mm { Horizontal Plane

____ End ____ mm { Horizontal Plane

____ End ____ mm { Side of Vertical Plane

____ End ____ mm { Side of Vertical Plane

E.B. MEYROWITZ

(Fig 6)

bodies in the eyeball. Prior to that time I had experimented for several months with various forms of fixed points of measurement about the eyeball, first using three indicators, one at each canthus and one opposite the center of the cornea, and afterwards one indicator, as in the manner described by Dr. Weeks, but I finally adopted two indicators. I have seen no reason during these years to change the underlying principle of the apparatus using the two indicators, although to secure the head of the patient more firmly, and to dispense with the tapes used in binding the localizer to the head, I have recently employed an apparatus clamped to the head, and this device I showed at the meeting of the Ophthalmic Section of the New York Academy of Medicine in February last. This arrangement consists of two uprights, one of which forms the plate-holder and indicators and the other firmly clamps the head against the plate. The patient lies upon a table during the making of the radiographs, a position I have always advocated and followed in my work.

To accurately locate a foreign body in the eyeball the operator must know the position of the anode of the tube at the two exposures. If only one indicator is employed the position of the tube at each exposure must be fixed or accurately measured. With two indicators of known relation to each other and to the plate, the angle of the tube need not be measured, since the shadow that one indicator bears to the other determines not alone the situation of the anode of the tube but gives the spot on the anode from which the rays originate. The only measurement to be recorded is the distance of the anode from the plate and the

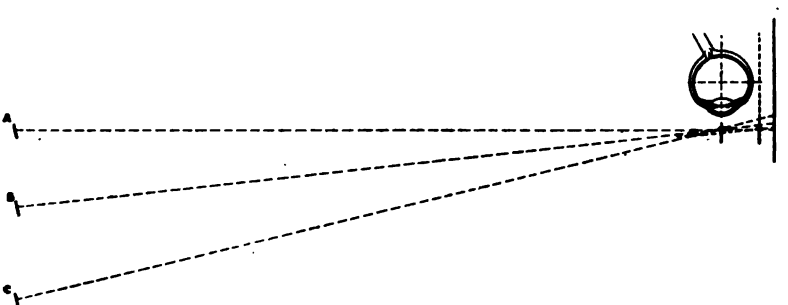

FIGURE 1.
Horizontal section of eyeball.

distance of one indicating ball from the summit of the cornea. This will be understood from the drawings on the blackboard. In the drawing (Fig. 1) is represented a horizontal section of the

eyeball, with the two indicators in the position which they occupy at the time of making the plates, one at the measured distance from the center of the cornea and the other at a fixed distance to the temporal side. In the second drawing (Fig. 2) is a vertical

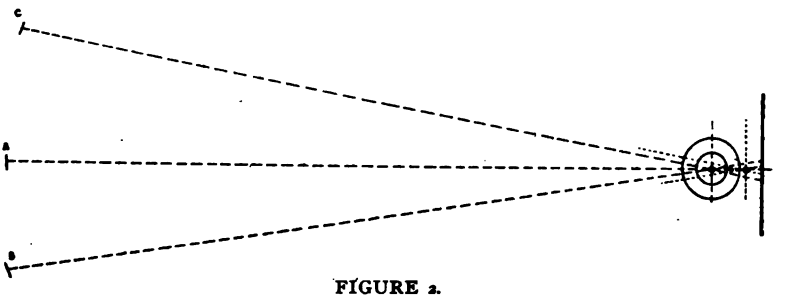

FIGURE 2.
Vertical section of eyeball.

section of the eyeball, the spot at the center representing the indicating ball opposite the center of the cornea, while the spot to the temporal side represents the external indicator.

In making the radiographs the X-ray tube is placed so that the rays pass through the injured eye obliquely, and the shadow on the plates of the indicator opposite the center of the cornea is therefore always posterior to that of the external ball, this distance increasing as the tube is moved anteriorly. Thus, if the tube is at A, Fig. 1, the two indicating rods will appear on the plate as one shadow or the two will be in the same vertical plane. If the tube is brought to B, the shadow of the center indicating ball will be posterior to that of the external ball, this distance increasing as the tube is brought forward, say to C.

The same is true as regards the vertical section of the globe. Thus, if the tube is in the plane of the two indicators, at A, Fig. 2, the shadow of one indicating rod will coincide with that of the other. If the tube is below the plane of the indicators, at B, the shadow on the plate of the indicator opposite the center of the cornea will be above that of the indicator to the temporal side, while if the tube is above the plane of the indicators, at C, the shadow of the center indicator is below that of the other shadow.

It therefore becomes a simple matter to determine the source of the rays at the two exposures, since the relation of the shadow of the two indicators varies with the position of the tube. Thus, employing circles to represent sections of the normal-sized eyeball, with the indicating balls in the position they occupied at the time the radiographs were made (see A, B, C, and D, Fig. 3, reduced

drawing of localizing chart), a measurement is taken of the distance that the shadow of the center ball on one of the radiographs is posterior to the shadow of the external ball, and this distance is entered above the spot (B) representing the external ball on the horizontal section of the globe. A line drawn from this point (K) through the center ball to the distance that the anode of the tube was away at the time of exposure gives the spot on the anode from which the rays came. The plane of shadow of the foreign body may then be determined by noting the distance on one of the radiographs that the shadow of the foreign body was posterior to the shadow of the external ball, entering this measurement above the spot (B), representing the external ball, and drawing a line from this point (O) to the source of the rays previously found.

The same method is followed in determining the planes of shadow of the foreign body on the vertical section of the eyeball (front view, Fig. 3). A measurement of the distance that the

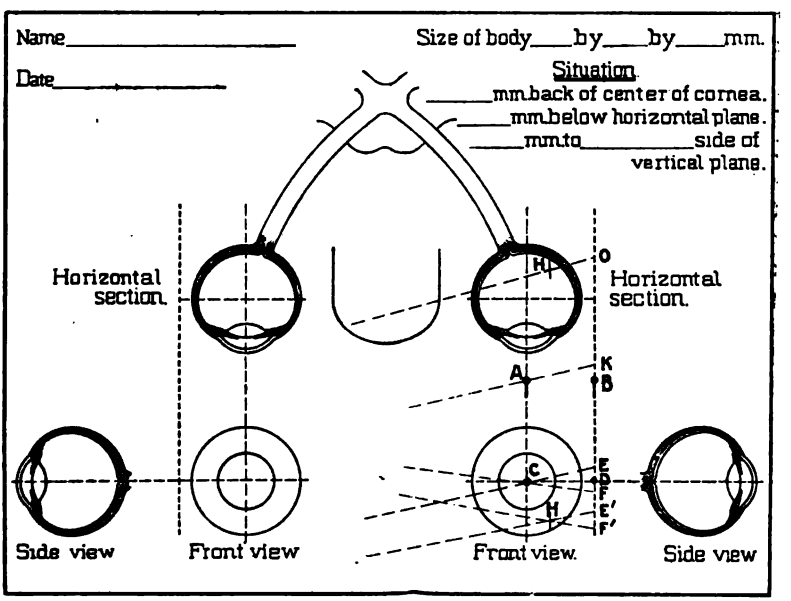

FIGURE 3.

Reduced drawing of Sweet's localizing chart, illustrating method of platting situation of foreign body in the eyeball.

shadow of the center ball on the two plates is above and below the shadow of the external ball is entered above and below the spot

(D) representing the external indicator on the diagram, and a line drawn from each of these points (E and F) through the center indicator (C) to the distance the tube was away at the time of exposure. This determines the source of the rays at the two exposures. If similar measurements are made of the distance the shadow of the foreign body is above and below the shadow of the external indicator, and these distances are entered above and below the spot (D) representing the external indicator, a line drawn from each of these points (E′ and F′) to the source of the rays, as previously determined, gives the two planes of shadow of the foreign body, and the point of crossing of these planes (H) is the situation of the foreign body as respects a vertical section of the globe. The depth of the body in the eye is at the point (H′) where a vertical line from the point (H) intersects the line of shadow of the foreign body on the horizontal section. The ruling of the localizing sheet in millimetre squares, as has been done in the chart shown by Dr. Weeks, will assist the operator in judging the position of the foreign body in the eyeball, and is therefore a useful addition to the chart.

Dr. J. E. Weeks, New York (closing) — Dr. Sweet has asked how we know, or determine, the position of the anode, or rather how we place the anode vertically to the cross wires on the plate (drawing on the board). A notched sight is placed vertical to the crossed wires on the side opposite to the anode. By sighting across this and the point of the crossing of the wires, the position of the anode can be determined. We place the anode of the tube directly in the line of vision.

Dr. Sweet is of the opinion that the location of the anode can be better made out by drawing a line through centers of the shadows of the markers, as by his method. Now, unless the line passes exactly through the centers there is a possibility of considerable error; fully as much as we should get by the other method, perhaps more.

WHAT ARE THE SO-CALLED REFLEXES WHICH CAN PROPERLY BE REFERRED TO EYE-STRAIN.

BY LUCIEN HOWE, M.D.,

BUFFALO, N. Y.

When Donders showed that the group of symptoms which had been called asthenopia, was in reality dependent upon efforts of accommodation or convergence, he included in this first group only the few symptoms which were intimately related to the eye itself. These were principally pain or discomfort at near work, imperfect focusing or blurring of vision, and some hyperæmia of the conjunctiva or increased lachrymation. A little later we learned that a second group of symptoms — including the various forms of headache — is often due to the same cause. This is not simply frontal headache, but that which is referred to the vertex, to the occiput and even extending down the back. The anatomical and physiological reasons for these headaches in connection with efforts at accommodation, it is unnecessary to dwell upon here.

Since the time of Donders we have also learned that when the relation between accommodation and convergence is disturbed — either by some anomaly, or even artificially — as we can do by placing certain glasses before the eyes, then, in certain persons at least, there results a feeling of discomfort more or less distinctly approaching nausea.

Nearly every ophthalmologist has now learned that these and a few similar symptoms are in some way associated with efforts at accommodation or convergence or with what we usually call eye-strain. These constitute a third group of symptoms and for reasons presently to be mentioned can properly be admitted among the reflexes of this eye-strain. Up to this point we are practically all of the same opinion.

But when we ask what other symptoms, or certainly what organic lesions are the result of eye-strain then confusion begins.

Thus most of us have seen curious cases in which some abnormal condition or symptom has apparently improved after proper glasses were fitted. But we do not venture to say that the glasses produced the improvement, because we have not taken the pains to make the equally important control observation — namely, to investigate how often the same abnormal condition improved *without* the fitting of glasses.

Concerning a very large number of changes in the eye or symptoms in different parts of the body, the more careful ophthalmologists simply say they are not yet ready to express an opinion as to whether these are, or are not the result of eye-strain.

They look with interest for painstaking investigation and for a calm impersonal statement of the results — no matter by whom they are given or what they are. But, while most of us are thus restrained by the desire to accept only what is really proved, on the other hand we find occasional practitioners of ophthalmology, especially in America, who are ready to assert in off-hand fashion that a host of organic changes in the eye, or elsewhere, and all sorts of symptoms are more or less directly the result of eye-strain.

Now in a question of this sort, the experience of any one individual is of comparatively little value, so it seemed desirable to ascertain how many had observed actual changes in the eyes, or other organs, or especially any reflexes in addition to those in the three groups already mentioned; which they had even thought could be ascribed to what we call eye-strain.

A provocation for raising this question has been offered since our last meeting by one of our members in a paper entitled "The New Ophthalmology." In that, the writer specified a large number of pathological conditions and symptoms which he considered to be due to eye-strain, and named other colleagues and practitioners, some not ophthalmologists, as participants in the same opinion.

Moreover, the impression was given that the rather extreme opinions expressed were being generally adopted by American ophthalmologists. It may be remembered that in order to ascertain the frequency of any such reflexes or other diseased condi-

tions, as shown by the experience of American ophthalmologists, a few months since I took the liberty of sending a circular letter to the members of this Society and to other ophthalmologists presently to be mentioned. A preliminary report can therefore be made of the results of this enquiry, though a complete study of all of the data obtained would require a much longer time than has elapsed since this circular letter was issued. As that letter may have been forgotten by some of the members of this Society and as it would, of course, be new to other readers, a copy is given. It is as follows:

183 DELAWARE AVE.,
BUFFALO, N. Y., Feb. 1905.

MY DEAR DOCTOR,

You are aware that some ophthalmologists insist that certain diseases of the deep structures of the eye, of remote organs, or of the general system, are more or less directly the result of "eye-strain."

Owing to the vagueness of most of these statements, they have usually been allowed to pass without notice. Of late, however, a member of the Ophthalmological Society, in publishing various books and articles, partly popular, has specified a number of these diseases as being the result of "eye-strain," and has named certain medical journals, and also several practitioners, as of the same opinion. Among the reasons why other ophthalmologists reject this "great truth," he says that "the desire for consultation practice, referred cases, professorships, hospital positions, and 'success' make the cunning silent or conservative"; moreover, that "nine-tenths of the glasses prescribed in these institutions" (public clinics) "are not correct," and proclaims various theses of a similar character, too numerous to mention here.

As it is quite possible that the few are right, and the many wrong, it seems worth while to obtain, if possible, the experience of a considerable number of practitioners. The following questions are therefore sent to members of the Ophthalmological Society, and to other ophthalmologists of large experience, in order that the replies, when tabulated, may show in just how many, out of thousands, or hundreds of thousands, of cases observed, it is possible to assert that these different diseases are, as claimed, the result of "eye-strain."

The reasons for the inquiry are:

1st. To learn the facts for my own satisfaction.

2d. To add these to more important data already collected in a study of the ocular muscles, which is now nearly completed.

3d. Because if the combined experience of many practitioners shows beyond doubt that these different diseases or any part of them *are* the

result of "eye-strain," that fact will be another contribution by Americans to the practical aspect of this department of ophthalmology.

If, however, such experience shows that these different diseases *cannot* honestly be ascribed to that cause, then in the future it will be impossible for any one to repeat those claims, as representing the opinions of American ophthalmologists.

With this rather extended explanation, necessitated by the circumstances, I venture to ask if you will fill out the blank on the opposite page and return it in the stamped envelope here enclosed. If, in the list of diseases specified none have been seen which were the result of eye-strain, please write across that part of the paper the word "none." If you have seen any, then specify the number, and add in a foot note whether or not you would be willing to give more data or detailed histories if requested to do so.

Any remarks or comments which follow would simply be classified, and no names would be mentioned without first asking permission, as it is desirable to keep the inquiry as free as possible from any personal bias.

Very truly yours,

LUCIEN HOWE.

"The questions are as follows:

1st. How many, or about how many cases of diseases of the eye have you recorded as seen in private and in hospital or dispensary practice altogether?

2d. Among them all how many have you recorded in which "eye strain" can justly be considered in any way a cause of any one of the following diseases or conditions? (These having been specified by the author of the New Ophthalmology as being the results of "eye strain".)

Keratitis? Iritis? Glaucoma? Cataract?
Choroidal diseases? Hyperaemia of the retina?
Diseases of the macula in any form?
Pigmented retinitis? Other retinal diseases?
Sinus diseases? Phyryngitis? Laryngitis?
Aphonia? Common colds? Influenza?
Pneumonia? Tuberculosis?
Anorexia? Denutrition? Intestinal Fermentation?
Constipation? Disorder of the Liver? Dyspepsia?
Loss of appetite? Nephritis? Cardiac palpitation?
Chorea? Epilepsy? Insomnia?
Scoliosis?

"This letter was sent

1st. To 162 members of the American Ophthalmological Society;

2d. To eight other ophthalmologists whose opinions were asked because of their unusually large experience, or because they had expressed the opinion that eye-strain was the cause of a considerable class of reflexes;

3d. To twenty-eight others who were also not members of this Society, some of whom did not claim to be ophthalmologists, but whom the writer of "The New Ophthalmology" had named as being advocates of the so-called advanced views.

One hundred and five replies have been received to the 208 letters which were sent out. The members of this Society returned by far the largest percentage, and to them I wish to express my thanks still again for these answers, as the search for the desired data must have involved no small amount of time and care.

In attempting to tabulate these replies, a few simple rules were followed:

1st. When an observer gave the total number of cases, which he had seen in a range from minimum to maximum number, — for example, when he stated that he had seen from thirty to forty thousand cases, — the lowest number mentioned was tabulated.

2d. When an observer reported that he had not observed a single case of a given kind, that statement was simply entered in the table.

3d. When an observer reported that he had seen this or that symptom as a result of eye-strain, at the same time giving the *number* of cases in figures even within a certain range — for example, eight or ten times — then here also the lowest number was taken to safely represent his experience.

4th. When an observer did not use any figures to express his experience, either as to the total number of patients seen by him or in the number of cases of reflex of any kind, — when, for example, he reported having seen "several," or "a few," or "not many," then evidently it was impossible to incorporate these statements in a table of statistics.

The results of the enquiry were as follows:

Total number of replies received was	105
Number who gave no figures nor approximation (some saying they are not ophthalmologists at all), ...	34
Number who reported at least approximately their total clinical experience was	71
In these 71—the number who answered all of the questions with figures; that is, in such a manner that they could properly form a part of a table of statistics, ...	24

Let us consider first the experience of these 24 observers, whose reports were complete. They had treated at least 1,245,685 patients. If we count 25 to 30 per cent. of these as cases of refraction or muscular anomalies (which is a low percentage even for hospital practice, in America) then we find that they had treated together something over 350,000 cases in which so-called eye-strain is factor.

Twenty of these twenty-four observers reported that they had not seen a single case in which the diseased conditions or reflexes mentioned in the circular letter were apparently due to eye-strain. Four of these observers, however, reported that the following were apparently the result of the eye-strain, namely: Choroidal diseases 3, diseases of the macula 1, hysterical laryngitis 1, chorea 1, epilepsy 5, insomnia 12. That is to say, these are all of the diseases or reflexes which were found by these twenty-four men among about 350,000 cases of refraction or muscular anomalies.

At first glance it may seem disappointing to have received only twenty-four answers, which contain statistics capable of being tabulated, from the 208 letters which were sent out. A moment's reflection, however, will show that this number is really quite large. For, when we remember the high pressure system under which the American physician, especially the American ophthalmologist, usually works, it is rather a matter of sur-

prise that so many replies were received, especially when we take into account the time and care necessary to answer that circular letter thoroughly, as was done by at least some of our colleagues.

What has been said thus far of the results, relates only to twenty-four observers; but there were forty-seven others whose testimony is not to be left out of account. They gave approximately their total experience in figures, but they did not answer the other questions with figures. Instead they were in doubt as to having seen some of these conditions or reflexes (as can occur to any of us) or they reported simply "a few cases" or "many," etc. Evidently it is impossible to make a statistical classification of these replies. But on the other hand it *is* possible to classify the doctors themselves. That is to say, it is possible to state how many of the entire seventy-one saw examples of this or that disease or symptom in the list cited, and also what that experience was. This is shown in the following table. In that the first column gives the number of observers who have not seen any of the reflexes or conditions mentioned in the list. The second column gives the number of those who were doubtful if they had seen any such; the third column, the number who were quite sure that at some time they had observed some such symptoms or conditions; the fourth column (A) the number who had seen "a few"; the fifth column (B) the number who had seen "several" or "some." The sixth column (C) the number who had seen "a number" or more.

It should be added that a considerable number of other pathological conditions and symptoms, including altogether about one-third of those mentioned by the author of "The New Ophthalmology" as being the result of "eye strain," have not been seen by a single one of these observers among their several hundreds of thousands of cases.

	None.	Doubtful.	Yes.	A.	B.	C.
Keratitis,	64	4	1	2	..	..
Iritis,	66	2	..	3	..	..
Glaucoma,	60	7	1	3	..	..
Cataract,	60	4	1	5	..	1
Chorodial diseases,	58	2	3	8	..	..
Hyperaemia of retina,	46	4	4	14	..	3
Macula changes,	60	3	3	5	..	..
Anorexia,	67	1	3	..	..	..
Denutrition,	66	..	3	2	..	..
Intestinal fermentation,	69	..	1	..	1	..
Constipation,	67	..	1	3	..	..
Disordered liver,	68	..	1	1	..	1
Dyspepsia,	60	..	4	7	..	..
Loss of appetite,	60	..	4	7	..	..
Nephritis,	69	2	..	..	..	..
Cardiac palpitation,	65	..	3	3	..	..
Chorea,	46	2	4	18	..	1
Epilepsy,	55	2	1	13	..	..
Insomnia,	49	2	8	10	..	2
Scoliosis,	69	1	..	1	..	..

These data and a more careful study of the answers shows:

1st. That the personal equation enters largely into these reports. Only comparatively few individuals have seen many such reflexes while most have observed only a few or none at all.

2d. This large experience shows beyond question that in the future it will be impossible for any one to repeat the claim that these reflexes or conditions or any of a similar kind are considered by most American ophthalmologists to be the result of eye-strain. This is simply the assumption of a few enthusiasts.

3d. An important cause of our confusion is the lack of definition of the morbid conditions under discussion, such terms as "intestinal fermentation," "disorders of the liver," "nephritis," etc., having no definite meaning.

4th. Another cause is the lack of exact diagnosis of the condition or the symptom which is suspected to be the result of the eye-strain. One man may call a hyperæmia of the retina what another would call normal eye-ground.

In view of these facts if we ask finally what are the symptoms which can be referred to "eye-strain," we can safely include

in that list, those in the three group first mentioned, namely, symptoms referred to the eyes, to the head in general, or the stomach. Other morbid conditions may be dependent upon eye-strain, but proof of that is what we need and not simply the aftive evidence, but especially the negative evidence of controls observations.

When any condition or symptom is stated to be due to eye-strain, then if that condition or symptom is one which even the majority of other practitioners have not also observed, evidently the burden of proof is on the person who makes any such assertion. It is for him to show that a real relation does exist between the eye and that condition or symptom. Also, the more unusual that supposed condition or symptom is, as compared with the very large experience here collected, the more careful then must a writer be to make his proof abundant and conclusive.

He who does that in a patient, painstaking manner, renders a distinct service to ophthalmology. He who does not or can not furnish such proof, simply indulges in statements which are, to say the least, misleading and unscientific.

DISCUSSION.

DR. ALEX. RANDALL, Philadelphia. I am not prepared to bring forward statistics, nor to make any very startling assertions, with regard to the reflex disturbances from eye-strain, but if I know anything in ophthalmology it is the occurrence of anatomical lesions of the eye, in the retina, choroid, and other portions, as well as various reflex neuroses, as a result of eye-strain. I have never seen epilepsy cured by its relief, but I have seen it mitigated so much that the sufferers practically ceased to have attacks. As to the production of choroidal irritation of marked degree and of forms that can go on to serious trouble, I am so confident that, if there are any who doubt it, I hope they will study the matter very carefully. I think they will surely recognize, if they so do, that such conditions frequently arise from eye-strain.

DR. WALTER L. PYLE, Philadelphia. I think Dr. Howe deserves a great deal of credit for his statistical labors, but I found his questions so irksome and difficult to answer that I believe his

work will be rather negative as to definite conclusions. I think it is wise to get some definite expression of opinion regarding this subject, but to pass final judgment in the face of the indifferent way in which these questions have been answered would not be wise.

In regard to the difference between functional and organic disease, I do not see where one can draw a definite border line. Functional trouble, if long continued, may result in organic change. As to the relation of degree, persons with very high degrees of ametropia are not likely to suffer from severe asthenopic symptoms, reflex or otherwise, because the optic defect is too great to be overcome by ciliary strain, and there is no continuous ciliary effort as in the cases of slight ametropia. Such patients usually complain of the diminution of visual acuity, and not of conjunctival irritation, headache, car-sickness, etc.

DR. LUCIEN HOWE, Buffalo (closing). In regard to the character of the questions, I may say that I presented them as simply as they could be made. I asked for "yes" or "no," and "how many." It was gratifying that out of 208, 105 replied.

What we need in America is careful investigation, instead of so much random talk in regard to eye-strain. That is the gist of the subject. We must admit promptly that the case is unproven, instead of making indefinite statements. I think after attention has been called to this matter a larger number may be induced to look over their cases and draw some definite conclusion.

RECURRENT IRITIS; A STUDY OF NINE CASES.

BY HIRAM WOODS, M.D.,
BALTIMORE, MD.

Text-books give comparatively little attention to Recurrent Iritis. Reasons are apparent. Diagnostic symptoms of recurring and primary attacks are the same, and so is the treatment. So far as I know, there is no reliable method of preventing recurrences. Consequently, after the etiology, symptoms, and treatment of the various forms of the primary affection have been described, there is little for an author to say beyond stating what forms are prone to have recurrence, and what influence, if any, such local abnormalities as posterior synechiæ, persistent deposits on the posterior corneal surface, etc., may have in increasing the danger of recurrence. Brief quotations from standard works will suffice to show accepted professional opinion regarding this disease in its most important features. Causes are, in the main, constitutional. De Schweinitz says that recurrences are uncommon in syphilitic iritis and that the exudate is usually abundant. The opposite is true, in both instances, of the rheumatic and gouty forms. Iritis may be the earliest manifestation of gout. Gonorrheal iritis, he thinks, is more common than is usually supposed. It neither follows immediately upon urethritis, nor is coincident with it, an arthritis often intervening. It is attended with severe pain and may relapse with each attack of gonorrhea. He thinks there is no adequate proof that posterior synechiæ can cause recurrence of iritis; that the "tendency of rheumatic iritis to recur requires preventive treatment in the forms of regulated diet, use of mineral waters, and proper attention to change of clothing according to the vicissitudes of the climate." Fuchs gives the same description. The small influence of posterior synechiæ he illustrates by citing the immunity from recurrence if the adhesions have resulted from an iritis following corneal ulcer-

ation, and the tendency to recur if rheumatism, gout, or syphilis caused the first attack. Iritis from these causes is apt to recur without synechiæ. In rheumatic iritis recurrence often coincides with return of joint symptoms. He thinks that gonorrheal iritis does not usually come till *after* arthritic disturbance; that it is prone to recur and the recurrence is often associated with renewal of urethritis or joint trouble. While the above quotations represent teachings of the present day, one finds, in tracing back their gradual evolution, that mainly in three ways have views of the causation of recurrent iritis undergone change: 1. What was formerly put down as "idiopathic iritis," and even now must sometimes be so considered, is often an early manifestation of gout or rheumatism, maybe hereditary, constitutional symptoms appearing at a later time; 2. Gonorrhea has not received its due recognition as a cause. Explanation seems to be the arthritis which usually intervenes between the urethritis and iritis. This joint involvement is in most cases of gonorrheal origin susceptible of bacteriologic demonstration, and yet has been looked upon as essential rheumatism. Subsequent recurrences of iritis have then been called rheumatic; 3. Posterior synechiæ have been given undue importance. That they are a source of danger when the pupil is excluded or occluded is, of course, recognized now as it was formerly; but even so, as Swanzy and others pointed out years ago, their danger is not so much in the direction of recurrent iritis as of secondary glaucoma, destructive cyclitis, etc. Review of such works as old editions of Swanzy, Nettleship, Higgins, Soelburg-Wells, and even as far back as Dixon, William MacKenzie, and George Frick's English edition of Beer, bring out in a most interesting way the gradual development of our present definite view of iritis.

I have had under observation for a series of years several typical cases of recurrent iritis. While the clinical history of the cases is appended I beg to call attention to some lessons which these histories teach. In the main, observations confirm prevailing views; in some details they do not.

1. Cause of original attack. In three cases of the nine it

was acute inflammatory rheumatism (Cases 3, 7, and 9). One of these (3) contracted gonorrhea two years after his rheumatism and *before* his first recurrent iritis. In two cases (2 and 5) there was the classical order of gonorrhea, arthritis, limited to one joint — the ankle in one case, knee in the other — and iritis. In but one case (6) was the primary iritis syphilitic. In two (1 and 8) the assigned causes of the primary attack was glare from the water and "unknown." In the families of these patients there is history of gout or rheumatism, and I am more disposed to attribute the iritis to these hereditary tendencies than to the causes given. One of these patients (1) contracted gonorrhea with subsequent arthritis in one ankle before his first recurrence. The other (8) had one recurrence, in the eye first affected, after two years. Two years later she had her only attack of acute inflammatory rheumatism, and after another period of two years developed iritis in the other eye, which recurred in four months. The cause of the first attack in the remaining case (4) is indeterminable. Twenty years, at least, before the iritis, he had had gonorrhea. He was positive he had had nothing after that attack. A few months after his first iritis he contracted syphilis. Prompt treatment was instituted, and the disease ran a mild course. In the eighteen years since this infection there has been no evidence of lues unless, indeed, it be his recurring iritis. I am not disposed to accept as causes of his first iritis the old gonorrhea, or syphilis in the recurring attacks. The patient has always been a "high liver," and ocular gout seems the most probable explanation. He himself attributes recurrences to efforts to see; but of this I shall speak more fully in a moment. I do not find, in studying the *original* cause of the iritis, anything which differs from the usual teaching. There is, however, confirmation of the causative influence of gonorrhea. In three of the nine cases (1, 2, 5) and possibly two more (3 and 6) it played an important part. The characteristics of gonorrheal arthritis and the joint affections of articular rheumatism seem sufficiently distinctive to enable one to avoid an error in diagnosis. I believe

if more pains were taken to avoid this error cases of "gonorrheal" iritis would be seen oftener. Study of the apparently *exciting* causes of recurrence affords considerable interest. In three cases the patient was only aware that he would go to bed comfortable and wake with severe pain, the eye would rapidly redden, and in a day, without previous warning, he was in an attack. These men (Cases 9,6, and 5) presented as constitutional causes rheumatism, syphilis, and gonorrhea. While the causes were different, the ocular condition was nearly identical. In two there was total exclusion of the pupil, and in the third extensive synechiæ. Of the other six, all assigned the same exciting cause of recurrence — effort to use the eyes for near or sustained work. In one case (8) I was unable to observe early changes, seeing the patient only twice, for a few days at a time, to advise upon operative procedures; but in the other five I have been able to make repeated observations. One case (4) has defective visual acuity from secondary lens and vitreous cloudings. All the others have, with refraction correction, normal vision. These patients have sent for me or come to my office time and again with what they termed "flushings," which came after use of the eyes in reading, or at the theater. They were faint circumcorneal injection, and were observed after a paroxysm of pain, which the patient learned to recognize as indicative of trouble. The history of cases 1 and 4 illustrate the experience. Frequently the injection disappeared in a day without treatment or after a single instillation of atropin; but in every instance of recurrence of iritis in these patients paid and faint circumcorneal injection were the earliest symptoms, and followed eye tax. In Cases 1 and 4, where old adhesions existed, injection was first always *observed along the corneal margin adjacent to these synechiæ*. At first I instilled atropin as soon as this injection was observed. At other times, because the pupil was active, the cornea free from deposits on its posterior surface, and the patient unwilling to have atropin used until the diagnosis was reasonably sure, I refrained from its use. Often no harm was

done by delay. But some of the worst attacks which Case 1 experienced began with two or three days of this slight redness without other symptoms than moderate pain. Then the pupil shut down in spite of all I could do.

Eye-strain has been insisted upon as a possible cause of recurrent iritis, notably by the late Dr. Noyes. In one of my cases (4) there was secondary lens and vitreous clouding, reducing V to 20/50, and in two others (7 and 8) permanent deposits on the posterior surface of the cornea, which did not lessen visual acuity. Myopic astigmatism against the rule, hypermetropic astigmatism .5 D. with rule, and hypermetropia 1.5 D. were associated refraction errors. Glasses improved vision somewhat, but did not lessen irritability on work. In the other three, however (1, 2, and 3), hypermetropic astigmatism with axes at 120° and 75°, mixed astigmatism, with rule, and 2D. myopia were found, and correction has been of decided benefit. The patients are all engaged in active life, and report that removal of glasses soon brings the old sensations which they have learned to associate with beginning attacks.

The *course* of iritis in these cases has been in some respects atypical of usual descriptions. For instance, in none of them was there a return of constitutional or local evidence of the original cause of the eye lesion. The gonorrheal cases did not have urethritis, the rheumatic did not have rheumatism. Possibly an exception should be made in Case 1, who had acute tonsilitis during the seventh attack of right iritis and acute pharyngitis in the ninth. This patient's first attack I have attributed to hereditary tendency to rheumatism, while recurrences may have been attributable to gonorrheal infection, with arthritis, *after* the first iritis, or to whatever produced the first attack.

The behavior of the exudates was somewhat different from that usually taught, in that it was abundant in rheumatic cases. Cases 3, 8, and 9 were certainly rheumatic. In Case 7 mild rheumatism occurring five years before outbreak of iritis was the only assignable cause. Case 1 was either rheumatic or gonorrheal.

In all the exudate was abundant. In two cases (7 and 8) deposits on posterior surface of cornea seemed to be permanent. So far as I could judge the tendency to exudate depended not so much on the cause of the iritis as upon the intensity of the congestion. Only one patient presented no exudate (Case 2). This was gonorrheal in origin.

The belief that each attack is less severe than its predecessor was, in a general way, confirmed, though Case 1 had his worst experience in the eighth attack in the right eye, with exudation and hemorrhage. Another confirmation was that *one* eye usually bears the brunt of the disease. But one eye was involved in three cases (6, 7, and 9). In Cases 1 and 3 the relation was, respectively, 11 to 2, and 3 to 1. In Cases 2 and 8 the two eyes were involved equally, while in 4 and 5, though figures were not obtainable, it was evident that one eye had been the greater sufferer.

Iridectomy was done four years ago during acute inflammation in Case 5, and to date there has been no relapse. Preventive iridectomy, between attacks, done for Case 4 by the late Dr. J. J. Chisolm and myself, for Case 9, were without avail. In both cases there was exclusion of the pupil.

In conclusion, I want to speak briefly of a few points in treatment. Dietetic regimen, mineral waters, etc., may be efficacious in preventing relapses in rheumatic cases; but I have not seen such results. My general rule is to refer such cases to their physician. Often they come back with printed slips of what they can and can not eat in gout or rheumatism. Such rules are observed until the next attack of iritis, and then they lose their faith. Two of the men considered here had their worst attacks while strictly following prescribed regimen and refraining from wine, etc. After disgust at a relapse or two they took up their old life of moderate eating and drinking and had no greater trouble than before. Another case (7) was distinctly benefited when all rheumatic regulations were withdrawn and generous diet allowed. I incline to the opinion that unless there are other evidences of rheumatism and gout than the iritis affords, general supporting treatment is preferable

to that directed to some dyscrasia of whose existence we are uncertain.

The repeated attacks of circumcorneal injection, near the synechial area, usually appearing after eye-strain, and the frequency of this limited injection as the earliest symptom of a recurrent attack led me to use atropin as a prophylactic in two of the cases, 1 and 4. In the former I had to discontinue its use because the man was well and wanted to go to work; but while the pupil was kept still he was free from trouble and had a relapse after its release. The other patient keeps his pupils constantly under weak atropin, one-half grain to ounce. He has only 20/50 vision, and adhesions along the lower border of the pupils, opposite Dr. Chisolm's iridectomies. He claims (and his claims seem to be just) that as long as he keeps the pupil quiet and does not use his eyes, he is free from trouble. Discontinue atropin or resume eye work and he has trouble. His last attack, in November, '04, was the first for two years, and followed non-use of atropin for a few days, through mistaking a boric acid solution for atropin, and an evening of bridge whist. Of course, it is easy to exaggerate the importance of such things as these; yet ocular irritation, of whatever kind, must be recognized as an aggravating cause in eyes predisposed to iridic inflammation. Pupillary reaction, pulling on synechiæ, *may be* enough in certain cases to start hyperemia. Iridectomy will not stop this pulling unless the synechiæ are cut through, for the uncut sphincter contracts. Again, in healing of an iridectomy new synechiæ may form. Atropin prevents the pulling, and my cases, though small in number, seem to teach that there is some efficacy in preventing it. In Case 2 there was no exudate, yet the pupil remained only moderately dilated after free use of atropin, and suddenly and completely dilated after jaborandi diaphoresis. In Case 7, there was the same pupillary condition, and the exudate was limited to a few spots on the posterior surface of the cornea. A large dose of salicylate of sodium was given, followed by sweating and depression. There was immediate dilatation. I

am not enthusiastic enough to assert that diaphoresis was the effective agent in securing the mydriasis from atropin previously ineffectual; but I am of the opinion that this class of remedies has a place of some importance in the early stages of iridic congestion, which merits farther study.

Atropin was the only mydriatic used except in Case 1, where it caused severe ciliary pains. As narrated in the clinical record, euphthalmin was substituted with excellent results.

The general truths underlying the *Recurrence* of Iritis seem to be that a constitutional dyscrasia, as Rheumatism or Gonorrhea, is always present; that the exciting cause of a relapse is one or another of numerous irritants which can produce hyperemia; eye-strain from effort to use an eye incapable of work from former disease, or refraction error; pulling on old synechiæ by pupillary action; exposure to wind, dust, etc. The only prophylaxis against RECURRENCE is to discover and, if possible, prevent, these exciting causes. If iridectomy, done for preventive purposes, has any beneficial effect, it is due to what we indefinitely call "nutritive changes," and has no relation to old synechiæ unless the latter have caused exclusion or occlusion of the pupil. The diagnostic use of weak atropin solution will show if synechiæ, *not* shutting off communication between the chambers, are a source of irritation. If the eye is found to be free from irritation while the pupil is kept quiet, the constant use of a weak mydriatic may be of benefit.

CASES.

Case 1. Merchant, 24 years of age, first seen in July, 1892, suffering from his sixth attack of iritis — the first I had observed. His left eye was involved, though all his other attacks had occurred in the right eye. Iritis was of the ordinary plastic type and recovered, with free pupil and faint pigment deposits on capsule, after a month. I obtained the following history, which I believe is reliable: There is a family history of rheumatism and gout. His first attack of iritis occurred seven years before I saw him, at the age of 17. At that time the boy had had

neither rheumatism nor gonorrhea, and the ocular disturbance was attributed to prolonged exposure to glare while on a yachting trip. A year after this attack he had acute rheumatism in one knee, probably following his first attack of gonorrhea. From his eighteenth to his twenty-first year there were several gonorrheal infections from which he seems to have recovered without trouble. He was under careful medical supervision and I am told by his physician that he never showed evidence of syphilis. After 1892 I did not see him for two years, when he came with plastic iritis in the right eye, recovering after six weeks with two or three points of synechiæ in the lower and outer quadrant. Ten months later, in March, 1894, and again in February, 1895, he presented slight pericorneal injection, near the synechial area, with severe pain. Under mydriatics both symptoms disappeared. There were fine deposits on posterior corneal surface in each of these experiences. In August, 1896, the right eye went through its seventh attack of plastic iritis. After two years, in September, 1898, there was a repetition of the circumcorneal injection, fine corneal deposits, and pain in the right eye, all yielding to mydriasis. Six weeks later, however, he went to bed with the worst attack of iritis he has ever had. The right eye was again involved. From the beginning there was exudation into anterior chamber followed on the fifth day by a hemorrhage nearly filling the chamber. Two days later, after a chill, and elevation of temperature, he developed double tonsilitis. He then remained well for twenty-two months, until August, 1900, when there was a repetition of the right circumcorneal injection, near synechial points. This lasted two days and was associated with fine deposits on posterior surface of cornea. In November, 1901, he experienced his ninth attack of right iritis, associated with acute pharyngitis. For the first time atropin increased his pain, and I was forced to substitute euphthalmin in 10 per cent. solution, used every two hours and with good results, the mydriasis, while not complete, being fairly well maintained. In May, 1903, there was repetition of the right pericorneal injection relieved by atropin. Reviewing his case at this time I found that during the

eleven years he had been under my observation he had had but one attack of iritis in the left eye. This was in 1892 and the first I had observed. On the other hand, the right had been through four attacks of iritis with abundant exudate, and had experienced five brief but painful attacks of pericorneal congestion, specially marked near old synechiæ. The left pupil was free. I had often asked him to allow an iridectomy in the right eye between attacks, being induced to give this advice by the apparent immunity of the left eye, with its *free* pupil, and the repeated disturbances in the right where the synechiæ existed. In the summer of 1903 he had concluded to accept this advice; but early in the fall he came with his eleventh attack of iritis, but it was the left eye which was affected. This attack, however, was mild, recovering with two or three points of unyielding synechiæ. Since the fall of 1903, although there are adhesions of each iris to the lens capsule, he has been free from trouble.

Case 2. Clerk, 30 years old, has consulted me frequently during the past four or five years for transient circumcorneal injection and pain in either eye. At these times a mydriatic, used for diagnostic purposes, has apparently removed all the symptoms. In November, 1903, he consulted me with the same symptoms. Atropin produced only moderate but regular dilatation. The left eye was involved, while old capsular deposits in the right eye evidenced former iritis. The left was free from either corneal or capsular exudates. He was suffering moderate pain. Two days after I saw him I was taken sick and he came under the care of a medical friend. About the tenth day the eye was free from pain and congestion, pupil regular, but still incompletely dilated. Atropin was discontinued, and the man allowed to take a walk. The following day he was seized with violent pain, rapid contraction of the pupil, in spite of the prompt use of atropin, and deep circumcorneal injection. I resumed charge of the case at this time. Morphia was needed to secure rest. After three days' trial to effect dilatation by strong atropin solutions, he was given a profuse sweat with jaborandi, repeated the next day. Whether *after* or because, I do not know, but the pupil,

which had remained minute, dilated promptly and regularly, the capsule failing to show any point of former adhesions. He has normal vision in each eye by correction of his mixed astigmatism. The most interesting portion of the case is the history. When 19 years of age he contracted gonorrhea which lasted two months. When recovering from this he was seized with rheumatism in the right ankle, complicated by right sciatica, which persisted several months after rheumatism had disappeared. For two years then he remained well. A second attack of gonorrhea was experienced between two and three years after the first. He was under treatment for this eighteen months. During the third month he had a spasmodic stricture. The first attack of iritis occurred soon after the occurrence of this stricture and involved the right eye, lasting about six weeks. His ocular troubles, then, have been an attack of iritis in each eye, eight years intervening between the two, numerous attacks of transient circumcorneal injection and pain. Rheumatism, confined to one joint, following gonorrhea, is the only assignable cause. Syphilis is definitely excluded. The first attack of iritis was evidently accompanied by exudates; the latter was not.

Case 3. Lawyer, 25 years of age, acute rheumatism when 15 years of age, gonorrhea two years later, mild right iritis the year after acute rheumatism. Remained well for six years, when, in June, 1898, he consulted me with pain in the right eye, circumcorneal injection, deposits on posterior surface of cornea. Pupils were of equal size, responding promptly to light. As a safeguard, atropin was used, in spite of which the pupil contracted, with increased pain and lymph deposits on posterior surface of cornea and capsule of lens. Eye recovered after two weeks with normal vision by correction of myopia, two dioptres. His third attack of right iritis (second under my care) occurred in November, 1900, and presented practically the same symptoms as those noted above. There was, however, persistent pain for several days after the pupil had become dilated. In June, 1901, I saw him for his fourth attack, which, however, involved the left eye. There was considerable exudate upon capsule of lens, cornea,

and into anterior chamber, which underwent slow absorption. Both eyes have recovered without synechiæ and with normal vision after correcting his myopia. He has had no attack of iritis for three years. Syphilis seems to be excluded.

Case 4. Retired merchant, 56 years old. First seen February, 1901, with iritis in left eye. He gave the following history: His first attack of iritis occurred in 1875 in the left eye. There was no cause that he could assign; had always before been in good health save for indefinite symptoms of gout. Eye trouble was attributed to exposure at races day before. He recovered completely in the course of two months, and early in '76 contracted syphilis. In his early life, when a "youngster," as he expressed it, he had several attacks of gonorrhea. Shortly after contracting syphilis he developed rheumatic symptoms in his shoulders and back. He was confident, and I could find no reason to doubt his statement, that except for this gonorrhea, some twenty years or more before the iritis, there was no definite constitutional cause to produce eye inflammation. From 1876 until 1885 he went through "innumerable attacks" of iritis, always in the left eye. Then he had one severe attack in the right eye. The late Dr. Julian J. Chisolm iridectomized both eyes about the years 1886 and '87 for exclusion of the pupils. In 1901, when he came under my care, both eyes presented large colobomata above, ring synechiæ along lower pupillary margins, cloudy lenses, and vitreous opacities. No choroidal lesion could be found. Since then I have attended him in three moderately severe attacks of left iritis, associated with considerable exudate on posterior surface of cornea, lens, and, once, into anterior chamber. The vision in 1891 was R. E. 20/50 by minus 1.00, D. S., c/w minus 1.00, D. C., x 90 degrees; L. E., 20/50 by same glass. Subsequent attacks have not lessened visual acuity. In addition to the three attacks of iritis which have come under my notice, there have been a number of "flushings," to use his own expression, several of which I have seen. They are marked by slight circumcorneal injection and some pain. He says he can always produce an attack of these flushings, which have been invariably

the first symptom of recurring iritis, by reading, watching a theatrical performance, or making any effort to do eye work. He obtained a temporary respite from iritis after the iridectomies. Since he has been under my care mild atropin solution has been used constantly. He says that whenever he stops the atropin, flushings of both eyes and pain supervene. There has been no manifestation of syphilis since the early secondaries and the rheumatic symptoms in 1876. His physician says he was entirely cured, he believes. The points of interest in the case are, first, the appearance of iritis without constitutional cause — unless, indeed, a gonorrhea, cured twenty years before, could be so regarded; secondly, the contraction of lues after the iritis, thus introducing a constitutional cause, which might produce subsequent attacks; third, the tendency to relapse in but one eye; fourth, the failure of iridectomy to stop these relapses.

Case 5. J. C., 32 years old, liveryman, was admitted to the wards of the Maryland University Hospital in January, 1901. He was recovering from an attack of gonorrhea, his third or fourth experience, and at time of admission had rheumatism of gonorrheal origin in right knee. He gave a history of having been through several attacks of severe eye inflammation during previous years. The first had followed his first infection from gonorrhea, and had preceded rheumatism. The left eye showed active plastic iritis with exclusion of the pupil. Pain was intense. On right capsule were a few pigment deposits from former attacks. After two weeks' treatment with salicylates, atropin, heat, etc., without result, I performed an iridectomy under chloroform. His recovery was prompt, and the eye was restored to normal vision in the course of a month. I next saw him in the fall of 1903 at the Presbyterian Hospital, with plastic iritis in the right eye, unassociated with rheumatic pain. He recovered without synechiæ. The left eye, which had been most frequently attacked before operation, has been free from trouble for nearly four years. There was neither history nor evidence of syphilis. I would call attention to the clearly defined order of events: gonorrhea, and iritis sometime before admission to the hospital;

fresh gonorrhea, with demonstrated gonorrheal rheumatism, and iritis after admission; relief only after operation; and, finally, iritis in the *unoperated* eye, without return of urethral symptoms.

Case 6. P. F., 50 years old, was brought to me in March, 1895. The history was unsatisfactory, but it was evident that there had been a number of attacks of iritis, always in the right eye. The present attack had lasted six days, was accompanied by obstinate posterior synechiæ along superior pupillary margin, severe pain, deposits upon posterior surface of cornea. Pain was increased on touch. It was difficult to get a definite account of the cause of his first attack. The man had had both syphilis and gonorrhea, but no rheumatism. He did not remember whether or not gonorrhea had preceded his first eye attack, but was sure syphilis had. This attack was uneventful, the patient being well in two weeks, with the upper pupillary margin adherent to lens capsule. I next saw him in February, 1899. He had right iritis with streaky infiltration of cornea and exudate into anterior chamber. Under ordinary specific treatment he made a prompt recovery, all the synechiæ this time yielding to atropin. In November, 1902, I attended him through his third attack of right iritis, and in May, 1904, during my absence from the city, my assistant, Dr. Davis, treated him again. After his recovery in 1902 I advised iridectomy, owing to extensive adhesions, although there was not exclusion of the pupil. The operation was declined. Attention is specially directed to the constant involvement of the same eye, syphilitic cause, extensive exudates.

Case 7. Mrs. W., 33 years of age, came to my office December 14, 1903, suffering, as she supposed, from a foreign body under the right upper lid. There was no foreign body, but a faint deep circumcorneal injection led me to suspect that there was more in the case than appeared. Vision was 20/15 in each eye, pupils were of normal size and reaction, cornea clear. The only item of interest in her history was a mild attack of rheumatism some five or six years before. She is not a strong woman, but is not anæmic, nor has her physician, one of our leading practitioners, been able to determine any organic trouble. The day

after her first visit to me, on December 15th, the circumcorneal injection was deeper, pain unrelieved. Atropin produced about two-thirds dilatation. No deposits on cornea or capsule of lens. For two weeks she remained in this condition, atropin solutions (1 per cent.) used every two hours, and even to constitutional effects, failing to produce farther dilatation. On January 1, 1904, while she was under salicylate of sodium and atropin, there was a sudden increase of the circumcorneal injection and pain. Deposits appeared on posterior corneal surface. She was now given three or four large doses of the salicylates at short intervals, which produced profuse diaphoresis, and this was followed by complete dilatation of the pupil for the first time since she had been under treatment. Two weeks later, when she was supposed to be well, atropin was stopped, with immediate return of circumcorneal injection and pain. During the late winter and spring of 1904 it was necessary to keep her pupil quiet by atropin, pain and injection returning as soon as it was stopped. In the fall she went through a moderately severe attack of iritis in the same eye while away from home. Soon after her return to Baltimore she again experienced several "flushings," in the right eye, not accompanied by much pain. At no time was there any evidence of rheumatic disturbance other than iritis. Indeed with the history of only one mild attack, five years ago, it seems uncertain as to whether rheumatism was the causative agent. There are now fine deposits on posterior surface of cornea. Visual acuity is normal with or without refraction correction: .5 H. As. x 90.

Case 8. Mrs. D., 27 years old, seen June, 1903, with right iritis of one week's duration. Pupil was widely dilated, deposits on posterior surface of cornea and lens capsule. From her physician, who had known her since childhood, I obtained the following history: There is a rheumatic and gouty tendency in the family running back at least three generations. The first rheumatic manifestation in this patient occurred in 1900. Four years before this she had had a severe attack of iritis in the left eye from unknown cause. The same eye had passed through a second attack two years later; both, therefore, appearing before her rheu-

matism, the right eye had had two attacks in February and June, 1903. Her vision was normal in both eyes with correction of her refraction error, 1.5 dioptres of hypermetropia. This patient does not reside in Baltimore and I have not seen her since 1903. I have understood that she has had several attacks of transient congestion and pain in both eyes. There has been no other rheumatic manifestation. Iritis before definite rheumatic manifestation is the point of special interest.

Case 9. W. H., age 35, had an attack of acute inflammatory rheumatism when he was 12 years old. Two years later there was some trouble in his left eye. Three years after this attack he was known to have had iritis. The following spring he had a relapse of rheumatism and was compelled to take to crutches for a year. During this time he had several attacks of mild inflammation in his left eye, undoubtedly iritis. During the next eight or ten years he seems to have alternated mild attacks of general rheumatism with left iritis, neither the rheumatism nor iritis being of long duration. In 1896, without previous rheumatic symptoms, he had the severest attack of iritis in his history. From then until I saw him, eight years later, in April, 1904, the left eye had undergone numerous attacks; the right eye had never been involved. I found left pupil excluded by total ringed synechiæ, unyielding to atropin. Vision in R. E. was 20/15 by refraction correction, plus 0.62, D. S., c/w plus 0.25, D. C., x 90. I confirmed the advice previously given him by Dr. Dunn of Richmond, that in view of the pupillary condition an iridectomy promised best as a preventive method. This operation was performed and a large coloboma secured. A recent letter from him, however, states that it was without effect. He has had two attacks of iritis since my operation, thirteen months ago, with continued rheumatic symptoms.

DISCUSSION.

Dr. H. F. Hansell, Philadelphia. The terms "relapsing" and "recurrent" do not indicate exactly the same affection, since the former refers to that form of inflammation which in the intervals between the active and acute inflam-

mation, though free from the external signs of inflammation is still the seat of increased vascularity or in which the seeds of the disease still lurk while the latter means that the eye perfectly recovers from the first attack and during the interval before the next is not only apparently, but really well. As an illustration of the former I may mention a case at present under treatment. An apparently healthy woman of 35 complained some weeks ago that vision in the right was dimmed. Inspection showed one small posterior synechia, a few fine opacities in the vitreous, and imperfectly marked pericorneal ring — a case of the so-called "quiet iritis." Under treatment the injection disappeared, the synechia was broken off, and vision became again perfect. In less than a week after the effect of the atropia had passed away all the previous symptoms returned. The eye again cleared up and now the patient is suffering from a third attack. An example of recurrent iritis is that of a young man who for three successive summers had violent attacks of acute iritis. In one the anterior chamber became filled with a weblike filmy membrane and vision was reduced to the perception of light. In all three attacks synechiæ were formed, but were later entirely broken away. The cause of the second case was undoubtedly the rheumatic and gouty diathesis of which the patient was cured by vigorous treatment at home and abroad. In the first case the cause is obscure, but may be ascribed to rheumatism.

I believe that the relapse or the recurrence is due in the great majority of cases to one of two conditions, namely, imperfect recovery from the first attack or the too early cessation of treatment and the still active underlying cause of the first attack. I think that the presence of posterior or anterior synechiæ may be disregarded in a consideration of the causation and the relapse referred to renewed activity of the fundamental disease.

Dr. C. J. Kipp, Newark. I have had my share of these cases, I suppose, and what has impressed me most is that they are the cases in which we get atropine irritation. The repeated attacks soon render the conjunctiva susceptible to atropine. In most all cases where I have had the patients under observation for fifteen or twenty years at some time or other I was obliged to stop the atropine and resort to other mydriatics. I recently saw mentioned by Scrini of Paris the use of atropine in olive oil and tried it but without good result. The continuous use of a solution of sulphate of zinc between the attacks is of benefit.

DR. S. D. RISLEY, Philadelphia. My own experience leads me to agree with the writer of the paper and with what has been said by Dr. Hansell. I rise to call attention to one fact which was not stated; namely, that in the attacks of iritis, in the majority of instances, the iris alone is not involved but the entire uveal tract and the inflammation subsides slowly, often requiring many weeks or months before the uveal tract has assumed a condition which may be called healthy. Then, such an individual on attempting to use the eye, or when exposed to light, will have these slight relapses with a moderate amount of ciliary injection, pain and sensibility to light. If these symptoms are disregarded they pass on to increased turgidity of the tract and into more or less severe attacks of iritis. So that I believe in many instances not only is the underlying dyscrasia present as an exciting cause of relapses, but that the recurrences are also frequently produced by the use of eyes too weak to permit such use because of the pathologic condition of the choroidal tract.

DR. S. L. ZEIGLER, Philadelphia. I have in a great many of these cases been able to get them under control by attention to the nasal condition. There is often an absorption of some material through the lymphatic chain causing these disturbances and nasal treatment has certainly often shortened the attacks and relieved the symptoms.

DR. HIRAM WOODS, Baltimore (closing). The necessity for care in discontinuing atropin was impressed upon me by some of these cases. Usually in treating iritis I use atropin until all injection has passed away; but then feel safe in stopping it. Immediate return of hyperæmia followed its discontinuance several times when these patients were under observation. Cases showing tendency to recur should be carefully watched for weeks after they are apparently well. Atropin was the only mydriatic used except during one of the attacks in Case I. Here it increased pain, and produced ciliary tenderness. Through a personal suggestion from Dr. Knapp, when he was visiting Baltimore a few years ago, and saw an obstinate case of iritis with me at the hospital, I substituted a ten per cent. solution of euphthalmine, used every third hour, with excellent results. The mydriasis is not so firmly maintained as with atropin; but, apparently through this occasional relaxation, ciliary tenderness decreased. I have never used zinc between attacks, as suggested by Dr. Kipp; but I can see how it might do good.

The point in the history of these cases which it seemed to me well worth bringing out prominently was the definite association between recurrence of iritis and effort to use the eyes. The explanation given just now by Dr. Risley is probably correct.

JUVENILE GLAUCOMA.

BY ROBERT SATTLER, M.D.,
CINCINNATI, O.

The following report of two cases of glaucoma in young subjects recites only, the following noteworthy points:

The first case, a little girl under 11 years of age, was brought to me with the history of failing vision during the last ten months or, shortly after completing her tenth year. She complained of so much difficulty at school that attendance was impossible, but she suffered no pain.

Her mother had confirmed simple glaucoma with complete abolition of vision at the age of 17.

Examination disclosed the following uncommon features. The episcleral vessels and muscular veins were prominent, but not particularly tortuous. The anterior chamber was deep. The pupils were possibly a little larger but their response to light impressions (monocular and associated) was prompt. The ophthalmoscope disclosed an uncommonly pronounced expression of posterior glaucoma. The optic nerve excavation was enormous and all the vessels dipping into it numerically increased and abnormally broad. The refraction was myopic. M. 4 R. E., V.=8/50. M. 4 L. E., V.=8/30. T+2.

A double iridectomy upwards was done with apparent arrest of the failing sight or at least it has been maintained at the same standard noted for several weeks after the operation.

The second case happened in a girl aged 17 without any discoverable hereditary predisposition. Acute congestive glaucoma of most pronounced declaration occurred during an acute attack of measles at the Cincinnati Hospital. The interne assumed that

it was catarrhal or phlyctenular in character and did not call my attention to the case until ten days after its manifestation in the left eye, and only after complaints of failing vision and pain were referred to the right eye.

It was stated that atropine had not been used before I saw her. Under persistent use of eserine for several hours there was no amelioration of the excessive pain and, as an acute attack seemed imminent in the right eye, immediate operation was decided upon.

Her general condition was bad. Vision was totally lost in the left eye which was excessively painful, and in the right vision was reduced to 0.1. In the course of the day an acute congestive attack came about in this eye. On the same day, under anæsthesia, scleral puncture of the left eye, for the reason that enucleation was violently objected to, and an iridectomy upwards in the right eye, were performed. This was followed by cessation of the attack, with its excessive suffering and high tension, and with preservation of a painless but considerably ectastic globe. Two years have elapsed and the left or blind eye is painless and its enlargement has not increased. The right eye retains an acuity of vision of 0.3. She is in good health and a hard worker.

DISCUSSION.

DR. W. C. POSEY, Philadelphia. Juvenile glaucoma is a very rare condition. In a study of 167 cases of glaucoma simplex made by Dr. Zentmayer and me in 1895, we found but one case under 25 years of age. This case was that of a boy 13 years old. Both corneæ were smaller than normal and the anterior chambers shallowed. Tension was elevated, but the discs were not pathologically excavated. The fields, however, for both form and color were concentrically contracted.

DR. HERBERT HARLAN, Baltimore. I should like to refer to a case I reported some time ago under the title of "Hereditary Glaucoma." The patient was a girl of 17, whose mother was blind, and I was able to follow the blindness back for five generations. I have seen four or five cases of cousins and sisters in that same family. In that case I did a double iridectomy and have kept track of it since. A few years later she had about the same

vision as at the time of operation. She has married and has seven children. She has retained about the same vision up to the present time. The other case I operated on has held the vision, so that it would seem that iridectomy in the subacute glaucomas in young children promises more than in senile glaucoma.

I have seen another interesting case in the past year — a girl of 17 who appeared with interstitial keratitis. As it got worse she called attention to the fact that vision in the other eye was bad and on examination it was found that she had glaucoma in that eye. It was iridectomized with good result. The interstitial keratitis appeared only on one side and the glaucoma only on the other.

DR. H. W. RING, New Haven. I think the last speaker has struck the keynote as to the causative factor; that is, hereditary influence. The only case I can recall was a student where there was a very marked hereditary tendency. This young man has glaucoma, his mother has it, and one or two of her sisters and brothers. If Dr. Sattler were able to follow out the family influence he would probably find this tendency to defective vision. In this particular case I mention I did a double iridectomy early. I have followed the case for two years now and there has been no retrogression.

DR. ROBERT SATTLER, Cincinnati (closing). In the first case there was no hereditary predisposition found, although it was investigated thoroughly. The grandparents were living in the same city and there was no history of trouble except in the mother and this little girl.

In the other case there was absolutely no family history towards the support of heredity as a causative factor. The mother of this little girl had simple glaucoma in both eyes and an iridectomy was done, but she became totally blind.

A CASE OF ACQUIRED CYST OF THE CONJUNCTIVA CONTAINING AN EMBRYONIC TOOTH-LIKE STRUCTURE.

BY EDWARD STIEREN, M.D.,

PITTSBURG, PA.

The following case of embryonic osseous tissue forming in the conjunctiva is unique in that it occurred after the tenth year of life.

The patient, Miss M., aged 16, was brought to me by her cousin, Dr. Paul J. McLain, on account of a tumor of the left eyeball. The history of the case as recited by her mother is as follows:

The growth was first noticed when the patient was 10 years of age. (The parent is positive that no growth was present during infancy.) At that time the tumor was about the size of a pin head. From ten years of age until two and one-half years ago it increased very little in size and gave no trouble whatever. The child then began to complain that the growth annoyed her; there was no pain, simply a disagreeable feeling. From this time on the tumor began to increase in size rapidly. During the last six months it annoyed her considerably, causing almost constant headache.

Examination. With the patient looking downward and inward and by retracting the upper lid a tumor of the bulbar conjunctiva is seen. The growth has every appearance of a dermoid cyst of the conjunctiva, is about the size and shape of an ordinary navy bean, and can be made to move slightly in all directions by force applied with the lid margin.

Excision was advised, and under holocain and adrenalin, local anæsthesia, the tumor was grasped with blunt tooth forceps. The sensation of a foreign body was imparted to the touch through the forceps, suggesting calcarous degeneration of the cyst. The tumor had rather a firm attachment to the episcleral tissue, but was shaved off with a cataract knife without difficulty. A small quantity of straw-colored fluid escaped from the cyst, the cavity being almost entirely filled with what appeared to be a well-formed, beautifully white, incisor tooth. It possessed a covering, no doubt periosteum, very loosely attached, which was, unfortunately, lost in making a dry preparation of the specimen. The "tooth" had a well defined crown and neck with a tapering extremity resembling a fang. It measured 10 mm. in length, 6 mm. in its widest diameter, with an average thickness of 2 mm. Half of the structure was prepared as a dry specimen and the

other half given to Dr. Elizabeth Moore, pathologist at Passavant Hospital, for histological study.

Histological Examination. The portion of the specimen used for histological examination was decalcified slowly in 1 per cent. hydrochloric acid solution. After decalcification, the usual technique of making celloidin sections was employed. Cross sections were made and were stained in hæmatoxylin and eosin and in indigo-carmine. The microscopical examination reveals well developed bone formation. The section presents a curved and a straight margin. On the curved margin the lamellæ are parallel to the external surface of the specimen and, probably, correspond to the fundamental lamellæ of true bone. The parallel system occupies about one-third the transverse diameter of the section. Scattered between the lamellæ are the spaces known as lacunæ — the bone corpuscles. The spiderlike processes by means of which the lacunæ communicate — the canaliculi — can be easily seen. The remainder of the section is occupied by distinct Haversian Systems. About each Haversian Canal are the concentric lamellæ, with the lacunæ communicating by their canaliculi with the canals. In many places the Haversian canals show an endothelial lining. Between the Haversian systems are lamellæ which correspond, probably, to the interstitial lamellæ of normal bone. The parallel system blends with the Haversian systems at the ends of the section. By the indigo-carmine stain a few of Sharpey's fibers between the lamellæ can be demonstrated.

Since the foregoing was written I have been informed by Dr. Edward Jackson that a similar condition was reported by Galtier, under the title "Sub-conjunctival Osteoma," in the *Annales d'Oculistique,* March, 1895, the article being abstracted in the *Ophthalmic Review* for May, 1895. Through the kindness of Dr. Miles Standish I was able to refer to the original article this morning. The author says, in part: "Occurrences of this nature are very rare. No mention is made of them in the best known works upon the pathology of the eye, and it is only in the extensive treatise by de Wecker and Landolt that we find a short

chapter upon this subject. Three cases are therein noted: one by von Graefe, one by Saemisch, and one by de Wecker."

Galtier reports a case of a girl ten years of age occurring in his practice. When the right eye, turned downward and inward, a well-defined projection the size and form of a slightly flattened pea was found at the equator of the eye, above the horizontal meridian and behind the equator. The growth was removed with toothed forceps and scissors. The author states: "What was my surprise, upon dissecting it, to find its contents hard, absolutely osseous, and formed of very compact tissue." Its length was one centimeter, its breadth, seven millimeters. The question that occurred to the author was whether this was really a new growth, or a portion of normal bone accidentally detached from one of the orbital walls. An histological examination showed that the bony tumor appeared to be composed of normal osseous tissue. The author's suggestion that the growth might be due to the presence of a fragment of detached bone rather than to an actual neoplasm, is supported by the history that the child had received a blow by falling and striking the right side of her face and forehead some six or seven months before. At the time, however, there was nothing which pointed to injury of the eye, and as his case resembles very closely the three recorded in de Wecker and Landolt's work, and the one reported by myself, and there is no history of traumatism in any of the four, I give his theory very little weight. It seems to have made a deep impression in Galtier's mind, however, as he concludes his article by saying: "I even question whether the subject of sub-conjunctival osteoma is a legitimate one, and whether the cases quoted would not better be included under the head of fractures of the orbital vault, with an encysted movable fragment of bone; this classification would slightly alter the prognosis, although it is true that these tumors are, up to the present time, classed with benign tumors of the conjunctiva."

FIG. 1.

In the histological examination of the case reported by me, it will be remembered that in several instances the section showed embryonic bone tissue, thus proving conclusively that bone can develop in the conjunctiva. Hence, it appears to me that Galtier's hypothesis in regard to osteomata, being encysted fragments of bone detached from the surrounding bony parts, is based on very slender facts indeed.

A CASE OF CYSTIC SARCOMA OF THE ORBIT; EXTIRPATION; DEATH.

BY HOWARD F. HANSELL, M.D.,
PHILADELPHIA, PA.

Reports of orbital tumors have been so frequently presented before this Society that I shall be brief in the verbal description of this new case. Moreover, the principal interest attaches to the photographs which graphically present the appearance and the enormous size reached by the growth and to the microscopic report.

The tumor undoubtedly had its origin in traumatism, thus differing in its etiology from many other cases which resemble it clinically. The case also is interesting in that it is an illustration of the great size such growths may attain when not interfered with by the surgeon's knife.

The patient was a boy of 18, who at 5 years of age had received a blow on the left side of the head. His family history is good. Some of his forbears had attained to great age and none had suffered from malignant disease in any part of the body. The only flaw in an otherwise clean family history is the death of three of his maternal uncles from tuberculosis. The patient had none of the usual diseases of childhood except measles. He had always beeen a frail delicate lad, uneducated and mentally and physically undeveloped. During the last ten years of his life his principal occupation was caring for his infirmity, which precluded the association of friends.

The nature of the traumatism to the left side of the head is unknown, but it was not severe enough to deprive him of consciousness. One month after it had been received the eye began to bulge forward and the sight to be impaired. Gradually a tumor appeared behind the ball forcing it more and more into prominence. The boy suffered more from the inconvenience and annoyance of the presence of the tumor than from pain during the thirteen years that had elapsed until I saw him, about January 1 of the present year. A tumor about the size of a man's fist protruded from the left orbit. Its roof, sides, and floor were partly covered by the distended skin of the lids; its anterior face, 7 cm. in diameter, by the red, glistening, and stretched conjunctiva. The only trace of the eye that could be found was a small, gray, round patch near the center of the anterior aspect under the conjunctiva that looked as though it might be the shrunken and opaque cornea. At this point during the operation was found an atrophied and compressed eyeball. The tumor was elastic and yielding to the touch in some places while in others it was hard and firm and not sensitive.

My colleagues, Drs. Hearn and J. Chalmers DaCosta, in con-

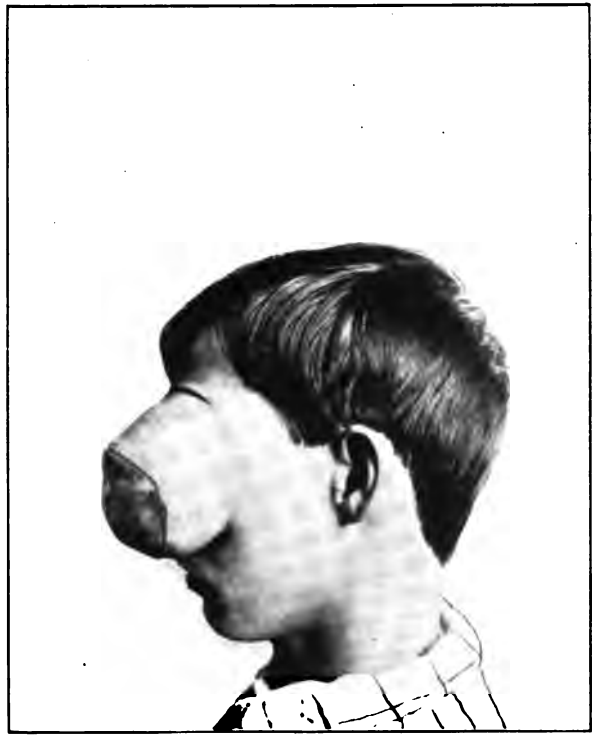

CYSTIC SARCOMA ORBIT - - HANSELL.

CYSTIC SARCOMA — HANSELL.

sultation with myself and Dr. Sweet, decided that the growth was a cystic sarcoma, and with a full understanding of the dangers of present operation and future recurrence on the part of the patient and his parents, advised removal.

On January 13, extirpation was performed without accident. A horizontal incision was made through the skin of the lids and conjunctiva, commencing at the external orbital margin and ending at the inner canthus. The lids and conjunctiva were dissected upwards and downwards, completely uncovering the tumor, which was then enucleated. Hemorrhage was insignificant. The tumor was completely enveloped by a capsule except at the orifice of the optic canal and sent no prolongations into any of the accessory cavities. The proximal end consisted of a pedicle which was attached to some of the postorbital structures or to another growth within the cranium. The periosteum of the orbit was intact and was not amalgamated with the capsule at any point. The orbital walls were thinned particularly near the anterior margin. The orbit itself was increased enormously in size, measuring in its horizontal diameter about 8 cm., or nearly three times the normal.

After enucleation of the tumor the cavity was packed with iodoform gauze, the lids trimmed and sutured leaving sufficient room for drainage. Although the dressing was frequently changed and the orbit douched with antiseptics, pus collected in such quantities that the sutures were removed and the entire surface of the wound exposed. Convalescence was seriously interrupted by a prolonged attack of erysipelas contracted from a sporadic case that developed in the wards. For many days the temperature varied from 103° to 104½°. Six weeks after operation the patient was sufficiently recovered to return to his home in Delaware. According to the report of Dr. James, who attended the boy at the latter's home, symptoms of meningitis developed within a few days and in three weeks the boy died. Death was probably due to continued growth of the tumor within the cranial cavity.

Report of Dr. W. M. L. Coplin, professor of pathology at the

Jefferson Medical College. Jan. 13, '05. Specimen consists of a large ovoid cyst-like mass of tissue weighing 315 grms. The antero-posterior diameter is 11.7 cm., the lateral or horizontal diameter 7.7 cm., and the supero-inferior diameter 6.4 cm. Posteriorly this mass tapers to a round pedicle 0.9 cm. in diameter; while the anterior end is rather blunt and capped by the walls of the collapsed eyeball, of which the cornea and anterior portion are cut away by a vertical incision which has permitted the vitreous humor to escape and exposed the dark retinal lining. Arising from the superior and externo-lateral surfaces of the eyeball and attached, respectively, to the antero-superior and antero-external-lateral segments of the tumor by shreds of muscle and fascia are two bands of muscle 0.8 cm. in width. The symmetrical contour is slightly varied by two rounded prominences, one bulging from the antero-superior and the other from the antero-inferior segments of the ovoid mass, and by numerous small hemispherical blebs, varying in diameter from 2 to 4 cm. and protruding here and there over the surface of the mass. The mass itself is pliable and elastic to the touch yet rather firm upon deeper pressure.

The entire specimen was fixed for 48 hours on 10 per cent. solution of formalin. The tumor was then incised, the line of incision passing from above downwards in the antero-posterior diameter of the tumor a little to the mesial side of the eyeball on the anterior aspect and of the pedicle in the posterior extremity. Upon incision 155 cc. of reddish-brown fluid issued from the interior. The outer portion of the tumor proved to be one large cavity which, in the superior half extended from the external to the internal or mesial wall. The only solid portion of the tumor is a bar of tissue varying in width from 2 to 3 cm., and in depth from 3 to 4 cm., occupying the lower and internal aspect and extending to the full length of the mass from the pedicle in the posterior to the eyeball in the front. This column of tissue presents a smooth, homogeneous, yellowish-white, firm yet elastic surface.

Blocks of tissue taken from this column of solid tissue were fixed, infiltrated, blocked, cut, mounted, and stained according to approved laboratory methods.

CYSTIC SARCOMA ORBIT—HANSELL.

Microscopically these sections are marginated along one side by a border of lamellated, wavy, fibrous, connective tissue, which form, as it were, a thick capsule. The fibrous tissue is non-nuclear, but here and there in gaps between the lamellæ are numerous nests of red blood cells. The remaining portion of the sections consists of a peculiar reticulum-like formation of stellate cells with long branching and anastomising filaments. These cells possess rather indistinct outlines and large round or oval nuclei, the perinuclear protoplasm appearing rather refractile and staining very indifferently. The anastomosing filaments or processes and their respective cells seem to form numerous, small polyhedral alveoli which contain a refractile, poorly-staining homogeneous, intercellular or ground substance possessing in part the microchemic characters of mucin. In some areas this mucoid ground substance is replaced by a fibrous connective tissue supplemented by a decided increase in the cellular elements. A few areas appear in which a homogeneous poorly-staining nondescript mass of tissue is surrounded by an enclosing band of wavy fibrous tissue containing oval nucleated cells which are most numerous along the inner border of this band. Here and there poorly formed blood vessels are present in cross and longitudinal section containing numerous erythrocytes.

Spreads made from the sediment obtained by centrifugalising the fluid contents of the tumor contain numerous erythrocytes and a number of large peculiarly staining cells resembling in appearance those found and described above as present in the solid portions of the tumor.

Diagnosis. Cystic myxo-sarcoma.

DISCUSSION.

DR. ROBERT SATTLER, Cincinnati. I had a similar case some years ago. I should like to ask Dr. Hansell if in the beginning there was pulsation in this case?

DR. HANSELL. I did not see this boy until he was 13 years old.

DR. SATTLER. In my patient, a lad aged 12, the incipient stage

of the neoplasm was attended by marked pulsation. An exploratory operation revealed the nature of the neoplasm, which in the course of several months assumed similar gigantic proportions as in Dr. Hansell's case. Owing to frequent and excessive hemorrhages the entire mass was removed by the aid of the thermacautery followed by exenteration of the orbit. Patient died from general exhaustion a little short of five months from the first or exploratory operation. The entire base of the brain and cerebellum was converted into a soft gelatinous sarcomatous mass.

CERTAIN CONGENITAL AFFECTIONS OF THE EYE, FOLLOWING STRONG ANTE-NATAL IMPRESSIONS MADE ON THE MOTHER.

BY HASKET DERBY, M.D.,
BOSTON, MASS.

"In spite of all strong-mindedness, based on theory, there lives no woman practically free from the prejudice as to the possibility of an effect from maternal impressions." Thus writes Karl Friedrich Burdach, professor of physiology at Königsberg, during the first half of the nineteenth century.

The belief in the possibliity of a strong maternal impression affecting the unborn child has existed among all peoples and in all ages. If there be any foundation for the hypothesis that a belief universally held has a substratum of truth, the doctrine as to maternal impressions deserves respectful consideration.

The scientific supporters of this doctrine exhibit a halting and somewhat shamefaced advocacy. Its hardheaded opponents, on the other hand, are direct and positive in their denial. I quote from one of them. "Of maternal impressions as a cause for malformations it is hardly worth while to speak. There is no scientific foundation for the belief, and no proof that maternal impressions can have any effect on the development of the embryo."[1]

---

1 Dr. Councilman in Boston Medical & Surgical Journal, Vol. CXXVI, p. 34.

During my professional career there have occurred in my practice a few cases where an impression made on the mother during pregnancy appeared to have influenced the development of the unborn child.

Case 1. Within a few days I have had brought me a child, 6 months old, with slight ptosis on the left side. The mother informed me that the labor had been a normal one, no instruments having been used at the delivery; further, that she had three other children, all with perfectly normal eyes. When this child was born the left eye seemed wholly closed and could not be opened when the other lid was raised. Gradually, as time went on, more and more power was gained over the levator, until at present the ptosis is relatively slight, the lid being raised about four-fifths as high as its fellow of the opposite side. I encouraged the mother to anticipate complete recovery.

To her inquiry as to what could have been the cause of such a state of things, I asked her the usual question. As is well known, it does not do in matters medical to admit one's profound ignorance on any point to the laity, and so I was ready with the inquiry which my old teacher, Carl Braun, always put to the mother who asked him the reason for any special peculiarity in her newly born offspring: "Haben Sie sich versehen?" In other words, "did anything unusual occur to you while you were pregnant?" It now, for the first time, occurred to the lady before me that, some three or four months before her child's birth, an old and very intimate friend of the family had died suddenly and under very distressing circumstances, having been supposed, in fact, to have taken his own life. A marked personal peculiarity of his had been, through life, the drooping of one eyelid, and whenever she thought of him this peculiarity had occurred to her. His death had made a profound impression on her and had often been in her thoughts. He was well on in years when he died, but on being given his name I ascertained that, at the age of 15, he had consulted me for this very difficulty, and I found the case in my records. His left eye had been the seat of a very marked ptosis. No operation or treatment had ever been undertaken.

In connection with this case I would cite an observation made by a man who is characterized as "a very reliable and critical scientific observer." Karl Ernst von Baer (1792-1876), professor in Königsberg and Dorpat, says as follows: "A pregnant woman was much startled and disturbed by the sight of a distant conflagration, inasmuch as she saw it in the direction of her home. In the end it proved that she had been mistaken; but, as the place was seven (German) miles distant, it took some time to get at the actual facts, and this long period of uncertainty may have had quite an effect on the woman's imagination, inasmuch as a long time afterwards she claimed that she still saw the flames before her. Two or three months after the fire she gave birth to a daughter, who had on the forehead a red spot, the apex of which pointed upwards in the form of a flickering flame, this spot lasted till she was seven years old. I relate this case because it is that of my own sister and because she complained of the flame before her eyes during her pregnancy, and did not wait until after her delivery, as is usually the case, to assign a cause for the mark."[2]

These curious coincidences, if such they be, reminded me that my records contained several instances in which malformation or disease of the eye had been found to follow a profound ante-natal impression made on the mother.

Case 2. A child a year old was brought to me with congenital cataract. The mother, who lived in a lonely spot on the Maine seacoast, boarded in the same house with a blind man. Shortly before her baby's birth, her husband being away, this blind man came to her door in the night and tried to force his way in, having evidently mistaken the room. She was greatly frightened and disturbed. There had been no tendency to disease of the eye in her family or that of her husband. The operation on the child's eyes was successful.

Case 3. I saw a young lady of 19, whose right eye was normal in every respect, while the cornea of the left was entirely opaque. This state of things was noticed at birth. At her second

2 Das Versehen der Frauen, by Gerhard von Welsenburg, Leipzig, 1899, p. 108.

visit her mother accompanied her and told me that, when she was four and one-half months pregnant with this child, she was one day watching her children playing together. One of them had a bow and blunt arrow. He fired this at his little brother and hit him just under one eye. The lids immediately closed and there came a gush of tears, which she at first took to be the eye running out. So frightened was she that she nearly swooned. It afterwards proved that the eye was uninjured.

This case seems allied to that which occurred in the practice of Dr. Nevermann in Plau (Mecklenburg-Schwerin). A woman in the first months of pregnancy was approached by a beggar who asked for alms, and took occasion to exhibit to her his left arm, which had been amputated at the elbow joint. She was much frightened, and later gave birth to a girl whose left arm stopped at the same point.[3]

Case 4. A boy, aged 2½ years, was brought me for examination. His right eye diverged, was sightless, and there was a peculiar reflex from the pupil, which proved to be due to a separated retina. As far as could be ascertained this was noticed at birth and had remained unaltered ever since.

Early in her pregnancy the mother, who then lived in California, saw a number of horned cattle being crowded hastily on board a steamer. There was a general mêlée, in the course of which she saw horns broken and eyes knocked out. The impression made on the lady was most painful, and she frequently dwelt on it afterwards.

Case 5. A lady, aged 38, presents a congenital cataract of the left eye. Previous to her birth her mother, for the first time in her life, had a good deal to do with the care of some blind children, with whose condition she felt great sympathy.

Case 6. A lady, two months pregnant, saw some boys engaged in despatching a horse. They had shot but not killed it, the animal was bleeding, whinnying, and screaming with pain. It ran around and made for a gate through which she was about to pass. By making a great exertion she ran and got there first,

---

3 von Welsenburg, cited in previous note, p. 149.

passing out before the animal could reach it. She was much alarmed and for a long while dwelt on the circumstance. When the child was born it had a number of small nævi grouped together on its right forearm, also a fine red, hairlike line on the skin near the inner corner of the left eye, just over the internal ligament. This had rapidly increased and now, the child being three months old, formed a nævus, raised and of appreciable size. It was successfully removed.

These cases are given for what they are worth. The writer has simply attempted an accurate presentation of the facts, and draws no deduction from them. They may be a series of singular coincidences. Certainly they are very infrequent of occurrence, these being the only instances met with among upwards of twenty-three thousand recorded cases, embracing, of course, many forms of congenital disease.

Among eleven thousand deliveries Professor von Bischoff noted no single instance of the effect of maternal impressions.[4]

A bitter opponent of the doctrine that an impression made on the mother could affect the unborn child was Jacob August Blondel, a London physician, who wrote in 1727. He cites, among other instances, that of Mary, Queen of Scots, in whose presence her secretary Rizzio was foully assassinated. While the dagger strokes were falling the victim clasped her knees and implored grace. The excitement of the Queen was, of course, indescribable. She was then pregnant with James the First of England, who is said to have shown absolutely no abnormality. Blondel claims that here, if ever, an effect ought to have been produced on the child.[5] He leaves out of sight, however, the fact that James could never bear to look on a drawn sword, a circumstance well brought out by Scott in the concluding chapter of the "Fortunes of Nigel."

DISCUSSION.

DR. HERMAN KNAPP, New York. I only want to say that in one hundred thousand private patients I have never seen a case that would remotely strengthen this hypothesis.

4 von Welsenburg, p. 154.
5 von Welsenburg, p. 58.

DR. E. E. HOLT, Portland, Me. I reported a case to this Society where a boy about 12 years old was brought to me with no eyes. His mother informed me that he was born without any eyeballs. Inquiry elicited the information that when about three months pregnant a cellar was being dug under the house and her older child came out on a pile of the earth. The workmen, not seeing the child, threw a shovelful of earth into its face. The mother saw this and attributed her child's deformity to that accident, although the older child did not lose its sight.

DR. WALTER L. PYLE, Philadelphia. In the preparation of a work on the "Anomalies and Curiosities of Medicine," I had occasion to examine nearly all the medical records of maternal impressions from the time of Hippocrates down and I failed to find any scientific evidence of this hypothesis at all. It is usually possible to suggest to the mother some incident that will be readily accepted as accounting for a deformity.

DR. LUCIEN HOWE, Buffalo. A point that may be worth mentioning in this connection is the negative evidence which we can obtain by examining the inmates of blind asylums. There we are apt to find two or more of the same family blind from the same condition. Our only explanation, therefore, would be that if these conditions are due to maternal impressions, the mother must have had the same impression before the birth of each child.

LESION OF THE CHORIOID DUE TO INTESTINAL INFLAMMATION FROM PTOMAINE POISONING.

BY CHARLES STEDMAN BULL, A.M., M.D.,
NEW YORK, N. Y.

It is a well-known fact that certain ocular symptoms and lesions can be caused by intestinal intoxication, but our knowledge on the subject is scanty, and ophthalmic literature contains comparatively few well-authenticated cases of lesions of the deeper tissues of the eye due to auto-intoxication. Physiological chemists agree that intestinal poisoning from ptomaines presents a sort of transition to acute infectious diseases. The ordinary ptomaine poisoning is due to the presence of toxic substances produced by

microbes from articles of food, though there may not at the time be present any decided phenomena of decomposition. The toxin thus produced may alone be taken into the system, or the bacteria may be absorbed into the general circulation, increase and give rise to toxic products, or both these conditions may prevail. In the first event we have to deal with a case of acute poisoning, characterized not infrequently by a general cutaneous eruption of urticaria or pemphigus, and this condition is produced when the microbes cannot develope any further, or when they have been destroyed by cooking. In the second event a more or less acute infectious disorder developes.

According to Kniess, the toxic products of the disassimilation of food vary greatly in character, and certain of them, it is well known, have a specific effect on the eye. For instance, muscarine and neurine cause myosis and spasm of accommodation, while tyrotoxine causes mydriasis and paralysis of accommodation.

The commoner general symptoms of intestinal intoxication are dryness in the throat accompanied by a scratchy sensation, difficulty in deglutition, gastritis and an eruption of urticaria or pemphigus. The local ocular symptoms are much less evident. Injection of the ocular conjunctiva is common in ptomaine poisoning. Ptosis and paralysis of the ocular muscles are not infrequent symptoms. These are nuclear in character, and may be due to hemorrhage or to localized basilar meningitis. As a general thing the vision is not impaired, but a number of cases of amblyopia without ophthalmoscopic findings have been reported for which no satisfactory explanation has as yet been offered. These visual disturbances are no doubt due primarily to putrefactive changes occurring in animal tissues, and most of the cases of ptomaine poisoning reported have been due to the ingestion of spoiled fish, meat, milk, or pastry. De Schweinitz is probably correct in regarding many of the ptomaines as basic compounds simulating the vegetable alkaloids, such as conicine, nicotine, atropine, veratrine, curare, and strychnine.

Valude (*Bull. Méd.*, March 23, 1904) thinks that the poisonous affections of the digestive tract may act on the eye, not only

by means of auto-intoxication but also by a generalized asthenia. The chronic intestinal inflammations often end in profound neurasthenia, in which some of the accompanying symptoms are accommodative asthenopia, insufficiency of convergence, retinal fatigue, photophobia, and ophthalmic migraine. He points to the fact that chronic affections of the liver often exert a marked influence on the eye, with the occurrence of such symptoms as conjunctival xerosis, xanthelasma of the lids, and hemeralopia without lesion of the fundus.

In regard to the cutaneous eruptions, accompanying intestinal intoxication, a number of examinations have been made of the contents of the pemphigus bullæ. A diplococcus has been isolated from the bullæ, and this injected into the veins of a rabbit has caused death. The diplococcus removed from this rabbit's blood, and identical with that removed from the pemphigus bullæ, was injected intravenously into a pig and produced a pustular eruption attended by mild constitutional symptoms.

Case I. Miss P., a young girl, aged 14, consulted me in 1903 because she thought she was growing myopic. She had been seriously ill with all the symptoms of ptomaine poisoning, contracted, as was supposed, from eating tainted meat in the form of croquettes. The vomiting and diarrhœa were very severe, and were accompanied by increased temperature, very rapid pulse, and, on the third day, by profound prostration and delirium. Large pemphigoid bullæ appeared on the trunk and extremities, being most numerous on the abdomen and inner surfaces of the thighs. When the delirium passed off she complained of indistinct vision, seeing objects through a fog or mist. Six weeks after the attack of poisoning began she was brought to my office for examination. The complexion was colorless, like old ivory, and the mucous membrane of the lips, mouth, nose, and eyelids was pale. The corneæ were clear, the pupils dilated, the iris immovable, and there was complete paralysis of accommodation. No mydriatic had been employed. There was a myopia of D 2 and an astigmatism of D 1 axis 180°, and under correction the vision was 15/50 in the right eye and 15/30 in the left eye. The

media were clear, and the optic nerves were pale. Scattered all over the fundus of both eyes, but more marked in the right eye, were patches of yellowish-white exudation in the chorioid, of varying size and shape, very flat, with scarcely any elevation above the general fundus. Some were in the stage of efflorescence, and others in the period of retrogression. The retinal vessels crossed them without any change in their direction or in the size of the vessels. The older patches were surrounded by a reddish margin, but there were no pigment masses anywhere in the fundus. On the abdomen and thighs were the remains of some of the pemphigus eruption, and in two or three places the bullæ were still present though much flattened. There was no scotoma in the visual field, and no peripheral limitation. Though there was but little in the ophthalmoscopic picture to suggest syphilis, a careful inquiry was instituted into the early history of the patient, but nothing was elicited which pointed in the slightest degree to congenital syphilis, and there was not the least evidence, after a careful physical examination of the young girl, of any constitutional taint. She was the eldest of four children, all of whom were living and in good health. The mother had never had a miscarriage. The father denied ever having had any form of venereal disease, and there was no evidence to cast doubts on the truth of his statement.

The patient was put upon the use of iron and strychnia, and after the first week arsenic was added, beginning with gr. 1/50 of the red sulphuret and gradually increasing the dose to toleration. Under this treatment the patches of chorioidal exudation began to grow smaller and the vision to improve. At the end of three weeks the paralysis of accommodation disappeared, and in three months the vision in the left eye had improved to 15/15, and in the right eye to 15/20. The patches slowly diminished in size and the outlines became less clearly defined. The cutaneous eruption entirely disappeared, though some discoloration of the skin remained. I last saw the patient in April last, and the vision was then 15/15, with correcting glasses, the pupil and accommodation were normal, and the patient was in perfect health.

Case II. A young lady, aged 27, consulted me in April, 1904. Eight years before I had examined her eyes for the usual symptoms of asthenopia and found, under atropia, a hypermetropia of D 1 and an astigmatism of D 0.25 axis 90°. Adduction and abduction were normal, and the vision was 15/10 with correcting glasses. The media were clear, and the fundus of both eyes was normal. The correction of the refractive error relieved all her symptoms, and I did not see her again until April 26, 1904. About two months before I saw her, she had been taken ill with symptoms of intestinal poisoning, and the nausea and diarrhea were very severe, and were attributed to poisoning from impure food. She complained of black spots before her eyes, dimness of vision and vertigo. Accompanying the gastric symptoms was a general eruption all over the body of large bullæ, raised considerably above the surface, most marked on the abdomen, and inner surface of the thighs and forearms, which was evidently a pemphigoid eruption. On reaching Rome her vision was very much impaired and she consulted Parisotti, who recognized in each eye a chorioiditis in the stage of efflorescence. He advised her immediate return to her home and I saw her on April 26th. Vision was then 15/30 in each eye, and there was complete paralysis of accommodation and mydriasis, though no mydriatic had been used. The corneæ were clear, but there were faint peripheral striæ of opacity in both lenses. There were numerous flat patches of exudative chorioiditis, with little or no elevation, all over the fundus. These patches varied in size and shape, all were surrounded by a red margin, but there was no pigmentary ring around the patches. The retina did not seem to be involved, and there was no unusual engorgement of the vessels. There was no scotoma in the visual field. On the chest, upper arms, and back were the remains of an undoubted pemphigoid eruption. She stated that her vision had decidedly improved. The most recent patches of exudation were around the posterior pole in each eye.

A rigid cross-examination of the patient and also of an old attendant of the family gave not the slightest evidence of any specific disease, either congenital or acquired, nor was I able to

discover any evidence of it in the family. The ophthalmoscopic picture was very different from that of syphilitic chorio-retinitis, and was unlike any case of chorioiditis that I had ever seen. She was, however, put on mixed treatment at once, including inunction, and a careful examination was made of the blood and urine. The blood showed a marked anæmia, hæmoglobin being only 75, but there was nothing notable in the appearance of the red or white globules. The urine had a specific gravity of 1015, there was a trace of albumen and a very few faint hyaline casts. The amount of indican was decidedly increased. In view of the marked anæmia, the mercury was discontinued, and iron was administered, at first combined with arsenic. After three weeks of this medication the iron was stopped, and the arsenic was administered in combination with strychnia. I saw the patient at intervals of a week until July 16th last. At that time the vision of each eye was 15/15, the paralysis of accommodation had entirely disappeared, and she read Jaeger No. 1 fluently. At no time was there any loss of power in any of the extrinsic muscles of the eyes. The opacities of the lens had disappeared in both eyes. A very marked change also had taken place in the fundus. The exudative patches, which had been bright yellow, became pale and the red margin disappeared. They did not shrink in diameter, but became less marked simply from change in color. I last saw the patient on March 4, 1905, and the only evidence remaining were the pale patches in the chorioid, and at the periphery of the fundus these were scarcely perceptible.

THE TREATMENT OF INOPERABLE CASES OF MALIGNANT DISEASE OF THE ORBIT BY THE X-RAY.

BY CHARLES STEDMAN BULL, A.M., M.D.,
NEW YORK, N. Y.

The ophthalmic surgeon has for years been searching for some method of treatment for inoperable cases of malignant

disease of the orbit, or for rapid recurrence of the disease in cases already subjected to operation, which would promise something more certain and satisfactory in permanent results than extirpation by the knife. Hence the claims made during the last few years for the various forms of radio-therapy, including the X-rays in this class of cases, are of great interest to us. The writer has carefully studied the published cases of malignant disease treated by the X-ray method, but he has not been very favorably impressed, partly owing, doubtless, to lack of detail in the histories of many of these reported cases, and some of them, it must be confessed, read like fairy tales.

Walther and Béclère have reported the case of a young man, who, having already undergone several operations for sarcoma of the inferior orbital margin, had recently had a recurrence with lesions so extended that further operation was considered impossible. The patient was then treated by the X-rays, and eighteen sittings, covering a period of four months, sufficed to cause all traces of the neoplasm to disappear.

Professor Berger treated with equal success a very serious recurrence of a sarcoma of the face, which, in spite of the most vigorous surgical intervention, including resection of the superior maxilla and ligation of the external carotid artery, recurred each time with the greatest rapidity. Under treatment by the X-rays, the tumor entirely disappeared.

Many of the cases reported have not contained any detailed account of the exact method employed, of the number of sittings, or of the time of exposure, and many of the reports of cases contain only a few important facts buried in a mass of merely speculative hypothesis.

When any new agent is introduced to medical practice, it is at once grasped with hysterical enthusiasm, and the most extravagant claims for its value are advanced, most of which are never realized, and we have naturally learned to criticize very minutely the reports of results so obtained.

It seems, however, to be an established fact that the X-rays do sometimes exert a marked influence on carcinomatous growths

of a superficial character, causing them to slough away and disappear. It has not been possible up to the present time for us to measure with any accuracy the activity of the radial energy coming from the tube, and hence we cannot determine the dosage.

We all admit that every case of malignant disease of the orbit, which has apparently not originated in or involved the adjacent sinuses, should be extirpated by the knife as speedily as possible; but the consensus of opinion seems now to be that when the neighboring sinuses are involved, a complete removal of the growth is impossible, a recurrence of the tumor is certain to appear, and with each repetition of the operation the return of the disease is hastened, and the life of the patient is by just so much shortened.

On the other hand, in view of what we actually know of the action of the X-rays, it would seem not only wise, but our duty, after such operation by the knife as may be necessary, to expose the parts a certain number of times to the X-rays, in order, if possible, to destroy isolated cells or aggregations of cells in the neighboring parts, which cannot be reached by the knife. It is stated on good authority that there has been a marked diminution in the death rate following operations in patients so treated. Reverting to the primary effect of the X-rays on malignant growths, there seems no doubt that epithelioma and carcinoma yield more readily to their influence than does sarcoma. Many cases are reported as benefited, but few have been completely cured. The tumors have shrunken and grown smaller, but the patient's general condition has not improved. The writer has also seen it stated in print on several occasions that metastasis is more common in cases treated by the X-rays than in those treated by the knife.

The writer's experience, based on his own cases in which this treatment has been employed, has proved that the pain so constantly complained of, has been speedily, sometimes immediately removed, by exposure to the X-rays, and if this is repeated a number of times, the pain does not return. Therefore in inoperable cases, whether from extensive spread of the disease or for other reasons, this method of treatment is to be recommended to patients because it relieves much of their suffering and thus may prolong

their lives. It would seem that the more recent and superficial a malignant growth is, the more rapid and favorable are the results from the X-ray treatment, but it takes time to prove the ultimate good results.

The writer has not himself observed any of the dangers or evil effects of the X-rays, which have been from time to time reported, in any of his own cases, such as infiltration and opacity of the cornea, optic neuritis, conjunctivitis, and cellulitis of the eyelids. Several authors have reported subcutaneous extravasations of blood, and Ehrman has described a telangiectasis appearing as a late result of exposure to the X-rays.

The writer presents the detailed reports of ten cases from his own private practice in which the X-ray treatment was employed after excision by the knife. Of these ten cases two were very much improved if not apparently cured, and of these two, one was an epithelioma and the other a carcinoma. The remaining eight cases, in which no demonstrable effect was produced by the X-rays, were all sarcomata. In the two favorable cases, showing entire disappearance of the growth under the influence of the radio-therapy, the writer did not observe any evidence of the marked cachexia so frequently reported in cases of malignant disease treated by this method. There seems to be but little doubt that the X-rays do act favorably upon superficial carcinomata and that the efficiency of the rays rapidly diminishes with the depth from the surface.

Our knowledge of the subject and of the real extent and nature of these rays is but scanty, and can only be rendered accurate by further experience.

Case I. Myxo-Sarcoma of Orbit. Gentleman, aged 40. Growth involved floor and inner side of left orbit. No apparent involvement of ethmoid cells, nasal meatus, or frontal sinus. Exophthalmos forward and outward. Apparently entire mass of infiltrated orbital tissue removed, leaving eye in place. Orbital plate of ethmoid intact. Relief of all symptoms for fourteen months; then return of growth as small nodule at infero-nasal angle of orbit. Patient refused further operative interference.

Tumor grew very rapidly so that in two months after its reappearance the exophthalmos was extreme and the growth filled the entire orbit and extended down upon the superior maxilla and upwards upon the frontal bone. Complete immobility of eyeball, ulcer and perforation of cornea from total anæsthesia. Constant severe pain which was almost immediately controlled by exposure to the X-ray treatment. In all, twenty-eight applications, beginning with an exposure of ten minutes on alternate days. Cessation of pain after second exposure. After the fifth session, treatment applied only once a week, which sufficed to check the pain, so that patient merely suffered from a slight dull ache in the orbit. No apparent effect produced by the X-rays upon the extension of the growth, which eventually filled the nasal meatus and pharynx. Patient died from exhaustion, eleven months after the reappearance of the tumor, and two years and one month after the first operation.

Case II. Fibro-sarcoma of Periosteum of Orbit and Superior Maxilla and of the Eyelid, without any involvement of the skin. Gentleman, aged 23. Beginning in floor of orbit and of very rapid growth, extending upward and backward in the orbit and outward and forward upon the superior maxilla within six weeks after its first appearance. Eyeball not involved. Operation for removal within two months of its first appearance, the skin of the lower lid and the eyeball being left *in situ*. Growth involved entire floor of orbit, and extended for an inch and a half beyond lower orbital margin upon the superior maxilla. It was not encapsulated, and as the operation progressed it was found that it would have been wiser to remove the entire contents of the orbit, including the periosteum, but to this the patient had not given his consent. After careful irrigation of the cavity, the floor and inner wall of orbit and external surface of maxillary bone were cauterized with the galvano-cautery, and the skin-flaps replaced. Patient made a rapid recovery and he remained free from any sign of return for nearly sixteen months. A nodule then returned at internal canthus and grew very rapidly in all directions and caused intense pain. Patient refused all further interference, but con-

sented to a trial of the X-ray treatment. The exposures were made at intervals of three days for fifteen minutes at a time. After the third application the pain became very much less intense, and the interval between the exposures was gradually increased to seven days. No effect was produced upon the growth of the tumor. The patient died from pneumonia three months after the return of the growth and nineteen months after the operation.

Case III. Probably Sarcoma of the Orbit and Sphenoid and Ethmoid Bones and Nasal Meatus. Lady, aged 45. For twelve months continuous neuralgia in right side of head and face and orbit, starting in upper jaw and extending to right temporal and parietal regions. Progressive exophthalmos, the protrusion being directly forward, with marked limitation in mobility. Exophthalmos resisted all pressure backwards. Accidental discovery of total blindness in the right eye. Pupil dilated and immovable. Fundus normal except for engorged retinal veins. No perception of light. Hard dense infiltration of orbital tissue filling entire orbit, roof, floor, outer and inner walls. Chain of enlarged glands behind angle of jaw and down along sterno-mastoid muscle to level of crico-thyroid region. Patient had had frequent bleeding from nose, and a profuse purulent discharge from right nostril for several months. Superior and middle nasal meatus filled with growth, which bled easily. Patient was told of the grave nature of the lesion, and of the necessity of an extensive radical operation, involving the removal of bone, and the resulting disfigurement, and she declined the operation. She was advised to try the treatment by the Röntgen rays for the relief of the pain, and the possible arrest of the growth. She received the X-ray treatment three times a week, beginning with a sitting of five minutes, and gradually extending the time of exposure to twenty minutes. There was almost immediate diminution of the pain after the first sitting and after the sixth exposure its complete abolition. Little or no effect was produced upon the growth of the tumor, though at times a retardation seemed perceptible. A piece of the growth from the nasal meatus was removed and prepared for examination by the microscope, which showed it to be a small-cell sarcoma.

Patient lived for nine months after I first saw her, and died from what looked like an abdominal metastasis, but no autopsy was allowed.

Case IV. Sarcoma of Orbit, involving the Ethmoid, Lachrymal, Frontal, and Superior Maxillary Bones. Gentleman, aged 72. Painless protrusion of left eye for five months. Eye blind from cataract and fundus invisible. Pain subsequently began deep in the orbit. Eye protruded forward, outward, and downward, and was pushed to extreme outer canthus. At inner canthus could be seen a tumor, which was hard, elastic, and resisting; in bulk larger than the eyeball, with smooth surface and firm attachment to periosteum of roof and inner wall of orbit. Tumor was not sensitive, but when pressed backwards caused severe pain at apex of orbit. Nasal meatus and pharynx apparently healthy. In view of the age of the patient I declined to operate, but advised him, if the pain became severe, to try the treatment by the X-ray. This he did, but without any effect either in lessening the pain or in retarding the growth of the tumor. He began by an exposure of ten minutes twice a week, and gradually increased the time of exposure to twenty minutes and the sittings to three times a week, having in all twenty-seven sittings. He died from exhaustion at the end of four months.

Case V. Carcinoma of Lid, Orbit, and Eyeball. Gentleman, aged 70. The growth had begun four years before by a small nodule in the lower lid, near internal canthus on right side, and had gradually extended into the orbit along the floor and inner wall, pushing the eyeball upward, outward, and backward. When I saw him the eye was almost buried in the mass of the tumor, which had involved the conjunctiva and cornea, and probably extended into the interior of the globe. The tumor also extend down upon the superior maxilla and outward upon the malar bone. A piece of the growth removed from the inner surface of the lid was examined under the microscope and proved to be a rather vascular carcinoma of slow growth. On account of the age and enfeebled condition of the patient I advised against operation. I suggested a trial of the treatment by the X-ray at his home in a

distant city, and this was carried out very faithfully by his family physician and a local surgeon familiar with the method. Beginning with semi-weekly sittings and five minute exposure, the sittings were increased to three a week and the exposure to twenty minutes and on several occasions to half an hour. The pain was relieved after the third sitting and could always be controlled by a five-minute exposure. In all the patient had thirty-four applications of the X-ray treatment. Not the slightest apparent effect was produced upon the growth of the tumor. The patient died a little over a year after I saw him from exhaustion.

Case VI. A gentleman, aged 56. About a year before I saw him the left eye began to protrude, he being at the time in perfect health. There was no limitation of motility and no pain or discomfort, and the vision was at first unimpaired. The exophthalmos slowly but steadily increased and the vision also failed, and he became conscious of a stiffness in and about the eye. When I saw him the eye protruded downward, forward, and outward, and motility in every direction was almost abolished. The cornea was clear and the iris and pupil were normal. R. E., V. = 20/20; L. E., counts fingers at three feet. The lens was clear and the fundus showed the usual appearances of a papillitis. Palpation revealed a hard, irregularly nodulated growth beneath the superior orbital margin and on the nasal side, which could be traced some distance backward into the orbit. Nothing abnormal was found in the nasal meatus or pharynx. The patient was advised to have the entire contents of the orbit, including the eyeball, removed, and this was done on the next day. After enucleation of the globe the growth was found to fill the apex of the orbit and encroached on the roof and nasal wall as far as the orbital margin. The orbital plate of the ethmoid was gone except for a few fragments and the tumor filled the ethmoidal cells. The entire cavity of the ethmoid was cleaned out and curetted and the periosteum was carefully removed from all the orbital walls. The hemorrhage was somewhat profuse, but was readily controlled, and then the entire orbital surface was cauterized with the actual cautery. The orbit was then packed with iodoform gauze and a firm ban-

dage applied. The healing progressed very rapidly and there was but little suppuration. Nearly three months later the growth reappeared in the ethmoid bone, and after again curetting it thoroughly, I advised the patient to make trial of the X-ray treatment, as I was sure the growth would return. He began the sittings with a five-minute exposure three times a week, and the time of exposure was gradually increased to twenty minutes. After the third sitting there was no more pain, and it never became severe afterwards. The growth returned at the apex of the orbit in less than a month and grew very rapidly in spite of the X-ray treatment. In less than two months it had filled the orbit and was extending down upon the cheek and upwards on the forehead. The patient died, apparently from heart failure, not quite eighteen months after the first appearance of the symptoms. The growth proved to be a fibro-sarcoma.

Case VII. Small-Cell Sarcoma of Orbit, Ethmoid Cells, Nasal Meatus, and Maxillary Antrum of very rapid growth. The patient was a lady, aged 39, whom I first saw at my office in consultation. Eight months before the left eye began to protrude and its movements were impeded. There were at times sharp twinges of pain in and about the eye. All the symptoms grew rapidly worse, and vision was lost about two weeks before she consulted me. At the time of her visit the left eye was crowded forward, downward, and outward by a growth which involved the roof, inner wall, and floor of the orbit as far back as the fingers could reach. It also extended beyond the orbital margin in every direction and filled the maxillary antrum, as was proved at the operation. The growth was smooth, hard, and non-sensitive. The lower half of the cornea was opaque and the conjunctiva engorged and chemotic. The left nostril was occluded and the growth showed in the naso-pharynx. The patient was told of the gravity of the case and the impossibility of a radical removal, but she decided to have as much of the tumor excised as possible as a means of relief from the pain. The entire contents of the orbit were removed, including a small portion of the floor which still remained, and the antrum was cleaned out thoroughly. No

attempt was made to remove any portions of bone as all the bones of the face and the sinuses were involved. The patient remained free from pain for not quite two weeks, and then the pain, which was of a burning character, returned in the orbit and cheek. I then advised a trial of the X-ray treatment and she began the sittings with ten-minute exposure, three times a week. After the third sitting the time of exposure was increased to twenty minutes, and the sittings reduced to twice a week. The pain grew less during the second sitting and ceased entirely after the third sitting and never returned in a severe form. The growth began to fill the orbit and antrum again within a month after its removal, and the radio-therapy did not produce the slightest effect upon the rapidity of the recurrence of the tumor.

The patient died from exhaustion and from what I believe to be an hepatic metastasis eight months after the operation. No autopsy could be obtained.

Case VIII. Sarcoma of the Orbit, Ethmoid Cells, Sphenoid Antrum and Naso-pharynx. Young woman, aged 26, in good physical condition, with protrusion of the left eye and greatly impaired vision. The exophthalmos began five months before, and at the same time she had difficulty in breathing through the left nostril. The symptoms grew rapidly worse, and two months before I saw her the vision of the left eye began to fail. The exophthalmos was forward and outward, and the motility of the eye was limited in all directions. The growth could be felt on the floor and nasal wall of the orbit, and protruded beyond the orbital margin on the nasal side. The left nostril was occluded, and the growth presented in the posterior nares. There was constant pain and a discharge from the nostril which was bloody and purulent. Vision was reduced to 10/200, and the ophthalmoscope showed a well-marked papillitis with great œdema and numerous hemorrhages. The patient was told that her only chance of relief was a radical operation, and that the tumor had so deeply involved the sinuses of the bones that a complete removal would be impossible. She consented to the operation, and the eye and contents of the orbit were removed with great difficulty two days later. The

orbital plate of the ethmoid was then removed, the ethmoid cells were thoroughly curetted, and a large piece of carious bone was extracted. The middle turbinated bone was removed from the left side, and a large mass of the tumor was curetted from the superior nasal meatus. The growth was found to extend into the sphenoid, which was also curetted and considerable carious bone removed. The maxillary antrum was not involved, and the right eye and orbit were healthy.

The patient made a good recovery and remained free from pain for nearly three months. Then the pain returned in the inner angle of the orbit and root of the nose and the growth soon after made its appearance in the ethmoid. I advised against any further operative interference and suggested a trial of the X-ray treatment. She began with a ten-minute exposure three times a week, and after the fourth sitting the pain disappeared and did not return until after the treatment was given up. She had in all forty sittings extending over a period of four months. The growth seemed to be somewhat retarded, but was not arrested, and gradually the orbit filled up and the nostril became again occluded. She died sixteen months after the operation from what was apparently an abdominal metastasis.

Case IX. Carcinoma of the Eyeball and Orbit. A gentleman, aged 60, complained of a growth on the right eye, which he had first noticed three weeks before I saw him. On the outer aspect of the right eye, in the temporal and infero-temporal region, was a large irregularly nodulated mass, projecting about five millimetres above the surrounding surface, whitish in appearance but highly vascularized, which had already encroached on the temporal margin of the cornea. It was non-sensitive, but bled easily, and was firmly attached to the conjunctiva and underlying sclera. R. E., V.=15/30; L. E., V.=15/15. The patient was told of its malignant character, and was advised to have the eye enucleated. He went away and I did not see him again for a month. When he returned the condition was much worse. The growth had involved the entire outer half of the eyeball, extended into the eye and involved the iris and anterior chamber, and closed the

pupil. He declined all operative interference, and I advised a trial of the X-ray treatment. A piece of the growth was removed for microscopical examination, and proved to be a true carcinoma. This case was the first one of the series which showed any marked improvement from the radio-therapy. The patient had in all twenty-seven sittings, at first on alternate days and afterwards twice a week. The exposures varied from five to twenty minutes. The pain ceased after the first sitting. After the seventh exposure the growth began to flatten and scale off from the exterior. The cornea did not perforate but flattened with the rest of the tumor, and eventually the growth entirely disappeared from the exterior of the eyeball, and the latter became atrophied and flattened, and at the end resembled an eye that had atrophied after a perforating wound or after an irido-cyclitis. This patient has been seen at intervals since the treatment was stopped more than a year ago, and there is still no evidence of a return of the growth.

Case X. Epithelioma of the Nose, Lids, and Orbit. A gentleman, aged 37, presented himself at my office with the following history: About a year before a small lump had appeared on the right side of the bridge of the nose, which soon ulcerated. It extended upward towards the eyebrow and outward to the inner canthus. It first involved the caruncle and then grew into the orbit and involved both eyelids. When I saw him the inner two-thirds of both lids were involved, and their ciliary margins were ulcerated. The conjunctiva oculi on the nasal side was infiltrated, and the growth had extended along the floor and inner wall of the orbit. Vision was normal, the media were clear, and the fundus was normal. The patient complained of a constant dull ache in the orbit and side of the nose, but there was no severe pain at any time. The case was a desperate one, and any operation for the removal of the growth seemed to be contra-indicated, on account of the great extent to which the eyelids and orbital tissue were involved, which would require a very extensive plastic operation afterwards. The patient consented to try what treatment by the X-ray would do, and this was at once begun. The exposures were

on alternate days, beginning with a period of ten minutes, and gradually increasing the time of exposure to twenty minutes. The number of sittings was thirty-four and extended over a period of nearly four months. The dull ache gradually subsided, though there was always a sense of burning in the parts involved. After the sixth exposure there was noticed a change in the appearance of the growth on the nose and in the lids. The swelling disappeared, the parts seemed to flatten out, and the excoriated edges of the lids became covered with a dry scab, which later fell off, leaving a colorless, cicatricial appearance. At the end of the treatment the infiltration of the nose, eyelids, and caruncle seemed to have entirely disappeared, and the infiltration of the orbital tissue had receded and could not be felt by the fingers on the floor of the orbit. Motility of the eye inwards was distinctly limited, but the eye itself remained as it was in the beginning with good vision, clear media, and a normal fundus. This patient has been seen at intervals since the treatment by the X-ray was discontinued and after sixteen months there is no return of the growth.

DISCUSSION.

DR. SAMUEL THEOBALD, Baltimore. I have had very little experience with the X-ray, but one case has recently come under my care which I think is worth mentioning. It was that of a young negro man, about twenty years of age, with marked exophthalmos, not suffering pain, limitation of movements of the eye, decided neuro-retinitis, with engorgement of the veins, etc. A diagnosis of orbital growth was made, and skiographs confirmed the diagnosis, showing that the growth was invading the orbit from region of the apex. Dr. Cushing, one of the surgeons at the Johns Hopkins Hospital, examined the patient and considered it to be a sarcoma, and advised against operation. One of my assistants, who had more faith in the action of the X-ray than I had, undertook to see that the case was treated in that way. I do not know exactly as to the length of exposures, or their frequency, and the case is still under treatment. The result of several weeks' treatment is that the exophthalmos has almost completely disappeared, and the man's condition has greatly improved, so that he has gained seventeen or eighteen pounds. Of course, it is impos-

sible to say what the final outcome will be, but I think the fact that he has thus gained markedly in weight is very significant.

DR. W. B. MARPLE, New York. Last winter I saw a patient who had had an epi-bulbar papilloma removed five or six years ago and at the time I saw him he had an epithelioma which surrounded the limbus of the lower and external portion of the cornea and the latter was more or less opaque and rough. This patient has been under Dr. Dixon's treatment with the X-rays and there has been a decided improvement. He began by applying cocaine and introducing a speculum to allow the rays to reach more of the globe. After a few applications the cornea looked very much like the condition of xerosis. It seemed as though perhaps the use of the cocaine had added to this condition. Whether the rays had anything to do with it I do not know. The growth is very materially lessened and the applications have been made almost every day.

DR. J. H. CLAIBORNE, New York. Seven or eight years ago I saw a patient with epithelioma of the right eye, in consultation. It had affected both lids and a deep ulcer had formed at the canthus. There was also some inflammation of the palpebral conjunctiva. She had 20/20 vision with that eye and a very serious question presented itself. After consulting with Dr. Pooley I decided to remove the eye. I did not cauterize the orbit, but scraped it out thoroughly and did a plastic operation filling up the cavity to a considerable extent so that when healing took place you could just see a slight sulcus where the eye had been. She remained well and free from epithelioma for seven years, but about six or eight months ago she returned with a few epitheliomatous patches on the face that had gone over on the opposite side towards the good eye. I did not operate, but sent her to the Skin and Cancer Hospital and at my suggestion they applied the X-rays three times a week for six or eight weeks with the result that the patches disappeared. It seems to me that in superficial epitheliomata at least we should not forget this means of treatment; I think it is preferable to the use of the knife.

DR. E. E. JACK, Boston. It seems strange that there exist so many different experiences with regard to this subject. One of the surgeons of the Massachusetts General Hospital, who has operated on many cases of epithelioma of the lid after they have had X-ray treatment, feels strongly that many are made worse by

the treatment and that others, growing worse in spite of the treatment, lose very valuable time. On the basis of a considerable experience he is much opposed to the X-ray for these cases.

DR. O. F. WADSWORTH, Boston. I have seen a few cases of the superficial epitheliomata treated by the X-rays. The first one I sent for that treatment had the canthus and the conjunctiva involved. It had gone so deeply that removal of the eyeball seemed necessary. The edge of the bone was apparently affected. It was deemed advisable to try the X-rays and certainly there was in the first few weeks a very great improvement, but the man stopped before there was a complete cure. I have seen several such cases benefited, these superficial affections, but I have not any knowledge of complete cure or continued immunity, so that I feel that the knife is better than the X-ray. It is less tedious and I believe is more certain. Certainly I can recall a good many cases where the patients have gone for many years after removal with the knife without any recurrence.

DR. DUNBAR ROY, Atlanta. A very important point brought out in Dr. Bull's paper was that the improvement he got was in cases where there had been no cutting whatever. Would it not be better, if the conservative treatment with the X-ray has such good results, to treat the cases thus without any operative interference? Where the operations had been performed and then the X-rays applied there was no improvement.

DR. HIRAM WOODS, Baltimore. A case occurs to me which illustrates the apparent benefit of the X-ray treatment immediately after operation and without waiting for return. In July, 1903, an old gentleman, 74 years of age, was brought to me from North Carolina by his son, a physician. Black elevations occupied almost the entire surface of the upper conjunctiva, extending to the caruncle. Smaller spots were in the mucosa of the lower lid, and a third mass was on the ocular membrane at the upper and inner limbus. A bit from the upper lid was excised for microscopic examination, and the diagnosis of conjunctival melanotic sarcoma was made by Dr. Hirsch, pathologist at the University of Maryland. I advised exenteration of the orbit; but before acceptance of operation, Dr. Gilchrist, one of our leading dermatologists, was consulted about the use of the X-rays. He advised operation and the immediate use of the rays after all operable portions had been removed. When the lids and globe had been removed, the

deeper orbital structures seemed healthy; and at the request of the patient's son, and really against my own judgment, further operation was not done. The patient went home and was immediately put under treatment with the X-rays under the supervision of Dr. Russell of Charlotte, N. C. This was continued for several months, when Dr. R. found a suspicious spot near inner canthus, about December, '03, and removed it. I saw the patient again in April, '04, in Baltimore, and had Dr. Gilchrist examine him, too. Neither of us could discover any trace of return, and I heard only recently that he had remained free from return — now nearly two years since my operation. Dr. Gilchrist made the statement that the efficacy of the X-ray treatment was greatest when it was instituted immediately after operation, which should include all parts subject to operation. If I followed Dr. Bull's paper correctly, in his cases the X-rays were used only after return.

Dr. Alexander Duane, New York. In cases of carcinoma of the breast I think the treatment generally advised now is to institute and continue the X-ray treatment after excision, and the results of that method, so far as can be judged, are satisfactory. The prognosis is said to be better if X-ray treatment is instituted immediately after operation.

Dr. C. S. Bull, New York (closing). In answer to Dr. Roy's remarks, of the two cases that were cured, during and after the application of the rays, one was operated upon, a very extensive operation, and the X-ray treatment subsequently instituted. The second case which was apparently cured had the rays applied before operation.

I had a double object in presenting this paper to the Society. One was to emphasize, as far as possible, what are, or what should be, absolutely inoperable cases by the knife. And the other was to call attention to the extremely unsatisfactory reports of the vast majority of these cases of malignant disease in which the treatment by means of the X-rays has been applied.

VERNAL CONJUNCTIVITIS IN THE NEGRO.

BY DUNBAR ROY, M.D.,
ATLANTA, GA.

I have been very much interested in the article read by Dr. Posey on "Vernal Conjunctivitis" at the New Orleans meeting of the American Medical Association, and even more so by the various discussions which followed the reading of this most excellent paper. It certainly, more than ever before, made me cognizant of the fact that either the character of such cases differs very materially in different sections of the country or that each observer sees things objectively in a very different manner. I suppose there is no way of ever finding out whether objects appear universally alike to all individuals, unless the same were reproduced again by drawings, and as few among us have this artistic skill we must be content with verbal representations.

The fact that the same type of disease differs in various localities is universally conceded, such being due not only to the elements of what we call climate, but also to the environments and modes of living among the people.

When one from a southern or western city visits the large clinics in New York he sees a distinct type of cases which he never has nor ever will see in his practice at home. Even in my own state these differences are noted. In Atlanta, with an elevation of 1,200 feet and clay soil, the type of eye cases differ from those seen in Savannah where the elevation is low and the soil sandy. The same differences exist between Atlanta and New Orleans. Hence I feel that it is never right to criticise a fellow practitioner because he gives symptoms of supposedly the same disease as quite different from those seen by you in your own locality. Consequently I take it for granted that the wide difference of opinions expressed in the discussion of Dr. Posey's paper was due largely to the fact that the speakers represented different sections of the country.

During the last eight years, in a large out-door clinic at the Atlanta College of Physicians and Surgeons, nine-tenths of whose patients are colored, I have observed ten cases which I have designated and so entered in their histories as circumcorneal hypertrophy of the conjunctiva. In the study of these cases they have been found to represent the so-called vernal catarrh, at least so far as we can find a composite group of symptoms, for one is bewildered at the varied subjective and objective symptoms which he finds described by various observers as representing the type of these cases. In all of my cases they represented the so-called bulbar form. In not a single instance has the palpebral portion of the conjunctiva shown any marked pathological changes. In every case there was a most minute examination of the conjunctiva upon the upper and lower lids and beyond some congestion and redness these surfaces presented a most normal appearance.

Without narrating the history of each individual case, I shall speak of them all under one general group because of the similarity of most of the symptoms both objective and subjective, and only individualize where there were some features distinctly prominent and different from the rest of the group. The prominent fact must be borne in mind that all of these cases occurred among negroes, notwithstanding the fact that we sometimes see the statement made that vernal catarrh does not occur among this race of people, just as the misstatement is also made that this same race is not afflicted with adenoids in the naso-pharynx. The only reason for the existence of these different opinions among southern observers must be due, as I have said before, to the fact that the type of cases differs in different localities.

Age. The youngest in these ten cases was 3 years and the oldest 25, the majority of them being between 6 and 12 years.

Sex. Practically no difference was found on this point, six being males and four females.

Type. The ten cases were all of that form designated as bulbar, and I have never seen in my city a case where the palpebral conjunctiva showed changes similar to those described by other observers.

Symptoms. These were quite characteristic in every case, differing only in the extent of involvement. In only one was this their first attack, all of the remaining having suffered with the disease from two to five years.

The subjective symptoms were by no means prominent, those usually complained of being some photophobia, a heavy feeling, burning and gritty sensation about the lids but in none of them was there any marked discomfort.

The objective symptoms were more characteristic. In those suffering from the first attack there was some congestion of both the bulbar and palpebral conjunctiva with some signs of a catarrhal discharge. The palpebral conjunctiva showed no changes beyond that of congestion. On the ball, at the sclero-corneal margin there was an elevated, circular, waxy, and gelatinous mass, extending from ½ millimetre to even 4 millimetres into the cornea, and which was always widest at the upper and lower margins of the cornea. This latter characteristic was evidently due to the mechanical action of the lids, rubbing back and forth, causing an undue irritation and a further extension of the hyperplasia. In one case, a photograph and drawing I show you today, the ring of hyperplasia extended so far on the cornea that there was left only bits of clear cornea about 4 mm. in diameter at the lower left quadrants, so that the patient holds his head to one side in order to see. At that portion of the cornea where the membrane stops there were absolutely no signs of a present or even a former involvement of this structure in inflammation.

Pigmentation at the conjunctival edge of the hyperplasia was by no means infrequent, for pigmentation in the conjunctiva especially in the superficial thickened layers at the inner and outer canthi, is a common occurrence in the negro race.

One peculiarity noted in several of these cases showing this pigmentation was the fact that the pigmentary layer of the skin on both the upper and lower lids, made this region very much darker than the surrounding areas, giving the patient the appearance of dark circles around the eyes. In no other class of cases have I noted this peculiarity in the negro race.

VERNAL CONJUNCTIVITIS.

Where the ring of hyperplasia had extended to any marked degree upon the cornea the eye was cocainized and an attempt made to see whether the gelatinous mass was really a part of the superficial layers of the cornea or only an outgrowth from the conjunctiva and resting upon it as a distinct membrane. In every case it was seen that this hyperplasia was practically a part of the cornea itself and could not be separated from it without cutting or shaving it with an angular keratome. Pieces were in this way removed as deeply as possible and submitted to Professor H. F. Harris for examination. His report is as follows:

" Specimens were fixed in Heidenhain's bichloride of mercury solution. Specimens were embedded in parafin, cut and sections stained with hæmatein, iron-hematoxylin (Heidenhain's), carmalum with picric acid, gentian violet by Van Gieson's method, Unna's alkaline methylene blue differentiated in his fuchsin-tannic acid, and finally carbol-toluidine blue, which proved to be the best solution for staining.

The specimens did not include any of the corneal tissue proper although a portion of the adjoining healthy conjunctiva was embraced in the sections. On microscopic examination, the neighboring healthy epithelial covering of the cornea was found to be normal, but as the diseased region was approached areas were encountered in which many of the epithelial cells of this layer were found to have lost their usual structure; the cells were swollen and their contents consisted of a granular detritus, in which the nuclei may or may not have been more or less preserved, and in addition to this the cells evidently in life contained more or less liquid.

In this area the epithelial layer was in many cases greatly thinned, this being the case to such an extent that it was often not more than one-third of its usual thickness. In the lower layers of this membrane, numerous eosinophile cells were found between the epithelial cells. In this region and also in that covering the lesion pigment cells were not so numerous as in the normal areas.

Projecting down into the deeper tissues there were numerous ingrowths of the surface epithelial layer. At the point where these

connect with the surface membrane, they generally consisted of masses of epithelium that were made up of two to four cells; but as these prolongations extended further downward they terminated into a clubbed extremity which were frequently from 15 to 20 cells across, some of them being as much as 0.175 mm. in diameter.

Beginning a short distance below the point where these pillars originated, there often began a more or less centrally located opening which enlarged as it passed downward and terminated in a rather long central cavity in the bulbous extremity of the projection. Oftentimes these cavities were found entirely empty, but in other instances desquamated cells and granular debris were encountered within them. These cavities were always separated by at least two epithelial cells from the surrounding tissues and ofttimes there were as many as three, four, or five elements intervening.

From the lower surface of the epithelial layer to the extreme limit of these projections there was a distance from 0.125 to 0.225 mm. In their beginning portions, the cells composing these projections resembled in every way the cells of the lower layer of the epithelial membrane of the cornea; but lower down they were more irregular in form and separated from each other by minute interspaces. The cells here resembled very much those in the Malpighian layer of the skin, though as to whether they were united to each other as are these cells, could not be stated with certainty.

Lying within these groups of cells very peculiar bodies were encountered. They were apparently swollen epithelial cells, having a diameter about 0.020 mm., within which there was apparently in life a clear fluid where there was suspended an oval body measuring about 0.010 mm. in diameter and which stained throughout with nuclear dyes and contained towards its center what was apparently a nucleolus. As to the true nature of these bodies nothing can be said with certainty, they were probably the result of cell degeneration, but bore a very close resemblance to some animal parasites.

These projections were limited externally by a layer of very small cells containing spindle-shaped nuclei. Between these epithelial ingrowths and extending between them and the surface layer of epithelium were multitudes of lymphoid and plasma cells and a considerable number of eosinophile cells. In the deeper portions of the specimen there was some newly formed fibrous tissue."

Summary. Principal alterations were: "1. Localized thinning of the surface layer of epithelium, the swelling and vacuolization of many of these elements, the presence of eosinophile cells between these elements.

"2. The projection downward into the deeper structures, club-shaped columns of epithelium containing usually more or less centrally located cavities.

"3. The presence in these cells of peculiar bodies which may be the result of degeneration of these bodies or possibly parasites.

"4. The presence between these columns of enormous numbers of plasma and lymphoid cells, quite a number of eosinophile cells and some newly formed fibrous tissue."

The type of these cases was so characteristic and the results in the treatment so unsatisfactory that one was compelled to recognize them as a distinct entity. The fact that such patients always applied to the clinic during the warm months made me recognize the disease as characteristic of this season. Nor was this affection limited to those with frail constitutions, or to such as presented symptoms of scrofula or hereditary syphilis, but in most cases they were in subjects who appeared healthy in every other respect. In two cases the patients belonged to the same family, but my observations do not lead me to the conclusion that the same is hereditary.

The extent of the circumcorneal lesion varied greatly. In some the gelatinous lymphoid elevation was so slight that it could only be seen by having the light fall upon the eyes at a certain angle, while in others the cornea would be encroached upon to the extent of several millimetres. In those cases where the disease had been periodically present from one to three years and were

seen during the interval, *i. e.* during the winter, the peripheral edges of the cornea showed changes resembling arcus senilis, indicating that the superficial layers of the cornea were also involved in the pathological process. Several cases were seen where the active process had ceased previously and only this latter condition remained; but such cases are not considered in this paper.

At the New Orleans meeting referred to, Dr. Posey's thorough paper on this subject was very freely discussed and very various opinions and observations were there expressed. Dr. Bruns in the discussion said that he had never seen a case of vernal conjunctivitis among the negro race, in which opinion Dr. Claiborne agreed, and that the cases so reported were nothing more than a form of phlyctenular conjunctivitis. In my own clinic I have also recognized the fact that phlyctenular conjunctivitis in various forms was common in the negro race, but the cases here reported were certainly of a very different type and quite similar to cases of the bulbar form of vernal catarrh seen in the European clinics.

Dr. Bruns' argument that such cases as these were phlyctenular, to use his own language, because of "the transient nature of the disease, the readiness with which it seems to yield to simple treatment, the local application of mercury and the internal administration of small doses, together with keeping the conjunctiva clean suffice to bring about a cure in a very short time" is the very reason why his cases do not correspond with those seen by me. My own experience shows that these cases are not transient but have recurred and persisted every year during the warm months; that they have not yielded to simple treatment or even successfully to any treatment, although every method has been tried, and that furthermore, distinct changes can be seen in the periphery of the cornea after the active process has subsided. I believe that these cases are more common than is to be supposed, the trouble being that they are often treated for something else. I have had two cases brought to my clinic, one of which was being treated for granular lids, and the other for a simple conjunctivitis, both having been treated for two years but only during the summer months.

It is almost a matter of impossibility to say in just what pro-

portion of conjunctival diseases cases of vernal catarrh occur among the negro race, for it is a well-known fact that this race of people never consult an eye clinic until the disease has so far involved the eye as to occasion great pain and suffering. Ordinary conjunctivitis is usually allowed to run its course unless it becomes purulent in character and frequently these cases wait until the cornea is already seriously affected. Consequently I am in no position to affirm or deny Posey's estimate of one case in every two to five hundred conjunctival diseases. Furthermore, in only two out of the ten cases was this their first attack, for it was only after a persistent recurrence that they could be brought to the point of seeking relief. The few cases seen among the white race showed very much more the signs of inflammatory congestion about the bulbar conjunctiva than that seen among the negroes, consequently the disagreeable subjective symptoms were more pronounced in the former than in the latter. In regard to the treatment, nothing can be added to the long list of remedies proposed and which has been fully mentioned by Posey. Mild applications were used, caustics were tried, and even surgical intervention was resorted to. In three of the worst cases, where the circumcorneal gelatinous mass was the largest, this was shaved off with a knife and afterwards the surface touched with a strong solution of nitrate of silver. This was successful in seeming to arrest the progress of the disease. The use of a mild astringent wash of sulphate of zinc, adrenalin chloride, and water together with the daily massage of the ball with the yellow ointment, the acute symptoms could usually be kept under control until the cool weather would cause a cessation entirely of the acute process.

Under such treatment I found that the severity of the symptoms decreased each season and after three or four years there was very little trouble. Whether the remedies used were responsible for this betterment or that the disease is more or less self-limited and runs its own course, I am unable to say. In the severest forms, *i. e.*, where the ring of hyperplasia is very broad without any marked acute inflammatory congestion, I am fully

convinced that surgical removal of the hyperplasia is the best mode of procedure, to be followed with continuous application of milder remedies.

DISCUSSION.

DR. WALTER L. PYLE, Philadelphia. In my earlier work in the dispensaries of Washington I was impressed with the apparent immunity of the negro to trachoma and the relative frequency with which vernal conjunctivitis occurred. On account of the negro's very white sclera and black iris, the appearance is very characteristic. Although the lesion is at times most formidable in appearance, its course is always one of simple conjunctival hypertrophy, usually near the sclero-corneal junction. The cornea is sometimes involved. The disease is not destructive in nature like trachoma and malignant affections, and tends to disappear without treatment, although recurring the next year. Of course palliative treatment during its course is beneficial. My own observations satisfy me conclusively that the disease does occur in the negro.

DR. HERBERT HARLAN, Baltimore. I concur with both the gentlemen who have spoken. The disease is comparatively common in Baltimore in the negro. One of the first cases I was called upon to see, when a medical student, was a case of vernal catarrh in the negro. One symptom that Dr. Roy did not speak of was the "itching." It is to be remembered that the sensation of burning and smarting may be called "itching" by some people, but this "itching" is very characteristic of the disease.

DR. EMIL GRUENING, New York. I think the microscopic examinations in these cases have been very thoroughly reported. There is a unanimity of opinion now that the condition is due to increase in the elastic tissue of the conjunctiva. In the cases of vernal catarrh that I see in New York the lesion is certainly more frequently limited to the upper lid than to the circumcorneal region. There are elevations which have a mushroom shape because of the pressure. They are hard like cartilage and when removed by the knife grow again in about a week. I have several cases in which during the summer I remove these elevations every week, once a week, and towards autumn they disappear, the conjunctiva becomes smooth again, and there is no further trouble. Last summer I made use of the "pollantine" that was put on the market by Dunbar of Hamburg for hay fever and the improve-

ment of these cases under that treatment is remarkable. It is, however, a very expensive form of treatment, but the relief is so great that the patients use it extensively in spite of its cost. It probably shows a definite relation between this disease and hay fever.

DR. W. C. POSEY, Philadelphia. I am rather surprised that Dr. Roy did not find any changes in the palpebral conjunctiva, as in my observations I found the characteristic whitish thickening of the palpebral conjunctiva in 70 per cent. of cases; 60 per cent. showed granulations in a typical form, but I have never seen the hard, gristly granulations that Dr. Gruening has alluded to in the negro, though I have noted this form, though rarely, in whites. I have recently tried the X-ray treatment in a few cases, with consequent marked lessening of the itching and burning. The granulations, also, became less pronounced.

DR. SAMUEL THEOBALD, Baltimore. I want to add my testimony to what Dr. Roy has said as to the absence of palpebral changes. I have never seen a typical case of *palpebral* vernal catarrh in the negro. The cases, as a rule, have not been very severe, and it is certainly true that some of the cases are not easily differentiated from phlyctenular conjunctivitis.

As to treatment, I have employed, in some cases with excellent effect, a collyrium of bichloride of mercury and sodium chloride. I use 1/16 gr. of the bichloride and 3 to 5 gr. of sodium chloride to the ounce three times a day. The treatment must be kept up for a long time.

DR. C. J. KIPP, Newark. I have recently compared my cases as far back as twenty years ago. These were all cases in which the palpebral form prevailed and in every one of them the excresences had all disappeared. In none of these cases had any operative treatment been resorted to.

VALUE OF THE SO-CALLED HIGH-FREQUENCY CURRENTS IN CERTAIN OCULAR CONDITIONS, WITH ILLUSTRATIVE CASES — PRELIMINARY REPORT.

BY JOHN C. LESTER, M.D.,
BROOKLYN, N. Y.

When one considers the peculiar climatic conditions of Norway, and Scandinavia in general, it is by no means strange that the first to suggest the value of light as a therapeutic agent should be one of her illustrious sons, the late Professor Finsen.

The old Norse Saga of the two sisters, Twilight and Dawn, I think beautifully typifies the position of the profession today in their estimate of the value of different forms of light in the field of therapeutics. Even now we are at Hammerfest in radiotherapy, and a vast field of infinite light beyond is waiting for exploration. The X-ray, N-ray, radium, thorium, and as yet undiscovered actinic energies are destined to be harnessed by a Roentgen, D'Arsonval, Oudin, and Curré abroad; a Tesla, Morton, Abbé, Piffard, Williams, and Pusey in this country; when certain morbid processes now the *bete noir* of the medical profession shall be attacked and overcome.

The so-called high-frequency currents are a form of electric energy or light which are due to an electric current alternating, or oscillating, at the rate of a million or more times per second. Dr. William T. Morton, in 1881, made use of these currents in medical practice. Tesla's experiments with these currents as a form of light followed, and D'Arsonval of Paris subsequently made them practical by the introduction of his high-frequency apparatus. The D'Arsonval-Oudin apparatus (which consists of a high tension spiral coil, an interrupter in the primary current, Leyden jars, and a solenoid plus the Oudin Resonator) has been the one employed by the writer in his treatment of the cases whose histories, with the results of treatment, are given later on in this

article. The induction coil has been universally used in preference to the static machine as a source of electrical energy, because of the higher amperage of the former and consequently the production of more local counter-irritation. Besides, a shorter period of treatment is necessary.

An especially constructed vacuum electrode made by Machlett & Sons of New York city, on lines suggested by the writer, and shown in the accompanying cut, has been universally employed. The vacuum in this electrode is of low degree, the current generated one of three to six milliamperes, length of treatment from one-half to one minute. A larger electrode, made on similar lines, but with the coils having a flat surface instead of a conical surface as in the eye electrode, has been applied to the temporal region. This application has been continued for from three to five minutes, or until there has been a very decided reaction. The brush discharge has not been, as a rule, employed, because of its disagreeable effect on the patient, and the fact that direct contact seemed to be of equal therapeutic value and practically free from pain or discomfort. I have used the monopolar method and have attached the conducting cord directly to the Oudin Resonator in order to increase the potential of the current.

Many and various theories have been advanced as to how these high-frequency currents act. D'Arsonval has shown that under their action there is a more or less pronounced local anæsthesia at the point of penetration; that the arterial tension falls; that the reaction of galvanism and faradism is lessened or lost; that there is a large increase in the respiratory exchanges as well as radiation of heat from the body; that their application to pyogenic bacilli caused them to become discolored and sterile after a short time. Drs. Demoyés and Lagruffoul have shown in experiments on tuberculous guinea pigs that there is an actual inflammatory reaction produced around the pulmonary foci, which subsequently leaves the lung clear of bacilli. In short, it may be stated that there is increased metabolism, producing a decided modification in general and local nutrition.

In this connection the following histories are presented:

Mr. R. E. H. Age 22; moulder by trade; a tall, muscular man, was first seen by the writer on November 1, 1903. He had just been rejected for the police service on account of defective vision in his left eye.

History. When 14 years of age was struck on the left eye with a baseball; was treated at a New York dispensary for some time after injury, but had never recovered his sight. Four years later had attended for some weeks another eye and ear infirmary without result as to vision. On date above mentioned he came under my care. His vision at that time was O. D. 20/10—; O. S. 10/200—, unimproved.

Examination of Eye. Media clear, with exception of vitreous, which was somewhat hazy; disc seemed normal; near and just below the macular region there was slight evidence of an old hemorrhage; otherwise the writer could discover no reason for the loss of vision.

The high-frequency electrode was applied directly to the globe and temporal regions once a week for three months. After two months' treatment (eight applications) vision had improved to 20/200—; this improvement continued and my last record showed vision to be 20/70— in the affected eye. On May 2, 1905, patient called at my request, and upon examination I found his vision practically the same as the last record.

Mr. J. C. J. Aged 18; occupation clerk in the Board of Education, New York city; member of semi-professional baseball club; noticed on baseball field that he had suddenly lost sight of his left eye and was unable to continue playing. After five days the "scum" over left eye not disappearing, he consulted a prominent Brooklyn ophthalmologist, who very kindly furnished the writer with the following history and treatment:

"November 25, 1904, pupil reacts to light stimulation consensually, but not directly; extensive vitreous opacities. Mydriatic used; dilatation of pupil good, but could get no view of fundus details. Vision O. D. 20/20, O. S. 20/100; 'mixed treatment' ordered. December 17th, less haziness of vitreous, opacities less dense. January 13, 1905, vision reduced to 3/200. Febru-

ary 2, no improvement; treatment discontinued." The vision taken on November 25th and December 17th (20/100) the doctor, in an accompanying note, states were probably incorrect.

The patient was first seen by the writer on February 17, 1905. Vision at the time for the left eye was reduced to perception of light. A view of the fundus was totally obscured by large vitreous opacities. Increasing doses of the iodides were ordered and continued for one month without result. On March 10, 1905, the high-frequency vacuum electrode, as illustrated above, was used. These treatments were given twice a week for four weeks, when the patient's vision was taken and found to be 20/20+, or practically normal.

Ophthalmoscopic examination now presented a remarkable change in the entire condition; vitreous opacities had entirely disappeared and a clear view of the fundus could be obtained. Disc and blood vessels were found to be normal, although the veins were somewhat distended and tortuous. Directly below the disc, about a half-disc diameter in distance, there was found a large white atrophic patch, markedly pigmented at its periphery. There were no other evidences of old or recent hemorrhages. The fundus was otherwise normal. In this case there was no history of epistaxis, constipation, or gout. This is a case, probably, of intraocular hemorrhage occurring in young men, which has been described by Eales, Abadie, Hutchinson, and others, for which, thus far, there has been no adequate explanation.

Mrs. A. R. Aged 56. December 21, 1904, was attacked with severe pain in right leg; veins became very large and stood out in knots; leg twice normal size. December 26, 1904, pain left the leg and lodged in the right side of head, causing considerable swelling of the eyelid and completely closing right eye. Family physician pronounced case one of "flying vein," and recommended removal to New York Hospital. The notes on physical examination, kindly furnished by New York Hospital, and of interest to the ophthalmologist, were as follows:

"Right eye closed, cannot be opened; complete paralysis of

ocular muscles; right pupil fixed in mid-contraction; slight tenderness in supra-orbital groove."

Patient left hospital at the end of two weeks physically improved, but ocular conditions were pronounced incurable by the attending physician. She was seen by the writer early in January, 1905, and has been continually under observation and treatment since that time. The conditions found at the first examination were practically those as described above. There was total paralysis of all the external muscles of the eye; the eye was fixed and immobile; lid swollen and absolutely closed; there was, in short, complete ophthalmoplegia externa. The diagnosis seemed to point to embolism following thrombus of the saphenous vein. The usual treatment — increasing doses of the iodides — was given without avail. On or about March 1st the high-frequency electrode was applied directly to the eyelid, temporal and occipital regions, each treatment lasting about five minutes. The strength of current used has varied from three to fifteen milliamperes and treatments have been given, on the average, three times a week. Improvement has been gradual, and at the present writing the patient can fully raise the upper lid and the external muscles of the eye have recovered at least half of their normal power, the patient moving the globe about equally in all directions. Diplopia is now present, and the eye has to be covered when the patient reads or walks.

From these cases and other cases under observation, the writer believes the following conclusions are warranted: That in the so-called high-frequency current we have a valuable therapeutic agent in the treatment of certain ocular conditions; that this treatment is peculiarly efficient in certain cases of vitreous opacities, which, heretofore, have been the despair of the ophthalmologist and his patient; that it is also valuable in paralysis of the external muscles of the eye, due to central lesions; that this action is both local and constitutional, and that it is probably due to the stress of the ions on cellular protoplasm.

Finally. In therapeutic discoveries, as in nature, there is a periodicity and antithesis. Macauley, speaking of the Puritans,

said: "They hated bear-baiting, not because it gave pain to the bear, but because it gave pleasure to the spectators." Comets and geniuses shed a weird light in their fitful and evanescent flights, and fashions come back. Whether this phantom light or energy we call the X-ray, and its congenors, shall take a permanent stand as a therapeutic agent, and be really as it is metaphorically "liquid sunshine" to the "lame, the halt, and the blind," only time shall determine.

DISCUSSION.

DR. EMIL GRUENING, New York. I am not convinced of the value of this treatment in these cases. In cases of ophthalmoplegia we know that recovery takes place with or without treatment in many instances. Cases of vitreous opacities clear up also and vision returns. I do not think that these cases are at all convincing, nor that the conclusions are correctly drawn. We should have much better proof to induce us to believe that the high-frequency current will cure these diseases more effectually than time.

TUMORS OF THE CONJUNCTIVA AND CORNEA — REPORT OF TWO CASES.

BY J. MORRISON RAY, M.D.,
LOUISVILLE, KY.,

PATHOLOGIC REPORT BY F. H. VERHOEFF, M.D., BOSTON, MASS.

The apparent want of an accurate description of the primary origin of growths involving the conjunctiva and cornea, associated with a looseness in their pathologic as well as their anatomic classification, calls for a report of such cases. The synonymous use of the terms papilloma, fibroma, granuloma, epithelioma, carcinoma, and even sarcoma, is evident to any one who attempts to investigate the subject in contemporary ophthalmic literature.

Case I. F. G., male, age 68, came to me in July, 1904.

History. He is a large, well-preserved farmer who has enjoyed good health. Two years ago his left eye began to annoy

him, became inflamed and painful. He consulted an eye surgeon, who told him that he had an ulcer on the eye. He remained under treatment for several weeks during which time the ulcer ruptured, following this the pain and inflammation subsided, but he has not seen with the eye, beyond an ability to perceive light. For six months he has been aware that something was growing on the eye, starting at the white spot left by the ulcer. At first it caused irritation by contact with the lids, but for the past two months it has grown so rapidly as to protrude beyond the lids and prevent their closing. There is no acute pain present now, but it has become unsightly and when the eye is moved the growth presses against the edges of the lids and keeps up an irritation and an annoying secretion. Examination shows a white roughened papillary looking mass protruding between the lids, nearly circular in shape, hiding the cornea and overhanging the conjunctiva. Under cocaine anæsthesia I found the growth very friable and confined entirely to the cornea. The base was constricted so that when the edge was raised a ring of corneal tissue was visible all the way around, this ring being slightly broader above and below than on the sides. Enucleation was advised and performed on August 4, 1904. There has been no recurrence.

After removal the growth measured 13 mm. at the widest and 5 mm. at the highest point. The eye was placed in 5 per cent. formalin. Three months later it was frozen and bisected in approximately the horizontal meridian.

The pathologic report is as follows:

The specimen consists of one-half of an eye sectioned in an antero-posterior horizontal plane passing through the optic nerve. Antero-posterior diameter, 25 mm., horizontal, 25 mm. The cornea, 12 mm. in diameter, shows a scar of a perforating ulcer situated a little to the temporal side. Attached to the cornea is a tumor 12 mm. in diameter and 3.5 mm. high, with slightly constricted base, which just reaches the limbus on the temporal side, but otherwise is entirely confined to the cornea. The surface of the tumor is white and presents a distinctly lobulated appearance. The cut surface is white and opaque, showing irregular

TUMOR OF CONJUNCTIVA AND CORNEA — RAY.

sharply defined translucent areas, which evidently correspond to the stroma. There are no hemorrhages or areas of necrosis to be seen. The growth has not broken through the cornea at any point. The iris is closely pressed against the cornea by the lens which is apparently normal. The ciliary body, choroid, retina, and optic nerve also appear to be normal.

On microscopic examination the tumor appears as a thickening of the corneal epithelium with which it is directly continuous. Within the epithelial mass are numerous rounded stroma spaces of variable size containing fibrillated connective tissue, which at the base of the tumor is found to be derived mainly from the corneal scar. The epithelial cells bordering on the stroma, always preserve the type of columnar cells seen in the basal layer of the normal corneal epithelium, and Van Giesen's stain shows that these cells abut on a delicate basement membrane. In no case do the epithelial cells lose their orderly arrangement and infiltrate the stroma. From the stroma spaces peripherally, the epithelium displays the typical structure of normal epidermis except that a keratin layer is occasionally reproduced. The tumor is perhaps best described by comparing it to a simple skin papilloma in which the separate papillæ have to a large extent become fused together and obscured. Definite pearly bodies are nowhere present, but when keratin is produced it is at the periphery of the papillæ as in a simple papilloma. Sections stained in Mallory's phosphotungstic acid hematoxylin, show in certain situations an abundance of the spiral fibrils of Herxheimer as well as the intracellular fibrils of Kronmeyer. This stain also brings out the prickly cells with special distinctness. The tumor shows no areas of hemorrhage or necrosis and no suppuration. The stroma, however, is considerably infiltrated with chronic inflammatory cells, as is also the subconjunctival tissue at the limbus. Karyokinetic figures are unusually numerous.

The cornea on the nasal side is normal, except that the epithelium has been replaced by fibrous connective tissue beneath the tumor. At the site of the old ulcer, however, Bowman's membrane has disappeared and the corneal stroma is largely replaced

by scar tissue, which, as has been stated, continues into and forms the stroma of the tumor. The corneal scar is vascularized principally by vessels from the limbus on the temporal side, although a few vessels superficial to Bowman's membrane reach it from the nasal side also. The iris on the nasal side is not united with the cornea, but is simply held in contact with it. Here the iris stroma is markedly infiltrated with plasma cells, but is otherwise comparatively normal. At the site of the ulcer, however, it has been incorporated into the corneal scar, and is represented simply by a line of pigment. The filtration angle is not occluded on the nasal side, but on the temporal side is completely blocked by the root of the iris. The lens shows beginning cataractous changes at the anterior pole. The ciliary body, choroid, and retina are normal. The optic disc seems slightly hollowed out.

Diagnosis. Papillary epithelioma, arising from a corneal scar.

Remarks. The diagnosis in this case is not easy, since it is difficult to decide whether the growth should be regarded as a simple papilloma or as a malignant tumor. The only real evidence of malignancy the tumor shows histologically is in its rapid growth, which is manifested by the great abundance of karyokinetic figures. This seems sufficient, however, to warrant the view that if left to itself the tumor would have gradually taken on a more and more malignant character. At the beginning such tumors are not highly malignant, so that simple extirpation can safely be tried before resorting to enucleation. In this case it seems reasonably certain that the occurrence of the tumor was dependent upon the corneal ulcer, since it arose exactly at the site of the latter, whereas the favorite seat of such tumors is the limbus. An examination of the specimens in the laboratory of the Massachusetts Charitable Eye and Ear Infirmary shows that this is the most frequent type of epibulbar tumors met with at the limbus.

The history in this case as given by the patient and the condition found at the first examination as well as the microscopical report, places this beyond question as a growth starting in the corneal tissue primarily. In fact at no time did it invade any

other structures. Epibulbar papilloma most often develops from the region of the inner canthus, sometimes from the sclero-corneal limbus. Primary papilloma of the cornea is extremely rare. Parsons says the first true case was that of Gayet in 1879. A few others, about which there is much doubt as to their exact origin, have been reported. Alt, in commenting on the microscopic features of a case reported by Kipp, says, while papilloma of the cornea primarily have been reported it seems hard to prove that they did not take their origin from the conjunctiva. He is of the opinion that the corneal tissue proper never is the origin of such tumors. Parsons is very much of the same opinion. He says it is extremely doubtful if either papilloma or epithelioma is ever truly corneal in origin. He further says that such cases so far reported have all started at the seat of a corneal wound. Fuchs says tumors which develop primarily in the cornea are among the greatest rareties. This statement is also borne out by Weeks.

Case II. P. S., German blacksmith, age 67, came to me first September 6, 1902.

History. When a young man he had been hit in the right eye by a piece of metal that had destroyed the sight. Since that time the eye had given him but little trouble until a few months previous to his visit to me when he found it getting red and inclined to tear, and his attention was attracted to a red mass growing on the eye. On examination I found an eye with occlusion of the pupil and no ability to see objects, on the outer sclero-corneal margin a flat mass of roughened slightly raised tissue that spread up and down, apparently following the limbus, and strongly suggestive of the circumcorneal thickening found in summer trachoma. I ordered for him cocaine and adrenalin drops, and advised him to return to me after the first frost. Early in October he returned. The appearance had not changed appreciably. Under cocaine anæsthesia I excised all the mass possible, scraped the sclero-corneal margin with a sharp curette and applied trichloracetic acid to the area. After the reaction had subsided the place looked well beyond a remaining thickening of the new formed tissue. I saw nothing more of the case until April, 1903,

when he came again with a return of the growth. This time the cornea was involved, a small area of which just in front of the growth was ulcerated. The growth was not thick, but covered considerably more surface than when first seen. It was very friable. With a sharp curette the surface was thoroughly scraped and then the cautery applied over the entire surface. The growth quickly returned after this operation and grew more rapidly. He refused further operative interference. In the spring of 1904 I urged him to have the eye enucleated, but he refused until the mass had become so large that it began to protrude between the lids and had covered the cornea, almost completely, and reached well back toward the cul-de-sac. The growth was much darker in color than when first seen. In November, 1904, he submitted to operation. The eye was removed and the orbit cleaned out except the conjunctiva on the nasal side and the cellular tissue on the inner orbital wall. Now, nearly six months after the operation, there has been no return of the growth.

The pathologic report is as follows:

The specimen consists of one-half of an eye with the optic disc included, which has been sectioned in an antero-posterior horizontal plane. Anterior-posterior diameter of eye 25.5 mm., horizontal 25.5 mm. Fixation in formalin.

Attached to the globe anteriorly there is a large tumor consisting of three distinct nodules united at their bases, which involves almost the entire surface of the cornea, and on the sclera reaches as far back as the equator. The largest nodule is situated on the sclera and measures 12 mm. in diameter and 6 mm. in height. The other two nodules are each about 9 mm. in diameter and 4.5 mm. high, one being situated on the sclera and the other, which has a slightly constricted base, upon the cornea and limbus. The surface of the cornea not occupied by the nodule is covered by a more or less uniform layer of tissue extending from the base of the latter. The surface of the tumor is white to brown in color, the brown discoloration no doubt being due to hemorrhage and to drying. The cut surface in general is not uniform in appearance, but is subdivided in an irregular manner by opaque white strands,

TUMOR OF CONJUNCTIVA AND CORNEA — RAY.

which are separated more or less sharply from one another by a relatively translucent substance. The cut surface also shows a number of hemorrhagic extravasations.

The cornea, 12 mm. in diameter, is not completely broken through anywhere, but at one point the growth has almost entirely replaced it, leaving only a thin layer of corneal stroma. The sclera, on the other hand, seems entirely to have escaped erosion. The anterior chamber is 2 mm. deep and free from coagulum. The filtration angle is open on the nasal side, but on the temporal side it is firmly blocked by the root of the iris, which is attached to Descemet's membrane for a distance of 1.25 mm. Along the line of union there is a thin white layer which splits into two at the point where the iris leaves the cornea, one layer following the cornea and the other the surface of the iris. The ciliary body on the nasal side is stretched forward, apparently by traction of the iris; on the temporal side it appears to be normal. The lens has almost disappeared, only a thin opaque mass containing gritty particles remaining in the capsule. The choroid, retina, optic nerve, and vitreous humor are normal.

Microscopic examination shows the tumor made up essentially of epithelial cells arranged in strands of considerable width. The strands generally take the form of convolutions. The appearance of solid tubules with thick walls is thus often produced in the sections. Here and there within the strands are typical epithelial pearls, composed of concentric laminæ containing keratohyaline granules and surrounded by prickle cells. In some situations areas of comparatively large size have undergone this keratin transformation, producing a picture such as is seen in a cholesteatoma. Sections stained in Mallory's phosphotungstic acid hematoxylin show many of the spiral fibrils of Herxheimer and the intracellular fibrils of Kronmeyer.

The connective tissue stroma of the tumor is derived from the cornea and episcleral tissue, and, except at the base, is very scanty. It consists of delicate fibrillated tissue which is almost everywhere highly œdematous. Frequently it is greatly infiltrated with tumor cells, and in consequence not sharply marked off from the

epithelial strands. The blood vessels which accompany the stroma are few in number, though comparatively large in size. The tumor has no definite capsule, but is bounded superficially by a zone of complete hyaline necrosis, probably due to drying. There are many blood extravasations throughout the tumor. Karyokinetic figures and multinucleated cells are numerous. The body of the tumor is infiltrated to some extent with lymphoid and pus cells, while its edges are infiltrated principally with plasma cells.

The cornea is vascularized throughout, and beneath the tumor nodule is in great part replaced by ordinary fibrous connective tissue, which in places has been invaded by the parenchyma of the tumor. Elsewhere Bowman's membrane is intact, but is covered over either with new connective tissue or lined directly by a thick layer of epithelium extending out laterally from the tumor. Descemet's membrane is intact throughout. No trace of an old penetrating wound is to be seen in any of the sections. Except near the limbus the sclera shows little evidence of invasion by the tumor, although an apparently isolated nest of cells is to be seen just beneath the choroid at the ora serrata. At the limbus the tumor cells have followed along the course of the ciliary vessels, infiltrated the canal of Schlemm, the anterior portion of the ciliary body, and entered the anterior chamber. Here they grow as a thin layer along the line of adhesion between the iris and the cornea. The cells then continue over half the surface of the iris as a thick somewhat uneven layer of stratified squamous epithelium, and over Descemet's membrane as a delicate layer 2-3 cells thick. The endothelium has disappeared beneath the epithelial layers.

The iris is somewhat thinner than normal and is considerably infiltrated with cells indicative of chronic inflammation. The ciliary body is œdematous and its processes are atropic. As already stated on the temporal side the ciliary body has been invaded by the tumor. On the nasal side, where the filtration angle is free, the iris is plainly exerting great traction on the ciliary body and has pulled the ciliary muscle forward and inward. The lens is represented by a thin layer of more or less degenerated cortical

matter enclosed in the capsule. The other structures of the eye show only such changes as are normally found in senile eyes.

Diagnosis. Highly malignant epidermoid carcinoma of cornea and sclera. Invasion of anterior chamber.

Remarks. The tumor in this case is similar to the ordinary epidermoid carcinoma of the skin, and differs from it only in being compelled to grow upon a resistant surface rather than within a tissue. Its malignancy is indicated not only by the invasion of the cornea and anterior chamber, but also by the infiltration of the stroma of the tumor itself. From a histologic standpoint there is nothing to indicate that the tumor arose from the site of an old injury. Moreover, injuries of the cornea are, of course, of great frequency, while epibulbar carcinoma is extremely rare. An interesting feature of this case is the blocking of the filtration angle on the side of the tumor only. In the absence of other evidences of glaucoma this is difficult to explain. Possibly it was due to local circulatory disturbances in the tumor leading to an increased outflow at this point, thus "drawing" the iris against the spaces of Fontana.

The clinical history in this case shows a tumor of the sclerocorneal margin, existing for nearly three years, the greater part of this time the tumor was small and confined to the limbus. In fact, the tissue removed at the two operations was composed of broken down fragments scraped away with a sharp curette. The rapidity of growth did not begin until after the second removal. The probability of this growth being purely papillomatous in its original formation is great since the tendency in papillomatous growths to take on malignancy has been noted by Bilroth and emphasized by numbers of others, this being especially true in those with a history of rapid growth, and those prone to recur after removal. In fact, Johnston, in a study of papillomatous growths of the cornea and conjunctiva could find only 32 cases of papilloma reported in which a reliable microscopic examination had been made. He thinks this due to the fact that sooner or later such growths degenerate into malignant epithelial neoplasms.

A study of these two cases suggests a number of points that

may be emphasized. Both occurred in men late in life. Saemisch, in Graefe-Saemisch's hand-book, says that in 24 cases all but 2 occurred in males. Another interesting fact is that the majority of cases of epithelioma reported have occurred in eyes that have been injured, usually a penetrating wound. In a study of 67 cases Panas locates the origin of the growths as follows:

On	the	temporal	limbus	in 41	cases.
"	"	nasal	"	" 17	"
"	"	lower	"	" 1	"
"	"	upper	"	" 2	"
Not stated				7	"

In 44,719 carefully recorded eye cases at the Massachusetts Eye and Ear Infirmary, 6 cases of epithelioma were observed at the corneal limbus.

I submit that both cases were primarily papillomatous in character. The first occurred in an eye injured by a corneal ulcer and from the scar of the ulcer. It was removed before it degenerated into a more malignant form of growth. The second case should have been enucleated after the first recurrence had the consent of the patient been obtained.

The only clinical appearance which seems to be of value in definitely deciding whether such growths at the limbus are malignant at their inception is the manner in which they invade the corneal tissue. If the growth is intimately incorporated in the corneal tissue with a tendency to ulcerate as it progresses the malignancy of the growth is assured, and, as shown by Lawford, enucleation of the eye is the safest procedure. If on the other hand the growth simply overlies the cornea or is loosely attached to the corneal epithelium, it may safely be excised. If this has been thoroughly accomplished the tendency to recurrence is not great.

Writers seem to differ very much on the question of penetration of these growths into the interior of the eye, this unquestionably being due to different observers having studied histologically different characters of growths. Panas says tumors at the limbus

resist for a long time penetration, this resistance to encroachment on the interior of the globe continuing even after one or more removals of the growth. Adamuk says tumors of the sclero-corneal margin fortunately have very little tendency to penetrate the globe.

On the other hand Fage asserts that while most observers have stated that epitheliomata of the limbus shows no tendency to grow inward, he is convinced that certain forms show this tendency to an extreme degree.

Parsons says epitheliomata at the limbus may penetrate the interior of the globe, when they do so it is along the perivascular and perineural lymph spaces of the corneo-scleral junction, never elsewhere. If, however, the growth is entirely corneal it never penetrates that structure.

A CASE OF HOMONYMOUS, LEFT-SIDED INFERIOR TETARTANOPSIA FOLLOWING TOXIC DOSE OF SALICYLATE OF SODA.

BY J. H. CLAIBORNE, M.D.,

NEW YORK, N. Y.

A large, short-necked gentleman of 57 years of age consulted me in July, 1904, on account of some ill-defined obscuration of vision, which had not been relieved by glasses. His business was matching and comparing cotton samples and he experienced an annoyance in his work which he found some difficulty in describing. His vision for far and near, in both eyes, had been tested by a surgeon, and found to be normal under correction. He had always been a free liver, and two months before I saw him had been on a moderate champagne spree, — a thing in which he was accustomed to indulge periodically.

The spree which immediately antedated the present trouble lasted about a week. Toward the end of it he took a bath, which was followed by some indefinite pains in the top of his head, arm, and leg. They were thought to be rheumatic by his physician,

who gave him salicylate of soda. The dose was large enough to produce physiological, characteristic symptoms of tinnitus; he took as much as eighty grains in twenty-four hours, according to the statement of his medical attendant. Twenty-four hours after commencing the treatment, vision became very misty, and a dark spot appeared toward the left. The salicylate was reduced to one-half the amount, but no clearing of vision resulted. It was then entirely discontinued. Within a week or ten days the vision had cleared gradually, until it was apparently normal, except for the indefinite blur already referred to.

The patient was sent me in consultation by the oculist whom he consulted, and this gentleman wrote me that at the time he first saw him there were normal fields of vision.

He had a compound hyperopic error and presbyopia. His vision with the right eye was 20/20, and the twenty-foot line was read easily and accurately. In the left eye, however, the vision was barely 20/20, and the line was read with apparent uncertainty.

On cross-questioning him closely, I obtained the statement that when the blur came on, it was much denser to the left, that it persisted in that region after the right side had cleared, and that during the general obscuration the darker spot referred to appeared on the left side.

He denied any specific history, and his urine subjected to amorphological and chemical analysis yielded practically normal results. At the time I saw him, the status was as follows:

R. eye=20/20 m+75 D. ⌒ +.25 Dc. ax. 180°.
L. eye=20/20?w.+75 D. ⌒ +.25 Dc. ax. 180°.
+2.75 D. s. ⌒ cyl. as above, for reading.

In each eye the retinal veins were a trifle large, arteries normal, disc normal; the rest of the fundus normal. No external signs; orthophoria, central color perception normal; pupillary reaction normal; left grip weak; left knee-jerk exaggerated; no Rhomboid; no disparity in sensation.

My colleague, who referred this patient to me, wrote that when he saw him just after the illness there was a possible pallor of the discs.

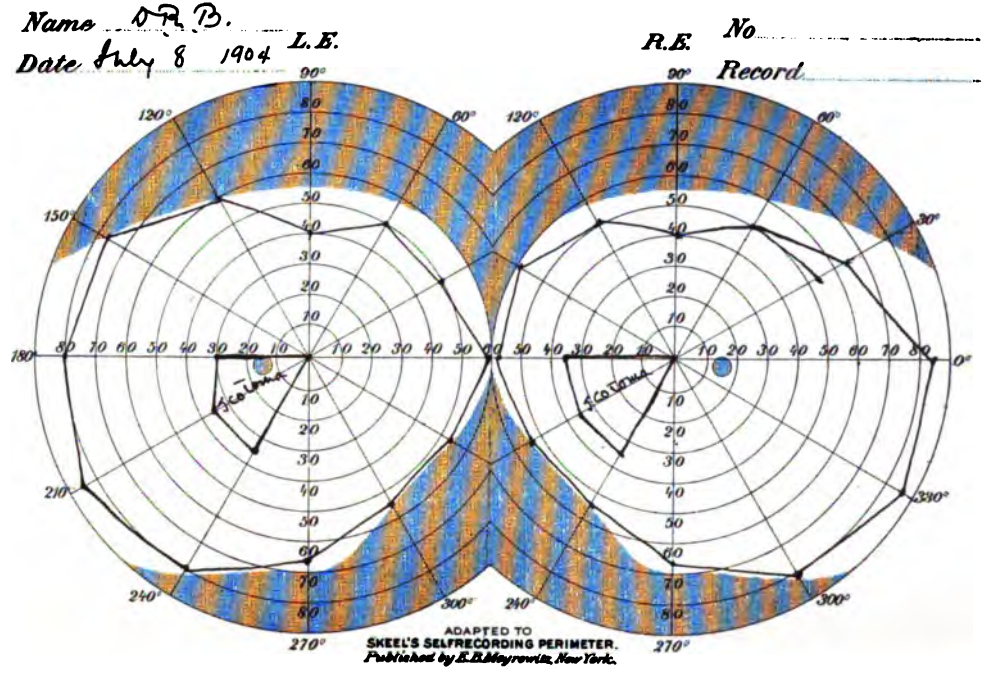

CASE OF TETARTANOPSIS.—CLAIBORNE.

The fields of vision in the two eyes constitute the interest in this case.

It will be observed that the extent of the field for form is about normal, but downward and to the left in each eye, almost mathematically symmetrical, is a scotoma which is absolute, and which represents a triangle. In the right eye the three points marked on the base were at 35° and the sides ran clean and straight to the apex at the center. In the left eye, almost the same thing occurred, only the point in the horizontal plane marking the limit of the scotoma was at 30° instead of 35°. I frequently tested this to see if I was in error, but repeated trials convinced me it was correct. It will be observed, too, that there was vision from the base of the triangle out to the periphery.

This scotoma is consistent with the fact that the obscuration of vision was mainly toward the left, and is probably the dark spot originally observed by the patient. Its position will also account for the fact that the final central vision in the left eye was not so good as in the right.

The fields for red and green are almost, if not quite, as interesting as that for form.

Let us look first at the field for red. In the right eye it is distinctly erratic and irregular. It will be observed that downward and to the left there is wanting a quadrant of 90°. In the left eye the field is still more contracted and erratic, but the temporal limit is naturally greater than the nasal in the right eye. There is here also a quadrantal deficit of 90°, but there is in the blind area along the sector nearest to the vertical, an islet of about 20°, in which red was distinctly recognized. Very careful trial a number of times proved this fact, and likewise the fact that it existed nowhere else in the red-blind area.

The field for green is quite as interesting. Let us look first at the right eye. It will be observed that the green-blind area invades the right half of the field below to the extent of 30°; also the upper half to the extent of 30°, so that this defect is not, strictly speaking, quadrantal.

In the left eye the green-blind area invades the right field,

30° below, but remains at horizontal limit to the left. As in the field for red there was found along the same sector an islet of vision for green. It differed, however, very slightly in length. As has been observed, the central perception for red and green seemed normal. It can be readily understood how this might be in the right eye, but it would appear reasonable that it should be slightly modified in the left eye, even as the central vision for form was, and indeed in all probability it was, but in the nature of things was not sufficiently striking for the patient to make the comparison.

After a comparatively patient and thorough search of the literature of the visual field, I have not been able to find anything like these fields, either for form or colors.

I am acquainted with the fugacious hemianopsic field for colors and also with the fugacious hemianopsic field for form, but I have never before seen a symmetrical form scotoma in a quadrantal scotoma for colors, in which the form scotoma was smaller than the color scotoma. The islets of green and red in the color-blind areas are interesting, particularly in their symmetrical character. I have seen islets for form in blind areas, but never an islet for colors in a color-blind area. It is interesting also to observe the invasion of the right field below by both the red and green-blind area and of the upper and left field by the green-blind area. And yet, it is not unreasonable, at least, in the case of green, since the green sense is less acute than the red, and the field naturally smaller. Similar islets of vision for form are at times found in the blind areas in quinine amaurosis.

I believe this is the first observation that has been made on the color field following salicylate of soda intoxication. The similarity of intoxication by the salicylate to that induced by quinine has been often noted. I, myself, have reported a case in which eighteen grains of quinine produced a transient but typical amaurosis.

As to the contributory intoxication from champagne, it was obvious that the patient was not a regular drinker, but that he occasionally got on "sprees," always from champagne, but never

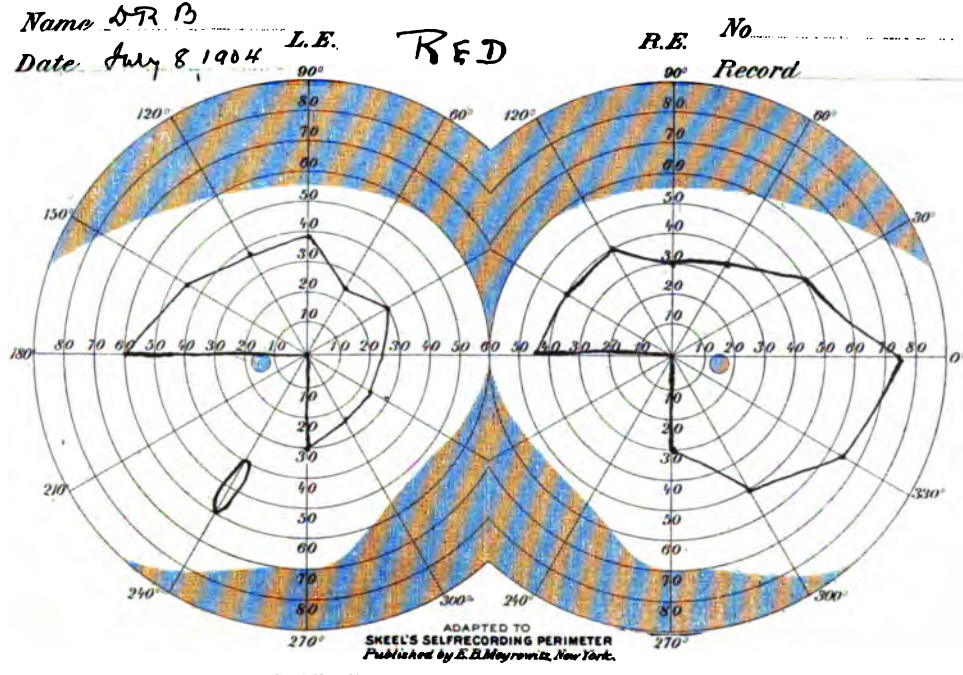

CASE OF TETARTANOPSIS — CLAIBORNE.

drank heavily during them. He was always capable of attending to business during these "sprees," and they never degenerated into a debauch. They were accustomed to last about a week.

I think it can be safely said that while the champagne was a contributory cause, the symptoms were those of salicylate poisoning, and the resultant fields may be cited as the result of it.

De Schweinitz, in "Toxic Amblyopsias," 1896, cites all the cases extant at that time of visual disturbances due to salicylic acid and salicylate of soda. He cites the case of Gatti, published in 1880, of a young girl of 16 years, who took eight grammes in ten hours. At the last dose she fell asleep and awoke entirely blind. The optic discs were normal, but the retinal veins were well filled. These conditions persisted after the restoration of vision, which took place in twenty-four hours after the blindness began.

Earlier than this, Riess, 1875, made the observation that five-gramme doses of salicylate caused tinnitus and disturbances of vision. Knapp, in 1881, in describing quinine blindness, remarked that he had seen three cases presenting precisely analogous symptoms, due to large doses of salicylate of soda.

De Schweinitz has made experiments on dogs with salicylate of soda. In the first experiment he gave a dog sixty grains of soda salicylate, by injection, and on the second day afterward he gave sixty grains of salicylic acid, in the same way. On the second day the dog became partially blind and failed to avoid objects about the room, — slight diminution in size of arteries. On the eighth day the dog was still partially blind; two days later the sight had evidently returned, as the dog no longer avoided objects. In three days more the discs were pale, the arteries distinctly contracted. De Schweinitz thought it probable the peripheric field was contracted.

In experiment No. 2 he injected sixty grains into another; the following day the dog was apparently blind. In several similar experiments partial blindness resulted.

The same author, after his experiments on dogs, concludes that it is possible to produce partial blindness with large doses of

salicylic acid or salicylate of sodium, and that the ophthalmoscopic picture in a minor degree is that produced by quinine.

The only ophthalmic sign in my case, two months after the intoxication, was fullness of the veins. The only sign in the fundus remarked at the time of the intoxication was "a possible pallor of the discs."

A recent communication from the surgeon who first examined this case tells me that he has found the fields, in April of this year, practically the same as I found them twelve months before; the main difference between his result and mine lies in personal equation. He did not, however, find the islets for green and red. The patient writes me he is no longer annoyed by his defect.

Brunner, in discussing the mechanism of quinine blindness, suggests the possibility that the blindness has a cerebral origin, the central ganglia of the cortex of the cerebri being affected, and that the loss of function depends upon circulatory disturbances or inflammatory processes in the cerebral cortex of the visual centers. He finally, however, dismisses this possibility, and accepts ischæmia of the retinæ, the ultimate result being secondary changes and thickening of the vessel walls.

De Schweinitz, in his study of quinine amaurosis, found complete atrophy of the visual path, optic nerve, chiasm, and tracts, as far as they could be traced.

Both Brunner and de Schweinitz admit that the original effect of quinine is upon the vaso-motor centers, and I believe all concur in this view. If this is true, then it is not impossible that there may be an acute endovasculitis or thrombosis at the cerebral centers, and that the degeneration of the retina and the visual paths, in quinine amaurosis, may be partly *descending,* if not entirely so.

Holden, in an experimental study on dogs, concludes that the pathological process, following quinine amaurosis, consists in a constriction of the retinal vessels, particularly of the arteries, followed by an albuminous serous exudation into the nerve fibre layer, and a degeneration of the ganglion cells, together with their axis cylinder processes.

Holden subsequently made other experiments, keeping the dogs

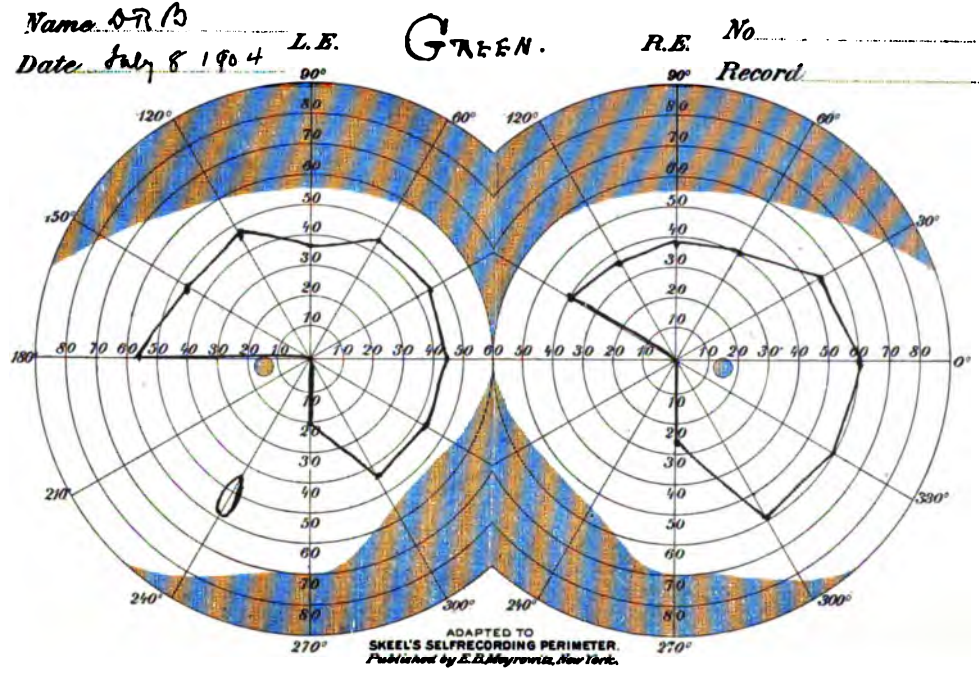

CASE OF TETARTANOPSIS — CLAIBORNE.

for six months, but found nothing more; the degeneration of the nerve fibres proceeded as far as the basal ganglia, but he did not find at any time any cortical changes. He regards the nerve degeneration as distinctly an ascending one. His later experiments are unpublished, and these remarks are based on his statement to me in person.

As far as I knew, no one up to the present has examined the cerebral cortex of any person who has suffered from quinine amaurosis, and until that has been done, the burden of proof must rest upon the pathological findings after experimenting upon the lower animals, and upon the observations of clinical observers.

In Gatti's case 8 grammes (about 120 grains) was taken in ten hours. The girl fell asleep and awoke entirely blind. Gatti explained the result by the direct action of the salicylate of soda upon the retina and optic nerve — clearly an opinion.

Riess observed visual disturbances after 5-gramme doses (about 75 grains. De Schweinitz found visual disturbances in 60-grain doses injected into the dogs. The patient in the present case had about 80 grains in twenty-four hours. A pallor of the discs was observed about that time, and the complete physiological effect of the drug was experienced. Incidentally, the islets of vision for red and green in the blind areas for these colors are consistent with findings in quinine amaurosis; likewise the resultant good vision.

A careful search of the literature bearing on this subject fails to bring to light any observations on the fields in salicylic acid or salicylate of soda intoxication.

Uthoff, than whom there is no greater authority in the toxic amblyopias, remarks that in the matter of the fields, in salicylate toxæmia, scarcely anything definite has appeared.

In Willbrand's masterly exposition of the field of vision, I have not been able to find anything comparable to the fields herewith shown.

In many other papers on quadrantal defects in the field I have found nothing similar. They are apparently unique, in the first place, as quadrantal defects, secondly, as the first carefully

outlined fields which have been observed to follow salicylate intoxication.

The location of the lesion is interesting as a matter of speculation, notwithstanding the elaborate scheme of Henschen. It was probably not subcortical or in the capsule, since there was no history of hemiplegia or hemianæsthesia. The weak grip and the exaggerated knee-jerk on the left, I believe, are entitled to but little consideration. I believe the lesion was in the cuneus, probably the lower portion.

To apply the term *hemianopsia* to fields like these, is obviously incorrect. The proper name is homonymous left-sided, inferior tetartanopsia.

EPITHELIAL CORNEAL CYST.

BY J. HERBERT CLAIBORNE, M.D.,
NEW YORK, N. Y.

A. C., aged 13, was struck in the left eye with a jagged stone three years ago. He remained in a darkened room for six months, when the eye became sufficiently tolerant of light and use to permit of his going to school.

Status Presens. The eyeball is somewhat prominent and macrophthalmic. The cornea has a vertical scar running down the median vertical plane to the lower sclero-corneal margin, and branching above about 2 or 3 mm. from the natural position of the corneal margin into a fork. The iris is firmly attached on either side of the vertical scar to the posterior surface of the cornea, the latter structure being stippled on the nasal side of said scar; on the temporal side the cornea is not stippled, but the iris can be clearly seen in a state of tension from above downward. Springing from about the position of the fork are two translucent cysts, the one smaller than the other, — one lying toward the nose and vertically upward, the other much larger and inclined upward and outward. Between the two there is a slight sulcus, as if the walls of each at this point are merged together and attached to

the underlying tissue. Just below and underneath this point is an oval-shaped opening, apparently through the sclera, from which no reflex can be obtained. The sclera can be clearly seen through the larger cyst, and only partly and imperfectly through the smaller, in which the dark aperture, just mentioned, largely lies. Both cysts have small blood vessels running over them, and one large vessel runs straight down the central scar to the lower edge of the cornea. The larger cyst extends about 8 mm. over the sclera, and the measurement of the two in a horizontal plane was 12 mm.; the measurement of the lesser cyst was therefore about 4 mm., but the exact measurement of this could not with accuracy be obtained, since it slightly ruptured and collapsed when the attempt was made to measure it. There was no reflex from fundus. T. — 2, — light perception, no pain except on studying, no lachrymation, no photophobia, no signs of phthisis bulbi; slight congestion on sclera above the cysts, which increased on use of the eyes. The smaller cyst had been twice punctured with a needle by a physician, but it refilled each time.

The right eye was normal in the matter of sight; there was no irritation of any sort; a slight degree of H. existed, and the fundus was normal.

In view of the fact that light perception alone existed, and that the eye was somewhat irritable on use, I advised enucleation, and this was done without rupturing either of the cysts.

The examination of the eye was made by Dr. E. B. Coburn, and the following is his report:

Examination of the eye of A. C.

Macroscopic. The cornea is somewhat flattened and shows a linear scar extending from the lower corneo-scleral margin to the upper, terminating in a double staphyloma, one at each side of the upper end of the scar, which seems to form a septum between the protuberances. This double staphyloma, considered as a whole, is oval in shape and measures horizontally 9 mm. and vertically 7 mm., of which 3 mm. lies in the cornea, the rest being formed from scleral tissue. On bisecting the eye, the lens appears to be absent. The anterior chamber is shallow, the iris and what

appears to be a cyclitic membrane being drawn forward by anterior synæchiæ. The staphyloma is now seen to be a cavity in the cornea and sclera and as sections were made, the ciliary body was seen to form a portion of the inner wall of the cavity. While, in another part, the inner wall was apparently lacking, the cavity of the staphyloma opening directly into the vitreous chamber. The cavity of one staphyloma which was examined, — the other being reserved for macroscopic demonstration, — is irregularly oval, having various diverticula, so that some sections appear to contain three or more cysts.

Microscopic. The anterior wall of the cyst is thin, contains a small patch of pigment, probably from the prolapsed iris, and is in part formed by corneal tissue and in part by scleral tissue, over which the conjunctiva is quite adherent. The lateral walls of the cyst are formed respectively of cornea and sclera, while the posterior wall is composed in part of these structures, in part by ciliary body and organized cyclitic membrane, and part by irregular spaces which open directly into the vitreous chamber. The cyst is lined on its posterior surface with epithelium, similar to the corneal epithelium, consisting of a cylindrical layer of cells on which are several layers of irregularly-shaped cells, and these in turn, are covered by a layer of flat cells. The intermediate layers decrease in number toward the sides of the cyst, and gradually diminish until only one layer is left, the layer of flat cells which lines nearly the whole anterior surface of the cyst. The various diverticula, which appear like separate cysts in different section are observed to be similarly lined. What was taken for the anterior chamber is really the posterior chamber, as the atrophied iris lies against and is adherent to the posterior surface of the cornea. What appeared to be the iris, are the extended ciliary processes drawn toward the opposite side by the suspensory ligament which is still adherent to the lens capsule. A small portion of the lens is still present contained in a mass composed of the iris, ciliary body, and cyclitic membrane.

Anatomical Diagnosis. Implantation epithelial cyst of the cornea and sclera.

EDWARD B. COBURN, M.D.

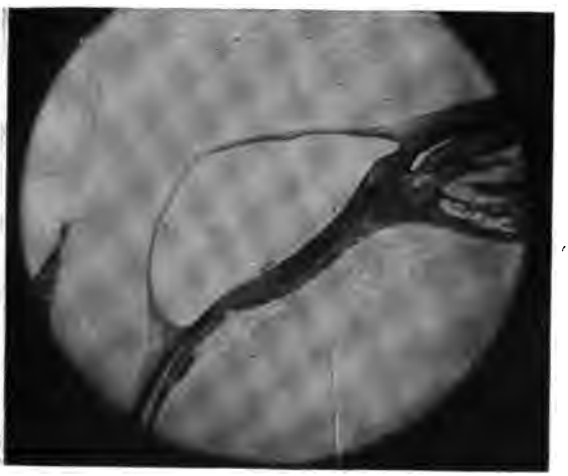

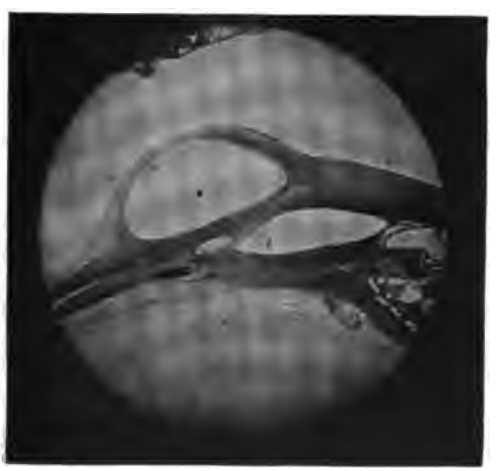

CORNEAL CYST.



3

CLAIBORNE CORNEAL CYST.

When I first saw the eye I made the clinical diagnosis of corneal cyst, and thought it probably the epithelial variety on account of the exceedingly thin cyst walls, and the extensive projection of the cysts on to the sclera. The microscopical examination confirmed the diagnosis. Dr. Coburn does not think it possible to state definitely whether they originate from the cornea or conjunctiva from the sections he has made, and considers it necessary to make sections of the entire eye to decide this point. Of course, until the origin of the cysts can be definitely proved, something will be lacking in the definition of the case. But, after all, the main point is clearly shown, and that is, that the cysts are of the epithelial variety.

Epithelial cysts are so called when their inner walls are lined with epithelium whether the epithelium comes from the cornea or conjunctiva, and the histories of most of such cases apparently show that the conjunctiva is the source of the epithelium. When a wound occurs in the cornea, there is an active proliferation of the epithelium and thus the wound is lined. When the wound heals normally the cavity heals like all normally healing wounds, from the bottom, and the epithelium is gradually pushed up and out. But at times, the wound heals at the top and then the epithelium in the depth is cut off from the surface, and so the cavity is lined with epithelium by proliferation.

When the wound is purely corneal, of course, the epithelium must come from the cornea, but it is when both the sclera and conjunctiva are involved in the wound that the latter plays an important rôle.

In my case, the wound evidently extended into the sclera, as was shown by a scleral cicatrix clearly seen under the larger cyst. The probability is that when the sclera is wounded and the conjunctiva along with it, there is more active proliferation of the conjunctival cells than of the corneal, on account of the greater blood supply in the former than in the latter; and yet, the cornea must furnish its quota likewise when it is wounded, — so that it would seem reasonable to say that epithelial cysts, which exists when cornea, scleral conjunctiva, and sclera are all wounded, are

lined by both conjunctival and corneal epithelium, but that epithelial cysts, arising from corneal wounds alone, are lined by corneal epithelium alone.

Treacher Collins has found epithelial cells in a cornea wounded by gunshot. There were several groups of epithelial cells, some of which were continuous with the surface epithelium.

In another case he found a large cyst in the center of a degenerated cornea, the result of a knife wound.

From these cases he suggests that epithelium may be transplanted into the substance of the cornea by mechanical means, for example, by shot in the first case just mentioned, by the knife-blade in the second. While this is obviously possible, the explanation heretofore given is certainly the more reasonable, and, therefore, the more likely.

Oatman holds this view.

This observer, in the *Archiv. of Ophthal.*, Vol. xxxiii, No. 31, 1904, has described a case of cyst of the cornea of the lymphatic variety. In these cysts the cavity is lined with endothelium, the natural lining of a serous cavity, and the conclusions he draws in regard to the formation of this variety of cyst is strongly at variance with the heretofore accepted views.

The prevailing view is that endothelial corneal cysts are caused by obstruction to the lymph currents, that this causes the canals to dilate and the consequent pressure on the lamellæ causes them to atrophy. In this manner, a cavity is formed. He maintains that the structure of the cornea is sufficiently dense to prevent any great distension of the lymph spaces from obstruction; that the drainage system of the corneal lymph spaces obviates or relieves any local obstruction; that atrophy of the lamellæ always precedes cystic dilatation of the spaces, and that this atrophy is caused by a vitiated lymph produced by pathological changes in the circumcorneal capillary system.

He likewise holds that the irritation of the altered lymph on the connective tissue of the lamellæ probably produces a proliferation of endothelial cells. He holds that cyst formation is there-

MARPLE CASE, PUPILLARY MEMBRANE.

fore rare; degenerated and ectatic corneæ with dilated lymph channels lined with endothelium are more common.

The observation of Oatman, as to the density of the cornea and its consequent ability to resist or prevent dilatation of the lymph spaces, is satisfactory and sound. The rest leaves something to be wished for.

The two principal forms of corneal cysts have been called epithelial and lymphatic. It may be said that the true differential diagnosis lies in the character of the lining of the inner walls, and since the term, "epithelial cyst" has been used to define one, I suggest that the term "endothelial cyst" be used to define the other, instead of the term "lymphatic cyst."

The nomenclature would thus be based upon the histological character of the inner walls of the cyst.

The literature of this subject has been collated by Oatman.

A CASE OF PERSISTENT PUPILLARY MEMBRANE OF RATHER CONSIDERABLE SIZE.

BY WILBUR B. MARPLE, M.D.,
NEW YORK, N. Y.

I wish to present, together with a drawing, the following very brief report of a case of persistent pupillary membrane of the left eye, which was as considerable a fœtal remnant of this character as I have ever seen:

I saw the case in my clinic at the New York Eye and Ear Infirmary in May, 1904. The patient was a little girl, R. B., aged 7½ years, of Jewish parentage. The vision of the right eye was 20/200, and that of the left was 15/200. She was myopic in refraction, but the vision was not susceptible of any practical improvement. In her right eye there was a coloboma of the iris downward, with some persistent pupillary membrane also. In the left eye the persistent pupillary membrane is very much more considerable in amount (see illustration), and, as the latter shows, is attached over the middle of the pupil to the lens capsule. The direction of the fibres of the membrane is from the upper nasal

quadrant of the greater circle of the iris, obliquely downward and outward to the lower outer quadrant. Hirschberg (Centralblatt f. prakt. Augenheilk., April, 1904), reports a very similar case, in which there was likewise a coloboma of the iris and choroid in one eye (the left) and a persistent pupillary membrane in the other. As in his, so also in my case, when the pupil contracted, there was a wrinkling or bending of the filaments composing the membrane, and some of the latter are attached to the lens capsule. Hirschberg says that in the cases seen at birth, or shortly afterward, conspicuous changes are often seen to take place in the course of some weeks or months, while those seen in older children or adults in most cases, remain stationary. He refers to one case which he had had under observation from the second to the twentieth year, in which very much of the membrane disappeared as the years went by. I should think it not improbable that in the case reported here, the membrane might grow much less in time.

A CASE OF DISCOLORATION OF THE CORNEA BY BLOOD PIGMENT, AND ONE OF HEMORRHAGE INTO THE CORNEA.

By O. F. WADSWORTH, A.M., M.D.

Pathological Examination by F. H. Verhoeff, A.M., M.D., Boston.

(Illustrated.)

Discoloration of the cornea by blood pigment appears to be comparatively rare. Indeed, in this country only three cases, so far as I am aware, have been published, and in only one of these was there a microscopic examination. It may be worth while, therefore, to put another case on record.

Aside from its comparative rarity, the condition is of interest because of the various interpretations the deposits in the corneal tissue received before their true nature was determined, because the path by which the pigment finds its way into the cornea is still not definitely settled, and because of its strong resemblance at a certain stage to a lens dislocated into the anterior chamber. Extensive hemorrhage into the anterior chamber appears to be a necessary condition precedent, yet there is a vast difference be-

tween the frequency of hemorrhage into the anterior chamber and the rarity of this condition of the cornea.

The first case reported was one by Baumgarten, in 1883.[1] He found, scattered throughout the substance of the cornea, numerous small, strongly refracting, sharply bordered, colorless, rodlike, oval or round bodies. Although these did not grow on various culture media, did not stain, and the corneal tissues showed no indications of inflammation or degeneration, he was disposed to believe them probably some low organism. Specimens were sent to Leber and Koch. Leber gave no definite opinion as to the nature of the bodies, but was not disposed to accept Baumgarten's conclusion. Koch, on the whole, considered the bodies crystalloid and the remains of an earlier exudation.

Five years later Lawford* reported a second case. He found the granules to stain with eosin, but not with hematoxylin.

Vossius,† in 1889, reported two cases. He concluded there had been direct hemorrhage into the cornea. He demonstrated that some of the deposits in the cornea, which gave an iron reaction, were hemosiderin. Others, and the more numerous, he thought were probably fragments of corneal fibers which had undergone hyalin degeneration. Leber, in an appendix to Vossius' article, upheld the view that these latter granules were the product of fibrin coagulation.

Weeks‡ reported a case in 1893. He supposed the granules in the cornea to be hematin, deposited from soluble hemoglobin which had entered from Fontana's spaces. He said there seemed to be a faint reaction from tests for iron.

In 1895 Treacher Collins§ reported nine new cases, and from consideration of these and those previously published maintained the discoloration to be due mainly to hematoidin granules, hemosiderin being present in some cases also. There was in all hemorrhage into the anterior chamber. He agreed with Weeks that the material probably found its way into the

[1] Arch. f. Ophth., vol. xxix, 3.
* Transactions Ophth. Soc. of the United Kingdom, vol. viii, p. 60.
† Arch. f. Ophth., vol. xxxv, p. 2.
§ Reports of the N. Y. Eye and Ear Infirmary. Part I.
‡ Trans Ophth. Soc. of the United Kingdom, xv.

cornea as soluble hemoglobin. But he thought it more probable that the hemoglobin entered by diffusion through the membrane of Descemet, because the usually increased tension points to obstruction to the exit of fluids at the iris angle, and also because the discoloration appears at the center of the cornea as soon as elsewhere.

Since Collins' papers nothing of importance has been added to our knowledge of the subject. It may be noted, however, that Frank* states that similar granules are also found in trachoma, even where there has been no hemorrhage.

In all cases there seems to have been extensive hemorrhage into the anterior chamber first; in many following a wound, which not always has involved the cornea; in many following late after detachment of the retina or other deep affection, either spontaneous or the result of a blow. The whole cornea appears to be involved at first, but after a few days the periphery clears and complete absorption may take place in some months or after a year or two.

The granules have been found in some cases pretty evenly distributed throughout the whole thickness of the cornea; in some the posterior layers have been free from them, in others they have been most numerous in the posterior layers, and in one case at least they were seen between the membrane of Descemet and the corneal tissue. How the soluble hemoglobin from which they are deposited enters the cornea — through the wound, from Fontana's spaces, or through the membrane of Descemet — is not definitely settled. In many cases a wound surface cannot have offered the path. Collins' idea, that it enters by diffusion through the membrane of Descemet, seems to have met the more general acceptance. The weight of evidence is overwhelmingly against direct hemorrhage into the cornea. The case here to be reported offers no points to aid in the determination of this question.

The color of the opaque cornea has been variously described as grayish-yellow, greenish, greenish-brown, greenish-black, rusty brown, and reddish-brown. And the tint changes with time.

Many observers have spoken of the close resemblance the con-

* Inaug. Diss., Rostock, Jahresbericht, 1902, p. 221.

dition bears to a lens dislocated into the anterior chamber, and the operation has been more than once undertaken for removal of the lens. Lawford said all who had seen his first case had thought it one of dislocation of the lens. This, as will be seen, was the mistake which I made.

Case 1. — *Discoloration of the Cornea by Blood Pigment.* — A boy of 12 was struck by a stick on his right eye. The next day there was ecchymosis of the conjunctiva and a horizontal wound in the cornea, about the junction of the middle and lower thirds, extending nearly to the edge on either side. There was a small prolapse of the iris through the outer third of the wound, some blood in the anterior chamber, apparently opacity of the lens. The prolapsed iris was excised, and also what seemed a bit of vitreous at the inner end of the wound. Atropin. The next day the eye was quiet, the wound closed, the pupil fairly large. The following morning he had considerable pain, relieved by sleep, and on the day after, when I next saw him, the anterior chamber was full of blood. Three days later he had had no more pain, the wound seemed well closed, and he went home.

After a month he returned, having had no pain and used no atropin. There was considerable congestion, not specially deep; the wound region was vascular, forming a band across the cornea 2½ mm. wide, with smooth surface, slightly rounded forward, reddish-gray. Below this band the cornea was grayish. Above it the cornea was smooth and reflected the light regularly. There was a narrow, clear zone some 1½ mm. wide at the periphery, through which the iris could be plainly seen, nearly normal in color and striation. The area within this zone appeared opaque, gray, very slightly tawny, melting below into the opacity of the wound region. Its edge all around above the wound was sharply defined, and with oblique light showed a distinct rounding backward toward the iris. T. slightly —. I believed I had to do with a lens in the anterior chamber and advised its removal.

The eye was not examined again until the boy was under ether. Then there was something in the appearance which led me to doubt whether the opacity was not after all in the cornea. But it seemed better to go on. A section was made at the upper

edge of the cornea. The knife, as it passed through the anterior chamber, would have transfixed a lens lying there. Gentle pressure brought nothing. Iris forceps drew out a bit of iris, which was cut off. A scoop brought only a very small amount of tawny substance, doubtless the remains of blood clot. A small protrusion of vitreous was cut off and the eye bandaged. Four days later the congestion was less, except in the neighborhood of the section. The opacity in the cornea was darker and of a slightly greenish tint. A narrow rim of cornea below the wound had become transparent.

Eighteen days after the operation congestion was somewhat diminished, but photophobia continued. The cornea had gradually become less dark, rather a stretch of imagination being required to call it greenish; the clear edge was a little wider. Under all the conditions existing enucleation seemed advisable and was done.

Pathologic Examination. — The globe was hardened 24 hours in formalin, frozen, and sectioned in a vertical antero-posterior plane. Diameters of globe: Antero-posterior, 25.5 mm.; horizontal, 24 mm.; vertical, 23.5 mm.

The cornea, 12 mm. in diameter, shows two opaque linear scars, 6 mm. apart, running horizontally across it, but ending some distance from the limbus on either side. The upper scar, which is more sharply defined than the lower, corresponds to the incision made at the first operation. Between the scars, but not reaching them anywhere, is a well-defined oval area, 8 mm. by 5.5 mm. in size, stained yellowish-brown. The surface of the cornea is perfectly smooth here and the stroma is not opaque, though less transparent than a normal cornea. Except at the sites of the scars the cornea is elsewhere clear. On the nasal side a few minute, deep-seated vessels approach the lower scar from the limbus.

The iris is caught in the corneal wound and in places is torn away from the ciliary body. The lens is absent and the lens capsule seems to be caught in and stretched between the two scars, leaving a small anterior chamber filled mainly with fluid. The vitreous body is clear, but it is almost completely fluid. The ciliary processes are drawn forward and compressed. At one

place, where a small hemorrhage has taken place from them, they are apparently covered by a slight exudate. On the nasal side the choroid and ciliary body show a white scar about 1 cm. in length. The choroid is otherwise normal, as are also the sclera, retina, and optic nerve.

Histologic Examination.— Celloidin sections were made vertically, taking in the entire cornea and passing through the middle of the discolored area and the scars. Horizontal sections were also made which included sufficient of the cornea to show the margin of the discolored area on the temporal side.

The cornea at the periphery is normal except that above and below the stroma contains a few blood vessels, which make their way toward the corneal scars. The edges of the cataract incision are sharply defined, but are separated from each other by newly-formed cellular fibrous tissue. Posteriorly, the edges are further apart than they are anteriorly, and the scar tissue becomes continuous with a thick fibrous membrane, which is connected with the lens capsule above and with the iris below at the site of the old wound. The latter is filled up with tissue similar to that in the cataract incision, but the line of demarkation between scar tissue and corneal stroma is not so sharply defined. The scar tissue here is continuous with the iris, which has been incarcerated in the wound, and with the fibrous membrane just referred to. The latter thus extends from wound to wound and marks off a shallow anterior chamber. At the margin of the old wound, Descemet's membrane is folded and reflected over the surface of the iris.

Between the two scars, the corneal lamellæ are greatly wrinkled in the anterior three-fourths of the cornea, but there are no new vessels and no formation of new tissue. In the posterior one-fourth, however, the stroma has been replaced by, or converted into, ordinary fibrous connective tissue, which is vascularized by vessels from the scars. Here Descemet's membrane is thrown into numerous folds, many of them quite large, which are filled up with delicate connective tissue.

The discoloration of the central portion of the cornea, seen with the naked eye, is found under the microscope to be due to an enormous deposit of granules, which in unstained specimens are

light yellow in color. These granules fail to give the iron reaction, stain in eosin and in picric acid, but react most intensely to Mallory's phosphotungstic acid hematoxylin, which stains them a dark blue. This later stain seems to be practically differential for the granules, which are evidently hematoidin, as after forma-

FIG. 1. — Enormous deposition of hematoidin particles in corneal stroma and spaces. Case I. Phosphotungstic acid hematoxylin and lithium carmin. Photo. x 105.

lin fixation it colors scarcely anything else except red blood corpuscles, in fact, nothing else for which the granules could be mistaken. The nuclei are brought out by a preliminary staining in Orth's lithium carmin. This method shows that the deposit is in the form of fine and coarse granules resembling various kinds of bacteria, but near the surface of the cornea the particles are especially large and often take the form of small plates, which seem to be composed of parallel rods fused together. The particles occur both within the lamellæ and within the corneal spaces, where they seem always to lie inside the corpuscles. While under the low power the distribution of the particles appears quite uni-

form, under the high power it is seen that there are numerous small, well-defined areas in the affected region which contain almost no deposit. The margin of the deposit is sharply defined, even under the high power. It does not reach either of the corneal scars and near the latter appears no different than in the clear cornea on the temporal side.

Sections stained differentially for iron in potassium ferro- and ferricyanid show relatively little hemosiderin in the discolored area, although almost all of the corneal corpuscles here contain a certain amount of it. There is a noticeable deposition of hemosiderin in the vicinity of Schlemm's canal, but otherwise the clear portion of the cornea is free from it, and there is no pigment of any kind in Bowman's or Descemet's membranes. Within the anterior portion of the ciliary body there is a considerable amount of hemosiderin and some of it is found also bordering on the subchoroidal lymph space throughout the uveal tract, but the retina, including the pigment epithelium and the pars ciliaris, which are most apt to be stained in siderosis bulbi, are free from iron pigment.

The iris has been torn away at its root above. Below, its pupillary margin is caught in the old scar, as already mentioned, and from the latter a thick fibrous membrane grows out over the surface of the iris for some distance. Posteriorly, the iris in places is adherent to the lens capsule. A considerable portion of the iris stroma is comparatively normal, but is infiltrated to some extent with chronic inflammatory cells, among which mast cells are especially numerous. Both the iris and the fibrous membrane with which it is connected show a number of interstitial hemorrhages and contain a large amount of pigment, which gives the iron reaction, and which fails to bleach by the method of Alfieri. This pigment, evidently hemosiderin, becomes less and less abundant as the corneal scars are approached, and clearly has no direct relation to the similar pigment in the discolored area in the cornea. This is all the more certain because the hemosiderin is scattered uniformly throughout the latter area and is no more abundant near the scars than at the margin elsewhere.

All that remains of the lens is its capsule and an insignificant amount of cortical matter inclosed in it. In places the capsular

epithelium has undergone proliferation. Back of the capsule and fibrous membrane there is a small amount of blood, probably resulting from the cataract incision. The hemoglobin is more or less completely dissolved out of many of the corpuscles, while mixed in with them are numerous granules (hematoidin) similar to those in the cornea. The filtration angle is blocked above by the ciliary body, which has been pulled forward over the spaces of Fontana. Below it is free. The ciliary processes are everywhere carried forward; the ciliary muscle is normal. The pars ciliaris retinæ posteriorly has in places undergone proliferation. The choroid, retina, and optic nerve are normal.

Diagnosis.— Old, healed, penetrating wound of cornea, with incarceration of iris. Intraocular hemorrhage. Circumscribed deposit of hematoidin granules in corneal stroma (hematogenous pigmentation of cornea).



FIG 2. — Extensive interstitial hemorrhage into cornea. Case 2. Hermatoxylin and eosin. Photo. x 128.

CASE 2.—*Hemorrhage Into the Cornea.*— This second case

is reported mainly to illustrate the widely different condition existing when there is true hemorrhage into the cornea.

A man of 45 years of age was admitted to the infirmary at the end of last August, with central ulcer of the left cornea and hypopion. A week later, other treatment having proved unsuccessful, the cornea was incised at the lower and outer edge, and the wound was reopened daily for three weeks. The middle of October he was discharged with a large central leucoma.

In January he was readmitted. Three days before, while lifting one end of a piano, external objects suddenly appeared red to him. There was lachrymation of the left eye, but no bleeding. Soon after he began to have pain in eye and temple. On entrance, there was considerable congestion of the conjunctiva, moderate catarrhal secretion. Occupying the center of the cornea was a triangular, bright red area, measuring 6 by 9 mm., with fairly regular outlines. Its surface was uneven, but apparently not broken, the central part slightly elevated. Appearing generally of pretty uniform color, oblique light showed a number of smaller, partly confluent areas of somewhat different degrees of brightness. A number of vessels passed into this area from the limbus, specially from below. The rest of the cornea was hazy, but allowed the iris to be seen. Five days later the lids became red, the conjunctiva more congested, the tension increased, and there was pain severe enough to cause much nausea. Two days later the eye was enucleated.

As the red area had meanwhile continued quite bright, it seemed evident that besides hemorrhage, there were numerous permeable blood vessels in it, although no individual vessels could be made out. This was confirmed by the fact that the area became much less bright on removal of the eye.

Pathological Examination.— The eye was hardened in formalin, and after freezing sectioned in an antero-posterior horizontal plane. The globe is normal in size and shape. The cornea shows a central, somewhat rounded, opacity, 6 mm. in diameter, which is stained unevenly reddish brown. The iris is united with the cornea throughout. The lens is in situ 3 mm. behind the cornea

and the intervening space is free from coagulum. The vitreous humor is normal, as are also the retina, choroid and optic nerve.

Microscopic examination shows that the greater part of the cornea has been replaced by dense fibrous scar tissue in which much of the iris has been incorporated. At the periphery, however, the corneal stroma is comparatively normal, although even here a superficial growth of vascularized connective tissue extends over the surface of the cornea from the limbus to the central scar. The scar tissue is greatly congested and in the center is extensively infiltrated with extravasated blood. The differential stain for iron brings out only a few cells containing hemosiderin and these were no doubt present previous to the hemorrhage. Almost no hematoidin granules are to be made out.

The subconjunctival tissue of the limbus is congested and shows a marked chronic inflammatory reaction. From the posterior part of the ciliary body a considerable exudation of lymphoid cells is taking place and there is also some proliferation of the cells of the pars ciliaris retinæ. The lens is normal and otherwise the eye shows nothing of importance.

Diagnosis.— Large interstitial hemorrhage into corneal scar.

A SERIES OF REVERSIBLE TEST-TYPES ARRANGED ACCORDING TO THE GEOMETRICAL PROGRESSION OF DR. JOHN GREEN.

BY CHARLES H. WILLIAMS, M.D.,
BOSTON, MASS.



a. b. c.

The above cuts show a new series of test-types arranged according to the geometrical progression first proposed by Dr. John Green in a paper read before this Society in 1868, and in another paper read at the International Ophthalmological Congress in London in 1872. A series in geometrical progression was also recommended by Javal at the Thirteenth International Congress

of Medicine at Paris in 1900, and his paper ends as follows: "En effet je ne doute pas qu'avec le temps, les échelles à progression géométrique proposées par Green dès 1868, ne soient universellement adoptées."

The Snellen standard angle of five minutes for the height of the letters and one minute for the width of their different parts and block letters which can be drawn into a square, have been retained in this series, and also the standard for average normal acuteness of vision as expressed by Snellen's formula $v = \frac{d}{D}$. It is desirable to have at least one line of letters which are smaller than Snellen's 5/5, to measure acuteness of vision which may be greater than the average normal of Snellen, therefore in this series such a line for V = 5/4, or 1.25, has been added.

The testing distance being 5 meters, the smallest line of letters in this series subtends the five-minute angle at 4 meters, and the largest line of letters subtends the same angle at a distance of 50 meters.

Taking Green's ratio of $\sqrt[3]{2} = 1.2599$ (approximately 1.26) for the ascending series, and $\sqrt[3]{0.5} = 0.7937$ (approximately 0.8) for the descending series we construct a series of numbers according to the formula $a : x = 1 : 1.26$, a being the known number of the series, and x being the number for the next line, $4 : x = 1 : 1.26 = 5.04$, etc. In this way we get the approximate series 4, 5, 6.3, 8, 10, 12.6, 16, 20, 25.2, 32, 40, 50.

Applying the ratio for the descending series, $50 : x = 1 : 0.8$, we get approximately 50, 40, 32, 25, 20, 16, 12.5, 10, 8, 6.2, 5, 4, which is practically the same as the first series.

Snellen's series is 5, 6, 10, 15, 20, 30, 50, and it will be seen that Green's series preserves most of the Snellen numbers and adds new ones, thus giving a finer measure of the acuteness of vision, with equal intervals between the lines.

The ratio which Javal recommends, but which was first proposed by Green, of $1 : \sqrt{2} = 1.41$, beginning with 3.5, gives the following series 3.5, 5, 7, 10, 14, 20, 28, 39, 55.

In the above figures (a, b, and c) the test types are shown with the largest letters below, but as each line has been engraved

on a separate plate the lines can be arranged for printing with either the largest or the smallest letters at the bottom as desired.

At the *left* of each line is a small red number showing the distance in meters at which the letters subtend the angle of five minutes, and these plates have been carefully engraved so that the printed letters will not vary more than 1/100 of an inch from the required sizes. As the intervals between the lines are equal, these types can be used with equal accuracy at a distance of four or five meters, or at any desired distance, according to the Snellen formula, $V = \frac{d}{D}$, but the best distance is five meters, especially as at this distance the small red figures at the *right* of each line of letters, show in decimal notation the acuteness of vision, and for those who are accustomed to the decimal record this is a convenience.

At a distance of five meters the acuteness of vision for the twelve lines of the test card will be as follows:

5/4, 5/5, 5/6, 5/8, 5/10, 5/13, 5/16, 5/20, 5/25, 5/32, 5/40, 5/50.

Decimal, 1.25, 1.00, .80, .60, .50, .40, .30, .25, .20, .15, .12, .10.

With Snellen's series we get 5/5, 5/6, 5/10, 5/15, 5/20, 5/30, 5/50.

From this it will be seen that the new series of letters preserves very nearly the Snellen series but adds intermediate lines to make the gradation an equal one between each line, and also adds one line smaller than 5/5.

It is important to have the illumination of the test-types constant, so that in comparing the acuteness of vision from month to month, or from year to year, the varying degree of daylight illumination may be replaced by one of more constant power.

In 1866 Dr. H. Derby read a paper before this Society, in which he said: "Let the letters used as a test be placed in a room from which daylight is excluded, and let them be illuminated by a steady flame uniform in intensity of illuminating power and placed always at the same distance from the letters." This is accomplished in my apparatus by a series of frosted incandescent lights arranged in vertical column on each side of the test letters and

completely screened from the eyes of the patient by a blackened tin shield. The letters on my series have been engraved with two lines of test letters, arranged in different order, for each of the twelve distance numbers of the series. For each distance the lines of letters are pasted one on each side of a horizontal slat, which revolves about a horizontal axis in the containing frame, and all these slats are connected by a chain and sprocket wheels, so that all the slats can be reversed together by pulling a string from across the room near the trial case, and a new series of letters can thus be presented to the patient, as is shown in the illustration at the head of this paper. This reversing gear is somewhat expensive, therefore a simpler form of changing the letters was devised by pasting all the lines of letters on a long card, as in the ordinary sets of test types, and on the back of this card pasting the second series, the whole card is then suspended from a simple bracket with an inexpensive device of wood by means of which the whole card can be revolved about its vertical axis by a string, so that either side of the card can be shown to the patient as desired.

SYMPTOMS PRESENTED BY THE DIFFERENT BACTERIOLOGICAL TYPES OF ACUTE CONJUNCTIVITIS.

By A. DUANE, M.D.,

NEW YORK CITY.

The 132 cases here reported all occurred in my service at Cornell University dispensary, and the pathological examinations were made with great care by Dr. T. W. Hastings of the pathological laboratory of that institution.

The cases are unselected and as they comprise the large majority of all cases with secretion which presented themselves during two successive years, they give a fair average picture of conjunctivitis as it occurs in New York City.

It was the purpose of this investigation to ascertain as far as could be done from a comparatively limited number of cases:

(a) The prevailing types of bacterial infection in conjunctivitis;

(b) The relation between the bacteriological types present and the clinical symptoms.

PLAN OF INVESTIGATION.

As each patient presented himself, note was made of the following particulars:—

Age and sex of the patient.

Duration of the trouble.

Condition of lids exteriorly (swelling and injection showing on cutaneous surface).

Condition of palpebral conjunctiva (swelling and injection).

Condition of ocular conjunctiva (injection, chemosis).

Amount and kind of secretion.

Character of corneal involvement, if any.

Unfortunately, in the hurry of dispensary work not all of these details were noted in every case. It is safe to say, however, that in no instance was any involvement of the cornea left

unrecorded, and in general when any serious symptom, such as œdema of the lids, is not noted in the table, it was not present.

Directly after the physical examination and before any treatment was applied, the patient was taken to the laboratory for a bacteriological diagnosis. This was made according to the following routine, the details of which have been furnished by Dr. Hastings.

The initial cultures were prepared by streaking the purulent material with a platinum needle or spatula upon the surface of glycerin-agar plates. No attempt was made to differentiate various strains of streptococci.

Smears of the conjunctival exudate were first examined after staining by Grams' method, controlled with known Gram-negative and Gram-positive organisms, and after staining for capsules by Welch's method or His's 20% copper-sulphate method, when necessary.

The media used for culture varied with the findings in the smears.

For the pyogenic cocci, micrococcus catarrhalis, micrococcus tetragenus, and Koch-Weeks' bacillus, plants were made on glycerin agar and plain agar, and in gelatin. When Gram-positive bacilli, suggesting bacillus xerosis, bacillus diphtheriæ, or bacillus of Morax-Axenfeld were present in the smear, plants were also made on blood-serum media and in plain broth and glucose broth.

In mixed infection with the pneumococcus present, the organisms were differentiated by growth on blood-smeared agar (hæmoglobin media) and in doubtful instances the pneumococcus was isolated by inoculation into mice.

For further transplantation for identifying the various organisms, the ordinary culture media, plain agar, glucose agar, neutral-red agar, plain milk, litmus milk, plain broth, glucose broth, and potato, all faintly alkaline in reaction to litmus, were made use of.

The results thus obtained are shown in the table annexed.

BACTERIOLOGICAL TYPES REPRESENTED.

As will be seen from the table, these cases included the folfowing bacteriological groups:

1. GONOCOCCUS INFECTION. But one case of this type presented, and this an atypical one in a woman of 35 in whom the inflammation had already existed for 4 days. There was only slight discharge and moderate swelling of the palpebral conjunctiva, rather intense general injection of the ocular conjunctiva, and no involvement of the cornea. So far the inflammation was of a mild type, but as an offset to this there was an adherent false membrane on both upper and lower lids. The subsequent history of the case is unknown.

2. INFECTION BY WEEKS' BACILLUS. (*a*) *Pure or Nearly Pure Infection*: There were 10 cases of pure infection. Of these, 5 had profuse muco-purulent or thick purulent discharge and in one of these cases the other symptoms were intense (moderate swelling of the lids, great injection of the ocular conjunctiva with large subconjunctival hæmorrhages, and slight chemosis).*

In addition to these cases of pure infection there were 3 in which the Weeks bacillus was a probable factor (all with slight symptoms) and 8 in which the xerosis bacillus was also present. In the latter group there were 3 cases with profuse discharge; in one of these chemosis was present and in another there were subconjunctival hæmorrhages and marked œdema of the lids.

In none of the 21 cases of this group was there any involvement of the cornea.

(b) *Mixed Infection with Weeks' Bacillus and Staphylococcus Albus.** There were 17 cases. In 10 there was purulent, usually profuse discharge. In 5 cases there was œdema of the lids sometimes quite marked; in 4 cases chemosis and in 3 involvement of the cornea.

(c) *Mixed Infection with Weeks' Bacillus and Staphylococcus Aureus.* 4 cases; discharge profuse in 2; œdema of lids in 1. In all four there was injection of the eyeball; in 2 there was chemosis and in 3 involvement of the cornea.

(d) *Infection with Weeks' Bacillus and Micrococcus Catarrhalis.* 2 cases; one an old trachoma with acute exacerbations;

* Some of these showed also the xerosis bacillus.

the other a type of intense infection with profuse greenish discharge, very intense injection of the eyeball and marginal infiltration of the cornea.

(e) *Infection with Weeks' Bacillus and Bacillus Pneumoniæ of Friedländer.* One case; slight discharge, marked swelling of upper lid which was coated with a diffuse, white, rather tenacious and adherent membrane. In two days this softened and seemed to consist of little more than coagulated mucus. There were probably other organisms present besides the two mentioned.

3. INFECTION WITH STAPHYLOCOCCUS ALBUS. (a) *Pure Infection.* 18 cases. 3 of these were trachoma with acute exacerbation. In 3 others there was a persistent, recurrent, more or less chronic, non-trachomatous inflammation. In 2 of the trachoma cases the discharge was purulent and in one of these was profuse. One case in history and in appearance strongly resembled a spring catarrh, but the histological examination showed typical trachoma granules.

In the 15 cases in which trachoma could be excluded, the discharge was purulent in 6 and profuse in 1; in 2 there was swelling of the lids. In one case there was an ulcer of the conjunctiva outside of the cornea and in 5 cases involvement of the cornea.

(b) *Mixed Infection with Staphylococcus Albus Predominating.* 5 cases, in which the staphylococcus albus was combined with the xerosis bacillus and the micrococcus catarrhalis. The only evidences of undue severity were an ulcer of the conjunctiva in Case 67 and œdema of the lids and rather marked chemosis in Case 69. In Case 69, however, it is probable that another organism, the bacillus pneumoniæ, was present with the staphylococcus and the xerosis bacillus.

4. INFECTION WITH STAPHYLOCOCCUS CITREUS. 3 cases, 2 of which were consecutive to abscess of the lid. In one of these staphylococcus albus also present. No special symptoms.

5. INFECTION WITH STAPHYLOCOCCUS AUREUS. 6 cases; one of pure infection, the others of mixed infection with staphylococcus albus, or with the latter and the bacillus xerosis. One of these was secondary to an abscess of the lids. Of the 5 primary cases, 3 showed involvement of the cornea and one

other a marked injection of the eyeball with punctate hæmorrhages. 3 showed purulent, more or less profuse discharge.

6. STREPTOCOCCUS INFECTION. 2 cases; no special symptoms.

7. PNEUMOCOCCUS INFECTION. 22 cases. Practically all of these were mixed infection, in some cases 5 different organisms being present at the same time.

The prevailing combinations were the pneumococcus and Weeks' bacillus (4 cases), and pneumococcus with staphylococci (11 cases). 5 of the cases were trachoma in a state of acute exacerbation, and in 2 cases (Cases 56 and 90) there was a dacryocystitis.

In the 17 non-trachomatous cases the evidences of pathogenicity were very slight. In only 5 cases was the discharge profuse. In one case (Case 94) the secretion formed a tenacious membrane adherent to the tarsus but this soon cleared up. In this case the only other organism present was the bacillus xerosis. In 3 cases out of the 17 there was involvement of the cornea; in one of these the Weeks' bacillus, in the other 2, staphylococci were associated with the pneumococcus.

It is particularly to be noted that those cases in which four or five different kinds of organisms were present were not particularly severe.

8. INFECTION WITH DIPLOBACILLUS OF MORAX. 5 cases; 3 certain, 2 probable. One was a pure infection; 4 were mixed infection usually with staphylococcus albus. Only one case (No. 104) showed any evidences of virulence.

9. INFECTION WITH XEROSIS BACILLUS. One case of lupus of the conjunctiva with membrane on the lids composed of great masses of xerosis bacillus in almost pure culture. There were also the Weeks' bacillus and staphylococcus albus which were probably responsible for the profuse purulent discharge present in this case. There was no xerosis of the conjunctiva.

10. INFECTION WITH DIPHTHERIA BACILLUS. 2 cases, both with false membrane. One with apparently an associated nasal and pharyngeal diphtheria got well; the other passed from under observation. It is noteworthy that in the former case (Case

109) two brothers and sisters (see Cases 10 and 11) were simultaneously affected, but showed infection with the Weeks' bacillus only, and that all three cases had profuse purulent discharge.

11. UNCERTAIN INFECTION. 10 cases showed the presence of bacteria which, however, could not be certainly identified.

12. FINDINGS NEGATIVE. In 12 cases the bacteriological findings were negative. In 2 of these cases, however, no culture was taken, only smears being examined.

One of these sterile cases was a trachoma with persistently recurring acute exacerbations unchecked by treatment.

Of the other 11 cases there was one with profuse purulent secretion, there were at least 6 with marked injection of the eyeball, 2 cases showed chemosis, and 2 had ulcers of the cornea.

In view of these evidences of intense reaction it is hard to believe that organisms were not present and the fact that they were not discovered in these 12 cases simply affords another proof that our bacteriological diagnosis is not inerrant; at all events that a negative finding is never sufficient evidence of the pathological innocuousness of the conjunctival secretion.

RELATIONS BETWEEN THE CLINICAL SYMPTOMS AND THE BACTERIOLOGICAL TYPES.

Since conjunctivitis represents the reaction produced by the specific action of bacteria, we may inquire how far does the specific variety of bacteria present determine (a) the clinical form of the conjunctivitis and (b) the intensity of the conjunctivitis?

CLINICAL FORMS OF CONJUNCTIVITIS PRODUCED BY DIFFERENT KINDS OF BACTERIA.

Clinically we may distinguish three types of conjunctivitis.

1. The *palpebral* form in which the conjunctiva of the lids is mainly affected.

In severe forms of this type the lids are swollen and œdematous, and the palpebral conjunctiva is swollen and diffusely engorged, and the discharge is profuse and purulent, while the ocular conjunctiva is but slightly reddened.

2. The *ocular* or "pink eye" form in which the conjunctiva of the lids is but slightly affected, the lids themselves are not swollen and the discharge is scanty, but the ocular conjunctiva is diffusely reddened and sometimes chemotic, and not infrequently there are subconjunctival hæmorrhages; punctuate or patchy (hæmorrhagic conjunctivitis).

3. The *mixed* form in which the severe symptoms of both types are combined, that is, the lids are swollen, both palpebral and ocular conjunctiva are intensely injected and engorged, the discharge is or soon becomes profuse and purulent and there are at times subconjunctival hæmorrhages. Sometimes when the reaction is exceptionally severe a false membrane forms on the conjunctiva of the lids.

In a general way we may say that in gonococcus infection the palpebral type of conjunctivitis predominates, although if the infection is at all severe, inflammation of the mixed type is produced.

On the other hand, the ocular type of conjunctivitis—the typical "pink eye"—has been regarded as especially characteristic of the infection by the Weeks bacillus.

It is doubtless true that this form does occur more often with the Weeks' bacillus than with other organisms, but then again the Weeks' bacillus may cause conjunctivitis of a decidedly palpebral type or a mixed conjunctivitis (see cases passim).

On the whole, the more we study these cases the more it appears that *no particular type of conjunctivitis is to be associated with a particular germ, and that we cannot from the clinical aspect of a conjunctivitis draw any positive inference as to the germ causing it.*

One special kind of conjunctivitis deserves mention on account of its great clinical significance, and this is *membranous conjunctivitis.* This is now recognized as expressing merely the reaction of any severe irritant upon the conjunctiva, for example the diphtheria bacillus, the streptococcus, or even a chemical irritant such as silver nitrate when applied too heavily or too often.

In the series under consideration there were 6 cases of membranous conjunctivitis, 2 due to diphtheria bacillus, one to gono-

coccus, one to mixed infection by the bacillus of Weeks and the bacillus pneumoniæ with probably other organisms, one to bacillus pneumoniæ and bacillus xerosis and one apparently to bacillus xerosis alone, since the membrane on the upper lid in this case consisted largely of masses of this organism in pure culture.

The presence of a membrane does not always indicate excessive severity. Thus, one of the diphtheria cases ran a very benign course (perhaps as the result of the early use of antitoxin), and in the case due to the gonococcus the other symptoms were surprisingly mild.

Another form of conjunctivitis that interests us is the *acute inflammation that occurs in the course of a trachoma*. This is of clinical importance because it is likely that it is particularly these acute forms which are responsible for the dissemination of trachoma. The latter in its ordinary chronic state with but little secretion is certainly only slightly contagious, but when through some extraneous infection the conjunctiva becomes acutely involved and discharges freely, a medium is afforded for the transfer not only of the organism directly causing the discharge but of the trachoma organism as well.

13 such cases of trachoma with acute exacerbation were observed in this series as follows:

Weeks' and micrococcus catarrhalis	1
Weeks' and staphylococcus albus	1
Weeks' and micrococcus catarrhalis	1
Staphylococcus albus	3
Pneumococcus and (few) Weeks'	1
Pneumococcus, staphylococcus albus, and micrococcus catarrhalis	1
Pneumococcus, staphylococcus albus and citreus, micrococcus catarrhalis and tetragenus	1
Pneumococcus and staphylococcus citreus	1
Pneumococcus, staphylococcus albus, aureus, and citreus, micrococcus catarrhalis	1
Uncertain	1
Negative finding	1
	13

A pretty heterogeneous collection.

INTENSITY OF INFLAMMATION.

Just as all kinds of conjunctivitis may be produced by any one germ, so all grades of intensity may be thus produced, although, of course, certain organisms like the gonococcus, the diphtheria bacillus, the streptococcus, and the pneumococcus are particularly virulent.

It so happened that in this series of cases the inflammation produced by just these organisms was relatively mild, no single one of the 29 due to these four germs being associated with, for example, destructive disease of the cornea. It is involvement of the cornea, indeed, that, clinically speaking, forms our test of the seriousness of an acute conjunctivitis, for, no matter how severe the other symptoms may be, we regard the condition as benign if the cornea remains intact. Judged by this criterion the Weeks' bacillus is relatively innocuous, for in no single case in which infection was produced by the Weeks' bacillus alone or in combination with the xerosis bacillus, was the cornea involved.

On the other hand, the staphylococcus albus, and still more the staphylococcus aureus, showed a fairly well marked virulence as regards their action on the cornea. Thus, as above shown, in 21 non-trachomatous cases in which the staphylococcus albus was present alone or with bacillus xerosis or micrococcus catarrhalis there was involvement of the cornea in 5.

To this may be added that of the 13 cases of trachoma on our list there are only 4 in which involvement of the cornea was recorded and of these, 2 were cases of pure staphylococcus infection, the other two being cases of infection with pneumococcus and staphylococcus citreus (Case 94) and with pneumococcus, staphylococcus albus, aureus, and citreus, and micrococcus catarrhalis (Case 95).

Furthermore, of the 17 cases of mixed infection with the Weeks' bacillus and staphylococcus albus (or 16 cases if the one case of trachoma is excluded), there were 3 with involvement of the cornea.

It would seem, therefore, that the staphylococcus albus distinctly predisposes to involvement of the cornea.

This is still more the case with the staphylococcus aureus. Nine cases of infection with the staphylococcus aureus alone or, or the staphylococcus aureus combined with the staphylococcus albus, bacillus xerosis, or Weeks' bacillus, showed 6 in which there was corneal ulceration.

Finally, as an evidence of the possible part played by the staphylococci in producing diseases of the cornea, it may be stated that, excluding the trachoma cases in which the corneal lesions were evidently old, there were only 3 cases of corneal disease out of 20 cases of infection by the pneumococcus and two out of these 3 were cases of mixed infection with staphylococci.

While not inclined to lay much stress on such comparatively small figures, I submit that they are at least suggestive and indicates that the staphylococcus albus is distinctly pathogenic.

MIXED INFECTIONS.

Most infections of the conjunctiva are probably mixed in that several kinds of germs are present. It would seem that in the conjunctivitis due to mixed infections the virulence of the more active germ present is not enhanced by the presence of the others; thus, the pathogenicity of Weeks' bacillus and the staphylococcus albus is not greater than that of the staphylococcus albus alone. Indeed, in the cases of pneumococcus conjunctivitis here studied, which were nearly all examples of complex infections, sometimes 5 different kinds of bacteria being present, the inflammation was of rather a mild type, almost as if one germ inhibited instead of assisting the action of the others.

CONCLUSIONS.

If the correctness of our observations be granted, the following conclusions appear to be justified:—

1. There is no special type of conjunctivitis associated with any special germ. The clinical picture presented, therefore, affords no clue to the germ causing the conjunctivitis.

2. Membranous conjunctivitis, as is well known, may be

caused by a variety of organisms. It does not necessarily indicate a severe inflammation or one that will produce other evidences of excessive reaction besides the false membrane.

3. In trachoma, particularly trachoma in the stage of acute exacerbation, a variety of organisms may be present. These do not, of course, cause the trachoma, but they are of importance in that they do produce an intercurrent acute conjunctivitis with secretion, which latter serves as a carrier of contagion and thus disseminates not only the conjunctivitis but the trachoma as well.

4. The staphylococcus albus and particularly the staphylococcus aureus are distinctly pathogenic and predispose to the production of corneal lesions. The fact that the staphylococcus albus is probably almost a constant inhabitant of the conjunctival sac does not invalidate this conclusion.* It may well be that ordinarily it is inert or the conditions are such that it can do no harm, but that at times either it is stirred to action by some agent that heightens its pathogenicity or else that a way is made for it to act either by the working of some other germ or by the effect of some mechanical injury. The production of stitch abscesses by the pyogenic germs normally resident in the skin would be an analogous case.

5. Very mixed infections seem, if anything, to be rather less severe than those in which one germ is the predominant infecting agent.

In presenting these conclusions let me forestall inevitable criticism by saying that I do not attach too much importance to the bacteriological findings and I admit that deductions can be made from them only with considerable reserve. I know that the methods employed may fail and in some of my cases undoubtedly did fail to show all the bacteria present, and that, in particular, the staphylococcus albus and the xerosis bacillus were undoubtedly present more often than they were found. That this must have been so seems evident from the demonstrations of Randolph, Gifford, and others. This fact should not be under-

* See for some interesting remarks on this subject with conclusive proof of the pathogenic action of staphlococcus albus, H. Gifford, Arch. Ophth., No. 6, 1898.

stood as constituting the least reflection on Dr. Hastings' work, which, on the contrary, deserves the highest praise for its care and thoroughness. It simply serves to show that ordinary methods, such as alone are compatible with the work of a busy general laboratory, are not always sufficient for investigations like these which are of special intricacy.

Again, it is urged with much plausibility that staphylococci, when found in old cases, particularly in the corneal lesions, represent not the primary infecting germ, but a secondary invasion, so that they are to be regarded not as the cause of the lesion but simply as a complication of it or a mere contamination.

Lastly, deductions as to the action of pathogenic germs must reckon not only with the kind of germ present, but also with the amount present in the given case. They must also reckon with the varying pathogenicity of the germ, for different specimens of the same organism may differ widely in this regard. Hence, to warrant sure conclusions, a much larger number of cases ought to be examined than in the series here presented, and the conditions ought to be more precisely stated.

Assigning full weight to all these considerations, I yet think that the bacteriological findings here given and the conclusions drawn from them have a certain value, and that at least they indicate the line along which future investigations extending over a considerably large number of cases, should be made.

Twelve Tables Showing

132 Cases

ACUTE CONJUNCTIVITIS.

1. Gonococcus.*

No.	Sex.	Age.	Duration (days).	Discharge.	Swelling of lids.	Swelling conj. of lids.	Injection conj. of lids.	Injection of eyeball.	Chemosis.	Involvement of cornea.	Remarks.
1	F	35	4	Slight	Slight	Moderate; conjunctiva of upper and lower lids covered with adherent false membrane	.....	Intense, general	.....	None	Case referred to hospital, and subsequent history unknown.

2. Weeks' Bacillus.

2A. Pure Infection.

2	F	9	8	Slight; purulent	.....	Slight	Moderate	Slight, reticulate	.....	.....	
3	M	2	3	Profuse, thick, greenish	.....	Slight	.....	Slight	.....	None	Recovered in a few days, relapse one month later.
4	F	45	4	Moderate, muco-purulent	.....	.....	Moderate, general	Moderate, general	.....	.. ..	
5	M	8	3	Profuse, purulent	Moderate, with reddening of skin	Slight	Moderate, diffuse	Great; large patchy subconjunctival hemorrhages	Slight	.....	
6	M	12	2	Slight and decreasing	.....	Slight but increasing and becoming papillary	Moderate	Moderate	.....	.....	
7	M	10	....	Slight, watery	.....	.....	Slight	.....	.....	.....	
8	M	32	8	.....	.....	.....	Moderate	.....	.....	.....	Photophobia.
9	F	10	....	Profuse, muco-purulent	.....	Marked	.....	Marked, general	.....	.....	
10	F	15	....	Profuse, muco-purulent	.....	Well-marked	Well-marked	.....	.....	.....	Sister of Nos. 11 and 109, who were simultaneously affected.
11	F	9	....	Profuse, muco-purulent	.....	Well-marked	Well-marked	.....	.....	.....	Sister of Nos. 10 and 109, who were simultaneously affected. Discharge and swelling persisting in spite of treatment for over one month.

2B. Probably Weeks'.

12	F	40	....	Muco-purulent	.....	.....	.....	.....	.....	.....	Lachrymal disease.
13	M	26	7	.....	.....	Slight	.....	Diffuse, general	.....	.....	Perhaps complex infection (some Gram-positive cocci present, also bacilli, probably influenza bacilli).
14	M	11	....	Muco-purulent	.....	Present	Present	.....	.....	.....	

2C. Weeks' and Xerosis Bacillus.†

15	M	....	....	Purulent	.....	.....	Marked	Marked	.....	.....	Photophobia. Weeks' B. in smear (few); Xerosis B. in culture.
16	F	19	1	Slight	.....	.....	Moderate	.....	.....	.....	Sister of cases 17 and 40, who were simultaneously affected. In first attack only Weeks' B. with occasional Gram-positive cocci (both in smear only); in second attack, six weeks later, Weeks and Xerosis B. (in culture); also a few Gram-positive diplobacilli (in smear only).
17	M	5	14	Moderate, purulent	.....	.....	.....	L. injected	.....	.....	Brother of cases 16 and 40, who were simultaneously affected. Weeks' B. in smear and culture, Xerosis B. in culture; in smear also Gram-positive cocci and diplococci apparently capsulated (? pneumococci).
18	M	7	3	Profuse muco-purulent	.....	Present	Present	Present	Present	.....	Pain. Weeks' B. in smear; Weeks and Xerosis B. in cultures.
19	F	4	2	Profuse purulent	Marked (eyes nearly closed)	.....	.....	Marked; diffuse hemorrhages	.....	None	Smear: Weeks' B. (scattered). Culture: Weeks and Xerosis B.
20	M	9	3	Muco-purulent	.....	Present	.....	Present	.....	.....	Photophobia. Weeks' B. in smear; Xerosis B. in culture. L. only affected.
21	M	7	....	Slight, muco-purulent	.....	.....	Present	.....	.....	.. ..	Weeks' and Xerosis B. (few) in smear. Acute attack in course of a chronic trachoma persisting after expression.
22	F	11	2	Slight, muco-purulent	.....	.....	Diffuse	Marked, reticulate	.....	None	In three days affected eye better; other eye now involved. Smear: doubtful. Culture: Weeks and Xerosis B.

* With staphylococcus albus and bacillus xerosis.

† See also No. 108.

2D. Weeks' and Staphylococcus Albus.

No.	Sex.	Age.	Duration (days).	Discharge.	Swelling of lids.	Swelling conj. of lids.	Injection conj. of lids	Injection of eyeball.	Chemosis.	Involvement of cornea.	Remarks.
23	M	7	....	Moderate, purulent	.....	See remarks	.....	.....	.....	None	Case of trachoma persisting obstinately after expression in spite of all treatment; recurrent exacerbations with marked papillary swelling of conj. Five months later showed only St. albus.
24	M	43	7	Thin muco-serous. Two months later, profuse	Eczematous reddening at outer canthus	Succulent swelling	Marked	.....	.....	.....	Few organisms.
25	M	23	60	Moderate, purulent	.....	.....	.....	Marked (also ciliary inj.)	.....	One punched out ulcer; two superficial infiltrates	Gradual improvement.
26	M	13	3	.....	.....	Diffuse	Present	Present	Present	.....	
27	M	13	14R. 1L.	Profuse muco-purulent	L. œdematous	Marked	Marked	Present	.....	None	B. Proteus also present (probably a contamination).
28	F	36	90	Moderate, muco-purulent	.....	.....	.....	.....	.....	.....	Lachrymal conjunctivitis. R. only affected.
29	M	10	1	Thick, purulent, moderate (becoming profuse)	Moderate	.....	Diffuse, uniform	Dense, reticulate	.....	On 8th day, marginal phlyctenula	
30	M	1¾	4	Purulent	Œdema both lids	Marked	.....	.....	Marked	Erosions of margin	Excoriation of upper lip and ala of nose. Smear, negative
31	F	13	4¶	Muco-purulent	.....	.....	.....	.....	.....	.....	
32	M	7	....	Purulent	.....	Swelling and thickening	.....	None	.....	.....	
33	M	8	....	Mucopu-rulent	.....	Papillary	Marked	.....	.....	.....	Also Xerosis bacillus, only a few Weeks' bacilli.
34	F	40	4	Purulent, stringy	.....	Moderate, diffuse	.....	Present	.....	.....	Mother of case 88 who was simultaneously affected. Pain. St. albus not certainly present; M. catarrhalis also probably present.
35	M	10	3	Scanty, thick muco-pus	.....	.....	Present	Present	.....	.....	Numerous Weeks' bacilli in smear; in R. (not L.) St. albus in culture.
36	M	8	4	Profuse, purulent	.....	Present	Present	Present	Present	.....	Pain, photophobia.

37	F	6	4	Profuse, thick, yellowish	Present (lids nearly closed)	.....	.....	Marked	.....	.....	Pain. Xerosis bacilli also present.
38	M	54	5	Profuse, purulent	Marked	Present	Present	Present	Present (extending to cornea)	.....	Smear, negative. Xerosis bacilli also present.
39	F	9	....	Profuse, purulent	.....	.....	.....	.....	.....	None	Recurrent inflammation in case 43.

2E. Weeks' Bacillus and Staphylococcus Aureus.

40	F	10	1	Profuse, thick	.....	.....	.....	Very mark'd with hemorrhages	.....	.....	Sister of cases 16 and 17 (Weeks' and Xerosis B. infection), who were simultaneously affected.
41	F	8	4	Very profuse, purulent	.....	Slight	Present	Marked with hemorrhages	Circum-corneal swelling	Few marginal infiltrates	Pain. Smear: few Weeks' bacilli Culture: St. aureus.
42	M	58	14	Slight; muco-purulent	Present	.....	Marked	.....	Circum-corneal swelling	Two days later, superficial erosions	Also M. catarrhalis. Intense itching, photophobia, and lachrymation.
43	F	9	4	Muco-purulent	.....	.....	Diffuse	Present (esp. R.)	.....	Perforating ulcer, forming cystoid cicatrix	Recurrence four months later with profuse discharge; this soon cleared up without corneal involvement; this time Weeks' and St. albus present.

2F. Weeks' and Micrococcus Catarrhalis.

44	M	....	....	.....	.....	.....	.....	.....	.....	.....	Acute inflammation complicating an old trachoma.
45	F	22	5	Profuse, greenish	.....	.....	.....	Very intense	.....	One to two marginal infiltrates	

2G. Weeks' and Pneumococcus.

See under *Pneumococcus.*

2H. Weeks' and Bacillus Pneumoniæ (Friedländer).

46	F	30	3	Diffuse, white, dense, tenacious, but not very adherent membrane	Upper lid swollen	.....	.....	.....	.....	.....	

3. Staphylococcus Albus.

3A. Pure Infection.

No.	Sex.	Age.	Duration (days)	Discharge.	Swelling of lids.	Swelling conj. of lids.	Injection conj. of lids.	Injection of eyeball.	Chemosis.	Involvement of cornea.	Remarks.
47	M	32	2	Muco-purulent	Œdema inner half upper lid	See remarks	See remarks	See remarks	See remarks	See remarks	Inflammation of socket from irritation of artificial eye. Same condition and bacteriological finding six months later. Smear neg.
48	F	3½	20	Slight	.....	Papillary swelling	Marked	Marked	.....	Small erosion	Smear neg.
49	M	16	8	Thick, purulent !	.....	Diffuse	.....	Leash of engorged vessels with phlyctenula	.....	None	Pain.
50	F	13	1	None	.....	.....	.....	General, marked	.....	.....	Smear neg. Pain.
51	M	3 wks	7	Moderate, thick, purulent	Slight	Moderate	.....	.....	.....	.....	Rapid improvement.
52	F	6½	....	Very profuse, purulent	.....	.....	.....	.....	.....	.....	Cocci in smear. Patient did not return. Three others in family simultaneously affected, all with profuse purulent discharge.
53	F	7	....	Muco-purulent	.....	Present	Present	Present	Present	.....	Trachoma. Smear neg.
54	M	9	....	Purulent	.....	.....	Present	Present	.....	.....	Photophobia.
55	M	14	....	Purulent; later serous	.....	See remarks	See remarks	Episcleral and circumcorneal	.....	Slight pannus; confluent, guttate superficial vascularized infiltrates	Has recurrent inflammation every spring. Aberrant trachoma. Papillary swelling lower retrotarsal fold. Upper tarsus covered with large, flat, raspberry-like, pale red, very vascular granulations. One of these excised and found to show lymphoid structure of a trachoma follicle. Repeated examinations show only Staph. albus. Secretion infectious (producing conjunctivitis in another case).
56	F	8	1	.....	.....	.....	.....	General conjunctival and ciliary	.....	Repeated punctate and striate infiltrates apparently subepithelial	A few granulations in lower lids, but no true trachoma. Smear neg.

57	M	....	....	Profuse, purulent	Moderate with pseudoptosis	Succulent with evidences of mixed trachoma and cicatrices	.....	.....	.....	Pannus and acute ulcer	Acute exacerbation of old trachoma. Ulcer checked only by actual cautery.
58	M	2½	60	Mucous	.....	.....	.....	Ciliary	.....	Central and marginal infiltrates	Inflammation recurring one year later. Then showed Staphylococcus albus.
59	M	31	30	Purulent	.....	.....	.....	.....	.....	Two phlyctenulæ (marginal)	Smear neg.
60	M	13	....	.....	.....	.....	.....	.....	.....	.....	Smear contained Bacillus anthracoides (contamination).
61	F	9	....	... ..	.....	Follicular swellings	.....	.....	.....	.....	Smear neg.
62	F	70	....	Muco-purulent	.....	.....	.....	.....	.....	.....	
63	M	5	....	Slight	.....	Slight	Marked	Marked	.....	.....	
64	M	63	7	Purulent?	.....	.....	.....	.....	.....	.....	Recurrent conjunctivitis for years.

3B. Staphylococcus Albus with other Organisms.

65	M	....	3	Profuse, watery	.....	.....	Marked	Marked over upper part of eye	.....	.....	St. albus and B. Xerosis.
66	M	1½	Sev'l	Muco-purulent	.....	Present	.....	.....	.....	.....	Following hordeolum. St. albus and B. Xerosis.
67	F	37	7	Slight muco-purulent	.....	.....	.....	Outer half with ulcer of conj.	.....	.....	St. albus and B. Xerosis; perhaps also Mic. catarrhalis.
68	F	10	60	Purulent (from lachrymal sac)	.....	.....	.....	.....	.....	None	St. albus, Mic. catarrhalis. In culture B. Proteus vulgaris. Lachrymal disease.
69	F	55	14	Muco-purulent	Œdematous	Present;	Present	Present	Present	.....	Pain. St. albus and B. Xerosis with capsulated B. (probably B. pneumoniæ).

4. Staphylococcus Citreus.

70	M	35	2	Mucous, slight	.....	Present	Present	.....	.....	.....	Following abscess of lid. St. citreus and albus.
71	F	7	....	Purulent	.....	.....	Present	Present, lower part eyeball	.....	.....	Few organisms. St. citreus and probably B. Xerosis.
72	F	35	4	Muco-purulent	Marked of lower lid (beginning abscess)	.....	.....	.....	Marked	.....	St. citreus.

5. Staphylococcus Aureus.

5A. Pure Infection.

No.	Sex.	Age.	Duration (days).	Discharge.	Swelling of lids.	Swelling conj. of lids.	Injection conj. of lids.	Injection of eyeball.	Chemosis.	Involvement of cornea.	Remarks.
73	M	10	7	Creamy pus	.....	.....	.....	.....	.....	Phlyctenula	Smear neg.

5B. Mixed Infection.

74	M	67	3	Muco-purulent shreds	.....	.....	Present	Marked, esp. round cornea	.....	Infiltrated ulcer	St. aureus and albus, B. Xerosis.
75	M	25	1	... ..	.....	.....	.....	Marked, local	.....	.....	Conj. associated with abscess of lids. St. aureus and albus. In smear also a few Gram-neg. bacilli and Gram-pos. diplococci.
76	M	30	20	.....	.....	.....	.....	Dense, circum-corneal	.....	Deep infiltrated ulcer with many other infiltrates	St. aureus and albus, B. Xerosis.
77	F	4	7	Profuse, thick, purulent	.....	.....	.....	Marked with punctate hemorrhages	.....	.....	St. aureus and albus.
78	F	29	4	Profuse, muco-purulent	.....	General	Diffuse	... ..	.....	.....	St. aureus and albus.

6. Streptococcus.

79	M	9	....	Moderate	.....	Moderate	.. ...	.....	.....	.....	Str. and B. Xerosis ; in smear also few Gram-neg. bacilli.
80	M	38	....	Purulent	.....	.....	.....	.....	.....	... ..	This is a later stage of case 101 (which see).

7. Pneumococcus.

81	F	6	6	Profuse muco-pus	.....	.....	.....	General	General	.....	In smear, Gram-pos. diplococci. In culture, L. eye pneumococcus, R. no growth.
82	F	6	5	.....	.....	.....	.....	General	.....	Slight multiple erosions of margin	Smear, Gram-neg. bacilli. Culture, pneumococcus and Weeks' B.

83	F	10	....	.....	.....	Trachoma follicles	.....	.....	.....	.....	Pneumococcus, St. albus, mic. catarrhalis.
84	F	3	35	Muco-purulent, scanty	.....	.....	Marked	Marked	.....	.....	Pneumococcus, St. albus and aureus.
85	M	....	4	Abundant	.....	.....	.....	Leash running to ulcer	.....	Infiltration and ulcer at margin	Smear, neg.; culture, pneumococcus, St. albus and citreus. Culture from nasal excoriation, St. albus.
86	F	48	....	Muco-purulent (from dacryocystitis)	.....	Velvety	.....	.....	.....	... ..	Pneumococcus, St. albus.
87	M	9	....	Slight, muco-purulent	.....	Moderate	.....	.....	.....	.....	Trachoma. Smear, few organisms. Culture, pneumococcus, St. albus and citreus, Mic. catarrhalis and tetragenus.
88	M	....	....	Profuse, purulent	.....	Moderate, diffuse	.....	.....	.....	.....	Pneumococcus and Weeks' B. Son of case 34 who was simultaneously affected.
89	F	12	....	Muco-purulent	.....	Present	Present	.....	.....	.....	Smear, many organisms (Weeks' B. and others). Culture, pneumococcus.
90	F	50	....	Watery	.....	.....	.....	.....	.....	.....	Old dacryocystitis. Smear, neg. Culture, pneumococcus, St. citreus.
91	F	1½	....	.....	.....	Present	.....	.....	.....	Marginal ulcer	Smear, few organisms. Culture, pneumococcus, B. Xerosis, St. albus, aureus, and citreus.
92	M	42	60	Slight	.....	Present	Present	.....	.....	.....	Smear, few but various organisms. Culture, pneumococcus, pneumobacillus, Mic. tetragenus, B. Xerosis, St. albus.
93	M	....	Sev'l	Slight, muco-purulent	.....	.....	Present	Marked	.....	.....	Smear, Weeks' B. Culture, Mic. catarrhalis, pneumococcus, (mixed culture), Weeks' B.
94	M	18	....	Scanty, purulent	.....	.....	Marked	Marked	.....	Infiltration upper half cornea (pannus)	Smear, few organisms. Culture, pneumococcus, and St. citreus. Exacerbation of trachoma.
95	M	26	100	Purulent	.....	Marked thickening and furrowing, forming lobulated masses	Marked	Marked	.....	Pannus with punctate ulcers	In smear, many Gram-neg. diplobacilli (probably Morax D.), scattered Gram-pos. cocci. Culture, pneumococcus, St. albus, aureus, and citreus, Mic. catarrhalis.
96	F	15	7	Thick, purulent	.....	.....	Marked, R. and L.	Marked, R. and L.	In R. eye	.....	R., St. albus, pneumococcus. L., Weeks' B., pneumococcus.
97	M	29	....	Muco-purulent	.....	.....	.....	.....	.....	.....	Pneumococcus, St. albus.

7. Pneumococcus.

No.	Sex.	Age.	Duration (days).	Discharge.	Swelling of lids.	Swelling conj. of lids.	Injection conj. of lids.	Injection eyeball.	Chemosis.	Involvement of cornea.	Remarks.
98	M	36	....	Profuse, muco-purulent	.....	.....	.....	Marked	.....	.....	Traumatic conjunctivitis. Conjunctiva torn. Smear, few organisms. Culture, pneumococcus, St. albus, Mic. catarrhalis.
99	F	57	.. .	Membranous exudate covering center of tarsus	Ectropium lower lid (this not present two years ago)	.....	.....	.....	.....	.....	Pneumococcus, B. Xerosis. Exudate cleared off in five days.
100	F	2	4	Profuse, thick, purulent	Slight	.....	.....	Marked; patches of hemorrhage	.....	.....	Pneumococcus, Weeks' B., B. Xerosis, St. albus, Mic. tetragenus.
101	M	38	8	Profuse, thick, purulent	.....	.....	.....	Marked	Slight	.....	Acute exacerbation of old trachoma. Smear, few organisms. (Weeks' B., pneumococcus, spirilla). Culture, pneumococcus. Two months later, smear shows Gram-neg. diplococci (? Mic. catarrhalis). Culture, streptococcus.
102	F	20	7	Slight, purulent	.....	Present	.....	.....	.....	.....	Smear, many cocci. Culture, pneumococcus, St. albus.

8. Diplobacillus of Morax.

No.	Sex.	Age.	Duration (days).	Discharge.	Swelling of lids.	Swelling conj. of lids.	Injection conj. of lids.	Injection eyeball.	Chemosis.	Involvement of cornea.	Remarks.
103	M	20	4	Slight. muco-purulent	.....	Present in lower lids	Moderate	Moderate	.....	.....	Morax B. in pure culture.
104	F	28	7	Thick, yellowish	.....	.. ...	.....	Localized inner third eyelid ulcer in ocular conj., with mass of adherent secretions covering it	Deep swelling conj. and semilunar fold	.....	Smear, Gram-pos. and Gram-neg. cocci (probably Mic. catarrhalis); Gram-neg. bacilli (probably Morax B.). Culture, B. Xerosis only.
105	M	26	2	Muco-purulent	.....	.....	Present	Present	.....	.....	Smear, diplobacilli. Culture, St. albus, Morax B.
106	M	47	17	Mucous	.....	In retrotarsus	Dense, diffuse	Reticulate on inner side of cornea	.....	.....	Smear, neg. Culture, St. albus, Morax B.

107	M	60	7	Muco-purulent	.....	Marked	.....	.....	.....	.....	Smear, intracellular Gram-neg. diplobacilli (probably Morax B.) Seven or eight months later, showed in smear, Gram-neg. diplobacilli; in culture, St. albus.
9. Xerosis Bacillus.											
108	M	54	....	Profuse, purulent; upper lid covered with persistently recurring white membrane (see remarks)	Much swelling and cicatricial distortion with ankyloblepharon and trichiasis	Irregular mushroom swellings with pit-like interspaces and dense white cicatricial bands	Great	.....	.....	R. Total leucoma (not xerotic) due to trichiasis	Lupus of conjunctiva, scars on skin, perforation of septum. Whitish membrane on upper lid consists almost of pure culture of Xerosis B. In smear also found B. Proteus and St. albus (few of latter). Culture, Weeks' and Xerosis B.
10. Diphtheria Bacillus.											
109	F	½	3	Profuse, purulent; adherent false membrane upper lid	Œdematous	Marked	.....	.....	Some	None	Marked purulent rhinitis. Five days later slight laryngitis. Under argyrol and antitoxin, discharge and œdema lessened, membrane disappeared. Finally complete recovery. Nasal secretion showed few diphtheria bacilli, secretion from eye only St. albus and B. Xerosis. Later examination showed a few diphtheria-like bacilli in eye and one culture showed some in throat. Two sisters simultaneously affected (Nos. 10 and 11), had pure Weeks' B. infection.
110	F	9 mos	4	Profuse, purulent; tenacious and lying like false membrane on lid	Marked	Marked	.....	.....	.....	.....	Marked coryza, throat normal, child evidently ill. Smear, cocci, diplococci, and Gram-pos. bacilli. Culture, B. diphtheriæ, Mic. catarrhalis, pneumococcus, St. albus, aureus, and citreus. Two days later, test showed precisely the same, (bacilli few, cocci numerous).
11. Uncertain Infection.											
111	M	23	12	.....	.....	.....	Marked	Marked	.....	.....	Smear, indefinite; Gram-neg. bacilli, few Gram-pos. cocci. Culture, neg.

11. Uncertain Infection.

No.	Sex.	Age.	Duration (days).	Discharge.	Swelling of lids.	Swelling conj. of lids.	Injection conj. of lids.	Injection eyeball.	Chemosis.	Involvement of cornea.	Remarks.
112	F	....	....	Profuse, muco-purulent	Present	.....	Present	.....	.....	.....	Smear, many organisms; Gram-pos. and Gram-neg. cocci and diplococci, few Gram-neg. diplobacilli. Culture, St. aureus and Gram-pos. and Gram-neg. cocci.
113	M	9	....	Stringy, purulent	.....	Marked	.....	.....	.....	None	Slight recurrent trachoma with acute exacerbation. Peristent in spite of treatment. Smear, intracellular Gram-neg. diplococci (few) (probably Mic. catarrhalis). Culture, neg.
114	M	4	3	Moderate, muco-purulent	.....	General	.....	General	.....	.....	Smear, few fine Gram-neg. bacilli (? Weeks' B.). Culture, B. Xerosis.
115	F	4	3	Muco-purulent	.....	General	General	.....	.....	.....	Smear, few Gram-pos. bacilli (probably B. Xerosis). Culture, neg.
116	F	13	3	Watery	Present	.....	Present	.....	Over temporal half	.....	Smear, uncertain. Culture, St. albus.
117	F	55	4	.....	.....	Diffuse	.....	General	.....	.....	Smear, no pus; few Gram-pos. cocci. Culture, neg.
118	M	49	3	.....	.....	.....	Present	Present	.....	Marginal infiltrates	Smear, few Gram-pos. and Gram-neg. bacilli. Culture, B. Xerosis.
119	M	15	....	.....	.....	.....	.....	Present	.....	.....	Smear. Gram-pos. cocci. Culture, neg.
120	F	6	14	Muco-purulent	.....	General	General	.....	.....	.....	Smear, leucocytes, cocci, and bacilli (probably B. Xerosis). Culture, St. albus.

12. Bacteriological Finding Negative.

121	M	10	....	Sero-purulent, slight	.....	.....	Marked	Marked	.....	.....	Smear, neg. Culture not taken.
122	M	7	....	.....	.....	Marked	.....	.....	.....	.....	Trachoma with recurrent exacerbation. After expression (very obstinate to treatment). Smear and culture, negative.
123	M	10	....	.....	.....	.....	.....	Circum-corneal	.....	Large superficial ulcer	Scrapings from surface of ulcer gave sterile smears and cultures. Same four days later.

124	F	15	40	.....	.....	.....	.....	.....	.....	Erosion L. cornea; old opacity R.	Smear, neg. Culture not taken.
125	F	59	30	.....	.....	Moderate	Moderate	.....	.....	.....	Smear and culture, negative.
126	M	40	4	Slight	.....	Moderate	Intense	Slight	.....	.....	Smear and culture, negative.
127	M	14	....	Muco-purulent	.....	Present	Present	.....	.....	.....	Smear, negative. Culture, one colony of B. Xerosis.
128	M	1	3	Muco-purulent	.....	Slight	Slight	.....	.....	.....	Smear and culture, negative.
129	F	21	....	Muco-purulent	.....	Present	Present	Extends to corneal margin	.....	.....	Culture, negative.
130	M	30	3	Slight	.....	Marked	Marked	Marked	Slight	.....	Culture, negative.
131	F	13	7	Slight, mucous	.....	Moderate	Reticulate	Marked, esp round cornea	.....	None	Smear and culture, negative.
132	F	7	3	Profuse, thick, purulent	Marked; also lids reddened	.....	.....	Marked	Present	.....	Smear, many cells. No bacteria. Culture, neg.

CYANOSIS RETINÆ.[1]

BY WILLIAM CAMPBELL POSEY, M.D.

PHILADELPHIA, PENN.

THIS term is used to describe the changes in the fundus which are observed in congenital heart disease with general cyanosis, and was first employed by Liebreich, in 1863, in his report of a case of this kind, the illustration of which may be found in the first edition of his *Atlas*. The honor of being the first to call attention to the changes in the eye-grounds, designated by the term of "cyanosis retinæ," however, belongs to Knapp, who exhibited a water-color and described the ophthalmoscopic findings in such a case before the Heidelberg Society in 1861. Von Ammon[2] had given a short description and sketch of the exterior of the eye in congenital heart disease in 1841, but no study of the fundus had been made, as the ophthalmoscope had not yet been discovered.

Since the publication of Knapp's description other cases have been recorded, although their number is exceedingly small, in view of the comparative frequency of congenital disease of the heart. This is to be accounted for, in all probability, not by the rarity with which this form of heart disease causes changes in the retina, but rather by the failure of clinicians to examine the eye-grounds in these cases, or, in the event of such examinations being made, to allot any special significance to them.

As may be seen by the illustration, from a case recently observed by the writer, and the description of which will follow, the changes revealed by the opthalmoscope in cyanosis retinæ are most striking, the vessels of the retina attaining a size which is rarely equalled in any other condition, this being particularly true of the veins, which may become enormously dilated and tortuous; the arteries, though usually similarly distended, being affected to a less degree. In addition to the change in their calibre, both veins and arteries, become much darker than normal,

[1] Read before the American Ophthalmological Society, May, 1905.

[2] Clinical Representation of the Diseases and Malformations of the Human Eye (Tafel, vol. xv, Fig. 3, Text, Bd. iii, p. 75).

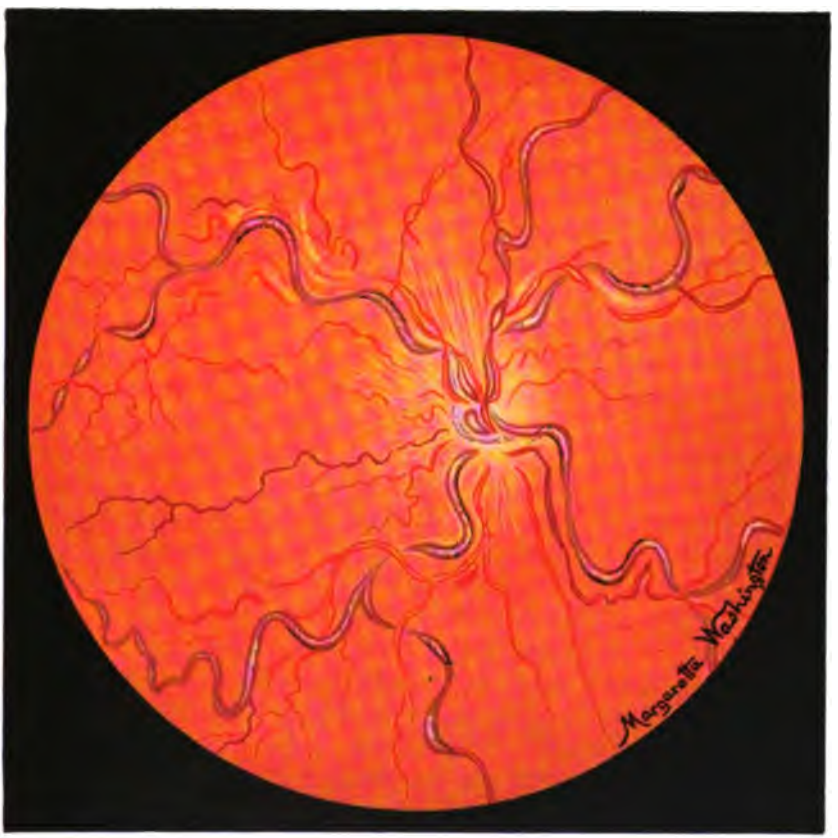

Cyanosis Retinæ.

the former assuming a deep-violet color, while the arteries resemble normal viens. The peripheral twigs of the retinal vessels are distended, and vessels which are usually invisible may be seen over the entire fundus. Pulsation in the vessels is absent. Small hemorrhages are of frequent occurence in the neighborhood of the disk; more rarely larger ones are found in the macula, when vision may be much affected.

As is well depicted in von Ammon's sketch, the exterior of such eyes also present marked signs of cyanosis, the lids becoming blue, the sclera violaceous, while the vessels of the conjunctiva are much distended. In the later edition of his *Atlas,* Liebreich withdrew the illustration of the case of cyanosis retinæ which had appeared in the first addition, and substituted for it one of abnormal pigmentation of the eye, to which he inappropriately applied the former name. Although, owing to the popularity of the *Atlas,* this change occasioned for a time some confusion regarding the precise application of the term, the subject is now well understood, and, as indicated in the opening sentence of this paper, the name of cyanosis retinæ is applied to the eye changes observed in cases of congenital heart disease alone.

The congenital diseases and malformations of the heart which may occasion changes in the fundi are various. Thus, they may be found where there is an abnormal connection between the right and left ventricles, and in cases in which there is a stenosis of the pulmonary artery or an abnormal origin of the aorta and pulmonary artery. They may also arise when there is a general retardation of the blood current, as a consequence of congenital dilatation of the entire vascular system.

The cause of the dilatation of the retinal vessels has been a matter of some dispute among clinicians, some maintaining that it is simply the result of the general venous stasis, while others aver that this cannot be true, as retinal changes rarely, if ever, occur in cases of general cyanosis due to causes other than congenital heart disease, and contend, moreover, that the arteries often manifest changes as well as the veins. Most authors attribute the dilatation of the vessels to a stretching in the walls of the vessels themselves, and consider this to be dependent upon a lessened resistance in the walls, due to disturbances in nutrition occasioned by insufficient oxygenation of the blood.

Although the examination of the eye-grounds in cases of congenital heart disease has not been considered by clinicians to be of particular moment, the dilatation and tortuosity of the retinal vessels being regarded as merely additional evidence of the general cyanosis, recent observations by Babinski and Nagel indicate that the ophthalmoscope may be of decided value both in the diagnosis and prophylaxis of this class of heart cases. Thus, Babinski has reported a case in which a marked dilatation of the retinal vessels preceded other evidence of general cyanosis, while Nagel, from a study of the cases in literature, and from his own observation, asserts that if the ophthalmoscopic examination reveals that the retinal arteries as well as the veins are darker and broader than normal, the presence of a connection between the two sides of the heart is assured; when the darker coloration and tortuosity is limited to the veins, he believes that the existence of some other congenital lesion is indicated, which does not permit the admixture of venous with arterial blood.

If these observations are true, clinicians should be made fully cognizant of them, for it is generally conceded that the diagnosis in cases of congenital heart disease is at times practically impossible from a study of the physical signs. It is hoped, therefore, that the practice of examining the eye-grounds in this class of cases may become more universal, and that the results of such examination be recorded, as it is only by means of a series of such observations that the assertions of Babinski and Nagel can be confirmed, and the actual value of the ophthalmoscope to the clinician proven.

The vision in eyes the seat of cyanosis retinæ may be normal, but if hemorrhages occur, as is not infrequently the case, vision may be more or less involved. Both eyes are usually similarly affected.

The attention of this Society was first called to the subject of cyanosis retinæ by Knapp, in 1870, who exhibited before the annual meeting of that year the sketch which he had prepared of the case exhibited by him in Heidleberg, and gave a short *résumé* of his notes. Since that time no further mention of the condition has been made before the Society, so that the writer considered that a brief *résumé* of the cases which had already been reported, and the details of two additional cases, might be not without interest.

1. As already recorded in the *Transactions* of the Society, in

Knapp's case there was non-inflammatory, excessive hyperæmia of both retinæ, occurring in a patient with enlargement of the heart, but without valvular anomalies, who exhibited general cyanosis and aneurysmal bruit at different parts of the body. The retinæ were so vascular that a countless number of thick and tortuous arteries and veins arose from the optic disks and branched radiating toward the periphery, like a caput Medusæ. The area and borders of the optic disks were totally concealed. The yellow spot was distinctly discernable. A great number of arterial and venous twigs reached to the fovea centralis. The retina, refracting media, sight, and visual field of both eyes were perfectly normal. The patient died in the hospital at Heidelberg. The body was found to exhibit a general enlargement of the whole vascular system.

2. The next case was observed by Liebreich, in 1863, and, as already stated, was illustrated in the first edition of his *Atlas.* Examination of the vascular system showed stenosis of the pulmonary artery, with considerable hypertrophy of the right ventricle. There was general cyanosis. The opthalmoscope showed the retinal veins to be twice as broad as normal, without being tortuous or presenting unevenness. The arteries were normal.

3. Leber[1] reported the third case, calling particular attention to the color of the blood, which was unusually dark in the arteries, being about the same color that the veins normally present, while in the veins it was dark violet-brown. The vessels were full and stood out from the level of the eye-ground. The anterior ciliary veins were unusually dark and the conjunctiva cyanotic. The patient was the subject of general cyanosis, and was thought to have stenosis of the pulmonary artery. This author, in his capacity as assistant, had had an opportunity to studying Knapp's case, and referred to it at length in his treatise in the first edition of the Graefe-Saemisch *Handbuch.*

4. In 1878 Stangloneier[2] reported a case of pulmonary stenosis in which there was endocarditis of the pulmonary valves, a patulous foramen ovale and ductus Botalli, small retinal arteries and very tortuous veins, with two large hemorrhages in the nasal part of the retina, which appeared shortly before death.

[1] First edition of the Graefe-Saemisch Handbuch, Bd. v, p. 525.
[2] Inaug. Dissert., Würzburg, 1878; Nagel's Jahrbuch f. Ophth., 1878, p. 261.

5. In the next case, a man aged twenty-five years, reported by Litten[1] in 1882, the fundus was found to be abnormally dark, emitting a decidedly bluish reflex. The retinal veins also were enlarged and tortuous. Examination showed a complicated valvular defect in the ostium pulmonale, associated with a defect in the interventricular septum. The same author[2] referred to another kind of cyanosis retinæ, namely, that produced by aniline poisoning, and cited a case in which the conjunctiva and fundus appeared violet and the retinal bloodvessels almost black. Vision was unaffected.

6. Nagel reported the sixth case, occurring in a boy aged nine years. One eye was staphylomatous, following a perforating ulcer of the cornea three years previously. The fundus of the fellow-eye showed the typical changes of cyanosis retinæ, the entire eye-ground being dark red and the veins almost black. The author was of the opinion that the marked cyanosis, the dyspnœa, the coolness of the skin, the clubbing of the fingers, pointed to a stenosis of the pulmonary artery, with probable mitral insufficiency.

7. In his monograph on *Congenital Affections of the Heart* (p. 23), George Carpenter cited a case which occurred in a child five and a half years old. There was extreme general cyanosis, the face and body being dusky, the mucous membrane slate-colored and the conjunctiva suffused. Ophthalmoscopic examination "showed the retinal veins to be *very* large, the arteries of good size, and both sets of vessels most intensely cork-screwy. There was no edge to the optic disk, and the red reflex apparently started from the physiological pit." At the autopsy both ventricles were hypertrophied and dilated, the right being in excess. The right auricle was twice the thickness of the left, but the left was dilated and the right auricular appendix was four times the size of its fellow, which was decidedly small. There was a patent septum ventriculorum, capable of admitting the index finger. The foramen ovale was closed. The aorta arose equally from both ventricles, and there were further abnormalities in its branches.

8. The same author referred to a second case, seen by him, in a small boy who was somewhat cyanosed. No cardiac bruit was detected. An opthalmological examination revealed fundal

[1] Deutsche med. Wochen., 1887, No. 8, p. 144.
[2] Berl. med. Wochen., 1881, Nos. 1 and 2.

changes similar to those noted in the case just reported, and suggested to him the nature of the complaint.

At the close of his interesting monograph Carpenter gave the notes of 22 cases of congenital heart disease, but unfortunately an ophthalmological examination appears to have been made in but one instance, where the history contains the note that "the veins of the optic disk pulsate and appear beaded."

9. In Loring's *Text-book of Opthalmology* (vol. ii, p. 106) will be found the notes of an additional case, occurring in a young woman aged twenty-eight years. Loring reports: "She had never noticed that her skin was darker than that of other people until six years ago, when she was shipwrecked, during which she was much terrified. Her finger-nails were, however, club-shaped, and she had been informed by her mother that this had been the case since she was ten months old. Her skin is now of a livid, bluish tinge, with dark-purple spots upon the face and hands, and she thinks that the color is increasing in darkness. The ears are purplish and the conjunctiva a good deal injected.

The veins of the fundus are enormously enlarged and tortuous, and have an anteroposterior curve in certain places, but only on the disk and its immediate neighborhood. There are very many vessels that are plainly visible and can be traced far into the retina, which, in the normal state, are either not present or are so minute as to be invisible. The color of the blood in the veins is of a violet tinge. The arteries are considerably enlarged, but not so much as the veins. The blood in the arteries is of the color of ordinary venous blood. There is no pulsation in either arteries or veins. An exhaustive examination by an expert failed to bring to light any disease of the heart or any abnormality in its sounds. The ophthalmoscopic picture presented a strong similarity to that of choked disk, and had been, indeed, taken for that."

10 and 11. In 1892, Hirschberg observed two cases. In the first, the retinal veins were dark blue, tortuous, and dilated. There were, in addition, general cyanosis, fingers clubbed, pulmonary emphysema, dilatation of right heart, and vision reduced to one-quarter in each eye. In the second case the heart was malformed and there was the same appearance of the eye as in the preceding case. Vision was normal.

12. Another case was reported by Galezowski,[1] in which vision

[1] No reference. Cited by Babinski, Revue neurologie, 1904, vol. xii, p. 1146.

was said to have been much lowered by intense congestion of the retina in the macular region, and, as in Stangloneier's case, retinal hemorrhages appeared a few days before death.

13. In 1899, Fehr reported a case before the Berliner Ophthalmologische Gesellschaft, April 20, 1899, but the writer has not had access to the *Transactions* of the Society, and has been unable to find the notes of the case elsewhere.

14. Quite recently Goldzieher[1] reported an interesting case of congenital disease of the heart with hyperglobulia, in which the left eye was lost, as a consequence of hemorrhagic iridocyclitis, and the right eye presented the typical changes described as cyanosis retinæ. The patient was a female aged nine years, who had always been sickly and had suffered repeatedly from nasal hemorrhages. The exterior of both eyes presented marked signs of cyanosis. The retinal arteries and veins of the right eye were much enlarged and darkened, and the edges of the disk were everywhere sharply outlined; there were no hemorrhages. The iris of the left eye, however, was stippled with small hemorrhages, and the vitreous contained so much blood that no reflex could be obtained from it. The globe was stony hard, and finally underwent spontaneous rupture through the sclera at the equator. Dr. Hochwall, who made a careful study of the case clinically, found a considerable increase in the hæmoglobin in the blood, as a consequence of increase in the number of red blood corpuscles, which he considered to be an expression of increased concentration of the blood. He thought the hyperglobulia was dependent upon the disturbance in the circulation, as a consequence of the congenital affection of the heart, and was not an instance of the symptoms-complex in which there is an association of polycythæmia, cyanosis, and tumor of the spleen. The determination of the precise nature of the cardiac lesion was difficult, but the physical signs and the employment of the x-rays indicated that either the foramen ovale was patulous or that there was a defect in the septum atrium.

15. In 1904, Babinski[2] saw a case in a ten-year-old subject with stenosis of the pulmonary artery. General cyanosis first appeared at three years of age, during an attack of whooping-cough. Left-

[1] Contrablatt f. prak, Augenheilk., September, 1904.
[2] Revue neurologie, 1904, vol. xii, p. 1143.

sided hemiplegia developed at this time also. The retinal arteries were tortuous and dilated, and the veins were enormously enlarged.

16. In a recent number of the *Annales d'Oculistique,* February 1905, the same author, in conjunction with Toufesco, reported another case occurring in a male aged thirty-five years. The patient had been sickly, but symptoms of cardiac congestion first became manifest after a prolonged attack of typhoid fever, when seventeen years of age. The pulmonary artery was stenosed. *Cyanosis of the retina was found without general cyanosis, both arteries and veins being markedly dilated.* The authors conclude from this that general cyanosis as a consequence of stenosis of the pulmonary artery may manifest itself in the retina before changes appear in the skin.

17. In 1903 a case of cyanosis retinæ was observed by the writer, which had been referred to him at his service in the Howard Hospital by Dr. S. M. Hamill, who had made a careful study of the general condition of the patient, which he later embodied in a report which has been published elsewhere.[1] The abbreviated history was as follows: The patient, a boy aged nine years, first became blue when a few months old. Dyspnœa had always been marked upon exertion. At the time of examination the boy was noted as being of normal size for his age and well nourished. The skin of his face and body and all the visible mucous membranes had a deep, purplish color. The skin was rough and dry and was covered with small, bluish follicles. The hands and feet were especially congested, and clubbing of both fingers and toes was present to a marked degree. Examination of the heart showed a double impulse, which was most marked in the fourth interspace. The left chest was more prominent than the right, but there was no thrill. At the apex there was a rather soft, short, blowing, early systolic murmur, which accompanied the first part of a divided first sound. The murmur and the divided sound were both heard in the axilla, over the body of the heart, and best in the third space to the left of the sternum. The murmur was heard faintly in the aortic area. The second pulmonic sound was much accentuated. The heart's action was fairly regular and rapid. There were marked pulsations in the veins of the neck and in the subclavians. Posterior to the sternocleido-

[1] Pediatrics, May, 1903.

mastoid muscle of the left side, and almost directly underneath the mastoid process, there was a marked pulsation, which on palpation felt like a tortuous and anomalously located external carotid artery. Dr. Hamill was unable, from the physical examination, to reach any satisfactory conclusion regarding its specific character, but inclined to the view that the case was one of stenosis of the pulmonary artery, with patulous ductus arteriosus, basing this opinion upon the age of the patient, the location of the murmur, and the greater frequency of this form of cardiac lesion.

As incorporated in Dr. Hamill's report, the condition of the eyes was as follows: The eyeballs were prominent. The conjunctival vessels, both those of the globe and those of the lids, were swollen, especially the veins, giving the eye a violaceous appearance. The pupils were large and the media clear. Vision was 5/6 in each eye.

The ophthalmoscope showed a neuroretinitis of marked degree. The retinal arteries and veins were greatly swollen and tortuous, resembling large angle-worms. The writer does not remember ever to have seen retinal vessels of a larger calibre, the retinal veins appearing to be increased to three times their normal size. The head of the optic nerve was obscured by the swollen retina, and there were a few small hemorrhages into the nerve-fibre layer of the retina close to the disk.

18. About the same time that Dr. Hamill's case was under observation, Dr. W. C. Swindells, the office assistant of the writer, found similar changes in the eye-grounds in a case of Dr. Howard Fussell, to whom he is indebted for the following note: "Male child, aged one year; presented no abnormality during the first two weeks of life. When next seen by Dr. Fussell, however, about a year later, marked signs of cardiac disease had manifested themselves. It was elicited from the mother that when the child was about two or three months old, and while he was lying in the cradle, he was suddenly seized by an attack of unconsciousness, during which his entire body became blue. As he grew older and moved about, attacks of dyspnœa became frequent, during which the face and fingers became blue. Occasionally, and especially when he was disturbed or attempted to run, attacks of unconsciousness supervened, during which the finger-nails became blue and the lips cyanosed. Examination revealed that the fingers were

clubbed; the precordia was prominent, and there was a marked prominence over the junction of the first and second piece of the sternum. The heart dulness was at the right border of the sternum and first rib diagonally downward to the nipple line. There was a very rough systolic murmur heard all over the chest, with greatest intensity at the upper border of the heart dulness, and transmitted into the vessels of the neck.

Shortly after this, and while still under Dr. Fussell's observation, the child had an attack of what was considered to be pneumonia and later was ill with true diphtheria with laryngeal stenosis. During the treatment of the diphtheria 2000 units of antitoxin were administered, with no untoward effects. After convalescence it was noted that the heart dulness had moved still farther to the right and was broader at the apex. A month later the cyanosis was more marked and the dyspnœa had become constant. The heart's action was slow and regular. A loud, high-pitched systolic murmur was heard over the aortic cartilage. The second heart sound was accentuated. To the left of the sternum the murmur was not as loud nor the second sound as sharp. The murmur was heard, however, over all the anterior part of the chest, its point of greatest intensity being just over the sternum, below the junction of the first and second parts. It could be faintly heard in the vessels of the neck and in the back. There was no pulsation in the external jugular. The second sound was loudest midway between the nipple and sternum, over the fourth interspace. The edge of the liver could not be plainly felt, but there was more resistance on the right side than on the left. The upper line of the liver dulness corresponded to the fifth rib in the axilla. There was no œdema of the legs. The child grew gradually worse and died a few months later with symptoms of cardiac failure. No autopsy was permitted; so that the probable diagnosis of mitral regurgitation, with, perhaps, some communication between the two sides of the heart, could not be ratified.

Owing to the fact that the diagnosis of the cardiac condition in the 18 cases which have been just cited was confirmed by autopsy in but four instances, and that the descriptions of the changes in the eye-grounds in most cases are too meagre from which to draw inferences regarding the precise lesion in the fundus which the various cardiac lesions may occasion, it has not seemed worth

while to attempt to summarize the facts which have been given, or to seek to prove the truth of Nagel's assertion from them. As indicating the value of ophthalmoscopic examination in cardiac cases of this type, it is of interest, however, in addition to the case of Babinski, which has already been cited, to refer to Carpenter's second case in which there was no cardiac bruit and but slight cyanosis, and the true nature of the complaint was determined only after the discovery of the typical changes of cyanosis retinæ by the ophthalmoscope.

NOTES ON THE CLINICAL DETERMINATION OF THE ACUTENESS OF VISION, INCLUDING THE CONSTRUCTION AND GRADATION OF OPTOTYPES, AND ON SYSTEMS OF NOTATION.

By JOHN GREEN, A.M., M D.,
ST. LOUIS, MO.

At the thirty-ninth annual meeting of the American Ophthalmological Society — Washington, D. C., May 13, 1903 * — a resolution was adopted in favor of the definitive conservation of Snellen's system, in which the height of the smallest test-letter recognized and named is referred to a standard based on a visual angle of five minutes (5′) subtended by the letter, or of one minute (1′) subtended by each of its component lines.

By the same resolution the Society pronounced in favor both of a gradation of test-letters in geometrical progression and of the adoption of the common ratios, $\sqrt{2}$ and $\sqrt[3]{2}$, substantially as first proposed by the writer and set forth by him in communications made to the American Ophthalmological Society at its fourth and fifth annual meetings—Niagara Falls, N. Y., (1867) and Newport, R. I., (1868).†

Since the adoption of these recommendations the question of "unification of visual scales" and of a "reform of the notation of visual acuity" has been considered by the *Société française*

* Transactions of the American Ophthalmological Society, Hartford, 1903.

† Transactions of the American Ophthalmological Society for 1867 and 1868, New York, 1868.

*d'Ophtalmologie,** and debated, without definitive action, by the Tenth International Ophthalmological Congress, — Lucerne, 1904.

In the light of these latest discussions, it has seemed opportune to present in review so much of earlier published work as may help to a true appreciation of recent proposals looking to a possible revision of present standards.

MINIMUM SEPARABILE.

The concept of a *minimum separabile,* deduced from measurements of the least visual angle under which two distant luminous points are distinguished by eyes assumed to be of normal defining power,† is at least two centuries old.

Defined as the least visual angle under which it is possible to distinguished parallel black lines separated by white interspaces of a width equal to that of the lines, it appears in the first wall-chart, by E. Jaeger,‡ designed for comparative measurements of the acuity of vision in individual eyes.

In a series made up of test-words in "lower-case" letters,§ by Giraud-Teulon,‖ the vertical strokes of the several letters are separated by spaces of the same width; short and long letters appear in the same word.

In the test-letters of Snellen** the width of the component lines of special "block-letter" capitals is taken as one-fifth of the height of the letter. The application of the principle of a *minimum separabile* is greatly restricted by the requirement of using letters of widely different shapes. The publication of Snellen's test-letters opened the way to the employment of methods of precision in measuring and recording the acuity of vision as a matter of daily routine in ophthalmic practice. Their continuing use, in authorized editions and in countless unauthorized reproductions, is a proof of the substantial correctness of the principle implied in their construction, namely, that approximately uniform legibility is of more importance than an imperfect conformity to a theoretically sound dictum.

---

* Annales d'Oculistique, CXXXI., Mai. 1904, pp. 382-92, 400.
† Hooke, Posthumous Works, 1705 (cited from Donders).
‡ Ueber Staar u. Staaroperationen, Wien, 1854. Reproduced in the Reference Handbook of the Medical Sciences, Art. "Optometry," New York, 1887.
§ literae minusculae.
‖ 2me Congrès international d'Ophthalmologie, Paris, 1862.
** Letterproeven tot bepaling der gezichtsscherpte, Utrecht, 1862.

OPTOTYPES.

The immediate and universal adoption of Snellen's test-letters, and the continuing employment of these and of other optotypes which make it possible to control the observations of the patient through his naming of the several letters or characters, is a sufficient proof of the practical superiority of such test-objects to those in which the determination rests on the counting of lines,* on the recognition of the number and relative positions of dots,† or on the noting of variations in the position of particular characters.‡ Untrained observing powers and lack of mental concentration, in young children; general inaccurateness and incapacity, on the part of illiterates of riper years; carelessness in observing, inability or disinclination to report accurately what is seen, an inveterate habit of guessing, on the one hand, or exaggerated conscientiousness, on the other hand, all militate against the trustworthiness, as well as the convenience in use, of tests in which the shortcomings of the patient cannot be definitely and readily controlled.

SELECTION AND CONSTRUCTION OF OPTOTYPES.

In the selection of test-letters, or of optotypes adapted to the limited capacity of young children and of illiterates, the principle of the *minimum separabile,* in so far as it involves the requirement of equality in the width of lines and spaces, must be sacrificed in the interest of approximately uniform legibility. In only a very small number of the Roman capitals, whether in the form adopted by Snellen or in such alternative forms as have been proposed, is this principle at all conspicuously exemplified, and these particular letters are found to differ widely in legibility from the far more numerous letters of simpler construction.§

---

* Jaeger. † Burchardt.

‡ Snellen's **E**, Landolt's **C**, etc.

§ This is conspicuously true of the letters B and S, which are especially difficult of recognition, one from the other. "Gothic" **E**, on the other hand, is of about average legibility, owing to its open side.

W. S. Dennett (Trans. Am. Oph'l Soc'y, 1885) has investigated the comparative legibility of the "Gothic" letters used by Monoyer in his wall-chart (1877). The greatest distance at which individual letters 2.5 centimetres high could be positively recognized was found to vary between the limits, 10.3 metres and 17.7 metres. Of the 22 letters, eight were recognized at maximum distances of from 13. metres to 13.7 metres. Scaled to conform to these measurements, the sequence of letters of widely different sizes shown in each of the consecutive rows taken from Monoyer's chart affords a striking demonstration both of the limited applicability of the

Snellen's ideal of capital "block" letters drawn within the boundaries of a square, as illustrated by his device of showing the several letters superimposed on squares or rectangles subdivided into smaller squares, is only partially realized in the case of the letters which he has used. E. Dyer (1862) following Snellen, although anticipating Snellen's publication by a few months, printed a few copies of a wall-chart in which several letters of the simplified form known to printers and sign-painters by the inappropriate name of "**GOTHIC**" were intermixed with others of the form adopted by Snellen. In 1865, the writer of this paper designed a tentative series of "Gothic" letters which were printed, from wood blocks, together with other illustrations contributed by him to "Recent Advances in Ophthalmic Science" by Dr. H. W. Williams.* Three years later he again made use of "Gothic" letters in a wall-chart of "Test-letters in Geometrical Progression" communicated to the American Ophthalmological Society at its fifth annual meeting.† "Gothic" letters were employed, several years later, by Monoyer, in his series based on a notation in arithmetical progression,‡ and lastly, with some notable alterations in the width of certain letters, have been reproduced by Sulzer.§

At the meeting of the Fourth International Ophthalmological Congress (London, 1872)‖ the writer, in presenting again the series communicated to this society in 1868, proposed a further change to a form of letter based on the practice of sign-painters and known to the trade in America as the "New York block-letter." These letters, in a different arrangement, were reproduced in the American edition of Carter "On the Diseases of the Eye."**

A revised series in the same form of "block" letter, drawn

---

principle of the *minimum separabile* in the construction of test-letters and of the necessity of discarding such letters as vary greatly from the average, in legibility.

Probably not more than half of the capital letters of the alphabet can be utilized with advantage for test-letters. C. A. Oliver (Trans. Am. Oph'l Soc'y, 1885) discarded all but seven letters in making a selection from Snellen's "block" letters, but these selected letters are not the same as the "Gothic" letters to which Dennett has assigned the most nearly equal legibility.

* Boston, 1866.

† Published in the Transactions of the American Ophthalmological Society, New York, 1868.

‡ 1874—1877.

§ Annales d'Oculistique, CXXXI., Mai, 1904, p. 384.

‖ Report of the Fourth International Ophthalmological Congress, London, 1873.

** Philadelphia, 1876.

anew to conform to the metric standard, which, meanwhile, had been definitively adopted by Snellen, was engraved on movable metal types, under the direction of the writer, in 1886. A sheet printed from these types was included in the plates appended to the article "Optometry" in the "Reference Handbook of the Medical Sciences."*

The variation from Snellen's prototypes, in these letters, consists mainly in a shortening of the terminal cross-lines to a length equal to twice the thickness of the principal lines, making it possible to draw certain letters more nearly within the limits of a square. Five of Snellen's letters were discarded, leaving seventeen in which the characteristic constructive lines follow most closely the outlines of the letters, with a view to securing greater uniformity in the distance at which the several letters are recognized.

Attempts have been made, from time to time, to construct special optotypes adapted to the limited capacity and observing powers of young children and illiterates. Pictures in the simplest possible outlines, suppressing all indication of perspective, appeal strongly to persons of undeveloped or uncultivated powers of observation. A few outline figures, suggesting the forms of familiar objects easily recognized and named, afford the readiest and most satisfactory means of extending the application of Snellen's method to cases in which the recognition of letters fails.

Arrangements of such characters, originally designed by Dr. A. E. Ewing to supplement the collection of test-letters made by the writer in 1886, are now obtainable in a revised edition.† In the estimation of the writer, these tests are unequalled for convenience and usefulness.

GRADATION OF OPTOTYPES.

The gradation of test-letters in a regularly progressive series‡ was first advocated in an oral communication made by the writer at the fourth annual meeting of the American Ophthalmological

* New York, 1887.

† Universal Test-characters, particularly applicable as visual tests for children, by Arthur E. Ewing, M. D., St. Louis, Mo., 1902.

‡ The "Échelle régulièrement progressive" of Giraud-Teulon does not justify its title.

Society—Niagara Falls, N. Y., 1867.* The principle of gradation in geometrical progression was set forth, and a descending series shown in which the common ratio $\sqrt{0.5}$ was utilized. An engraved wall-chart of "Gothic" letters, also in descending geometrical progression but with a change of the common ratio to $\sqrt[3]{0.5}$,† was presented at the meeting of 1868 and published in the Transactions of the Society of that year.

The same series, in the modified "block" letter already mentioned and showing a descending geometrical progression of single letters in sequence, was presented at the meeting of the Fourth International Ophthalmological Congress—London, 1872—and was published in its proceedings.‡ This series, with a change to a more compact arrangement of the letters, was appended to the American Edition of Carter.§

In the revised (metric) series prepared by the writer in 1886, the common ratio $\sqrt[3]{0.5}$ (or its reciprocal, $\sqrt[3]{2.}$) was employed in the gradation of the Roman "block" letters. The factor $\sqrt{0.5}$ (or its reciprocal, $\sqrt{2.}$) was used in a series of letters in Fractur (drawn by Dr. A. E. Ewing), in graduated reproductions of Snellen's **E**, and in Dr. Ewing's test-characters for children and illiterates, included in the same collection.

The principle of gradation in geometrical progression has been endorsed emphatically, in recent utterances, by E. Javal,‖ and later, following Sulzer, has been accepted by the *Société française d'Ophtalmologie.*** The common ratio preferred by Javal is $\sqrt{2}$ (1,414); the factor adopted by the *Société française* is given as 1.259.††

It is a property of any series of optotypes in geometrical progression that the ratio of the visual angle subtended by any letter to that subtended by any smaller or larger letter is constant for all distances. If we take the distance (d) so that the height (D) of

* Transactions of the American Ophthalmological Society, New York, 1868.

† Changing the form to that of an ascending series the factors $\sqrt{0.5}$ and $\sqrt[3]{0.5}$ become $\sqrt{2.}$ and $\sqrt[3]{2.}$, respectively.

‡ London, 1873.

§ Philadelphia, 1876.

‖ Annales d'Oculistique, 1900.

** Annales d'Oculistique, Mai, 1904, p. 490.

†† $\sqrt[3]{2}=1{,}2599$ is represented more nearly by 1.26 than by 1.259.

a letter corresponding to any term of the series shall subtend an angle of five minutes (5′), the fact of the recognition of that letter at that distance is expressed, in Snellen's notation, by the formula: —

$$\frac{d}{D} = \frac{d}{d}.$$

Representing the common ratio of progression by r, the formula expressing the limit of visual recognition becomes, for all cases in which $D > d$:—

$$V = \frac{1}{r^n} \frac{d}{d},$$

or, for all cases in which $D < d$:—

$$V = r^n \frac{d}{d}.$$

If we regulate the distance (d) so that a letter (D) shall subtend a visual angle other than 5′, we may measure V in terms of any preferred unit other than that adopted by Snellen. A wall-chart of test-letters in geometrical progression may, therefore, be used at any convenient distance,* limited by its range, and any size of letter may be taken at will, as the unit of measurement.†

SYSTEMS OF NOTATION.

All systems of notation in which the acuity of vision (*S—Schschärfe, or V—visus*) is estimated in terms of a unit assumed to represent normal vision are open to the criticism that they invite, or at least suggest, erroneous interpretation. Thus, a finding recorded in the form, $V = \frac{d}{2d}$, when reduced to its arithmetical equivalent, $V = \frac{1}{2}$ or $V = 0.5$, is not infrequently loosely construed as justifying the statement that vision is only one-half, or has fallen off to one-half, of the normal, and expert testimony embodying such erroneous and misleading evaluation is almost sure to be brought forward whenever a case of alleged impairment of sight is carried into a court of law for adjudication.

* Not infrequently, more trustworthy measurements may be made at some short distance, 1. m. or 2. m., than at the usual distance of 5. m. or 6. m.

† The unit recommended by Sulzer, and tentatively named by him after Snellen, is a letter which subtends an angle of 54′ (1. grade) at a distance of 5. metres. The Société française d'Ophtalmologie, adopting this unit, has pronounced in favor of the name *Opt.*

With the general utilization of Snellen's test-letters, it was found that the observed acuity of vision varies notably for practically normal eyes. In persons of exceptionally sharp sight, the angle under which the component lines of Snellen's letters are recognized, as shown by the correct naming of most of the letters in the line, is not very infrequently as small as 0.4′*, and a visual angle of 0.8′ is observed in so large a proportion of all the eyes examined as to have suggested the proposal to adopt this value as the unit of reference. It is evident, therefore, that neither the value $\frac{d}{d}$ (Snellen), corresponding to a visual angle of 1′, nor a unit based on a visual angle of 0.9′ ($\frac{1}{10}$ grade),† nor, indeed, any arbitrarily chosen unit, can be accepted as a standard of normal acuity of vision.

Snellen's formula $V = \frac{d}{D}$, considered apart from any particular series of optotypes, signifies nothing more than that D is the smallest size of letter recognized and correctly named at a distance designated by d. As employed by its author, it expresses also the fact of such a relation of D to d that when $D=d$ the height of the letter subtends a visual angle of 5′, and the width of each of its component lines subtends an angle of 1′. In its actual form it is the complete expression of an observed fact, which is not the case when it is reduced to lower terms — as, for instance, to the form of a fraction in which the numerator is taken as unity — or to decimal notation.

The visual angle subtended by a component line of any letter (D) at the distance (d) is expressed, in minutes of arc, by the reciprocal $\frac{D}{d}$ of Snellen's $\frac{d}{D}$. If we invert Snellen's equation, we have: —

$$\frac{1}{V} = \frac{D}{d},$$

* This is about the smallest angle under which Snellen's letters are read by persons of exceptionally acute vision. In the wall-chart published by the writer in 1868, and designed for a distance of 20 feet, the series was extended to VII.

B. Joy Jeffries (Trans. Am. Oph'l Society, 1869; — Report of the Fourth International Ophthalmological Congress, London, 1873,) reported a series of personal observations showing $V = \frac{32}{XV}+, \frac{32}{XII}, \frac{23}{X}$, and $\frac{20}{VIII}$, using Snellen's test-types.

† Sulzer.

which expresses the measure, in minutes, of the least visual angle under which it is possible to distinguish individual letters; writing Λ (*lambda*) for $\frac{1}{V}$ in the first member, we have:—

$$\Lambda = \frac{D}{d} \text{ minutes.}$$

With the elimination of the concept of a *minimum separabile* arbitrarily assumed as a standard of normal acuity of vision, Snellen's equation satisfies all scientific requirements.

The five cards of test-letters, herewith presented,* have been selected from a collection of optotypes engraved and printed in 1886. For the scheme of gradation of optotypes in geometrical progression, the adoption of a modified form of "block" letter, and the alternative arrangement of single optotypes in sequence, the writer of this paper is alone responsible.

The letters are graded, as accurately as may be, in true geometrical progression, so that the height of any letter is the geometric mean of the height of the next smaller and that of the next larger letter. The consecutive values of D may be written, therefore, in the general form:—

$$a,\ r\,a,\ r^2a,\ r^3a,\ \ldots\ldots\ r^{n-1}\,a.$$

Taking $r^2=2$ ($r=\sqrt{2}$), the consecutive coefficients of a are:—

$$1,\ \sqrt{2},\ 2,\ 2\sqrt{2},\ 4,\ 4\sqrt{2},\ \text{etc.,}$$

or, representing the surd, $\sqrt{2}=1.41421356\ldots$, by 1.414:—

1., 1.414, 2., 2.828, 4., 5.656, 8., 11.312, 16., 22.624, 32., 45.248, 64., etc.

Taking $a=2.5$, we have the numerical series:—

2.5, 3.535, 5., 7.071, 10., 14.142, 20., 28.284, 40., 56.568, etc.,

or, discarding decimals after the second term:—

2.5, 3.5, 5., 7., 10., 14., 20., 28., 40., 56., etc.

This series, which was utilized by the writer in 1886, in arrangments of tests for illiterates, and which was adopted from him by Dr. A. E. Ewing for his test-characters for children, is probably the most convenient that has been proposed for use with patients

* These letters are reproduced in compliance with a request of the Society, 1903.

of limited mental capacity; it is intended to be used at a distance of 5. metres. Taking $r^3=2$ ($r=\sqrt[3]{2}$; $r^2=\sqrt[3]{4}$), the consecutive coefficients of a are: —

$$1,\ \sqrt[3]{2},\ \sqrt[3]{4},\ 2,\ 2\sqrt[3]{2},\ 2\sqrt[3]{4},\ 4,\ 4\sqrt[3]{2},\ 4\sqrt[3]{4},\ 8,\ 8\sqrt[3]{2},\ 8\sqrt[3]{4},\ 16,\ 16\sqrt[3]{2},\ 16\sqrt[3]{4},\ 32,\ 32\sqrt[3]{2},\ 32\sqrt[3]{4},\ 64,\ 64\sqrt[3]{2},\ \text{etc.},$$

or, representing $\sqrt[3]{2}=1.2599210506$ by 1.26, and $\sqrt[3]{4}=1.587401052$ by 1.5875: —

1., 1.26, 1 5875, 2., 2.52, 3.175, 4., 5 04, 6.35, 8., 10.08, 12.7, 16., 20.16, 25.4, 32., 40.32, 50 8, 64., 80.64, etc.

Taking $a=1$, these numerical coefficients represent consecutive values of D and d.

This series, graded from $D = 2.$ to $D = 80.64$, covers a range which has been found sufficient for all practical needs in determining the acuity of vision at a distance. The common ratio, $r = \sqrt[3]{2} = 1.26$, is probably as small as can conveniently be utilized in clinical work.

The numbering of the several sizes of letters (following Snellen) represents the distances, in metres, at which the respective letters subtend an angle of 5′. The observed least visual angle is recorded in the form of a fraction: —

$$\frac{D}{d},$$

in which D represents the number designating the smallest size of letter recognized, and d represents the distance in metres at which the letter is recognized; *i. e.*, the distance at which the card is hung, which may be 4., 5.04, 6.35, or 8. meters, as determined by the size of the room. Thus the recognition of a letter (D) at a distance (d) is recorded in the form: —

$$\Lambda = \frac{D}{d} \text{ minutes};$$

or, in Snellen's notation: —

$$V = \frac{d}{D}.$$

These fractional forms (following Snellen) ought not to be reduced to lower terms, or to decimals.

The Roman numerals shown on the several cards indicate an alternative numbering of the letters in thirds of a metre; these numbers may be used in the place of the Paris feet adopted by Snellen in his original test-letters (1862). The series based on the common ratio $\sqrt{2}$ becomes, then:—

VIIss., Xss., XV., XXI., XXX., XLII., LX., LXXXIV., CXX., CLXVIII., etc.;

and the series based on $\sqrt[3]{2}$ becomes:—

VI., VIIss., IXss., XII., XV., XIX., XXIV., XXX., XXXVIII., XLVIII., LXss, LXXVI., XCVI., CXXI., CLII., CXCII., CCXLII., etc.

The "block" letter used in these test-cards has been in continuous use in the practice of the writer since 1873. Slight changes in the construction of a few letters and in the selection of letters were made in 1886, and other minor changes for the better might be made in the event of engraving them anew. It is possible, also, that a more acceptable series may be designed in "Gothic" than has yet been produced in that character.

The arrangement of single letters in sequence (dating from 1872) materially shortens the time consumed in making approximate tests; it is also of use as a guide to the particular line of letters which a patient may be expected to read.

It is important that the letters the recognition of which indicates approximately normal vision be hung at about the height of the eyes of the patient. For this reason, if for no other, Snellen's arrangement of letters diminishing in size from above downwards should be retained.

VOL. X.—INDEX

INDEX OF SUBJECTS.

Angelucci's modification of the technique of the cataract operation, Dr. R. Sattler, ... 342
Argyrosis of conjunctiva and lachrymal sac following use of protargol, Dr. G. E. Schweinitz, ... 161
Are tenotomies for hyperphoria necessarily more uncertain in their results than those for esophoria and exophoria, Dr. S. Theobald, ... 154
Astigmatism, sixteen diopters of, corrected by galvano-cautery, Dr. C. F. Clark, ... 125
Bacterial diagnosis of diphtheria bacillus, esp. in diagnosis, Dr. A. Knapp, ... 283
Bacteriological types of acute conjunctivitis, symptoms presented by the different; Dr. A. Duane, ... 608
Choroidal lesion due to intestinal inflammation from ptomaine poisoning, Dr. C. S. Bull, ... 535
Congenital affections of eye following strong ante-natal impressions made on the mother, Dr. H. Derby, ... 530
Congenital anomaly in vitreous chamber and inner membranes of both eyes, Dr. C. J. Kipp, ... 279
Conjunctivitis nodosa, Drs. G. E. de Schweinitz and E. A. Shumway, ... 237
Cortical fusion of some color-sensations, Dr. C. H. Williams, . 290
Cyanosis retinae, Dr. W. C. Posey, ... 632
Cystadenoma of the lachrymal gland, Dr. E. Stieren, ... 323
Cyst of conjunctiva containing tooth-like structure, Dr. Edw. Stieren, ... 521
Cystic sarcoma of orbit, Dr. H. F. Hansell, ... 525
Degeneration involving central zone of the choroid and retina, Dr. Edw. Jackson, ... 150
Determination of the acuteness of vision, including the construction and gradation of optotypes, and systems of notation, Dr. Jno. Green, ... 644
Dextrocularity and sinistrocularity, pathologic results of, Dr. G. M. Gould, ... 306
Diseases of the eye in the white and negro races, Dr. H. D. Bruns, . 87
Discoloration of cornea by blood pigment and hemorrhage into cornea, Dr. O. F. Wadsworth, ... 594
Electro magnet, improved surgical methods for successful use of, Dr. R. Sattler, ... 460
Emphysema of orbit and lids (traumatic), Dr. H. F. Hansell, . . 326
Epithelial corneal cyst, Dr. J. H. Claiborne, ... 588
Excision of superior cervical ganglion of the sympathetic for simple glaucoma, Dr. C. W. Cutler, ... 397
Glaucoma (simple) with some unusual features, Dr. W. E. Lambert, ... 297

PAGE

Glaucoma (juvenile), Dr. R. Sattler, ... 519
Glaucoma (acute) incited by use of euphthalmine for diagnostic purposes, Dr. H. W. Ring, ... 109
Hemianopsia bi-temporal (case of) with remarkable fields, Dr. C. A. Veasey, ... 383
High-frequency currents in certain ocular conditions, Dr. J. C. Lester, ... 566
Hypopion ulcer of cornea — prognosis and treatment, Dr. C. J. Kipp, ... 275
Improvements in the refractometer for the correction of ametropia, Drs. Wm. and A. G. Thomson, ... 409
Importance of testing the ocular muscle balance for *near* as well as *distant* vision, Dr. S. Theobald, ... 377
Intra-capsular irrigation in cataract operations, Dr. H. O. Reik, . 64
Interstitial keratitis complicating ophthalmia neonatorum, Dr. A. A. Hubbell, ... 158
Intra-ocular tumor (congenital) containing epithelium and cartilage, Dr. A. N. Alling, ... 265
Intra-ocular tuberculosis, Dr. W. C. Posey, ... 244
Lantern for testing color-perception, Dr. C. H. Williams, . . 187
Leuco-sarcoma of choroid, Dr. T. R. Pooley, ... 137
Localizing foreign bodies by means of X-rays, Dr. J. E. Weeks, . 476
Magnetic properties of steel alloyed with other metals, Dr. W. M. Sweet, ... 470
Macular degeneration of cornea (two cases in family), Dr. C. A. Veasey, ... 387
Meibomian glands, hypertrophy and degeneration of, Dr. H. Knapp, 57
Memoir of Dr. W. F. Norris, Dr. S. D. Risley, ... 9
Melano-sarcoma of choroid, Dr. C. J. Kipp, ... 432
Melanoma of choroid and pigmented sarcoma of choroid, Drs. G. E. de Schweinitz and E. A. Shumway, ... 439
Mind-blindness, unique in that the entire mesial surface of both occipital lobes and both optic radiations were preserved, Dr. W. A. Holden, ... 286
Muscle of Horner and its relation to the retraction of the caruncle after tenotomy of the internal rectus, Dr. L. Howe, . . 319
Metastic carcinoma of ciliary body, Dr. C. W. Cutler, . . . 451
Neuro-retinitis and serous uveitis (sympathetic) following enucleation with implantation of glass globe — resection of optic nerve — recovery, Dr. R. Sattler, ... 337
Operations upon the eyeball in the presence of an infected conjunctival sac, Dr. C. S. Bull, ... 212
Ophthalmoplegia-externa bi-lateralis, Dr. W. E. Lambert, . . . 294
Optic atrophy following intestinal hemorrhage, Dr. W. M. Sweet, . 183
Optic neuritis, double traumatic, followed by absolute blindness and recovery, Dr. W. H. Wilmer, ... 165
Orbital cellulitis, with empyema of ethmoid and frontal sinuses, Dr. E. Gruening, ... 175
Orbital osteoma of ethmoidal origin, Dr. P. Fridenberg, . . . 83
Panophthalmitis following discission of the capsule, Dr. L. H. Taylor, ... 130
Persistent pupillary membrane, Dr. W. B. Marple, ... 593
Perforations of the macula lutea, certain non-traumatic; Dr. G. E. de Schweinitz, ... 228
Prism exercises; indications and technique, Dr. A. Duane, . . 300
Prolapse both lachrymal glands, Dr. D. Roy, ... 179
Ptosis (traumatic) operated according to method of Gruening or de Grandmont, Dr. W. B. Marple, ... 169

PAGE

Pulsating exophthalmos, of traumatic origin, ligation of common carotid — recovery, Dr. C. S. Bull, ... 38
Recurrent iritis, Dr. H. Woods, ... 501
Reflexes which can be properly referred to eye-strain, Dr. L. Howe, 491
Report of committee on standard test-types, etc., Dr. C. H. Williams, chairman, ... 189
with appendix by Jno. Green, ... 190
Retinitis pigmentosa (case of), Dr. W. L. Pyle, ... 172
Reversible test-types, Dr. C. H. Williams, ... 602
Sachs lamp for transillumination of the eye, Dr. E. S. Thomson, . 457
Skin-grafting in ophthalmic surgery, Dr. F. Buller, ... 134
Standards of vision. Report of committee on, ... 403
Subconjunctival injections (present status of) in ophthalmic therapeutics, Dr. C. S. Bull, ... 31
Symmetrical enlargement of parotid and lachrymal glands, nodular iritis, Dr. C. W. Cutler, ... 390
Tetartanopsia following toxic dose of salicylate of soda, Dr. J. H. Claiborne, ... 581
Terato-neuroma, a rare tumor arising from the pars ciliaris retinae, Dr. F. H. Verhoeff, ... 351
Tobacco amblyopia, possible etiological factors in, revealed by an analysis of the urine, Dr. G. E. de Schweinitz, ... 41
Tuberculosis of the conjunctiva, Dr. Edw. Jackson, ... 146
Tuberculosis of the eye (two cases), Dr. J. A. Spalding, . . 141
Tubercle of choroid, case of conglomerate, Dr. T. R. Pooley, . 256
Tumors of conjunctiva and cornea, Dr. J. M. Ray, ... 571
Uniform nomenclature of the movements and motor anomalies of the eye, Dr. A. Duane, ... 102
Uveitis treated with radium, Dr. C. H. Williams, ... 269
Vernal conjunctivitis in the negro, Dr. D. Roy, ... 556
Vicarious menstruation into retina followed by detachment and retinitis striata, Dr. P. Fridenberg, ... 116
Winking (the act of) and its photographic measurements, Dr. L. Howe, ... 332
X-ray treatment of inoperable cases of malignant disease of orbit, Dr. C. S. Bull, ... 540

INDEX OF AUTHORS.

Dr. A. N. Alling. Intra-ocular tumor (congenital) containing epithelium and cartilage, ... 265
Dr. H. D. Bruns. Diseases of the eye in the white and negro races . 87
Dr. C. S. Bull. Choroidal lesion due to intestinal inflammation from ptomaine poisoning, ... 535
Pulsating exophthalmos, of traumatic origin, ligation of common carotid — recovery, ... 38
Subconjunctival injections (present status of) in ophthalmic therapeutics, ... 31
Operation upon the eyeball in the presence of an infected sac, 212
X-ray treatment in inoperable cases of malignant disease of the orbit, ... 540
Dr. F. Buller. Skin-grafting in ophthalmic surgery, ... 134
Dr. C. F. Clark. Astigmatism, sixteen diopters of, corrected by galvano-cautery, ... 125
Dr. J. H. Claiborne. Epithelial corneal cyst, ... 588
Tetartanopsia following toxic dose of salicylate of soda, . 581

PAGE

Dr. C. W. Cutler. Excision of superior cervical ganglion of the sympathetic for simple glaucoma, ... 397
Metastatic carcinoma of ciliary body, ... 451
Symmetrical enlargement of parotid and lachrymal glands, nodular iritis, ... 390
Dr. H. Derby. Congenital affections of the eye following strong ante-natal impressions made on the mother, ... 530
Dr. A. Duane. Bacteriological types of acute conjunctivitis, symptoms presented by the different; 608
Prism exercises, indications and technique, ... 300
Uniform nomenclature of the movements and motor-anomalies of the eye, ... 102
Dr. Percy Fridenberg. Orbital osteoma of ethmoidal origin, . 83
Vicarious menstruation into retina followed by detachment and retinitis striata, ... 116
Dr. G. M. Gould. Dextrocularity and sinistrocularity, pathologic result of, ... 306
Dr. Jno. Green. Determination of the acuteness of vision, including the construction and gradation of optotypes and systems of notation, ... 644
Appendix to report of committee on standard test types, . 190
Dr. E. Gruening. Orbital cellulitis with empyema of ethmoidal and frontal sinuses, ... 175
Dr. H. F. Hansell. Cystic sarcoma of orbit, ... 525
Emphysema of orbit and lids (traumatic), ... 326
Dr. W. A. Holden. Mind-blindness, unique in that the entire mesial surface of both occipital lobes and both optic radiations were preserved, ... 286
Dr. L. Howe. Muscle of Horner and its relation to the retraction of the caruncle after tenotomy of the internal rectus, . 319
Reflexes which can be properly referred to eye-strain, . . 491
Winking (the act of) and its photographic measurements, . 332
Dr. A. A. Hubbell. Interstitial keratitis complicating ophthalmia neonatorum, ... 158
Dr. Edw. Jackson. Degeneration involving central zone of choroid and retina, ... 150
Tuberculosis of conjunctiva, ... 146
Dr. C. J. Kipp. Congenital anomaly in vitreous chamber and inner membranes of both eyes, ... 279
Hypopion ulcer of cornea, prognosis and treatment, . . 275
Melano-sarcoma of choroid, ... 432
Dr. H. Knapp. Meibomian glands, hypertrophy and degeneration of, ... 57
Dr. A. Knapp. Bacterial diagnosis of diphtheria bacillus, especially in diagnosis, ... 283
Dr. W. E. Lambert. Glaucoma (simple) with some unusual features, 297
Ophthalmoplegia, externa bilateralis, ... 294
Dr. J. C. Lester. High-frequency currents in certain ocular conditions, ... 566
Dr. W. B. Marple. Traumatic ptosis operated according to method of Gruening or de Grandmont, ... 169
Persistent pupillary membrane, ... 593
Dr. T. R. Pooley. Leuco-sarcoma of choroid, ... 137
Tubercle of choroid, case of conglomerate, ... 256
Dr. W. C. Posey. Cyanosis retinae, ... 632
Intra-ocular tuberculosis, ... 244
Dr. W. L. Pyle. Retinitis pigmentosa, ... 172
Dr. J. M. Ray. Tumors of conjunctiva and cornea, ... 571

PAGE

Dr. H. O. Reik. Intra-capsular irrigation in cataract operations, . 64
Dr. H. W. Ring. Acute glaucoma incited by use of euphthalmin for diagnostic purposes, ... 109
Dr. S. D. Risley. Memoirs of Dr. W. F. Norris, ... 9
Dr. Dunbar Roy. Prolapse of both lachrymal glands, ... 179
Vernal conjunctivitis in the negro, ... 556
Dr. R. Sattler. Angelucci's modification of the technique of the cataract operation, ... 342
Electro magnet, methods for successful use of, ... 460
Glaucoma (juvenile), ... 519
Neuro-retinitis and serous uveitis (sympathetic) following enucleation with implantation of glass globes, ... 337
Dr. G. E. de Schweinitz. Argyrosis of conjunctiva and lachrymal sac following use of Protargol, ... 161
Perforations of the macular lutea — certain non-traumatic, . . . 228
Tobacco amblyopia, possible etiological factors in, revealed by an analysis of the urine, ... 41
Drs. G. E. de Schweinitz and E. A. Shumway. Conjunctivitis nodosa, ... 237
Melanoma of choroid and pigmented sarcoma of choroid, . 439
Dr. J. A. Spalding. Tuberculosis of eye, two cases, ... 141
Dr. Edw. Stieren. Cyst of conjunctiva, containing tooth-like structure, ... 521
Cystadenoma of lachrymal gland, ... 323
Dr. W. M. Sweet. Magnetic properties of steel alloyed with other metals, ... 470
Optic atrophy following intestinal hemorrhage, ... 183
Dr. S. Theobald. Importance of testing the ocular muscle balance for *near* as well as for *distance*, ... 377
Are tenotomies for hyperphoria necessarily more uncertain in their results than those for esophoria and exophoria, . 154
Dr. E. S. Thomson. Sachs lamp for transillumination of eye, . . 457
Drs. Wm. and A. G. Thomson. Improvements in the refractometer for correction of ametropia, ... 409
Dr. L. H. Taylor, Panophthalmitis following discission of the capsule, ... 130
Dr. C. A. Veasey, Bi-temporal hemianopsia, with remarkable fields, ... 383
Macular degeneration of cornea, ... 387
Dr. F. H. Verhoff. Terato-neuroma, a rare tumor arising from the pars cilaris retinæ, ... 351
Dr. O. F. Wadsworth. Discoloration of cornea by blood pigment and case of hemorrhage into cornea, ... 594
Dr. J. E. Weeks. Localizing foreign bodies by X-rays, ... 476
Dr. W. H. Wilmer. Optic neuritis (double traumatic) followed by absolute blindness and recovery, ... 165
Dr. H. Woods. Recurrent iritis, ... 501
Dr. C. H. Williams. Cortical fusion of some color-sensations, . . 290
Lantern for testing color-perception, ... 187
Reversible test types, ... 602
Report of Committee on standard test types, etc., ... 189
Uveitis treated with radium, ... 269

41B
227



U. HOLZER BINDER